



A New 3D Reconstruction Method to Assess Anatomical Restoration in Vertebral Compression Fractures

David C. NORIEGA GONZALEZ, Gianluca MAESTRETTI, Thomas MITTLMEIER, Paul DUFORT, Peter-Jürgen MEEDER, Antonio KRÜGER

From the Valladolid and Marburg Universities

Deformation of the spine following vertebral compression fracture (VCF) can be associated with severe spinal dysfunction. Anatomical restoration is described as the complete reduction and stable fixation of the fracture with the goal to restore the pre-fracture local and global spine properties. The essential need to obtain endplate reduction, and consider the whole vertebral body in the management of vertebral fractures is pointed out. A new 3D imaging technique is described.

A new assessment method based on CT scans 3D reconstructions was developed. This new method was used to assess the anatomical restoration of the fractured vertebrae. A procedure consisting in placing two expandable titanium implants for fracture reduction, together with stabilization with a high viscosity PMMA cement was used to demonstrate the method.

The cases presented here are demonstrating that this 3D-mapping software is a tool which can address the lack of a valid, reproducible and user-friendly method to evaluate the anatomical restoration in VCF.

The evaluation of the anatomical restoration of the fractured vertebrae raises some issues in terms of interpretation because of a lack of consensus in the existing reporting methods. A 3D-reconstruction method, using CT scans and a newly-developed software, is proposed to evaluate the anatomical restoration in a clear, valid, reproducible and user-friendly way.

Keywords : vertebral compression fracture ; vertebral endplates ; 3D reconstruction ; anatomical restoration.

INTRODUCTION

Vertebral compression fractures (VCF) is a true concern in the aging population with 700 000 new osteoporotic VCF reported each year in the United States (9). The number of annual fractures and associated costs are predicted to rise by almost 50% by 2025 (3).

-
- David C. Noriega Gonzalez¹, Prof. Dr.
 - Gianluca Maestretti², Dr. Med.
 - Thomas Mittlmeier³, Prof. Dr.
 - Paul Dufort⁴, Ph. D
 - Peter-Jürgen Meeder⁵, Prof. Dr.
 - Antonio Krüger⁶, Prof. Dr.

¹Spine-Unit (PhD), University Hospital Valladolid, Royal Academy of Medicine and Surgery, Spain.

²Department of Orthopedic Surgery, Hôpital Cantonal Fribourg, Fribourg, Switzerland.

³Department of Trauma and Reconstructive Surgery University of Rostock, Germany.

⁴Computational Imaging Scientist, Joint Department of Medical Imaging Mount Sinai Hospital, University Health Network, Women's College Hospital, Toronto, Canada.

⁵University of Heidelberg, Heidelberg, Germany.

⁶Department of Trauma, Hand and Reconstructive Surgery, Philipps University Marburg, Germany.

Correspondence: Prof. Dr. David Cesar Noriega Gonzalez, Spine-Unit, University hospital Valladolid, Royal Academy of Medicine and Surgery, Valladolid, Spain.

E-mail : dcnoriega1970@gmail.com

© 2017, Acta Orthopaedica Belgica.

No benefits or funds were received in support of this study. The authors report no conflict of interests.

The progressive deformation of the spine as a result of the osteoporotic VCF can have severe clinical consequences such as chronic pain, reduction of the pulmonary function, and a negative influence of the quality of life, as well as a psychosocial impact with altered body image, depression and social withdrawal (6,18,19).

Currently, there are two main ways to reduce VCF. The first way is an indirect action exerted on the vertebral body using the ligamentotaxis effect by prone positioning of the patient. This treatment can be conservative and includes bed rest and analgesics, or can consist of minimal surgical procedures such as vertebroplasty or percutaneous instrumentation (8). In another way, forces are directly applied on the bone of the fractured vertebra (balloon kyphoplasty). These direct forces are supplemented by the forces due to the prone position of the patient during this procedure.

Although vertebral height restoration has been demonstrated, fractured endplates reduction is more or less limited. An incomplete treatment could cause different patterns of healing and of alteration of the discs which might be responsible of complications such as recurrent kyphosis after posterior reduction, or recurrent pain (13,15,16). Thus, a more comprehensive approach should take into account the anatomical restoration of the vertebral body geometry in whole, i.e. the cortical ring and endplates, and consider the sagittal alignment of the spine. Having an agreed definition of the anatomical restoration/reconstruction of vertebral fracture, and a consensual method to evaluate it, is essential.

Anatomical restoration in a VCF can be described as the complete reduction and stable fixation of the fracture with the goal to restore the pre-fracture local and global spine properties of the affected vertebral body. The global spine properties are defined by the sagittal and coronal angulations of the thoracic kyphosis and lumbar lordosis which are usually measured by the Cobb angles. Any change in spinal load leads to an imbalance of the system and results in alteration of spinal biomechanics and global spinal imbalance. These are important factors in the functional deficit associated with osteoporotic VCF and could increase the risk of

subsequent fractures (2,22). Therefore, the control of the sagittal-coronal balance is one essential parameter in the treatment of the VCF (17).

The reduction of the endplate fracture is a key point for the reconstruction of the vertebral body and the restoration of its biomechanical behavior (20). Restoration of the vertebral height and of the kyphosis angle is indeed not sufficient. The additional aim of the VCF reduction should be to restore the shape of the endplates and to replace them at their pre-fracture position in an attempt to restore the overall spinal alignment. In order to demonstrate the efficacy of the VCF reduction, the anatomic placement of the endplates with respect to the posterior elements should be evaluated by comparison with a normal non-fractured vertebra of the patient.

Today, the reporting of anatomical restoration in VCF is a real issue because no real consensus exists on how to measure and report the height restoration in VCF. This question was discussed for X-ray imaging technology by McKiernan et al. (14). The X-rays imaging protocol generally used produces biases and its reproducibility is insufficient (5). Even if new technologies, such as computed tomography (CT) bring better accuracy [7], the lack of consensus in methodology to evaluate height restoration makes the interpretation and comparison of results within and between studies difficult.

There are 4 methods most commonly used to report height. To estimate the height restoration all four methods used are described below. For all methods the abbreviations are a) = the reference vertebral height, b) = the initial fracture height and c) = the restored vertebral height.

- Method 1: Absolute restoration in mm = $c - b$
- Method 2: Percent restoration relative to the initial fracture height = $(c-b)/b \times 100$
- Method 3: Percent restoration relative to the lost vertebral height = $(c-b)/(a-b) \times 100$
- Method 4: Percent restoration relative to a reference vertebral height = $(c-b)/a \times 100$

Depending on the method selected, the outcome of vertebral restoration can markedly vary. In addition,

some vertebral height restorations are published in millimeters (mm) and others in percentages.

Independently from the imaging technique used, different values should be considered: (1) The size of a normal vertebra, i.e. the calculated shape of the vertebra pre-VCF, (2) the pre-operative size of the vertebra, and (3) its post-operative size.

In this work a 3D-reconstruction method using CT scans and a newly-developed software is proposed to evaluate anatomical restoration in a clear, valid, reproducible and user-friendly method (4,12). A new surgical procedure involving an intravertebral implant which could provide an anatomical restoration of the fractured vertebra including cortical ring reduction as well as endplate anatomical restoration has been used to demonstrate the new 3D reconstruction method (10,11).

METHODOLOGY

The lack of a standardized method and the heterogeneity of the existing protocols are analyzed on case based examples to illustrate the huge differences. To make the differences more illustrative, and to support our concept, we theoretically explain the weaknesses of the methods used in today's practice following McKiernan et al (14). Afterwards we introduce and illustrate a new measurement method on one of the cadaver models performed, and followed by a clinical case.

In order to understand the existing methods and their shortcomings, two simple examples were evaluated using each method. The first example illustrates a severe fracture and the second one a mild fracture:

Example 1: Severe fracture

- Normal vertebra (estimated based on the adjacent inferior and superior vertebrae [V-1 & V+1]) 30 mm
- Broken vertebra (pre-operative) 10 mm
- Restored vertebra (post-operative) 20 mm

Example 2: Mild fracture

- Normal Vertebra (estimation based on V-1 & V+1) 30 mm
- Broken vertebra (pre-operative) 20 mm
- Restored Vertebra (post-operative) 30 mm

Comparison of the methods regarding these 2 examples:

In the first method, where the absolute restoration method is applied, the vertebral height restoration is 10 mm in each case. With this method, the severity of the fracture is not really considered and the height restoration is not really assessed.

The second method over-estimates the height restoration in severe fractures because of the small denominator (initial fracture height). In the mild fracture example, the height restoration amounts to 50% whereas, for the severe fracture example, the height restoration is 100%.

In the examples provided, the height restoration evaluated with the third method is 100% and 50% for the mild and the severe fractures respectively. This method favors small restoration in mild fractures, and underestimates the clinical significance of the same restoration in more severely fractured vertebrae.

In the fourth method, a referent or a normative vertebral height is introduced but no reference to the fracture severity is made in this model. In the examples considered, the height restoration is 33% for both the mild and the severe fractures.

In order to objectively demonstrate restoration and compare the results obtained by the different treatment technologies, it is essential to define a clear, valid, reproducible and user-friendly method which would allow to assess not only the height restoration in a more precise way but also the anatomical restoration.

A method using 3D-reconstruction allowing to quantify this anatomical restoration has been developed in collaboration with medical image processing researchers at the Joint Department of Medical Imaging of the UHN (Toronto, CANADA). Using axial millimeter size slices from CT scan examinations, 3D-reconstructions can be obtained by automated segmentation technique. This method has been previously described (4,12) and further developed to allow a 3D-comparison between two or more longitudinal 3D-vertebral reconstructions. The software initially presents cross-linked axial, sagittal, and coronal views of the scan volume, and requires the operator to position each view's cross-hairs at the approximate center of the target

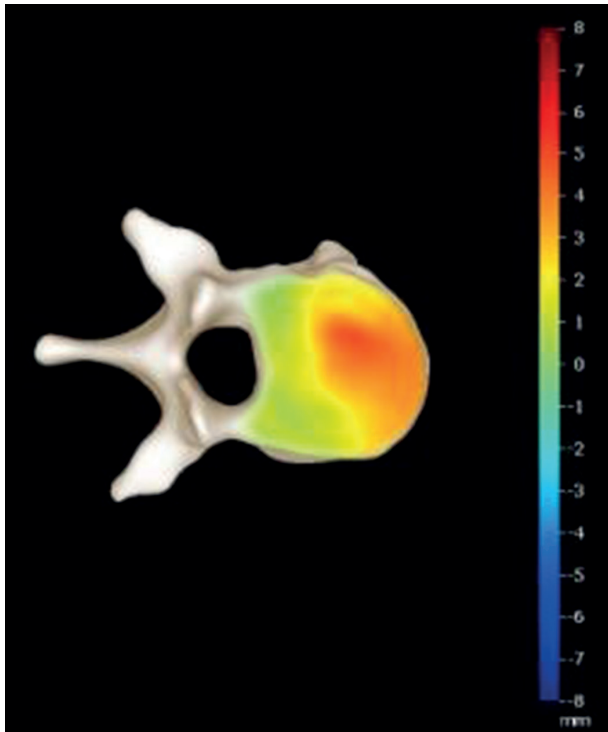


Fig. 1. — An example of a 3D reconstruction and the 3D mapping showing the 3D anatomical restoration.

vertebra, taking only a few seconds. After this, the algorithm is fully automated and completes the 3D reconstruction in approximately 1 minute per reconstructed vertebra. Once 3D reconstructions are obtained preoperatively and postoperatively for the same vertebra (Fig. 1), the two scans are rigidly registered in 3D and superimposed using the fact that the posterior arch is not affected either by the VCF or by the procedure itself. The two 3D-reconstructions are compared by calculating the distance between each point of the two reconstructed surfaces of the vertebra (pre and postoperative). This distance indicates the amount of restoration of each depressed area in mm. (Fig. 2).

The accuracy of these measurements depends on the CT scan slice thickness. In this application, each 3D-reconstruction is usually obtained thanks to millimeter size slices providing an accuracy of better than 1 mm. These 3D-reconstructions enable also to quantify the vertebral angular changes between the two endplates without any of the biases usually observed with techniques involving bi-planar projection of a 3D-object. Thus, based

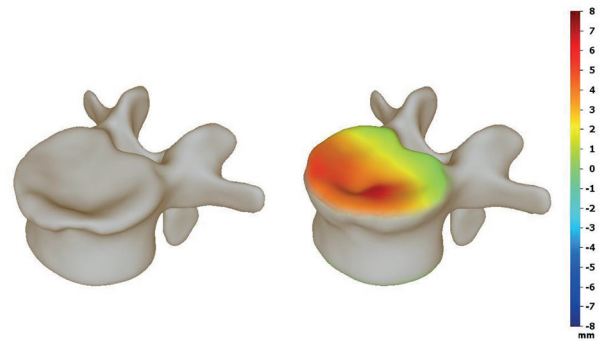


Fig. 2. — 3D mapping of the superior endplate of the anatomically restored vertebra. Colour codes refer to the amount of restoration of each depressed area.

on this 3D-reconstruction, the sagittal vertebral kyphosis angle can be determined using the projection of the two vertebral endplates in the sagittal plane (Fig. 3).

The 3D-mapping software is a tool which can address the lack of valid, reproducible and

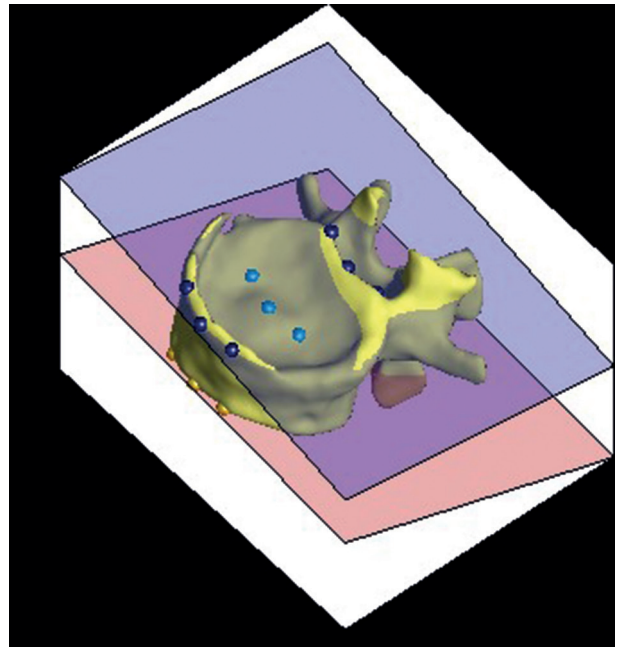


Fig. 3. — Determination of the vertebral angular changes. Based on the 3D-reconstruction, the sagittal vertebral kyphosis angle can be determined by using the projection of the two vertebral endplates in the sagittal plane. A procedure is repeated to produce nine unique points on each of the upper and lower vertebral endplates. The least-squares plane through these points is used to compute the angular orientation of the endplates. The angle measured is the difference between upper and lower vertebra endplates.

user-friendly method to evaluate the anatomical restoration in VCF. Such as an example, in figures 1 and 2, it may be easily understood that the most depressed of the endplate visualized in dark red in the tomogram has been restored.

RESULTS

Biomechanical test case

To demonstrate and illustrate the 3D software, vertebral body specimens from a biomechanical test performed, including 24 cadaveric vertebral bodies, could be used (11). A fresh human cadaveric single vertebra were CT scanned and dissected. A vertebral wedge compression fractures was created by a material testing machine (Universal testing machine, Instron 5566). After post fracture computed tomography the vertebral body was placed in a custom made loading frame with a preload of 100 N. The vertebral body was “treated” using SpineJack® (Vexim sa, France). A post treatment

computed tomography was performed. Anterior, central and posterior heights were measured pre- and post-fracture as well as after treatment. For the cadaveric vertebra the following results were documented (Tab.1) (Fig. 4, fig. 5)

Clinical case

A 50-year-old male working as a painter presented a traumatic A1.2 wedge fracture in T10 after a fall from 3 meter height. The evaluated pain preoperatively as an 8.3 using the VAS scale. The superior endplate showed a defect in the central part as shown in the preoperative CT scan (fig. 6) The patient was discharged 3 days after surgery with a significant reduction in pain from 8,3 to 2.1 at the VAS scale. The kyphosis vertebral angle was reduced by 80% (from 13.7° pre-op to 2.7° at discharge). As far as the anatomical reduction is concerned, the superior endplate was restored as shown by the 3D reconstruction, and the 3D mappings (fig.6, fig.7) are demonstrating that the two implants have made

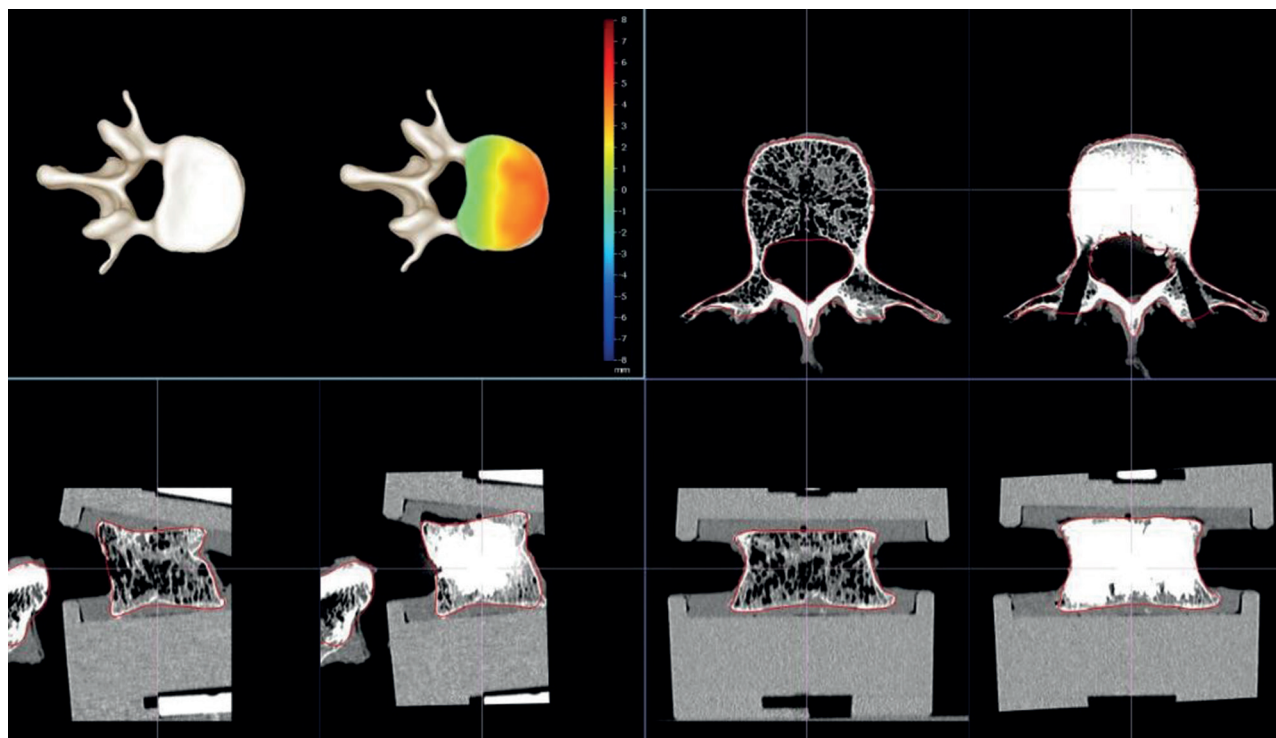


Fig. 4. — Preoperative and Postoperative CT scans of the vertebra used in a biomechanical test, giving evidence of the anterior height restoration, and the 3D mapping showing restoration of the superior endplate

Table 1. — Height measurements L2
Anterior, central and posterior heights were measured post-fracture as well as after the treatment

Height data	L2	
Fractured Anterior Height	21.29	
Fractured Central Height	20.56	
Fractured Posterior Height	25.75	
Restored Anterior Height	25.41	
Restored Central Height	22.45	
Restored Posterior Height	25.69	
Difference of heights between pre-op and post-op		L2
Fractured-Restored	Anterior Height	4.12
	Central Height	1.89
	Posterior Height	-0.06

Table 2.— Pre- and Post-op anterior, central and posterior height and Angle measurements
The superior endplate was restored as shown by the gain in anterior and central heights, demonstrating that the two implants managed successfully to reduce the fractured endplate.

Visit	HeightAM	HeightMM	HeightPM	Angl3D
Pre-op	14.831	17.559	19.778	13.709
Post-op	21.887	22.38	22.862	2.661

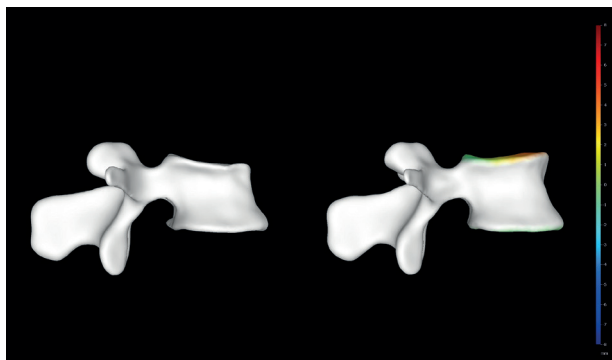


Fig. 5. — Profile view of same fractured vertebra as shown in fig.4, before (left) and after (right) fracture reduction with SpineJack® expandable implants.

it possible to reduce the fractured endplate before its stabilization with cement (Tab. 2).

DISCUSSION

This concept/definition of anatomical restoration presented here takes into account the vertebral body in whole, and tries to introduce the benefits of the

anatomical reduction of vertebral endplates in VCF treatment. The two main reasons for treating VCF in an anatomical way are (1) to achieve a complete reduction of the post traumatic vertebral kyphosis angle in order to avoid occurrence of late kyphosis and improve quality of life, and (2) to avoid the degeneration cascade due to an incomplete anatomical restoration of the endplate.

Height restoration and vertebral kyphosis angle reduction have already been described as beneficial for mortality risk reduction and improvement of the quality of life (1). The anatomical restoration as defined in this article takes into account the anatomy and geometry of the joint surface, the rehabilitation of its biomechanics and a stable fixation. Sagittal-coronal profile restoration of the level treated and endplate anatomical restoration shall enhance the clinical outcomes. The endplate depression after a vertebral fracture impairs the ability of the disc to distribute load evenly to the adjacent segments. Load concentration on the anterior portion of the adjacent vertebrae may

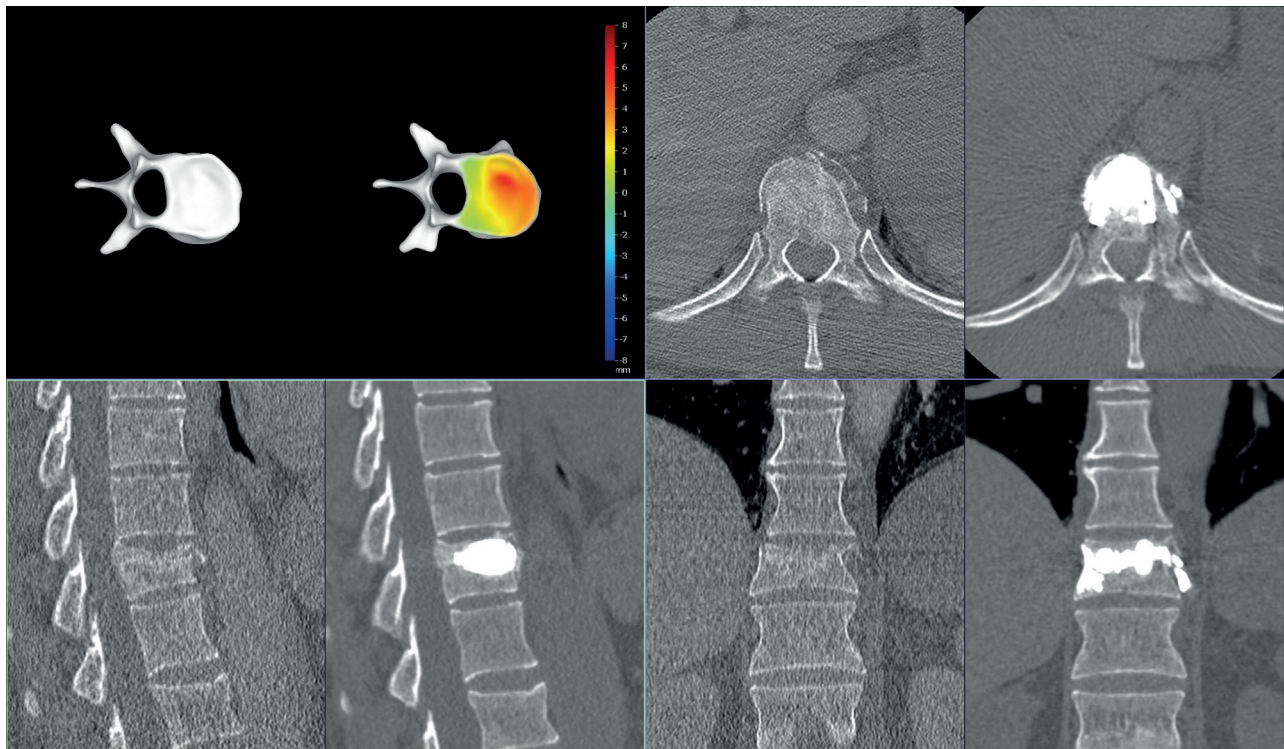


Fig. 6. — Preoperative and Postoperative CT scans of T10 vertebra evidencing anterior height restoration after the SpineJack® procedure was performed. A 3D mapping showing the amount of restoration of the superior endplate

contribute to increased subsequent fracture risk after an osteoporotic vertebral fracture (20). Therefore, the restoration of the endplates anatomy will allow to avoid changes in the load transfer through the disc, to reduce the risk of adjacent fractures, and to avoid disc creeping and degeneration, progressive kyphosis due to disc collapse, facet joint arthritic degeneration at adjacent level, and compensatory hyperlordosis (15).

Kyphoplasty allows to achieve a certain amount of height restoration, and to some extent kyphosis angle reduction. However, the placement of the inflatable balloon for the purpose of endplate fracture reduction in the desired intravertebral location might be difficult and uncontrolled. In fact, the direction of the balloon expansion tends to follow the path of least resistance, which might not be consistent with the height reduction direction. Part of the reduction is lost as a consequence of the hydrostatic counter pressure of the intervertebral disc and the viscoelastic-properties of the surrounding ligaments (21). In addition, the void created under the endplates after balloon inflation

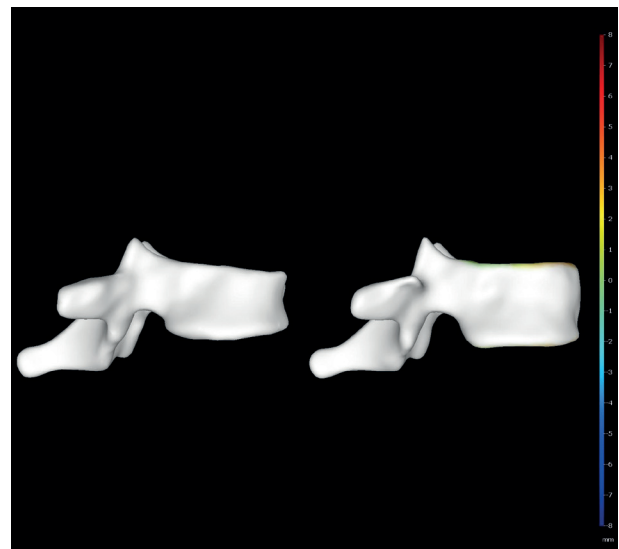


Fig. 7. — Profile view of same T10 vertebra as shown in fig.6, before (left) and after (right) fracture reduction with SpineJack®

may cause a decrease in axial strength because vertebral trabeculae are displaced to the periphery (21). The methods currently used to manage VCF need to be refined to achieve a better control of the

height restoration and kyphosis angle reduction. New devices developed over the last years are promising because they allow the surgeon to have a better control of the fracture reduction, including the endplate. In order to assess their efficiency and to compare the different procedures (conservatives, vertebroplasty, kyphoplasty and any other new procedure), a robust and clear method should be used to evaluate the anatomical restoration. This method does not only allow a comparison between the pre- and the post-treatment situation of the fractured vertebra level but allows also to compare the fractured vertebra post treatment with a non-fractured adjacent vertebra.

CONCLUSION

A 3D-evaluation method (3D-mapping software) is proposed to address the lack of a consensual method in assessing the effect of the reduction and stabilization procedures on the vertebral levels. This method, is to our knowledge, the first one allowing the evaluation of the endplate restoration in a precise and spatially measurable way. Clinical studies will need to confirm the benefits of this 3D-imaging technique in the management of VCF.

No support in any form was provided or will be provided by third parties to conduct this research. This study aims at investigating biomechanical and anatomical principles, not related to implants. No project-related funding.

Authors contributions:

Each author has made substantial intellectual contributions to this multicenter research. All authors read and approved the final manuscript.

Ethics committee approval, patients signed informed consent to publish the data.

REFERENCES

1. Alvarez L, Alcaraz M, Perez-Higueras A, Granizo JJ et al. Percutaneous vertebroplasty : Functional improvement in patients with osteoporotic compression fractures. *Spine* 2006 ; 31 : 1113-1118.
2. Black DM, Arden NK, Palermo L, Pearson J, Cummings SR. Prevalent vertebral deformities predict hip fractures and new vertebral deformities but not wrist fractures. Study of Osteoporotic Fractures Research Group. *J Bone Miner Res* 1999 ; 14 : 821-828.
3. Burge R, Dawson-Hudges B, Solomon DH, Wong JB, King A, Tosteson A. Incidence and economic burden of osteoporosis-related fractures in the United States, 2005-2025. *J Bone Miner Res* 2007 ; 22 : 465-475.
4. Dufort, P. Joint Segmentation and Deformable Registration of Fractured Vertebra Using a Synthesis of the Expectation Maximization and Belief Propagation Algorithms. Invited talk at the Special Session on Graph-Based methods in Medical Imaging, Fields-MITACS Conference on Mathematics of Medical Imaging, 2011 ; 20-24, University of Toronto, Toronto, Canada.
5. Grados F, Fechtenbaum J, Flipon E, Kolta S, Roux C, Fardellone P. Radiographics methods for evaluating osteoporotic vertebral fractures. *Joint Bone Spine* 2009 ; 76 : 241-247.
6. Hall SE, Criddle RA, Comito TL, Prince RL. A case-control study of quality of life and functional impairment in women with long-standing vertebral osteoporotic fracture. *Osteoporosis Int* 1999 ; 9 : 508-515.
7. Hiwatashi A, Wetesson PL, Yoshiura T et al. Kyphoplasty and vertebroplasty produce the same degree of height restoration. *AJNR Am j Neuroradiol* 2009 ; 30 : 669-673.
8. Heini PF. The current treatment— a survey of osteoporotic fracture treatment. Osteoporotic spine fractures : the spine surgeon's perspective. *Osteoporosis Int* 2005 ; 16 : S85–S92.
9. Hulme PA, Krebs J, Ferguson SJ, Berlemann U. Vertebroplasty and kyphoplasty : A systematic review of 69 clinical studies. *Spine* 2006 ; 31 : 1983-2001.
10. Krüger A, Baroud G, Noriega D et al. Height restoration and maintenance after treating unstable osteoporotic vertebral compression fractures by cement augmentation is dependent from the cement volume used. *Clinical Biomech* 2013 ; 28 : 725-730.
11. Krüger A, Oberkircher L, Figiel J et al. Height restoration of osteoporotic vertebral compression fractures using different intravertebral reduction devices : a cadaveric study. *Spine J* 2015 ; 15 : 1092–1098.
12. Le Pennec G, Campana S, Jolivet E, Vital JM, Barreau X, Skalli W. CT-based semi-automatic quantification of vertebral fracture restoration. *Comput Methods Biomech Biomed Engin.* 2014 ; 17 : 1086-95.
13. Lin CC, Wen SH, Chiu CH, Chen IH, Yu TC. The clinical influence of fluid sign in treated vertebral bodies after percutaneous vertebroplasty. *Radiology* 2009 ; 251 : 866-872.
14. McKiernan FE, Faciszewski T, Jensen R. Reporting height restoration in vertebral compression fracture. *Spine* 2003 ; 28 : 2517-2521.
15. Oner FC, Van der Rijt RR, Ramos LMP, Dhert WJA, Verbout AJ. Changes in the disc space after fractures of the thoracolumbar spine. *J Bone Joint Surg* 1998 ; 80-B : 833-839.
16. Ortiz AO and Bordia, R. Injury to the vertebral endplate-disk complex associated with osteoporotic vertebral

- compression fractures. *Am J Neuroradiol* 2011 ; 32 : 115-20.
- 17. Pradham BB, Hyun WB, Kropf MA, Patel VV, and Delamarter RB.** Kyphoplasty reduction of osteoporotic compression fractures : Correction of local kyphosis versus overall sagittal alignment. *Spine* 2006 ; 31 : 435-441.
- 18. Schlaich C, Minne HW, Bruckner T et al.** Reduced pulmonary function in patients with spinal osteoporotic fractures. *Osteoporosis Int* 1998 ; 8 : 261-267.
- 19. Silverman SL.** The clinical consequences of vertebral compression fracture. *Bone* 1992 ; 13 : S27-S31.
- 20. Tzermiadianos MN, Renner SM, Phillips FM et al.** Altered disc pressure profile after an osteoporotic vertebral fracture is a risk factor for adjacent vertebral body fracture. *Eur Spine J* 2008 ; 17 : 1522-1530.
- 21. Verlaan JJ, van de Kraats EB, Oner FC et al.** The reduction of endplate fractures during balloon vertebroplasty : A detailed radiological analysis of the treatment of burst fractures using pedicle screws, balloon vertebroplasty, and calcium phosphate cement. *Spine* 2005 ; 30 : 1840-1845.
- 22. Yuan HA, Brown CW, Phillips FM.** A biomechanical rationale for the clinical consequences and treatment of vertebral body compression fractures. *J Spinal Disord Tech* 2004 ; 17 : 236-242.