



Anterior lumbar interbody fusion using a hybrid graft

Mohamed Adel EL MASRY, Athansois KATSOCHIS, Walid Salaheldin BADAWY, Youssry Kamal EL HAWARY

From the Department of Orthopaedic Surgery, Cairo University, Cairo, Egypt

This prospective study evaluates the clinical and radiological results of anterior lumbar interbody fusion using a femoral cortical ring allograft (FCA) packed with cancellous autologous bone (hybrid graft), combined with posterior pedicular fixation but without posterior fusion, for symptomatic degenerative disease of the lumbar spine. Twenty-eight out of 30 consecutive adult patients were followed up for a minimum period of 2 years. Intra- and postoperative complications were seen in 2 out of 28 patients (7%) ; no complications resulted from the allografts. Clinically, 24 out of 28 patients (85%) had a good to excellent result, one patient (4%) a fair result, and 3 patients (11%) a poor result. Radiologically, the overall fusion rate by the level was 98% in 28 patients.

might be eliminated by anterior fusion. Several authors have described success with combined anterior and posterior fusion in case of chronic disabling low-back pain (9, 15, 17, 18), but there are few reports on combined anterior interbody fusion and posterior pedicle screw fixation without posterior fusion.

Various grafts have been described in the literature. The gold standard is the autogenous bone graft (5). However, there is evidence that the use of allograft bone in lumbar interbody fusion provides a union rate at least equal to that provided by autogenous bone (8). Consequently, a hybrid graft, consisting of a strong femoral cortical ring allograft (FCA) packed with cancellous autografts, may appear ideal as it provides both biomechanical and biological advantages.

INTRODUCTION

The management of chronic disabling low back pain has been problematic and controversial ; however, spinal fusion is an accepted method for treating patients with chronic disabling back pain (6).

Various fusion methods have been described in the literature, with various reports on their merits and outcomes. A meta-analysis of the published data on fusion showed that no one form of fusion is significantly better than the other, but there is some evidence suggesting better outcomes following anterior fusion (4). Moreover, Weinstein *et al* (21) have shown the nociceptive capability of the outer third of the annulus of the vertebral disc, which

■ Mohamed Adel El Masry, MD, Lecturer in Orthopaedic Surgery.

■ Athansois Katsochis, MD, Research Fellow.

■ Walid Salaheldin Badawy, MD, Lecturer of Orthopaedic surgery.

■ Youssry Kamal El Hawary, MD, Professor of Orthopaedic surgery.

Department of Orthopaedic surgery. Cairo University, Cairo, Egypt.

Correspondence : Mohamed A. El Masry, 3 Malvern Gardens, Wonford, Exeter EX2 5EG, UK.

E-mail : drmedoelmasry@yahoo.co.uk.

© 2004, Acta Orthopædica Belgica.

It has been postulated that restoration of the disc space height can be achieved, especially when using a rigid femoral cortical ring interbody graft. In several studies however this has been shown to be untrue, with loss of the disc space height, mainly because of graft subsidence into the adjacent vertebral bodies (1, 10).

The purpose of this study was to evaluate the clinical and radiological outcome of anterior interbody fusion using a hybrid graft, combined with posterior pedicle screw fixation in order to obtain rotational stability for the interbody graft, but without posterior grafting, in patients with symptoms due to lumbar disc disease. Posterior grafts were avoided, because they would be resorbed anyway, as observed by Gill and O'Brien (9).

MATERIALS AND METHODS

This prospective study included 30 consecutive adult patients who underwent anterior lumbar interbody fusion using a femoral cortical ring allograft (FCA) packed with autologous cancellous iliac crest graft (hybrid graft), combined with posterior pedicle screw fixation but without posterior fusion. There were 18 males and 12 females, with a mean age of 43 years (range, 32 to 58 years). Fifteen patients had primary degenerative disc disease, 14 had previous discectomy, and 1 had a failed posterolateral fusion. All were judged to have a significant reduction in their quality of life.

Patients were excluded from the study if they had a history of psychiatric illness, were involved in medicolegal claims or were receiving financial benefits for reported invalidity.

Preoperatively all patients were carefully assessed clinically and radiographically. Each patient also had an MRI of the lumbar spine to detect disc degeneration and, where relevant, nerve compression.

The femoral cortical ring allografts were processed by freeze-drying, and sterilised with ethylene oxide.

The surgical procedure consisted of a combined anterior and posterior exposure in one sitting. First an anterior retroperitoneal approach was made, so that the disc or discs could be exposed and excised. End plate preparation was achieved by curetting the cartilaginous layer down to punctate bony bleeding, with careful preservation of the subchondral bone. The left anterior iliac crest was exposed through a separate incision; only cancellous bone was harvested, using gouges. An appropriately sized FCA was chosen in function of depth and height

of the disc space, and fashioned with a burr. The FCA was packed with the cancellous autograft, and then impacted into the disc space. An AO screw and a washer were used to buttress the graft. The patient was then turned prone. A posterior midline incision was made. Subperiosteal dissection gave access to the posterior elements of the lumbar spine. The facet joint capsules were preserved, as posterior fusion was not contemplated. Pedicle screws and longitudinal rods were inserted. Postoperatively all patients wore a thoracic lumbar sacral orthosis for 12 weeks.

A total of 49 levels (n = 49) were fused in 30 patients. Eleven patients had a single level fusion (n = 11): 9 at the L5 / S1 level, and 2 at the L4 / L5 level. Nineteen had a double level L4 - S1 fusion (n = 38). Two patients had a concomitant L4/L5 discectomy and L5/S1 decompression.

The patients were routinely followed up, clinically and radiologically, at 3, 6, 9 months and then yearly. The minimum follow-up was 2 years (range, 2 to 3.3 years), except for two patients who were lost to follow-up after one year. These two patients were not included in the final evaluation: an acceptable drop-out ratio of 7%. Clinical assessment was performed using the scale described by Stauffer and Coventry (19). A good to excellent result was defined as 76% to 100% pain relief, return to previous employment status, and no or only slight restriction of activity. A fair result was defined as 26% to 75% pain relief, return to work with limitations, and mildly limited activities. A poor result included an outcome with less than 25% pain relief, no return to work, and greatly limited activities. From a radiological viewpoint fusion was considered solid when no lucent line was present between the graft and the adjacent vertebral body, and no shift or breakage of the instrumentation had occurred.

RESULTS

As mentioned, 28 out of 30 patients were available to follow-up at two years. Excellent to good results were achieved in 24 patients (85%), a fair result in one patient (4%), and poor results in 3 patients (11%). Considering excellent and good results as satisfactory, 24 out of 28 patients (85%) were judged to have a satisfactory clinical outcome. There was no difference in clinical outcome between primary and secondary cases.

Twenty-seven patients achieved a solid fusion (fig 1), and only one patient had a non-union. The

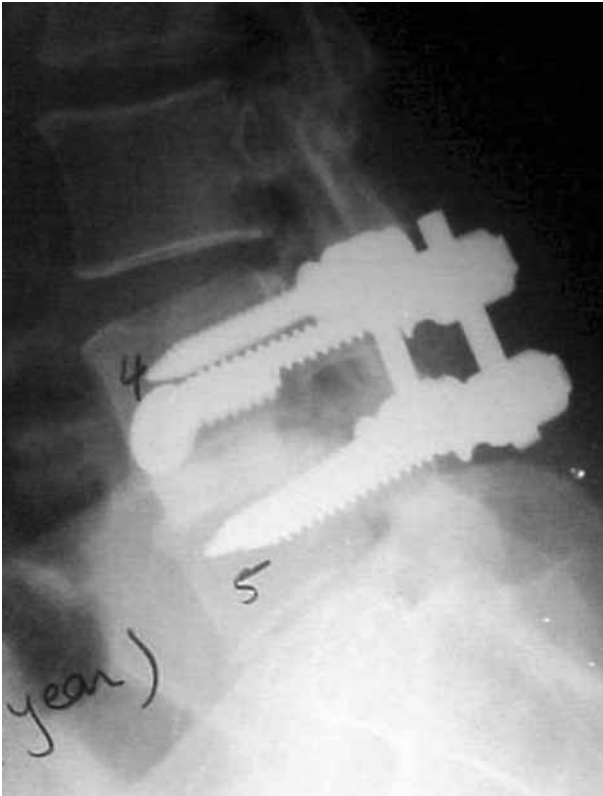


Fig. 1. — Lateral view, one year postoperatively, showing a well united femoral cortical ring allograft at the L4/5 level (one level fusion).

overall fusion rate by level was 98%, or 45 out of 46 levels, in 28 patients. A solid fusion was also achieved in all patients who had previous spinal surgery. Allograft remodelling appeared to be slow ; most of the grafts still appeared to be quite dense. Only 4 of the 46 allografts were felt to be totally incorporated at 2 years follow-up.

Complications were seen in 2 cases (7%). Intraoperatively, one patient had a tear of the left common iliac vein which was repaired. Postoperatively, one patient had an incisional hernia which was managed conservatively. There were no infections, no neurological problems and no graft-related complications.

DISCUSSION

The advantage of anterior lumbar interbody fusion is the fact that the large subchondral cancel-

lous area along the vertebral end plates, and the compressive loads present at the fusion site, facilitate fusion. An additional benefit is the removal of the pain source itself.

The disadvantages of anterior lumbar interbody fusion are mainly related to the possible serious complications associated with the anterior exposure of the lumbar spine, namely vascular injury and retrograde ejaculation. In this study only one vascular injury was seen, and it was successfully repaired intraoperatively ; retrograde ejaculation was not reported. This study clearly shows that the anterior retroperitoneal lumbar exposure is safe, provided that a meticulous technique is adopted.

If the goal is to use an interbody graft that can tolerate loads, exceeding those which are to be transmitted in the postoperative period, the use of cortical bone grafts becomes an important consideration. The strength advantage of cortical bone is immediately obvious, although the union rate associated with cortical bone is certainly less than that of cancellous products (12). Estimates of lumbar *in vivo* loads have ranged from 340 to 725 kg for static loads, and to 906 kg. for high-level loads. The compressive strength of iliac allograft products ranges from 180 to 668 kg., whereas the compressive strength of femoral cortical allografts is in excess of 6874 kg. From an autograft standpoint the only available cortical bone is that of the fibula ; however, the donor site morbidity is prolonged (5). The use of femoral cortical ring allografts, packed with cancellous autograft (hybrid graft), will allow capitalising on the mechanical strength of the allograft and on the biological strength of the autograft (12).

The femoral cortical ring allograft will be stable in both flexion and extension, but lacks rotational stability ; the posterior fixation will provide this and will lead to a better fusion rate. Indeed, a retrospective analysis of 101 patients by Pettine *et al* (16) demonstrated that the fusion rate of the hybrid graft was higher if adjuvant posterior pedicle screw fixation was used (16). Although the use of rigid posterior fixation is essential to provide the required mechanical stability for interbody graft incorporation, there is no need for adding a

posterolateral graft, as this graft will be deprived from the proper mechanical forces, with subsequent resorption (9). There is abundance of evidence to suggest that the use of allograft bone in lumbar interbody fusion provides a union rate at least equal to that provided by autogenous bone (3). Moreover, the presence of multiple marrow elements, only millimeters away, would well allow the use of allografts.

In the current study there were no complications related to the hybrid allograft and no cases of infection.

There was lack of correlation between the radiological and clinical outcome in 4 patients who reported themselves as having a less satisfactory clinical outcome despite a solid fusion. Two of these patients had the procedure as a revision, and two as primary surgery. The poor clinical outcome in patients with revision surgery has been previously documented, among others by North *et al* (14); they reported only 33% of good results in a retrospective review of 102 patients with failed back surgery syndrome. There was however no evident explanation for the poor outcome in the 2 cases from our primary group; Fritzell *et al* (6) felt that restoring a patient with chronic lumbar back pain to normal status is beyond the expectation of surgical fusion, regardless of the technique used.

From a general view-point, Fujimaki *et al* (7) advocate *anterior* interbody fusion as a salvage procedure on the basis of better vascularity and better mechanical support in the anterior column of the spine. A scar from previous *posterior* surgery will lead to a poor vascular bed for the bone graft and so to failure (11, 20). This study clearly shows that solid fusion was obtained in all 15 secondary procedures, including the failed posterolateral fusion. The current authors continue to support the effectiveness of anterior lumbar interbody fusion in revision surgery, as their results compare favourably with the best results reported in the literature (2, 10, 13).

As to the future, the authors believe that improved anterior instrumentation would avoid the necessity to add posterior instrumentation, so avoiding, among others, disruption of the posterior musculature, and spinal stenosis (4).

REFERENCES

1. Bendo JA, Spivak JM, Neuwirth MG, Chung P. Use of the anterior interbody fresh-frozen femoral head allograft in circumferential lumbar fusions. *J Spin Disord* 2000; 13 : 144-149.
2. Cohen DB, Chotivichit A *et al*. Pseudarthrosis repair. Autogenous iliac crest versus femoral ring allograft. *Clin Orthop* 2000; 371 : 46-55.
3. Crock HV, Bedbrook G. *Practice of Spinal Surgery*. Springer Verlag, New York, 1983.
4. Fraser RD. Interbody, posterior, and combined lumbar fusions. *Spine* 1995; 20 : 167S-177S.
5. Freivalds A, Chaffin DB, Garg A, Lee KS. A dynamic biomechanical evaluation of lifting maximum acceptable loads. *J Biomech* 1984; 17 : 251-262.
6. Fritzell P, Hagg O, Wessberg P *et al*. Lumbar fusion versus nonsurgical treatment for chronic low back pain : a multicenter randomized controlled trial from the Swedish lumbar spine study group. *Spine* 2001; 26 : 2521-2532.
7. Fujimaki A, Crock HV, Bedbrook GM. The results of 150 anterior lumbar interbody fusion operations performed by two surgeons in Australia. *Clin Orthop* 1982; 165 : 164-167.
8. Gill K. Technique and complications of anterior lumbar interbody fusion. In : Lin PM, Gill K (eds). *Lumbar Interbody Fusion*. Aspen Publishers, Rockville, 1984.
9. Gill K, O'Brien JP. Observations of resorption of the posterior lateral bone graft in combined anterior and posterior lumbar fusion. *Spine* 1993; 18 : 1885-1889.
10. Holte DC, O'Brien JP, Renton P. Anterior lumbar fusion using a hybrid interbody graft. A preliminary radiographic report. *Eur Spine J* 1994; 3 : 32-38.
11. Hurley LA, Stinchfield FE, Bassett AL, Lyon WH. The role of soft tissues in osteogenesis. An experimental study of canine spine fusions. *J Bone Joint Surg* 1959; 41-A : 1243-1254.
12. Kozak JA, Heilman AE, O'Brien JP. Anterior lumbar fusion options. Technique and graft materials. *Clin Orthop* 1994; 300 : 45-51.
13. Liljenqvist U, O'Brien JP, Renton P, Halm H. Simultaneous combined anterior and posterior lumbar fusion with femoral cortical allograft. *Eur Spine J* 1998; 7 : 125-131.
14. North RB, Campbell JN, James CS *et al*. Failed back surgery syndrome : 5-year follow-up in 102 patients undergoing repeated operation. *Neurosurgery* 1991; 28 : 685-690.
15. O'Brien JP, Dawson MHO, Heard CW *et al*. Simultaneous combined anterior and posterior fusion. A surgical solution for failed spinal surgery with a brief review of the first 150 patients. *Clin Orthop* 1986; 203 : 191-195.
16. Pettine K, Salib R. Femoral diaphyseal allograft for anterior lumbar interbody fusion (abstract), 6th Annual meeting, North American Spine Society, 1991.

17. **Selby DK, Henderson RJ.** Circumferential (360 degree) spinal fusion. In : Frymoyer JW(ed). *The Adult Spine : Principles and Practice*. Raven Press, New York, 1991.
18. **Slosar PJ, Reynolds JB, Schofferman J et al.** Combined anterior and posterolateral lumbar fusions : primary and revision procedures (abstract), 9th Annual meeting, North American Spine Society, 1994.
19. **Stauffer RM, Coventry MB.** Posterolateral lumbar-spine fusion. *J Bone Joint Surg* 1972 ; 54-A : 1195-1204.
20. **Steinmann JC, Herkowitz HN.** Pseudarthrosis of the spine. *Clin Orthop* 1992, 284 : 80-90.
21. **Weinstein J, Claverie W, Gibson S.** The pain of discography. *Spine* 1988 ; 13 : 1344-1348.