



## Evaluation of intra-operative imaging during scarf osteotomy – an unnecessary cost or an essential prerequisite?

George COOPER, Yue Yang LI, Abhijit GUHA

*From the Worcestershire Acute Hospitals NHS trust, UK*

Scarf osteotomy is an effective surgical treatment option for hallux valgus. It can manipulate alignment in three planes, allowing accurate anatomical correction. The potential benefit of intra-operative image intensification (II) to gauge deformity correction during surgery however, has not been quantitatively reported. This study aims to compare the correction of hallux valgus by scarf osteotomy with and without intra-operative imaging.

Retrospective analysis of a consecutive series of scarf osteotomy in 2 groups. Group A had intra-operative radiographic assessment and group B did not. Patient and surgical data was collected with a mean follow-up of 14 months.

Of 99 scarf osteotomies there was no significant difference in age, gender or pre-operative deformity between the groups ( $p < 0.05$ ). No statistical difference was found between the radiographic corrections of the two groups ( $p < 0.05$ ), although operating time was less in group B.

This series shows that intra-operative imaging does not improve accuracy of deformity correction, or implant position in scarf osteotomy. We suggest it is not required routinely during scarf osteotomy.

**Keywords:** Scarf osteotomy; Hallux valgus; intra-operative imaging

### INTRODUCTION

Adult idiopathic primary hallux valgus is a progressive deformity of the first metatarsophalangeal

joint (MTPJ) with a pooled prevalence, in the over 65 year old age group, of up to 36%.<sup>13</sup> While non-operative management has recognised benefits, randomised prospective studies have shown surgical correction can lead to superior functional outcomes in symptomatic patients (22).

Of the numerous procedures reported, the scarf osteotomy first described by Weil (4) and further popularized by Barouk (2), has gained significant popularity and remains to date, one of the most effective surgical procedures used to address moderate to severe deformity.<sup>(20,9)</sup> It has widely been reported to improve alignment as well as validated outcome scores (AOFAS, SF-36 and VAS) in the mid to long term (6,1,10,11).

The deformity in idiopathic hallux valgus progresses in three planes and thus correction about a single centre of rotation cannot fully restore the normal alignment. The scarf osteotomy offers flexibility to address longitudinal alignment, translation and rotation. Calculating the amount of combined tri-planar correction via intra-operative operator assessment is subjective and non-standardised. Recurrence, associated with under

- George Cooper.
- Yue Yang Li.
- Abhijit Guha.

*Worcestershire Acute Hospitals NHS trust, UK.*

Correspondence : George Cooper, Worcestershire Acute Hospitals NHS trust, United Kingdom.

E-mail : george.cooper@nhs.net

© 2017 Acta Orthopaedica Belgica.

*No benefits or funds were received in support of this study.  
The authors report no conflict of interests.*

Acta Orthopaedica Belgica, Vol. 84 - 2 - 2018

correction (elevated distal metatarsal metaphyseal angle (DMMA)) may be avoided if more accurate correction can be achieved at the index procedure (17).

To improve accuracy, O'Briain et al have reported the use of geometric formula, to provide objective assessment pre-operatively to guide correction, to improve radiological outcomes (14). This technique however has multiple measurements, and final assessment of correction is still only confirmed after post-operative x-rays. The routine use of post-operative x-rays following scarf osteotomy has no significant effect on outcome and Blundell et al recommend their use only where clinically indicated (3).

Intra-operative x-ray imaging, however, can assess the alignment on the operating table and allow immediate adjustment of correction or implant position if required. It is more commonly used than geometric formulae, although there is no consensus as to whether it may improve accuracy of correction. Its use is therefore a topic of debate.

This study aims to compare the anatomical correction of hallux valgus surgery achieved by scarf osteotomy with and without the use of intra-operative imaging. Secondly we aim to assess the impact of such imaging upon surgical time and health economics.

## MATERIAL AND METHODS

Retrospective review of our units' database identified all patients who underwent consecutive

surgical management, by scarf osteotomy, of adult idiopathic primary hallux valgus, between January 2013 and December 2014 under the care of the senior author. Clinical review was undertaken pre and post-operatively in clinic with weight bearing radiographs. Case notes were reviewed to obtain patient demographics, details of surgery and complications. The pre and post-operative weight bearing radiographs were reviewed by the lead authors who were blinded to the use, or not, of intra-operative radiography (Fig. 1 and 2). Measurement of the inter-metatarsal angle (IMA), hallux valgus angle (HVA) and DMMA was performed using an electronic tractograph as reported by Robinson et al. 16 Patients were excluded if they had undergone previous foot and ankle surgery.

The patient population was divided into 2 groups; those who underwent scarf osteotomy with intra-operative imaging (group A) and those who underwent scarf osteotomy without intra-operative imaging (group B). The indication for surgery, irrespective of intra-operative imaging availability, was symptomatic moderate to severe hallux valgus, assessed pre-operatively in outpatient clinic with weight-bearing radiographs. Once operative management had been agreed, surgery was undertaken with no relation to the use of intra-operative imaging. Where available, which was random according to demand elsewhere, imaging was used in two orthogonal planes and patients were unaware of its use during surgery. There was no change in practice and the same differential pitch screw system, senior surgeon, and post-operative

Table I. — Baseline results between group A and group B

	Group 1 (Intra-operative imaging used)	Group 2 (intra-operative imaging not used)	P value
Mean age	56.2	57.0	0.967t
Gender (M/F)	3/28	3/48	1.000*
Laterality (right/left)	19/18	34/28	0.683*
Additional Akin procedures	21	43	0.199*
Mean pre-operative IMA (degrees)	15.35	15.43	0.905t
Mean pre-operative HVA (degrees)	35.7	34.0	0.8773t
Mean pre-operative DMMA (degrees)	32.3	31.4	0.965t
Mean follow up (months)	16	13	0.068t

t = Student t-test, \* = Fishers exact test (2 tailed).

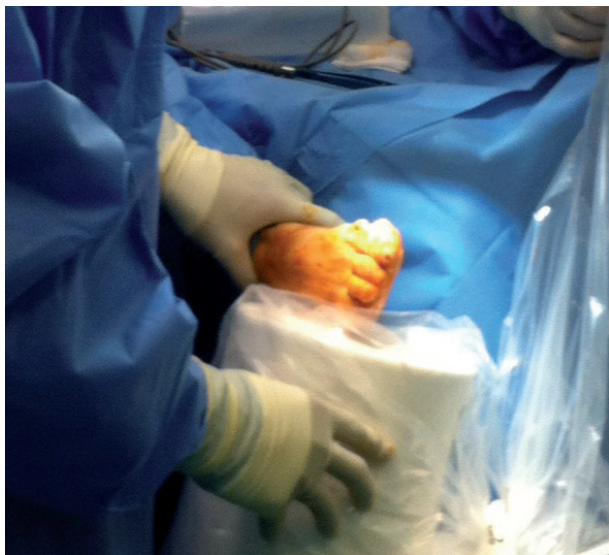

Fig.1.

regimen were used for all patients. A single calibrated Insight 2 (Hologic UK, Crawley, Sussex) mini c arm machine was used for intra-operative radiographic assessment and was positioned to achieve dorsoplantar weight bearing and lateral views of the forefoot to include the tarsometatarsal joint to the distal phalanges, with the ankle in the plantigrade position (Fig. 2). Images were assessed during the procedure and prior to wound closure.

Data was analysed and described with frequencies and percentages, and outcomes were compared using the student's t-test for continuous variables and Fishers exact test for categorical data.

## RESULTS

99 consecutive scarf osteotomies were identified with or without an Akin procedure. There were 6 males and 76 females. The mean age at treatment was 57 years (range 26-80) and the mean follow

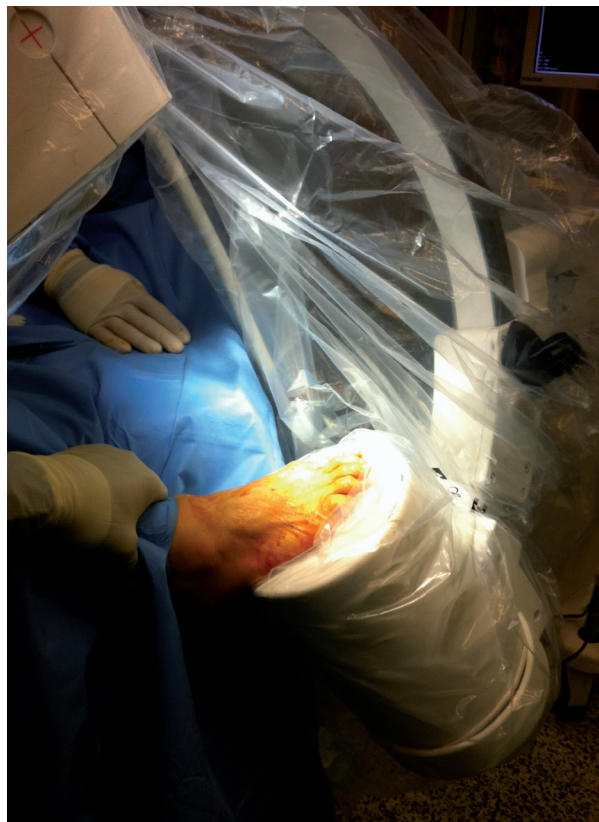


Fig.2.

up was 14.1 months. There were 37 procedures on 31 patients in group A and 62 procedures on 51 patients in group B. When comparing groups A and B, there was no statistical difference in age, gender, pre-operative deformity, follow up, laterality or the number of adjunctive Akin osteotomies performed between the two groups (Table I).

The mean overall pre-operative IMA, HVA and DMMA were 15.4 (95% CI 14.75-16.06), 34.8 (95% CI 33.27-36.32), and 32.5 (95% CI 30.70-34.31) respectively. The overall mean surgical time was 47 minutes. The mean interventional radiation

Table II. — Comparison of mean correction achieved for group A and group B

	Group 1 (Intra-operative imaging used)	Group 2 (intra-operative imaging not used)	P value (unpaired student's t-test)
Mean IMA correction (degrees)	7.84	8.00	0.820
Mean HVA correction (degrees)	21.32	21.95	0.792
Mean DMMA correction (degrees)	18.11	20.18	0.265
Surgical time (minutes)	50.7	44.9	0.045

exposure, where intra-operative imaging was used, was 1.25 mGy-cm<sup>2</sup>.

The mean improvement in IMA, HVA and DMMA was 7.84, 21.32 and 18.11 respectively for group A and 8.00, 21.95 and 20.18 respectively for group B. There was no statistical difference in the correction achieved between the 2 groups, but the operating time was 5.7 minutes less in group B ( $p = 0.045$ ) (Table II).

One patient (group A) required metalwork removal for prominence after the osteotomy had united and one other patient had a superficial infection (also group A) which was treated successfully with antibiotics. One separate patient (group A) had persistent pain, although has not required further surgery at latest follow up.

## DISCUSSION

The scarf osteotomy is known to achieve successful correction of hallux valgus and our results are comparable to previously reported anatomical corrections (7,9). These improvements are reported in conjunction with improved functional outcomes (AOFAS, SF-36 and VAS). Whilst patient satisfaction, assessed by questionnaire however, has been reported to be higher with greater correction of HVA and IMA23, the association between degree of correction and improvement in function, does not appear to be a direct correlation (3). Okuda et al (2008) found no difference between the pre-operative severity and functional outcome (AOFAS) when performing a distal soft tissue procedure combined with an osteotomy (15). Whilst functional improvement goes hand in hand with anatomical restoration, Thordarson et al suggest that the magnitude of pre-operative deformity, post-operative deformity and correction does not significantly influence the amount of improvement in validated outcome measures (AOFAS, SF-36) for the chevron, modified McBride and modified Lapidus procedures (21). In addition, hallux valgus correction has been reported to improve quality of life related outcomes independent to the severity of deformity (18). This would support the view that variation of a few degrees in the corrected position may not be of clinical relevance.

In our study, the use of intra-operative II did not confer any benefit to the precision or accuracy of correction of hallux valgus by the scarf osteotomy with or without an Akin procedure. We therefore suggest that it offers no benefit in functional outcome. Of the 3 complications reported, all happened to be in the intra-operative imaging group – suggesting metalwork prominence can be a problem even despite intra-operative imaging. We put forward that scenarios of metalwork malposition can be reliably prevented simply with the use of direct vision and palpation during surgery. This 3-dimensional visual assessment in addition to palpation is likely to be superior to relying on 2-dimensional imaging to assess metalwork position, as all implant related complications occurred in the x-rayed group. As previously reported, it is in symptomatic patients that post-operative x-rays are indicated, and the combination of clinical acumen and post-operative radiology may be more sensitive at identifying surgical complications than intra-operative imaging alone.

Although intra-operative x-rays are not weight bearing films, a recent study found that assessment of radiographic parameters was independent of the weight bearing status during exposure, and thus intra-operative imaging (Fig. 1) may be sufficient to provide an accurate record of the correction achieved for medico-legal purposes, if so desired (5). However, the justification behind recording the degree of correction, merely as a medico-legal tool to establish correction obtained intra-operatively is somewhat insufficient due to the aforementioned evidence showing that outcome is not necessarily correlated with the achieved final correction. Minor degrees of mal-alignment are therefore unlikely to be identified as direct causation in review of cases with an unsatisfactory outcome hence disregarding the importance of intra-operative imaging for documentation purposes alone.

When considering the ionizing radiation in deciding to expose a patient to x-rays, the practitioner must have a full knowledge of the potential advantage and detriments associated with the procedure, and show a net benefit from the intervention (8). Despite our finding that the mean dose is very small, our results show no “net benefit”. Additionally



the cumulative logistical and economic burden of regular intra-operative II is significant due the high prevalence of this condition (13). Whilst we recognize that an imaging machine may need to be available elsewhere and hence the overlay cost of the machine and staff may still be required for any particular health service, a reduction in use leads to less maintenance and requirement of staff training hours as well as further availability where it is known to be of benefit. We found the surgical time to be significantly reduced when intra-operative II was not used, as one would expect. Whilst 5 minutes may not be considered to be clinically significant the financial saving of reduced training and maintenance, however, may well be.

There are important technical points of the scarf osteotomy that may explain why intra-operative II is not required to improve bony correction or outcome. Firstly the lateral release, which is crucial to ensure correction of the sesamoid sling, is essential to achieving correction and reducing the chance of recurrence as is other soft tissue balancing (19). These substantial soft tissue components of the scarf procedure are critical steps in achieving the desired alignment, and are easily visualised by the naked eye. Secondly, the careful exposure of the distal aspect of the 1st metatarsal not only protects the neurovascular structures of the medial plantar bundle, but allows visualization of the diaphyseal axis, DMMA and articular surface to accurately align the osteotomy cuts and position screws under direct vision (7,12).

We observe that the use of minimally invasive procedures is becoming more popular, and the major reduction in bone exposure necessitates the mandatory use of intra-operative II to gauge overall bony correction in conjunction with the clinical appearance. Formal open procedures, such as the scarf osteotomy, however, remain the gold standard for comparison.

More long term studies are required to assess the possibility of recurrence, and significantly higher patient numbers would probably be required to identify any long term effect. Reasons for recurrence are multifactorial and we suggest that using II will not impact these although further long term studies are required to establish this.

We also appreciate that this study is retrospective in nature, but feel that the assessor blinding and the fact that II was deployed independent of clinical deformity and symptoms (albeit not prospectively randomised) are relative strengths to support the recommendation that II is not required routinely in scarf osteotomy. Furthermore we suggest that scarf osteotomies can be safely performed in regional centres, such as day units, where II is not necessarily available, with no detriment to correction achieved or outcome.

In addition it may be that outcomes (anatomical and functional) of other procedures, such as 1<sup>st</sup> MTPJ arthrodesis, are not improved by intraoperative II, and any such effects should be assessed in further studies.

## CONCLUSIONS

Scarf osteotomy is a safe and effective method to treat symptomatic patients with hallux valgus. Correction of bone alignment is one part of the corrective procedure and in isolation does not appear to directly correlate to functional gains. Our results show that using intra-operative imaging does not improve surgical accuracy or precision of bone deformity correction and therefore does not directly improve surgical outcome. Whilst we suggest that the use of intra-operative II is not indicated for routine scarf osteotomy, it is essential during minimally invasive forefoot surgery and can be a useful surgical adjunct to gauge alignment in more complex deformity correction.

## REFERENCES

1. **Aminian A, Kelikian A, Moen T.** Scarf osteotomy for hallux valgus deformity: an intermediate follow up of clinical and radiographic outcomes. *Foot Ankle Int* 2006 ; 27 : 883-886.
2. **Barouk L.** Scarf osteotomy of the first metatarsal in the treatment of hallux valgus. *Foot Dis* 1991 ; 2 : 35-48.
3. **Blundell C, Murphy R.** Are postoperative X-rays needed following surgery for hallux valgus? An evaluation of their use after scarf osteotomy. *Ann R Coll Surg Engl* 2007 ; 89 : 281-4.
4. **Borrelli A, Weil L.** Modified scarf bunioneectomy: our experience in more than 1000 cases. *J Foot Surg* 1991 ; 30 : 609-22.

5. **Burg A, Hadash O, Tytiun Y, Salai M, Dudkiewicz I.** Do weight-bearing films affect decision making in hallux valgus surgery? *J Foot Ankle Surg* 2012 ; 51 : 293-5.
6. **Choi J, Zide J, Coleman S, Brodsky J.** Prospective Study of the Treatment of Adult Primary Hallux Valgus With Scarf Osteotomy and Soft tissue alignment. *Foot Ankle Int* 2013 ; 34 : 684-90.
7. **Coughlin MJ, Mann RA, Saltzman CL.** Surgery of the Foot and Ankle. 8th ed. Part I, Chapter 6: Hallux valgus. Philadelphia : Mosby Elsevier ; 2007. Department of Health. The Ionising Radiation (medical exposure) regulations 2000. [www.gov.uk/government/publications/the-ionising-radiation-medical-exposure-regulations-2000](http://www.gov.uk/government/publications/the-ionising-radiation-medical-exposure-regulations-2000)
8. **Fakoor M, Sarafan N, Mohammadhoseini P, Khorami M, Arti H, Mosavi S, Aghaeeghadam A.** *Arch Bone Jt Surg* 2014 ; 2 : 31-6.
9. **Jones S, Al Hussainy H, Ali F, Betts R, Flowers M.** Scarf osteotomy for hallux valgus. A prospective clinical and pedobarographic study. *J Bone Joint Surg Br* 2004 ; 86 : 830-6.
10. **Kilmartin T, O'Kane C.** Combined rotation scarf and Akin osteotomies for hallux valgus: a patient focussed 9 year follow up of 50 patients. *J Foot Ankle Res* 2010; 3 : 2.
11. **Molloy A, Widnall J.** Scarf osteotomy. *Foot and ankle clinics* 2014 ; 19 : 165-80.
12. **Nix S, Smith M, Vicenzin B.** Prevalence of hallux valgus in the general population: a systematic review and meta-analysis. *J Foot Ankle Res* 2010 ; 3 : 21.
13. **O'Briain D, Flavin R, Kearns S.** Use of Geometric Formula to Improve the radiographic Correction Achieved by the Scarf Osteotomy. *Foot and ankle international* 2012 ; 33 : 647-54.
14. **Okuda R, Kinoshita M, Yasuda T, Jotoku T, Shima H.** Proximal metatarsal osteotomy for hallux valgus: comparison of outcome for moderate and severe deformities. *Foot Ankle Int* 2008 ; 29 : 664-70.
15. **Robinson A, Limbers P.** Modern concepts in the treatment of hallux valgus. *J Bone Joint Surg Br* 2005 ; 87-B : 1038-45.
16. **Sammarco G, Idusuyi O.** Complications after surgery of the hallux. *Clin Orthop Relat Res* 2001 ; 391 : 59-71.
17. **Saro S, Jensen I, Lindgren U.** Quality-of-life outcome after hallux valgus surgery. *Qual Life Res* 2007 ; 16 : 731-738.
18. **Scranton P, McDermott J.** Prognostic factors in bunion surgery. *Foot and Ankle Int* 1995 ; 16 : 698-704.
19. **Smith E, Landorf K, Butterworth P, Manz H.** Scarf versus Chevron Osteotomy for the correction of 1–2 Intermetatarsal Angle in Hallux Valgus: A Systematic Review and Meta-analysis. *J Foot Ankle Surg* 2012 ; 51 : 437-44.
20. **Thordarson D, Ebramzadeh E, Moorthy M, Lee J, Rudicel S.** Correlation of hallux valgus surgical outcome with AOFAS forefoot score and radiological parameters. *Foot Ankle Int* 2005 ; 26 : 122-7.
21. **Torkki M, Malmivaara A, Seitsalo S, Hoikka V, Laippala P.** Surgery vs orthosis vs watchful waiting for hallux valgus: a randomised controlled trial. *J Am Med Assoc* 2001 ; 285 : 2474-2480.
22. **Wilson JD, Baines J, Siddique M, Fleck R.** The effect of sesamoid position on outcome following scarf osteotomy for hallux abducto valgus. *Foot and ankle surgery* 2009 ; 15 : 65-68.