



Treatment of chronic osteomyelitis with antibiotic-loaded bone void filler systems: an experience with hydroxyapatites calcium-sulfate biomaterials

Jacopo VISANI, Eric L. STAALS, Davide DONATI

From the Musculoskeletal Oncology Department of the Rizzoli Orthopedic Institute, Bologna, Italy

This is a retrospective study that aims to quantify the problem of chronic osteomyelitis in one of the largest Italian orthopedic centers. Furthermore this study is focused on evaluation of efficacy of bone void filler systems with particular attention to a subgroup of patients treated with PerOssal®. Ninety-seven patients were included in this study between 2008 and 2013 with a minimum follow up of 24 months. A subgroup of 52 patients was treated with curettage plus PerOssal®, another group was treated with curettage only or curettage with other bone void filler systems.

Overall we obtained a cure rate of 80,4%, whereas 19,6% had recurrent infection. Looking at the subgroup treated with PerOssal® we found a healing rate of 86,5%, which was significantly higher compared to the other groups. Of the patients with recurrence of infection, those treated with PerOssal® recurred 106 days later than the other patients.

Keywords : Osteomyelitis ; Bone void filler system ; local antibiotic delivery.

bone or may involve numerous regions, such as marrow, cortex, periosteum and surrounding soft tissues. The key of successful management is early diagnosis and appropriate surgical and antimicrobial treatment, a multidisciplinary approach is required. Surgical approach requires aggressive debridement followed by antibiotic therapy (4), whereas antibiotic therapy alone leads to a high failure rate. Even after conservative debridement, recurrence rates are relatively high, therefore some authors suggest to treat osteomyelitis as a malignant diseases (10-11) involving wide excision margin and replacement of bone defects. Filling of dead space is very important, and if left unmanaged may contribute to infection recurrence. Based on the size of surgical debridement it can be achieved during the operation using reabsorbable bone substitute (see figure 1) or, in very extensive bone defects, with more complex surgical procedure including Masquelet or Ilizarov techniques (8-10). Antibiotic therapy

INTRODUCTION

Chronic osteomyelitis still represents an important cause of morbidity often requiring several surgical procedures. Osteomyelitis is defined as infection of bone and bone marrow caused by a microorganism, especially bacteria and more rarely fungi (5). The infection may be limited to a single portion of the

- Jacopo Visani, MD.
- Eric L. Staals, MD, Orthopaedic Surgeon.
- Davide Donati, MD.
- Scott Oishi, Professor.

Musculoskeletal Oncology Department of Rizzoli Orthopaedic Institute, Bologna, Italy

Correspondence : Davide Donati, Istituto ortopedico Rizzoli, Via Pupilli 1, 40126 Bologna, Italy.

E-mail : davide.donati@ior.it

© 2018, Acta Orthopaedica Belgica.

No benefits or funds were received in support of this study. The authors report no conflict of interests.

Acta Orthopaedica Belgica, Vol. 84 - 1 - 2018

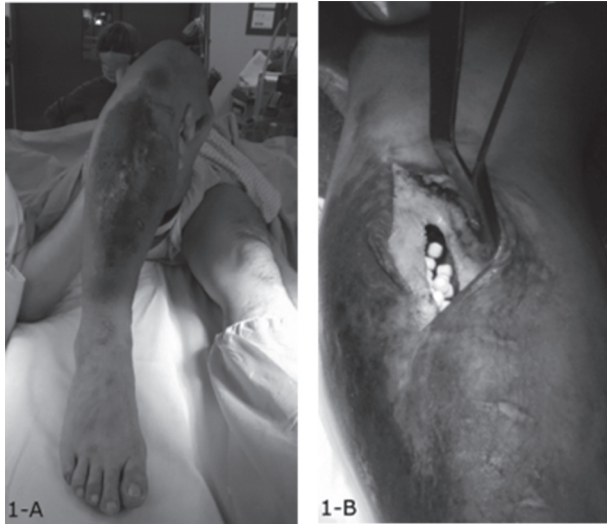


Fig. 1A. — Clinical aspect of chronic osteomyelitis the tibia.
Fig. 1B. — Intraoperative photograph showing hydroxyapatite beads in the bone defect after surgical debridement

is the main adjuvant to the surgical procedure to avoid recurrence of infection and can be delivered systemically or locally, by antibiotic-loaded bone void fillers. The rationale is to obtain a high local concentration of antibiotic drugs, increasing the cure rate and reducing systemic adverse effects, offering also a scaffold for bone regeneration. Surgical debridement plus antibiotic-loaded bone substitutes leads to high healing rate compared with surgical debridement alone as established by several studies (1-7). We have conducted this retrospective study to compare the outcomes of different bone void filler (BVF) systems used in our institute.

MATERIALS AND METHODS

We retrospectively studied all patients hospitalized in our Department with diagnosis of osteomyelitis involving the long bones in the period between 2008 and 2013. We identified 136 patients, 39 were excluded from this study for the following reasons: 16 received no surgical treatment, 10 had insufficient follow up (less than 24 months). In 5 cases the final diagnosis was different from chronic osteomyelitis and 8 patients underwent direct amputation.

The final population included 97 patients, 59 males and 38 females with an average age of 36 years. Seventy-two patients had infection at lower limb and 25 at the upper one. All patients were classified according to Cierny and Mader classification (6): where type I represents medullary, type II superficial, type III localized and the type IV diffuse osteomyelitis. An A-host means a normal host; B-host can be locally compromised (BI), systemically compromised (Bs) or both (BIs). The C-host means that the treatment can be worse than the disease itself. Forty cases were stage IA, 1 was IIA, 12 IIIA, and 1 was IV; 4 were IB, 21 IIB, 16 IIIB and 2 were IVB (table I). Within the group of B-hosts, 5 patients had type II diabetes, 7 had a neoplastic comorbidity and 22 patients received previous orthopedic treatment: 20 with hardware implantation and 2 with prosthetic implants. The diagnosis of osteomyelitis was achieved with both histologic confirmation and positive microbiological cultures in 36 cases. In 15 cases there were positive microbiological samples only and in 41 cases the diagnosis was based on histology with negative culture samples. In 5 cases the diagnosis was based on clinical, laboratory and radiological signs only.

All patients were treated with surgical debridement of infected bone and soft tissues. In 8% of the cases the surgical debridement required a segmental bone resection that was reconstructed with the Masquelet or Ilizarov technique. A further classification of this population was made based on BVF systems that were used. The larger subgroup was formed by 52 patients (53%) treated with PerOssal® which is BVF system composed for 51,5% of nanocrystalline hydroxyapatites and for 48,5% of Calcium sulfate (4-9). It is reabsorbable and offers a scaffold of osteoconductive materials

Table I. — Patients classification

Cierny and Mader Classification System					
	I	II	III	IV	Total
A	40	1	12	1	54
B	4	21	16	2	43
C	0	0	0	0	0
Total	44	22	28	3	97

for bone regeneration. Based on susceptibility tests the system can be loaded with various antibiotic drugs intra-operatively⁹. Vancomycin was added in all cases. Gentamycin or Imipenem was also added, respectively in 10 and 2 cases. 45 cases were treated with different systems: 25 cases with curettage only, without any BVF, 6 with a haemostatic gelatin sponge (Spongostan®), 6 with other antibiotic loaded BVF (Osteoset-T® which is composed of calcium sulfate added with 4% of tobramycin) and 8 cases were treated with antibiotic loaded Polymethylmetacrylate (PMMA). At surgery, primary wound closure was achieved in all cases. In case of high skin tension, for example due to sinus tract excision, the wound edges were carefully advanced. Only in 1 of cases a fascio-cutaneous flap was applied to close the wound.

Cases were considered cured when there were no signs of infection (lack of wound healing, secretion, stiffness, presence of sinus tract) or radiological signs of infection or elevation of serological inflammatory marks (CRP) for at least 12 months after the surgical treatment. All data was collected using Excel work sheet and statistical analysis was performed using dedicate IBM statistical software spss statistic 19®: Chi-squared univariate analysis was used to confront different treatment groups.

RESULTS

Deep surgical samples revealed *Staphylococcus aureus* in 29% of the cases, coagulase-negative staphylococci (most frequently *Staphylococcus epidermidis*) in 7%, *Pseudomonas aeruginosa* in 6% and *Streptococcus* genera in 5%. The other group was represented by a miscellaneous etiology involving *Klebsiella*, *Enterococcus*, *Proteus*, and fungi. In only one case we found an osteomyelitis caused by *Mycobacterium tuberculosis*. In 6 cases we found a polymicrobial infection. No significant growth was found in 46% of cases.

The clinical outcomes in relation to the implantation of different BVF systems are presented in the table-II. The subgroup of 52 patients treated with PerOssal® showed a cure rate of 86,5%. The subgroups treated with Osteoset-T® and PMMA showed a cure rate of 50% and a subgroup treated

with curettage only had an 80% of cure rate. After a univariate analysis PerOssal® showed a significantly higher cure rate than the other treatments. In the whole series 19 patients showed recurrence of infection; in 12 a second surgical debridement was performed: 2 patients were treated with resection and bone graft, 1 with arthrodesis; in 2 cases an amputation was performed and 2 cases received no further treatment. It was possible to eradicate the infection with conservative procedure in only 4 of the recurrent cases and in 2 cases an amputation was required; the other 13 patients developed a chronic infection.

The 19 patients who had a recurrence of infection after the first surgical treatment were divided in two subgroups based on their BVF systems: one group treated with PerOssal® and the other treated with different BVF systems. Their Kaplan-Meier survival curves are presented in figure 2. The mean time to recurrence in the PerOssal® group was 314 days, in the other group 208 days. This difference was statistically significant ($p < 0,05$).

DISCUSSION

The surgical treatment principles for osteomyelitis are well accepted including aggressive surgical debridement, management of dead space and association with antibiotic therapy. The

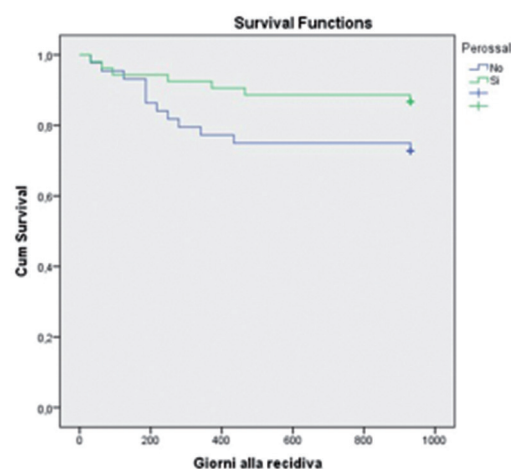


Fig. 2. — Kaplan Meier curves showing results of patients with recurrence of infection treated with PerOssal® or other BVF systems.

Table II. — Table showing result achieved with different BVF systems

BVF	Recurrence		Cure		Total
Nothing	5	20%	20	80%	25
Osteoset	3	50%	3	50%	6
Perossal	7	13,5%	45	86,5%	52
Cement	4	50%	4	50%	8
Spong.	0	0%	6	100%	6
Tot.	19	19,6%	78	80,4%	97

effectiveness of antibiotic-loaded BVF systems is highly recognized: these systems permit to fill bone cavities after surgical intervention and some offer a scaffold for new bone formation in order to restore the mechanical and physiological proprieties of the bones after surgical injury. Due to non-standardized radiographic follow-up we did not analyze the time to reabsorption of the BVF's nor the quality and quantity of new bone formation. Overall, we found complete disappearance of Osteoset® and PerOssal® beads and gradual new trabecular bone formation in the treated area between 6 and 18 months postoperatively. However there was a wide variety in the reabsorption interval, which depends likely on the volume of threatened area, the BVF material, age of patient, site of the osteomyelitis, local condition of bone and soft tissues, weightbearing status, infection status etc.

Several studies have established the importance of obtaining a high local antibiotic concentration in order to reduce the rate of local recurrence (1-7) Therefore several BVF systems can be used for local antibiotic delivery. In our hands PerOssal® offered a higher cure rate compared to other techniques used in this series. Furthermore, PerOssal® holds several practical advantages compared to other BVF systems: first, the addition

of hydroxyapatite increases the biocompatibility and reduces the inflammatory reaction induced by the biomaterials made of Calcium sulfate alone (9). Second, PerOssal® can be loaded with a large choice of antibiotic drugs, based on previous culture samples and epidemiology data. Finally it can be loaded with antibiotics intra-operatively preserving the molecules from the decontamination process (9).

The weaknesses of our study are its retrospective nature that does not exclude selection bias, and the presence of an inhomogeneous control group.

Compared to other reports in literature we found overlapping results, with clear prevalence of Staphylococcus genera in culture samples and cure rate of 80,4 in the total patients population (1-3). Looking at the subgroup of patients treated with PerOssal® we achieved a cure rate of 86%, higher than reported by authors with similar patient volumes (3-12) and approaching the results of specific infection units (2) (table III).

CONCLUSION

This study underlines the effectiveness of PerOssal® in the treatment of chronic osteomyelitis of the long bones. Better results were achieved using PerOssal® added with targeted antibiotic therapy based on susceptibility tests after radical surgical debridement than with other techniques.

REFERENCES

1. Chang W, Colangeli M, Colangeli S et al. Adult osteomyelitis: Debridement versus Debridement plus Osteoset T® pellets. Acta Orthop. Belg. 2007 ;73: 238-43.
2. Ferguson JY, Duradeva M, Riley ND et al. The use of biodegradable antibiotic-loaded calcium sulfate carrier containing tobramycin for the treatment of chronic osteomyelitis Bone Joint J 2014; 96-B: 829-36.

Table III. — Results with BVF for osteomyelitis in the literature

Authors	Year	Journal	Bone void filler	Number of cases	Cure rate
Donati et al.	2015		PerOssal	52	86,5%
Wang et al.	2007	Actha orth.Bel.	Osteoset T	25	80%
Fleiter et al.	2014	Bone Joint Res.	Herafill G	20	80%
Ferguson et al.	2014	JBJS	Osteoset T	195	97,9%

3. **Fleiter N, Walter G, Bösebeck H et al.** Clinical use and safety of a novel gentamicin-releasing resorbable bone graft substitute in the treatment of osteomyelitis/osteitis. *Bone Joint Res* 2014; 3: 223-9.
4. **Lazzarini L, Mader JT, Calhoun JH.** Osteomyelitis in long bones. *J Bone Joint Surg Am.* 2004; 86-A: 2305-18.
5. **Lew DP, Waldvogel FA.** Osteomyelitis. *The New England Journal of Medicine* 1997; 336: 999-1007.
6. **Mader JT, Shirliff M, Calhoun JH.** Staging and staging application in osteomyelitis. *Clin infect disease* 1997; 25: 1303-9.
7. **Ostermann PAW, Seligson D, Henry SL.** Local antibiotic therapy for severe open fractures. *J Bone Joint Surg.* 1995; 77:93-7.
8. **Parsons B, Elton S.** Surgical management of chronic osteomyelitis. *Am J Surg* 2004; 188: 56-57
9. **Raushmann MA, Wichelhaus TA, Stürnal V et al.** Nanocrystalline hydroxyapatite and calcium sulfate as biodegradable composite carrier material for local delivery of antibiotics in bone infections. *Biomaterials* 2004; 26: 2677-84.
10. **Sanders J, Mauffrey C.** Long bone osteomyelitis in adults: Fundamental concepts and current techniques. *Orthopedics* 2013; 36: 368-75.
11. **Simpson AH, Deakin M, Lathan JM.** The effect of the extent of surgical resection on infection-free survival. *J Bone Joint Surg Br.* 2001; 83: 403-7
12. **Von Stechow D, Raushmann MA.** Effectiveness of combination use of Antibiotic-loaded PerOssal® with spinal surgery in patients with spondylodiscitis. *Europ Surg Res* 2009; 43:298-305.