



Non-union of osteoporotic vertebral fractures – identification and treatment of an underestimated pathology in elderly patients with persistent back pain

Daniel ADLER, Sven K. TSCHOEKE, Nicolas VON DER HOEH, Jens GULOW, Georg VON SALIS-SOGLIO, Christoph-E. HEYDE

From Department of Orthopaedic Surgery, University Hospital Leipzig, Leipzig, Germany

Objective : Non-union of osteoporotic vertebra fractures are a seldom entity. However, when back pain persists in the course of conservatively treated osteoporotic vertebra fractures, a non-union should be considered. We thus sought to validate our diagnostic algorithm in patients with known osteoporotic vertebra fractures presenting persistent back pain and advert to the diagnosis and treatment of vertebral non-unions.

Patients and Methods : Patients admitted with pre-existing osteoporotic vertebra fractures and therapy-resistant back pain were retrospectively analysed. All admitted patients were subject to standard plain radiographs in erect position and conventional CT or MR imaging of the spine, respectively. In addition, patients with suspected non-union were subject to lateral fulcrum radiographs in supine position.

Results : From a total of 172 admitted patients, four patients presented with non-union of a fractured osteoporotic vertebra (2%). The subsequent surgical therapy included cement-augmented rod-and-screw stabilization, with or without additional correction of deformity, and kyphoplasty (N = 3) or kyphoplasty alone (N = 1). All surgical interventions were successful in pain reduction and allowed immediate and improved postoperative mobilisation.

Conclusions : Non-union of osteoporotic vertebra fractures must be considered when symptoms outlast conservative treatment. In these cases, plain lateral fulcrum radiographs are a simple and effective adjunct to the conventional diagnostic methods. Surgical stabilization then proves to be the effective treatment of choice.

Keywords : persistent back pain ; osteoporosis ; vertebral non-union ; kyphoplasty ; spine surgery.

INTRODUCTION

Osteoporosis is defined as the significant reduction of bone mass with changes in the trabecular architecture and consecutive loss of stability leading to an increased risk of fracture (12,19,23). Vertebral compression fractures of the thoracic and lumbar spine are the most common complication of osteoporosis and often the first sign and symptom of this particular disease (13,16,17,19). While the inci-

-
- Daniel Adler^{1,3}, MD (fellow).
 - Sven K. Tschoeke^{2,3}, MD (chief attending).
 - Nicolas von der Hoeh³, MD (fellow).
 - Jens Gulow³, MD (attending).
 - Georg von Salis-Soglio³, MD (professor and department director).
 - Christoph-E. Heyde³, MD (professor and department director).

¹Department of Orthopaedic Surgery, Hospital Ingolstadt, Ingolstadt, Germany.

²Department of Spine Surgery, Park Hospital GmbH, Leipzig, Germany.

³Department of Orthopaedic Surgery, University Hospital Leipzig, Leipzig, Germany.

Correspondence : Daniel Adler, Department of Orthopaedic Surgery, Hospital Ingolstadt, Krumenauerstrasse 25, 85049 Ingolstadt, Germany. E-mail : dan_adl@gmx.de

© 2014, Acta Orthopædica Belgica.

Conflict of Interest : All contributing authors declare no conflict of interest.

All diagnostics and therapy were performed at the Department of Orthopaedic Surgery, University Hospital Leipzig. D. Adler and S. K. Tschoeke contributed equally to the article.

dence of osteoporotic vertebral fractures continuously increases, they similarly resemble a high socioeconomic burden worldwide. Recent studies have estimated approximately 20 million patients in the US and 2.8 million in Germany to be affected by osteoporotic fractures of the spine (7). Acute vertebral fractures show a high mobility within the fracture zone, thus being of avail to selected surgical reduction techniques, including cement-augmented stabilization procedures (17,19). Yet, the majority of osteoporotic vertebral fractures may be successfully treated conservatively and as bony union and stability progresses, the associated pain gradually subsides. However, in cases where bony union is not achieved within the average consolidation period in conservative treatment, the fracture consequently maintains its dynamics, subsequently representing a non-union (9,11,17,19). This dynamic fracture mobility has been demonstrated to appear radiographically evident as an intravertebral cleft, induced by forced elevation of vertebral height in a supine hyperextension cross-table (lateral fulcrum) radiographic technique (17). Due to the associated pathomorphology of delayed, ostensibly posttraumatic ischemic osteonecrosis and collapse of the vertebral body, this observation has become synonymous with Kummel's disease and is thus referred to as Kummel's sign (9,13).

Therefore, in the standard diagnostic follow-up of patients with osteoporotic vertebra fractures the conventional two-plane x-ray in an erect position occasionally lacks sufficient informative value, while MRI and/or CT are predominantly subject to specific objectives. In the following study we sought to evaluate our patient cohort presenting with persistent back pain and a history of osteoporotic vertebral compression fractures and advert to the diagnosis and treatment of non-unions, respectively.

PATIENTS AND METHODS

Patients

From January 2009 through December 2009 patients treated for osteoporotic vertebral fractures at the Department of Orthopaedic Surgery, University Hospital Leipzig, Germany, were retrospectively analysed. In all

patients, symptoms presented either spontaneously or after an incident of inadequate or low-energy trauma. Osteoporotic patients presenting acute or chronic back pain with a history for adequate or high-energy trauma were excluded from the study. Imaging diagnostics included conventional two-plane radiographs in erect position, lateral fulcrum radiographs in supine position as described by McKiernan and colleagues (17) and an MRI of the spine. Computed tomography (CT) was only used in place of MRI in patients presenting specific contraindications (e.g. cardiac pace-maker). Fractures were classified according to the Magerl classification (15). Hospital admission was indicated in cases of kyphotic or scoliotic deformity, progressive sintering or persistent back pain unamenable to further ambulant conservative treatment. Patients discharged from in-ward treatment received a clinical and radiographical follow-up after 6 weeks, 3, 6 and 12 months, respectively. Severity of pain was subjectively assessed by the average level of back pain at the time of initial consultation using the Visual Analogous Scale (VAS). Functional disability was evaluated by the Oswestry Disability Index (ODI). Comorbidities and risk factors with regard to osteoporosis were recorded. In cases where osteoporosis was suspected, patients were subject to osteodensitometric analyses via dual-energy x-ray absorptiometry (DEXA). All patients admitted for further in-patient treatment underwent routine laboratory investigation.

Indication for Surgery

Patients presenting a kyphotic deformity of more than or equal to 15 degrees at the thoracic or greater than 20 degrees at the lumbar level, as well as patients with progressive sintering of greater than 10 per cent within 14 days, were indicated to receive surgical stabilization. Furthermore, indication for surgery included patients complaining of persistent pain for more than 7 days in spite of intensified in-patient analgesic treatment, but without significant deformity.

RESULTS

Patient demographics

A total of 172 consecutive patients (N = 172) were diagnosed with osteoporotic vertebral fractures and enrolled into the study. 68 (N = 68) of these patients (39,5%) (average age of 69.3 ± 6.8 years (54-87 years)) were admitted to further in-

Table I. — In-Patient treatment

	Conservative	Surgery
n Female (mean age)	13 (76)	39 (73)
n Male (mean age)	8 (76)	8 (63)

Table II. — Surgical procedures

	n Female	n Male
Kyphoplasty (1 segment)	27	5
Kyphoplasty (> 1 segment)	2	3
Posterior screw-and-rod	5	4
Instrumentation		
cement-augmented	5	4
additional corrective osteotomie	3	0

patient treatment according to the criteria mentioned above (Table I). The average level of back pain was indicated to be 8.0 ± 1.6 on the VAS. Of these, 21 patients were successfully treated with optimized pain medication and physiotherapy indicating an average VAS of 3.0 ± 1.2 at the time of discharge. 4 patients required additional bracing for supportive stabilization within a continued conservative treatment concept. The remaining 47 patients (N = 47, 69% of all patients admitted to in-patient treatment) with an average age of 72.5 ± 8.4 years (65-87 years) showed no improvement and persistent symptoms despite optimized analgesic treatment and customized physiotherapy and required surgical stabilization (Table II). Respectively, there was no significant difference between the cohort of patients with successful conservative treatment and those requiring a surgical intervention.

Non-unions

Of the 47 patients presenting with therapy resistant symptoms of severe back pain, 4 patients (N = 3 female, N = 1 male patient) were identified to show a vertebral non-union. Conventional two-plane radiographs in erect position demonstrated a collapsed flat vertebra in 3 cases (N = 3) and a kyphotic vertebral sintering in one case (N = 1). In 2 cases (N = 2) the conventional radiographs in erect position featured signs of an intravertebral vacuum phenom-

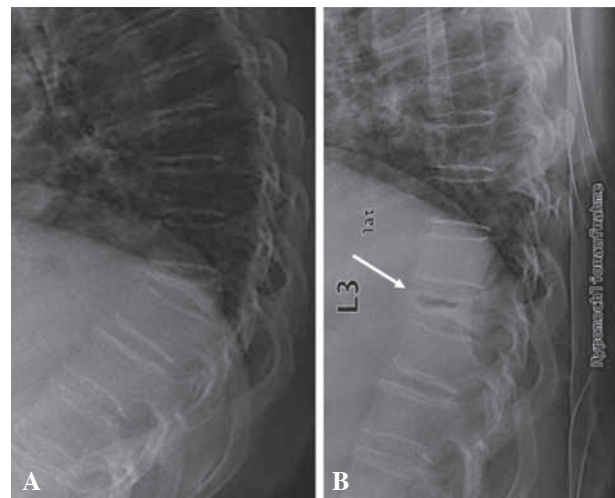


Fig. 1. — A) Conventional lateral X-ray of the thoracolumbar junction in erect position showing the collapsed Th10 vertebra. B) Lateral fulcrum radiograph revealing the non-union of Th10 with its pathognomonic intravertebral cleft (Kummel's sign) (white arrow).

enon. The additional fulcrum radiographs in supine position ultimately confirmed the instable vertebra and intravertebral vacuum phenomenon in all 4 patients (Fig. 1). This was further confirmed by an increase in signal intensity in the Turbo-Inversion Recovery-Magnitude sequence (TIRM) and reduced signal intensity in T1-weighted images of the subsequent MRI (Fig. 2). In patients where MRI was omitted due to specific contraindications (e.g. *in-situ* cardiac pace-makers), the intravertebral vacuum sign and fracture morphology was identified by computed tomography (Fig. 3). Subsequently, all 4 patients with confirmed non-unions received primary kyphoplasty of the fractured vertebra. In 3 patients, this procedure was supplemented by corrective osteotomy and cement-augmented posterior screw-and-rod instrumentation (Fig. 4). Due to the small number of patients demonstrating a non-union, there was no significant difference in the presence or distribution of co-morbidities (Table III).

DISCUSSION

Atraumatic or vertebral compression fractures related to low-energy or inadequate trauma are, along

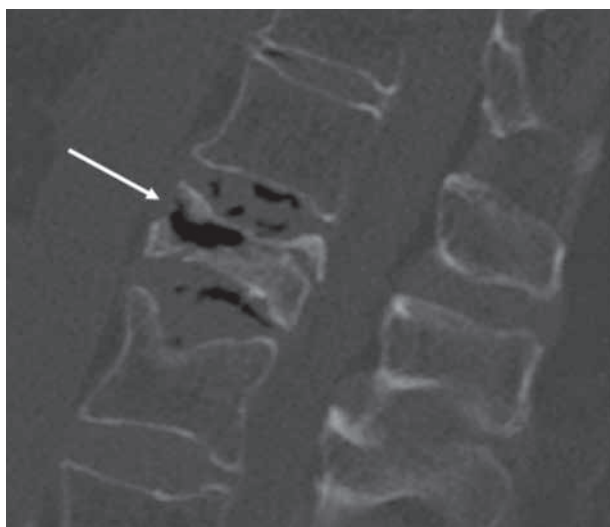

Fig. 2. — Sagittal CT image of L1 showing the pathognomonic intravertebral cleft (white arrow) in an 81 yo female patient with persisting back pain 10 weeks after onset of initial symptoms.

with proximal humerus fractures, wrist fractures and fractures of the hip, the most common complication of osteoporosis in the elderly (1). Beside the progressive socioeconomic burden associated with these complications, their consequences highly compromise the individual's activity level and overall quality of life. Studies investigating the clinical course and overall morbidity in patients with osteoporosis have demonstrated that complications secondary to unidentified or untreated vertebral fractures are associated with a significant increase of the

one- and five-year mortality rate in both women and men (7,8,17,19).

In addition to the poor local microvascularization and reduced capacity of remodeling in osteoporotic bone, osseous microlesions of the vertebral endplates have been suggested to increase the risk of developing vertebral compression fractures, particularly in degenerative disc disease. Moreover, once such an incident has occurred, the likelihood to sustain additional compression fractures at an adjacent level increases exponentially. However, since osteoporotic vertebral fractures are rarely unstable, fractures resulting from high-energy or adequate trauma in osteoporotic patients must clearly be delineated. As a result, the majority of osteoporotic compression fractures are successfully treated conservatively. While adequate pain medication and anti-osteoporotic drug therapy is mandatory, further adjuncts of the conservative treatment regimen include specific exercise and training therapy, and in some cases temporary bracing. In order to identify or prevent secondary deformity and progressive sintering, close-meshed radiological follow-ups are required. In line with these measurements, simple plain radiographs may then elucidate the pathophysiological occurrence of a non-union as an intravertebral vacuum phenomenon (14).

In the rare event of an unstable osteoporotic compression fracture or imminent neurological compromise, primary surgical stabilization methods should be considered in analogous manner to unstable fractures resulting from high-energy or adequate trauma.

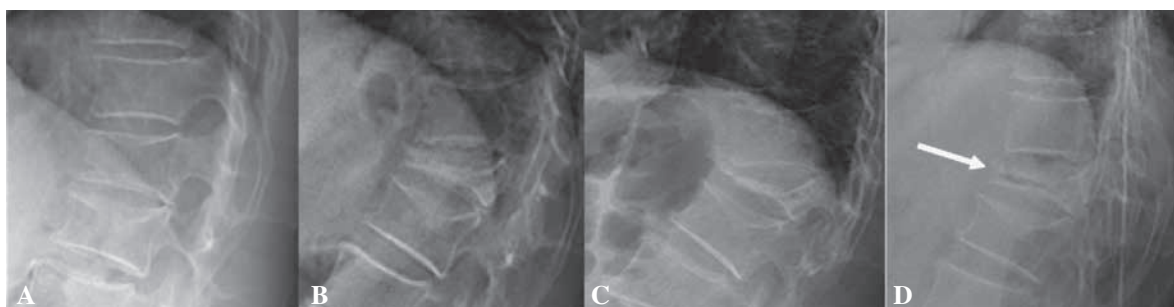

Fig. 3. — Follow-up series of a 75 yo female patient presenting with persistent back pain. A) Lateral X-ray at initial consultation (4 weeks after onset of symptoms) showing a mild sintering of the cranial endplates of L1 and L2. B) Lateral X-ray 4 weeks after initial consultation showing a collapsed L1 vertebra. C) Lateral X-ray 6 weeks after initial consultation with complete collapse and D) obvious Kummel's sign (white arrow) in the lateral fulcrum radiograph identifying a non-union of L1.

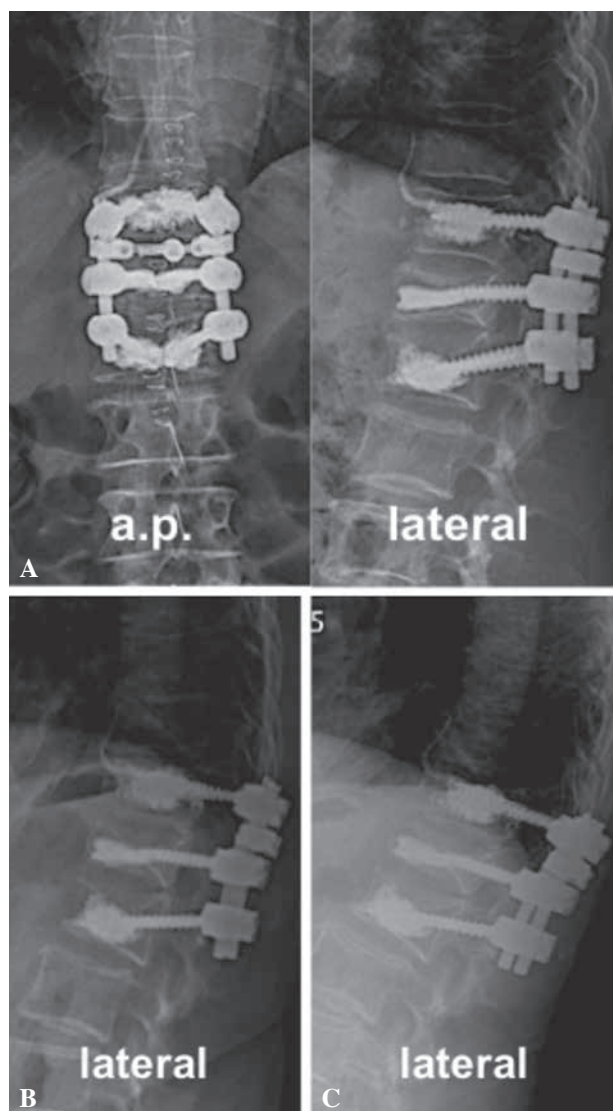


Fig. 4. — Conventional X-rays of the 75 yo female patient in erect position after posterior cement augmented screw-and-rod instrumentation and kyphoplasty of the L1 vertebra at 3 days post-op (A), 6 months (B) and 1 year after surgery (C).

Pain persistency within the clinical course of conservative treatment, however, may have diversified causes. These include progressive sintering, fractures of the adjunct vertebra or a vertebral non-union. Dynamic instability is often characterized by analogical symptoms : while patients sense less or no pain in supine position or at rest, erecting or mobilization is often accompanied by local and intense pain, which subsides once the patient reaches his erect position. From a biodynamical point of view,

Table III. — Co-Morbidities

	<i>n</i> Surgery	<i>n</i> Non-union
Hypertonia	43	4
Past history of vertebral fracture	17	1
Past history of malignant tumor	13	0
Rheumatoid arthritis	6	0
Cardiopathy	11	4
Diabetes	5	2
Parkinson's disease	2	0
Spondylitis ankylosans	3	0

this may be due to the collapse of the vertebra and subsequent gravity-induced compression, otherwise restricted by gaping in the supine position. Thus, the event of collapsing and its subsequent excitation of the periosteum have been suggested to be one of the leading causes for the pain often, but not obligatory, described by patients with vertebral non-unions, respectively (9). Although the event of a non-union is likely to be associated with poor bone quality, similar aspects may be observed when intervertebral disc tissue dislocates into the fracture cleft of healthy vertebrae (19). However, in osteoporotic bone, osteonecrosis due to an insufficient blood supply of the anterior vertebral column (7,10,11,16) or microlesions of the osseous endplates (6) lead to the characteristic radiological signs (intravertebral vacuum phenomenon in kyphotic or compression fractures) and associated morphological changes (13). In this line, Tsujio and colleagues investigated possible predictive factors for non-union in a cohort of 363 osteoporotic vertebral fractures. Among the 350 patients included in their study, the authors identified fractures within the thoracolumbar region, the presence of a middle-column injury and a confined high intensity or a diffuse low intensity area on T2-weighted MRI to be of significant importance (26). Consistent with these factors, vertebral non-unions from our patient collective all presented within the thoracolumbar region ($n = 2$ Th12, $n = 2$ L1). However, compared to the latter observation and a recent report by Wu and colleagues (29) the incidence of osteoporotic non-union

vertebra fractures from our patient cohort was significantly lower (34,8% (29) and 13.5% (26) vs. 2%). Based on the radiological appearance, dynamic mobility of an osteoporotic vertebral fracture characteristically shows an intravertebral cleft (Kummel's sign), but may be missed on standard imaging such as the conventional two-plane radiographs in erect position, MRI or CT. Although both MRI and CT have been shown to equally identify vertebral fracture union and non-union (27), lateral fulcrum radiographs in supine position may be of higher value when comparing respective Cobb-angles from conventional radiographs to determine the scale of dynamic mobility and potential therapeutic options of correcting deformity (vertebroplasty/kyphoplasty with or without additional posterior instrumentation). Toyone and colleagues defined a "wedging rate" by comparing the distance ratio of the leading vertebral edge in standard lateral versus lateral fulcrum radiographs (25). In their patient cohort a wedging rate exceeding 10 degrees significantly correlated with the indication of pain of greater than 40 on the VAS. However, in cases where non-unions may be related to other inflammatory, infectious or malignant entities, the characteristic intravertebral cleft may very well be absent (7-9,14,17,19).

The range of therapeutic options is wide spread. Studies investigating vertebral non-union fractures have suggested both conservative and surgical approaches, including primary conservative bracing and diverse surgical interventions, particularly in patients treated conservatively without any benefit for over 4 to 6 months (8). However, the majority of non-operative treatment methods risk failing such primary therapeutic goals as restoring function, sufficient stabilization and the physiological sagittal balance in secondary deformities. In addition to vertebroplasty and kyphoplasty, the scope of surgical interventions is amended by autogenous and allogeneous bone grafting, with or without posterior instrumentation, and, in cases with impairment of neurological structures, decompression of the spinal canal, eventually combined with anterior stabilization (1,3,7-9,11,13,18,28). Due to the reduced bone quality in osteoporotic vertebral fractures, however, posterior screw-and-rod stabilization often implicates the instrumentation of multiple levels to im-

prove the overall load-sharing. In addition, pedicle screw stability within the demineralized bony structure of the osteoporotic vertebra may be enforced by cement-augmenting techniques (2,18,20-21,24). Other strategies of correcting severe kyphotic deformity may include additional subtraction or posterior closing wedge osteotomies (4-5,22) to ensure the restoration of a physiological sagittal balance.

Although non-union of osteoporotic vertebra fractures remains a seldom entity overall, our study adverts to this pathology particularly in conservatively treated patients presenting with persistent back pain. In this line we believe, that additional lateral fulcrum radiographs in supine position qualify for an easily accessible and effective diagnostic tool to assess both the incident of a non-union, as well as the potential to correct the related secondary deformity.

Acknowledgement

The authors would like to thank Mrs. Mandy Gabel for her kind efforts and assistance in acquisition and evaluation of all in-house clinical and outpatient follow-up data.

REFERENCES

1. **Blauth M, Lange UF, Knop C, Bastian L.** Spinal fractures in the elderly and their treatment. *Orthopade* 2000 ; 29 : 302-17.
2. **Burval DJ, McLain RF, Milks R, Inceoglu S.** Primary pedicle screw augmentation in osteoporotic lumbar vertebrae : biomechanical analysis of pedicle fixation strength. *Spine (Phila Pa 1976)* 2007 ; 32 : 1077-83.
3. **Chang MC, Liu CL, Chen TH.** Polymethylmethacrylate augmentation of pedicle screw for osteoporotic spinal surgery : a novel technique. *Spine (Phila Pa 1976)* 2008 ; 33 : E317-24.
4. **Gertzbein SD, Harris MB.** Wedge osteotomy for the correction of post-traumatic kyphosis. A new technique and a report of three cases. *Spine (Phila Pa 1976)* 1992 ; 17 : 374-9.
5. **Goel MK.** Vertebral osteotomy for correction of fixed flexion deformity of the spine. *J Bone Joint Surg Am* 1968 ; 50 : 287-94.
6. **Hasegawa K, Homma T, Uchiyama S, Takahashi H.** Vertebral pseudarthrosis in the osteoporotic spine. *Spine (Phila Pa 1976)* 1998 ; 23 : 2201-6.
7. **Hasegawa K, Homma T, Uchiyama S, Takahashi HE.** Osteosynthesis without instrumentation for vertebral pseudarthrosis in the osteoporotic spine. *J Bone Joint Surg Br* 1997 ; 79 : 452-6.

8. **Hashidate H, Kamimura M, Nakagawa H, Takahara K, Uchiyama S.** Pseudoarthrosis of vertebral fracture : radiographic and characteristic clinical features and natural history. *J Orthop Sci* 2006 ; 11 : 28-33.
9. **Heini PF.** The current treatment-a survey of osteoporotic fracture treatment. Osteoporotic spine fractures : the spine surgeon's perspective. *Osteoporos Int* 2005 ; 16 Suppl 2 : 85-92.
10. **Heo DH, Chin DK, Yoon YS, Kuh SU.** Recollapse of previous vertebral compression fracture after percutaneous vertebroplasty. *Osteoporos Int* 2009 ; 20 : 473-80.
11. **Jang JS, Kim DY, Lee SH.** Efficacy of percutaneous vertebroplasty in the treatment of intravertebral pseudarthrosis associated with noninfected avascular necrosis of the vertebral body. *Spine (Phila Pa 1976)* 2003 ; 28 : 1588-92.
12. **Kanis JA, McCloskey EV, Johansson H, Oden A, Melton LJ, 3rd, Khaltayev N.** A reference standard for the description of osteoporosis. *Bone* 2008 ; 42 : 467-75.
13. **Kim DY, Lee SH, Jang JS, Chung SK, Lee HY.** Intravertebral vacuum phenomenon in osteoporotic compression fracture : report of 67 cases with quantitative evaluation of intravertebral instability. *J Neurosurg* 2004 ; 100 : 24-31.
14. **Libicher M, Appelt A, Berger I, Baier M, Meeder PJ, Grafe I, Dafonseca K, Noldge G, Kasperk C.** The intravertebral vacuum phenomenon as specific sign of osteonecrosis in vertebral compression fractures : results from a radiological and histological study. *Eur Radiol* 2007 ; 17 : 2248-52.
15. **Magerl F, Aebi M, Gertzbein SD, Harms J, Nazarian S.** A comprehensive classification of thoracic and lumbar injuries. *Eur Spine J* 1994 ; 3 : 184-201.
16. **Maldague BE, Noel HM, Malghem JJ.** The intravertebral vacuum cleft : a sign of ischemic vertebral collapse. *Radiology* 1978 ; 129 : 23-9.
17. **McKiernan F, Jensen R, Faciszewski T.** The dynamic mobility of vertebral compression fractures. *J Bone Miner Res* 2003 ; 18 : 24-9.
18. **Muller EJ, Russe OJ, Muhr G.** Osteomyelitis of the spine. *Orthopade* 2004 ; 33 : 305-15.
19. **Robinson Y, Tschoeke SK, Finke T, Kayser R, Ertel W, Heyde CE.** Successful treatment of spondylodiscitis using titanium cages : a 3-year follow-up of 22 consecutive patients. *Acta Orthop* 2008 ; 79 : 660-4.
20. **Ryu KS, Park CK, Kim MC, Kang JK.** Dose-dependent epidural leakage of polymethylmethacrylate after percutaneous vertebroplasty in patients with osteoporotic vertebral compression fractures. *J Neurosurg* 2002 ; 96 : 56-61.
21. **Singh K, Heller JG, Samartzis D, Price JS, An HS, Yoon ST, Rhee J, Ledlie JT, Phillips FM.** Open vertebral cement augmentation combined with lumbar decompression for the operative management of thoracolumbar stenosis secondary to osteoporotic burst fractures. *J Spinal Disord Tech* 2005 ; 18 : 413-9.
22. **Smith-Petersen MN, Larson CB, Aufranc OE.** Osteotomy of the spine for correction of flexion deformity in rheumatoid arthritis. *Clin Orthop Relat Res* 1969 ; 66 : 6-9.
23. **Soehle M, Wallenfang T.** Spinal epidural abscesses : clinical manifestations, prognostic factors, and outcomes. *Neurosurgery* 2002 ; 51 : 79-85 ; discussion 86-7.
24. **Tezeren G, Kuru I.** Posterior fixation of thoracolumbar burst fracture : short-segment pedicle fixation versus long-segment instrumentation. *J Spinal Disord Tech* 2005 ; 18 : 485-8.
25. **Toyone T, Toyone T, Tanaka T, Wada Y, Kamikawa K, Ito M, Kimura K, Yamasita T, Matsushita S, Shibo R, Kato D, Kaneyama R, Otsuka M.** Changes in vertebral wedging rate between supine and standing position and its association with back pain : a prospective study in patients with osteoporotic vertebral compression fractures. *Spine (Phila Pa 1976)* 2006 ; 31 : 2963-6.
26. **Tsuji T, Nakamura H, Terai H, Hoshino M, Namikawa T, Matsumura A, Kato M, Suzuki A, Takayama K, Fukushima W, Kondo K, Hirota Y, Takaoka K.** Characteristic radiographic or magnetic resonance images of fresh osteoporotic vertebral fractures predicting potential risk for nonunion : a prospective multicenter study. *Spine (Phila Pa 1976)* 2011 ; 36 : 1229-35.
27. **Warwick R, Willatt JM, Singhal B, Borremans J, Meagher T.** Comparison of computed tomographic and magnetic resonance imaging in fracture healing after spinal injury. *Spinal Cord* 2009 ; 47 : 874-7.
28. **Winking M, Stahl JP, Oertel M, Schnettler R, Boker DK.** Treatment of pain from osteoporotic vertebral collapse by percutaneous PMMA vertebroplasty. *Acta Neurochir (Wien)* 2004 ; 146 : 469-76.
29. **Wu CT, Lee SC, Lee ST, Chen JF.** Classification of symptomatic osteoporotic compression fractures of the thoracic and lumbar spine. *J Clin Neurosci* 2006 ; 13 : 31-8.