



Detection of pulmonary cement embolism after balloon kyphoplasty : should conventional radiographs become routine ?

Christopher BLIEMEL, Benjamin BUECKING, Johannes STRUEWER, Eike Immo PIECHOWIAK,
Steffen RUCHHOLTZ, Antonio KRUEGER

From the University Hospital Giessen and Marburg, Location Marburg, Germany

Fatal pulmonary cement embolism is the worst complication after balloon kyphoplasty. Therefore the authors conducted a prospective study about the use of postoperative plain radiographs of the chest as a screening tool for the detection of pulmonary cement embolism. More specifically, they tried to determine its incidence. Postoperative AP and lateral plain radiographs of the chest confirmed this diagnosis in only one out of 94 patients (1%). Systematic use of CT would probably have led to a higher incidence. To the authors' knowledge this is the only study assessing the incidence of pulmonary cement embolism after balloon kyphoplasty. Computed tomography confirmed the diagnosis in the single patient affected, but she remained asymptomatic. Given the low incidence, routine postoperative plain radiographs of the chest do not seem to be indicated in asymptomatic patients, although the radiation exposure is low. Reasonable suspicion (dyspnea, peroperative findings via image amplifier) warrants computed tomography for confirmation of the diagnosis.

Keywords : percutaneous vertebroplasty ; balloon kyphoplasty ; pulmonary cement embolism ; algorithm.

INTRODUCTION

Percutaneous vertebroplasty and balloon kyphoplasty are well-established procedures for the treatment of painful osteoporotic vertebral compression fractures resistant to conservative therapy.

Extravertebral leakage of cement following these procedures is a common problem (3). Computed tomography demonstrated cement leakage in up to 90% of the cases after vertebroplasty (19), and in up to 37.5% after kyphoplasty (11). Leakage was due to the use of still too liquid polymethylmethacrylate (PMMA) cement, or to high pressure at injection. Fortunately most vertebral extrusions remain asymptomatic, but pulmonary embolisms can be fatal (5,17,20,26,27). Plain radiographs detected pulmonary cement embolism in 3.5% to 6.8% of all vertebroplasty cases (1,6,9). Computed tomography raised this percentage to 26% (12,21): thus the

-
- Christopher Bliemel, MD, Orthopaedic Resident.
 - Benjamin Buecking, MD, Orthopaedic Resident.
 - Johannes Struewer, MD, Orthopaedic Resident.
 - Steffen Ruchholtz, MD, Professor of Orthopaedic Surgery.
 - Antonio Krueger, MD, Consultant Orthopaedic Surgeon.
*Department of Trauma, Hand and Reconstructive Surgery,
University Hospital Giessen and Marburg, Location Marburg, Germany.*
 - Eike Immo Piechowiak, MD, Resident Radiology.
Department of Radiology, University Hospital Giessen and Marburg, Location Marburg, Germany.

Correspondence : Christopher Bliemel, Department of Trauma, Hand and Reconstructive Surgery, Baldingerstrasse, 35043 Marburg, Germany.

E-mail : bliemel@med.uni-marburg.de

© 2013, Acta Orthopædica Belgica.

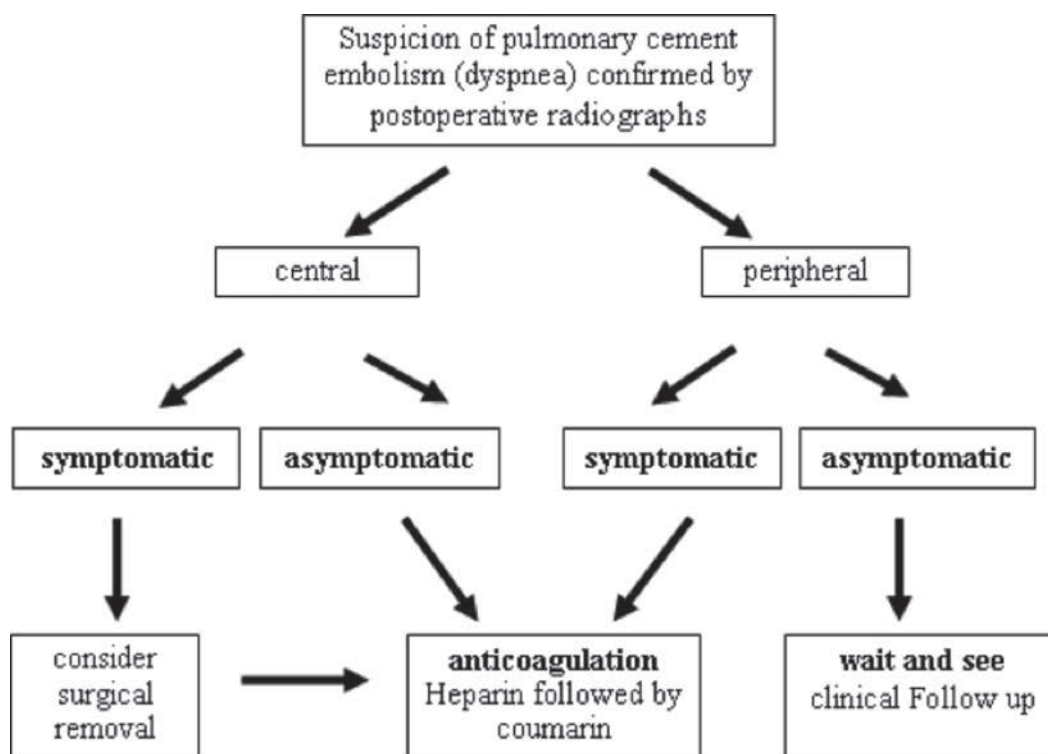


Fig. 1. — Algorithm for the management of pulmonary cement embolism (14)

incidence of pulmonary cement embolism after vertebroplasty may have been underestimated, although it has high clinical relevance. The current study was set up to investigate this incidence after balloon kyphoplasty. To the authors' knowledge no other studies have been published about the incidence of pulmonary cement embolism in a 100% kyphoplasty series.

An algorithm for the treatment of patients sustaining cement embolism after vertebroplasty or kyphoplasty was developed and used as a guideline in our hospital (Fig. 1). This implicated that AP and lateral radiographs of the chest were obtained after balloon kyphoplasty (14). A second purpose of the current study was to evaluate this clinical guideline in order to evaluate the impact of postoperative plain radiographs of the chest for the detection of pulmonary cement embolism in a 100% kyphoplasty series.

MATERIALS AND METHODS

The inclusion criteria were : a. balloon kyphoplasty for the treatment of painful osteoporotic fractures resistant to conservative therapy, b. pre- and postoperative chest radiographs in two planes. The exclusion criteria were : spinal tumours or insufficient imaging.

Between January 2009 and December 2011 a total of 104 patients (76 women ; 28 men ; mean age 78 years ; range : 49-98 years) underwent 106 kyphoplasty procedures (two patients were treated twice) at 150 levels. Seven patients (7 kyphoplasties) were excluded because they lacked radiographs in two planes and 4 other patients (4 kyphoplasties) because of non-osteoporotic affection of the spine (liver cancer, urothelial carcinoma, 2x multiple myeloma). Ninety-four patients with 95 procedures (one patient was treated twice) remained in the study. Eighty-five out of 94 patients had a follow-up interview by phone after +/- 16 months : two patients could not be contacted, while the other 7 patients died before the

follow-up examination for reasons unrelated to the procedure.

Sixty-two patients were treated at one level, 26 patients at two levels, and 6 patients at three levels. The mean interval between trauma or diagnosis and procedure was 19.6 days (range: 3-140 days). The mean amount of injected cement was $6.7 \text{ ml} \pm 2.5 \text{ ml}$ (95%CI: 6.2-7.1 ml).

The cement used was Kyph-X PMMA, which is similar to that used by Kim *et al* (12) (PMMA cement + cefazolin), Anselmetti *et al* (1) (PMMA cement + barium), Choe *et al* (6) (PMMA cement + barium + tobramycin) and Duran *et al* (9) (PMMA cement + barium).

In 2008 (14) the authors developed an algorithm for the treatment of patients sustaining pulmonary cement embolism after vertebroplasty or kyphoplasty. It was based on an extensive review of the literature. It was set up to provide a practical and useful guideline for the postoperative treatment of patients with pulmonary cement embolism after vertebroplasty or kyphoplasty. This guideline included routine postoperative AP and lateral plain radiographs of the chest, a policy not supported by the current study.

The radiographs were prospectively analysed from January 2009 to December 2011, in order to identify pulmonary cement embolism after balloon kyphoplasty. Magnetic resonance imaging (MRI) and conventional spine radiographs were conducted in two planes before kyphoplasty to assess the correct indications for the procedure and to identify the levels requiring treatment. Kyphoplasty was carried out when local tenderness was concordant with MRI hyperintensity on STIR-weighted sequences. Computed tomography was used when MRI examination was contra-indicated or when involvement of the spinal canal required better preoperative planning. Plain radiographs of the spine were also obtained after the procedure, in order to check the correct positioning of the injected cement as well as the proper restoration of vertebral height in comparison with preoperative radiographs.

All images were independently evaluated by six medical doctors; two radiologists: a resident and a consultant; and four traumatologists: a resident, a consultant, a senior and the head of the department. Afterwards inter-rater reliability was determined.

Balloon kyphoplasty was always performed under general anaesthesia. Patients were positioned prone for closed reduction through traction, lordosation and ligamentotaxis. All procedures were performed using a single image amplifier in two planes. A bilateral transpedicular approach was used. All patients received

thrombosis prophylaxis with low-molecular weight heparins peri- and postoperatively until they were remobilized. Perioperatively a single intravenous injection of an antibiotic was administered. After the procedure patients were encouraged to resume all normal daily activities without restrictions.

A visual analogue scale for pain was obtained preoperatively, at discharge and at follow-up. Dyspnea, change in respiration, subjective satisfaction, level of activity, and need for pain medication were also documented. Follow-up was based on a standardized telephone interview, which consisted of a questionnaire proposed by Wiggins *et al* (25). Questions were answered by the patients themselves or, if this was not possible, by relatives or other close people.

For statistical analysis Predictive Analysis SoftWare (PASW®) version 18.0 (SPSS Inc., Chicago, IL, USA) was used. The rate of patients suffering from a PCE following BK was calculated by descriptive statistical analysis with bootstrapping to determine the 95% confidence interval (95% CI). The amount of injected cement was analysed with explorative data analysis (means, standard deviations, 95% CI).

RESULTS

The VAS for pain decreased from 7.9 preoperatively to 2.8 at discharge and to 2.8 at follow-up.

Cement leakage was observed in 29 patients (30.8%). These extrusions were located in the paravertebral soft tissues (12 patients), in the intervertebral disc (7 patients), in front of the vertebral body (7 patients) or behind the vertebral body (3 patients).

All six investigators agreed independently that pulmonary cement embolism occurred in a single patient (100% inter-rater reliability): a 69-year-old woman with a fracture of Th12, treated with 6 ml of PMMA cement. So the incidence of pulmonary cement embolism was 1/94 or 1%. Preoperatively the image amplifier had shown extrusion of cement into the paravertebral vein plexus, which disappeared seconds later. The patient was monitored in the intensive care unit for 24 hours, although she remained asymptomatic.

All patients were clinically asymptomatic during their stay in the hospital as well as during the after-care period. They were released from the hospital, without a brace or an orthosis, after 9.9 days on an average.

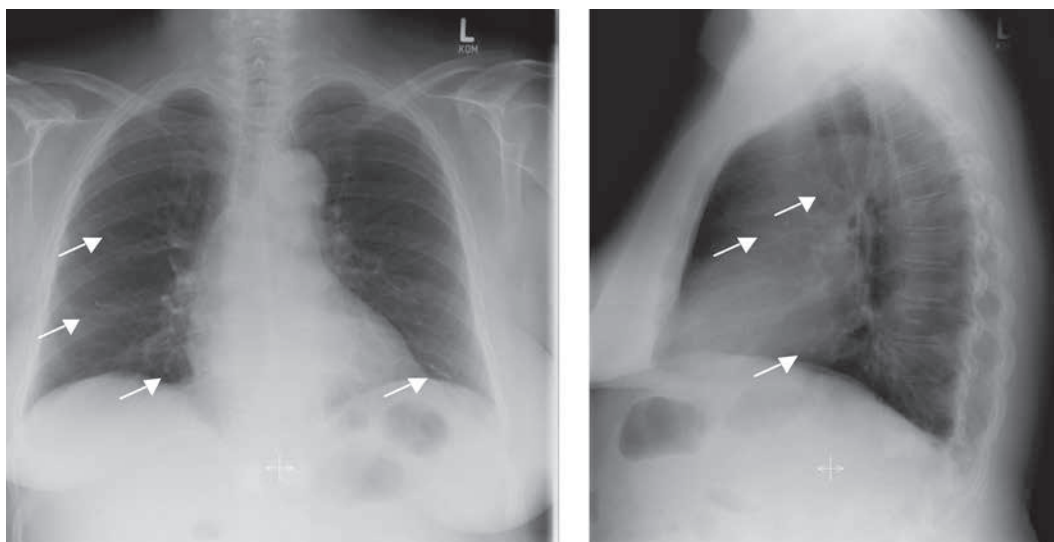


Fig. 2. — Postoperative AP and lateral plain radiographs of the chest in the single patient with pulmonary cement embolism after balloon kyphoplasty. Numerous radiographically dense tubular branching opacities (arrows) can be seen in both lungs, corresponding to segmental and subsegmental pulmonary vessels.

DISCUSSION

The single case of pulmonary cement embolism was diagnosed peroperatively with the image amplifier, and confirmed with plain radiographs after the procedure (Fig. 2). Subsequently computed tomography of the chest, the gold standard for the detection of thrombotic lung embolism, was performed in this single patient for further confirmation of the diagnosis (12) (Fig. 3). Computed tomography not only demonstrates the cement, but also the surrounding tissues and possible appositional blood clots. Pulmonary function tests were normal. All the other patients also remained asymptomatic.

Incidence of pulmonary cement embolism : 1%

Most patients are asymptomatic, and asymptomatic patients are not routinely screened with postoperative chest imaging. Symptomatic cement embolisms can be recognized via dyspnea/tachypnea, tachycardia, cyanosis, chest pain, coughing, hemoptysis, dizziness and sweating. Asymptomatic cement embolisms are more difficult to diagnose, as in the current study. Most authors do not attach too much importance to asymptomatic cement embolism and therefore do not routinely search for it in their

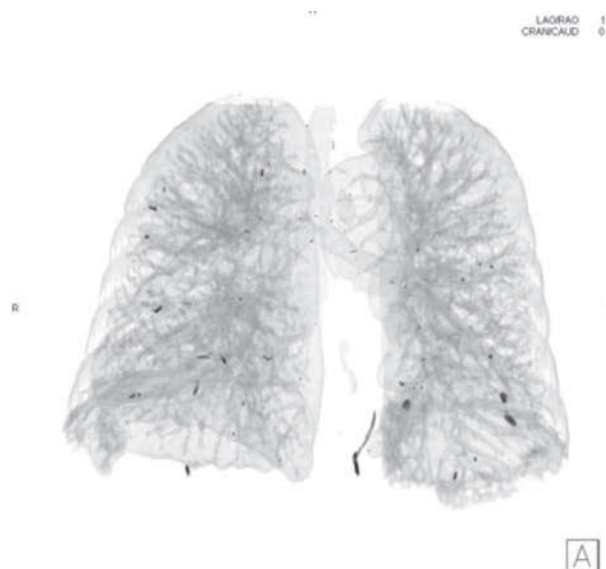

Fig. 3. — Three-dimensional reconstruction of a computed tomography lung scan of the single patient with pulmonary cement embolism after balloon kyphoplasty (black spots = cement).

kyphoplasty patients. Others are more concerned and fear the thrombogenic effect of intravascular cement, which can lead to progressive occlusion of pulmonary arteries (14).

Five studies have analysed the risk for pulmonary cement embolism after percutaneous vertebroplasty (1,9,12,21) or mixed series of vertebroplasty and kyphoplasty (6). They were based on plain radiographs (1,6,9) or on computed tomographies (12,21). According to these publications the risk for pulmonary cement embolism ranges from 3.5% to 26%, depending on the sensitivity of the diagnostic test used. With 94 patients included, our patient population was larger than that of other studies dealing with this topic (1,6,9,12,21).

The current study was set up to assess the procedure-related incidence of pulmonary cement embolism in a 100% kyphoplasty series. Conventional radiographs were chosen because they represent a practical procedure in daily patient care, while the radiation exposure is limited. Cement differs significantly from lung parenchyma as a result of its 30% barium content, which enhances its visibility. Thus larger and therefore clinically relevant cement emboli can easily be recognized on conventional chest radiographs (4,13).

Only one single case of pulmonary cement embolism was seen in 94 kyphoplasty patients : an incidence of 1%. With an overall incidence of 1% (95% CI : 0-5.3%) in our analyzed population, the rate of pulmonary cement embolism was numerically lower than the rate published for vertebroplasty in the literature (3.5% to 6.8%). However, taking the 95% confidence interval into account, our results for balloon kyphoplasty seem to be comparable to the rate of pulmonary cement embolism after vertebroplasty, diagnosed with plain radiographs (1,6,9).

A weakness of this study was the fact that computed tomography was limited to the single patient with dyspnea. Universal use of CT would probably have led to a higher incidence of cement embolism.

Pressure : important

A biomechanical study on cadaveric spines by Weisskopf *et al* (24) showed that the intravertebral pressure measured during cement augmentation was lower in balloon kyphoplasty than in vertebroplasty (24). Phillips *et al* (18) reported similar results based on an *in vivo* comparison between both operative techniques. This is probably one of the reasons

why extrusion of cement and cement embolism are less frequent after balloon kyphoplasty.

Cement volume : no role

Furthermore McDonald *et al* (16) found that novice operators performing vertebroplasty tended to use larger cement volumes than experienced operators. They did not state that there would be an identifiable danger to patients treated by novice operators, but a larger volume of cement may somehow be a risk.

More cement was used by the authors (mean 6.7 ml) than by Duran *et al* (mean 5.1 ml) (9) and Kim *et al* (mean 5.3 ml to 5.9 ml) (12). They tried to restore the vertebral height as much as possible. Therefore the balloons were inflated until they touched the endplates or the lateral wall of the vertebral body. After deflation of the balloons the vertebral body tends to sink down (22,23). Thus it was believed that the void in the vertebral body should be filled with as much cement as possible to achieve primary stability. However, it is well known that pain reduction is independent of the cement volume used. A high rate of vertebral cement leakage was noted : 30.8%. Lower cement volumes (2) or the eggshell technique (10) might further reduce the risk of pulmonary cement embolism. According to the eggshell technique, after primary reduction with the balloons, a small amount of doughy cement is injected into the cavity followed by re-inflation of the balloons. This cement "eggshell" prevents further leakage when the rest of the cement is injected under radiographic control.

In agreement with Anselmetti *et al* (1), Duran *et al* (9), Kim *et al* (12), Venmans *et al* (21), our results confirm that the occurrence of pulmonary cement embolism is not associated with higher volumes of injected cement. Indeed, in the single case of pulmonary cement embolism the amount of cement (6 ml) was even lower than the average volume used ($\pm 6.7 \text{ ml} \pm 2.5 \text{ ml}$) (95%CI : 6.2-7.1 ml).

Consistency of the cement : important

Finally the consistency of the injected cement is of major importance (2). While the injected cement

is supposed to be of lower viscosity in vertebroplasty, the cement should reach toothpaste consistency in kyphoplasty. The cement was probably still too liquid in the single case described by the authors. This led to cement extrusion and pulmonary embolism.

More cement extrusion in case of malignancy

Vertebral body fractures due to malignancy are at a higher risk for cement extrusion than osteoporotic vertebral fractures (6-8, 15). Choe *et al* (6) reported about a series with 73.5% malignant tumours and 26.5% osteoporotic fractures. Anselmetti *et al* (1) published a series with 57% osteoporotic vertebral fractures. The series of Duran *et al* (9) (92% osteoporosis), Kim *et al* (12) (100% osteoporosis) and Venmans *et al* (21) (100% osteoporosis) were comparable to our series (100% osteoporosis).

REFERENCES

1. Anselmetti GC, Zoarski G, Manca A *et al*. Percutaneous vertebroplasty and bone cement leakage: clinical experience with a new high-viscosity bone cement and delivery system for vertebral augmentation in benign and malignant compression fractures. *Cardiovasc Intervent Radiol* 2008; 31 : 937-947.
2. Becker S, Meissner J, Bartl R *et al*. Preliminary results with modified techniques of balloon kyphoplasty for vertebra plana, traumatic fractures and neoplasms. *Acta Orthop Belg* 2006; 72 : 187-193.
3. Bliemeel C, Oberkircher L, Buecking B *et al*. Higher incidence of new vertebral fractures following percutaneous vertebroplasty and kyphoplasty – fact or fiction? *Acta Orthop Belg* 2012; 78 : 220-229.
4. Braiteh F, Row M. Right ventricular acrylic cement embolism: late complication of percutaneous vertebroplasty. *Heart* 2009; 95 : 275.
5. Chen HL, Wong CS, Ho ST *et al*. A lethal pulmonary embolism during percutaneous vertebroplasty. *Anesth Analg* 2002; 95 : 1060-1062.
6. Choe DH, Marom EM, Ahrar K *et al*. Pulmonary embolism of polymethyl methacrylate during percutaneous vertebroplasty and kyphoplasty. *AJR Am J Roentgenol* 2004; 183 : 1097-1102.
7. Cotten A, Dewatre F, Cortet B *et al*. Percutaneous vertebroplasty for osteolytic metastases and myeloma: effects of the percentage of lesion filling and the leakage of methyl methacrylate at clinical follow-up. *Radiology* 1996; 200 : 525-530.
8. Deramond H, Depriester C, Galibert P *et al*. Percutaneous vertebroplasty with polymethylmethacrylate. Technique, indications, and results. *Radiol Clin North Am* 1998; 36 : 533-546.
9. Duran C, Sirvanci M, Aydoğan M *et al*. Pulmonary cement embolism: a complication of percutaneous vertebroplasty. *Acta Radiol* 2007; 48 : 854-859.
10. Greene DL, Isaac R, Neuwirth M *et al*. The eggshell technique for prevention of cement leakage during kyphoplasty. *J Spinal Disord Tech* 2007; 20 : 229-232.
11. Hauck S, Buisse R, Bühren V. Vertebroplasty and kyphoplasty in spinal trauma. *Eur J Trauma* 2005; 31 : 453-463.
12. Kim YJ, Lee JW, Park KW *et al*. Pulmonary cement embolism after percutaneous vertebroplasty in osteoporotic vertebral compression fractures: incidence, characteristics, and risk factors. *Radiology* 2009; 251 : 250-259.
13. Ko HJ, Park KS, Cho CS *et al*. Clinical images: cement embolism following percutaneous vertebroplasty. *Arthritis Rheum* 2009; 60 : 1341.
14. Krueger A, Bliemeel C, Zettl R *et al*. Management of pulmonary cement embolism after percutaneous vertebroplasty and kyphoplasty: a systematic review of the literature. *Eur Spine J* 2009; 18 : 1257-1265.
15. Mathis JM, Barr JD, Belkoff SM *et al*. Percutaneous vertebroplasty: a developing standard of care for vertebral compression fractures. *AJNR Am J Neuroradiol* 2001; 22 : 373-381.
16. McDonald RJ, Gray LA, Cloft HJ *et al*. The effect of operator variability and experience in vertebroplasty outcomes. *Radiology* 2009; 253 : 478-485.
17. Monticelli F, Meyer HJ, Tutsch-Bauer E. Fatal pulmonary cement embolism following percutaneous vertebroplasty (PVP). *Forensic Sci Int* 2005; 149 : 35-38.
18. Phillips FM, Todd Wetzel F, Lieberman I *et al*. An in vivo comparison of the potential for extravertebral cement leak after vertebroplasty and kyphoplasty. *Spine* 2002; 27 : 2173-2178.
19. Schmidt R, Cakir B, Mattes T *et al*. Cement leakage during vertebroplasty: an underestimated problem? *Eur Spine J* 2005; 14 : 466-473.
20. Stricker K, Orlor R, Yen K *et al*. Severe hypercapnia due to pulmonary embolism of polymethylmethacrylate during vertebroplasty. *Anesth Analg* 2004; 98 : 1184-1186.
21. Venmans A, Klazen CA, Lohle PN *et al*. Percutaneous vertebroplasty and pulmonary cement embolism: results from VERTOS II. *AJNR Am J Neuroradiol* 2010; 31 : 1451-1453.
22. Verlaan JJ, van de Kraats EB, Oner FC *et al*. The reduction of endplate fractures during balloon vertebroplasty: a detailed radiological analysis of the treatment of burst fractures using pedicle screws, balloon vertebroplasty, and calcium phosphate cement. *Spine* 2005; 30 : 1840-1845.
23. Voggenreiter G. Balloon kyphoplasty is effective in deformity correction of osteoporotic vertebral compression fractures. *Spine* 2005; 30 : 2806-2812.

24. **Weisskopf M, Ohnsorge JA *et al.*** Intravertebral pressure during vertebroplasty and balloon kyphoplasty : an in vitro study. *Spine* 2008 ; 33 : 178-182.
25. **Wiggins MC, Sehizadeh M, Pilgram TK *et al.*** Importance of intravertebral fracture clefts in vertebroplasty outcome. *AJR Am J Roentgenol* 2007 ; 188 : 634-640.
26. **Yoo KY, Jeong SW, Yoon W *et al.*** Acute respiratory distress syndrome associated with pulmonary cement embolism following percutaneous vertebroplasty with polymethylmethacrylate. *Spine* 2004 ; 29 : E294-297.
27. **Zarghooni K, Siewe J, Kaulhausen T *et al.*** Complications of vertebroplasty and kyphoplasty in the treatment of vertebral fractures : results of a questionnaire study. *Acta Orthop Belg* 2012 ; 78 : 512-518.