



The success of tibiotalocalcaneal arthrodesis with intramedullary nailing – A systematic review of the literature

Shah JEHAN, Mohammad SHAKEEL, Andrew J. F. BING, Simon Owain HILL

The Robert Jones and Agnes Hunt Orthopaedic Hospital, Oswestry, UK

Tibiotalocalcaneal arthrodesis with an intramedullary nail may find indications for a variety of conditions of the hindfoot. We performed a systematic review of the literature primarily to find out the union rates and complications of tibiotalocalcaneal arthrodesis with an intramedullary nail. We included 33 studies for this review. These studies included 631 patients who had 659 procedures. Eighteen cases were excluded and 641 joints (613 patients) were available for the final analysis. We analysed the indications, union rates, complications and re-operation rates. The union rate was 86.7% with an average union time of 4.5 months. The complication rate was 55.7%. Metalwork related complications made a significant proportion of all the complications. The re-operation rate was 22%. Revision arthrodesis was done in 3% and amputation in 1.5% the cases.

The review indicates that tibiotalocalcaneal arthrodesis with an intramedullary nail has a relatively good union rate but a high rate of complications. Majority of the complications are related to the metalwork. The suggested strategies to minimise these complications are discussed.

Keywords : systematic review ; tibiotalocalcaneal arthrodesis ; intramedullary nail ; union rate ; complications ; re-operation.

INTRODUCTION

Tibiotalocalcaneal arthrodesis (TTCA) with intramedullary fixation is not a new idea. Lexer reported in 1906 the use of boiled cadaveric bone as

an intramedullary device for tibiotalocalcaneal arthrodesis (30,33). The first case of tibiotalocalcaneal arthrodesis with an intramedullary (IM) nail was reported by Adams in 1948 (1). Russotti *et al* used Steinman pins and external fixators for tibiotalocalcaneal arthrodesis (41). The rigid internal fixation for TTCA with use of a retrograde IM nail as the sole mean of fixation was reported by Kile *et al* in 1994 (27). They used a posterior approach for joint preparation. In the past a variety of intramedullary nails were used, which were not primarily designed for hind foot fusion (22,26,34,38). With time there has been evolution both in surgical technique and design for intramedullary devices.

- Shah Jehan MRCS, Clinical Teaching Fellow.
The South West London Elective Orthopaedic Centre Epsom, UK, KT18 7AG.
- Mohammad Shakeel, MRCS, Registrar ENT.
Aberdeen Royal Infirmary, Aberdeen AB25 2ZN, UK.
- Andrew James Fill Bing, FRCS (Trauma and Orthopaedics), Consultant Orthopaedic Surgeon.
The Robert Jones and Agnes Hunt Orthopaedic Hospital Oswestry SY10 7AG, UK.
- Simon Owain Hill, FRCS (Trauma and Orthopaedics), Consultant Orthopaedic Surgeon.
The Robert Jones and Agnes Hunt Orthopaedic Hospital Oswestry SY10 7AG, UK.

Correspondence : Mr Shah Jehan, Clinical Teaching Fellow, The South West London Elective Orthopaedic Centre Epsom, UK, KT18 7AG. E-mail : shahjehan200@hotmail.com

© 2011, Acta Orthopædica Belgica.



Fig. 1. — Modern Intramedullary nail specially designed for tibiotalocalcaneal arthrodesis with proximal and distal locking screws. (Ortho Solutions, Maldon, Essex, UK).

Currently there are IM nails available specifically designed for the hind foot fusion (Fig. 1).

The indications of tibiotalocalcaneal arthrodesis include severe deformity and instability of the hind-foot resulting from a variety of conditions (33,40). It is usually reserved as a salvage procedure for failed fusion and failed total ankle replacement (TAR) with talar avascular necrosis (AVN) and severe bone loss. The other common indications include Charcot arthropathy, rheumatoid arthritis and post-traumatic arthritis (11,17). It has also been reported as a successful procedure after tumour resection and management of tuberculous arthropathy (18,33). The common goal of the procedure is to achieve a painless solid arthrodesis with a biomechanically stable plantigrade foot (40).

Although the TTCA with an intramedullary nail was reported more than 50 years ago, there has been a lack of agreement on its success in terms of union rates and complications, probably because of the variety of indications and heterogeneity among the patients. There is a wide variation in reported complication and re-operation rates as well. As far as we know, so far there has not been a systematic review of the English orthopaedic literature for tibiotalocalcaneal arthrodesis with an IM nail. The purpose of this study was to perform a systematic review of the literature to find out the answers to the following primary questions :

1. What is the union rate of TTCA with an IM nail ?
2. What is the nature and rate of complications of TTCA with an IM nail ?
3. What is the nature and rate of re-operation procedures ?

After collecting and analysing the data, we were also able to answer the following secondary questions :

1. The nature and ratio of indications for TTCA with IM nail,
2. Proportion of cases with prior surgical procedures before TTCA.

PATIENTS AND METHODS

A thorough literature search was carried out using Medline and Embase. The key words for the search included: hind foot, ankle, intramedullary nail, intramedullary device, tibiotalocalcaneal, fusion, arthrodesis, and IM nail. The search was limited to the English language and from 1950 to present. The initial search produced 165 titles. After carefully evaluating these titles, 105 abstracts were selected for abstract review. The abstracts were reviewed by two reviewers independently. Among these abstracts 53 were selected and full articles obtained. Full articles were then reviewed by both reviewers. Finally 20 articles were excluded and 33 articles were included for the review (3, 4,6-9,11,12,14,18-28,31-35,37-40,42-45). The reviewers then agreed on the nature of data to be captured from these articles to determine the answers for primary questions. Articles were excluded on the basis of the following criteria :

1. Non-clinical studies, for example biomechanical and cadaveric studies.
2. Studies where screws were used for arthrodesis.
3. Studies where a mix of screws and nails was used, but the patients who were treated with a nail could not be isolated.
4. Studies where blade plate or external fixators were used, either alone or in combination with internal fixation.
5. Personal opinions about TTCA with IM nail.
6. Studies where the primary indication for intramedullary nail was not arthrodesis, for example use of nail or Steinman pin in acute injuries to stabilize a fracture.
7. Studies where only the tibiotalar joint was fused with an IM nail and the subtalar joint was not fused.

The inclusion criteria comprised :

1. Clinical studies where a research question and outcome measures were defined.
2. Studies where the intramedullary device was used for arthrodesis and not for stabilizing acute injuries alone. For example, in some studies the nail was used in acute fractures but the ankle and subtalar joints were fused. We included these studies.
3. Studies where both ankle and subtalar joints were fused with an IM nail.
4. Studies where the talus was resected and a tibiocalcaneal arthrodesis was performed with an IM nail were also included.

Among the 33 articles, 30 were cases series, 2 case reports and 1 technical report. Among the 30 case series, eight were prospective studies, 15 retrospective studies and in eight studies it was not clear whether they were prospective or retrospective. We collected the data for number of cases, indications, prior surgical procedures. The fusion rates, follow-up times and complications were noted. The number and nature of revision or additional procedures were also recorded. The average number of cases per study was 19.5 (1-50). At the beginning of these studies there were 631 cases and 659 joints. The average age was 57.5 years (range : 17-90). There were 322 males and 309 females. The average follow-up time was 28.5 months (range : 4-97). The indications were analysed by the number of joints at the beginning of studies (659). We included 641 joints for final analysis, as 18 cases (18 joints) were excluded from the studies for various reasons. The fusion rates, complications and re-operation rates were analysed on the basis of final number of joints.

RESULTS

Indications

The most common indication was inflammatory arthritis. This made 22.6% (149 cases) of all the indications. Among this group, 97.4% had rheumatoid arthritis and only 2.6% had other inflammatory conditions. The second common indication was neuropathic arthropathy which made 21.7% of all the cases. In this group, 83% of the cases had Charcot neuroarthropathy and 17% had other neuropathies. Failed total ankle replacement was noted in 6.22% and failed arthrodesis in 8.5% of the cases as the immediate indication. Table I shows the indications and their percentage.

Previous procedures

Previous procedures were recorded in 306 (48.5%) cases. It was not possible to analyse precisely the nature of all the previous procedures because all the studies did not mention the nature of previous procedures. However, wherever it was

Table I. — Indications of tibiotalocalcaneal arthrodesis with intramedullary nail. OA = Osteoarthritis, TAR = Total ankle replacement, AVN = Avascular necrosis of talus, CTEV = Congenital Talipes Equinovarus, TB = Tuberculosis

Indications	Number of joints	Percentage of all joints
Inflammatory arthritis	149	22.6%
Neuropathic	143	21.7%
Secondary OA	142	21.6%
Primary OA	59	8.9%
Failed arthrodesis	56	8.5%
Failed TAR	41	6.2%
AVN	18	2.7%
CTEV	14	2.1%
Deformity	9	1.4%
Multiple	9	1.4%
Fractures	8	1.2%
TB	7	1.1%
Not mentioned	4	0.6%

Table II. — Complications of tibiotalocalcaneal arthrodesis with an intramedullary nail

Complications	Number of cases	Percentage of all joints (641)	Percentage of all complications (357)
Metalwork related	107	16.8%	30.0%
Non-union	85	13.3%	23.8%
Infection	54	8.4%	15.1%
Delayed union	23	3.6%	6.4%
Non-infective wound problems	17	2.6%	4.8%
Neurovascular	16	2.5%	4.5%
Deformity	11	1.7%	3.1%
Mal-union	11	1.7%	3.1%
Amputations	10	1.5%	2.8%
Other	7	1.1%	2.0%
Thromboembolic	7	1.1%	2.0%
Plantar pain	5	0.8%	1.4%
Bleeding	4	0.6%	1.1%

mentioned, the major previous procedures were failed TAR or failed arthrodesis. Other common previous procedures included open reduction and internal fixation (ORIF) for fractures, debridement of ulcers and arthroscopic procedures.

Union Rates

At final appointment, 641 joints were available. Union was achieved in 556 of the joints (86.7%). Non-union was seen in 85 joints (13.3%). The average union time was 4.5 months.

Complications

Complications are shown in table II. In 33 studies, we recorded 357 cases with at least one complication. The overall complication rate was 55.7%. The most common complications were related to the metalwork (16.7%). These complications included prominent metalwork, broken metalwork, ulcers due to metalwork, stress reactions and stress fractures due to metalwork. Non-union was noted in 85 cases. This made 23.8% of all the complications and 13.3% of all the procedures. Some studies did not include this as a complication but we were able to retrieve this information from the results sections. Amputations were recorded in 10 cases

making 2.8% of all the complications but only 1.5% of all procedures.

Re-operation rates

The re-operation rates are shown in table III. A total of 142 re-operation procedures were performed. This made 22% of all the primary 641 procedures. Removal of metalwork made the bulk of the re-operation procedures: combined together, removal of nail and removal of screws made 70% of all the re-operation procedures. Although there were 85 cases of non-union, only 22 (26%) of these required revision arthrodesis. It also

Table III. — Re-operation rates

Re-operation	Total number	Percentage of all procedures* (641)
Removal of screws	73	11.4%
Removal of nail	27	4.2%
Revision arthrodesis	22	3.4%
Other	10	1.6%
Amputation	10	1.5%

*This indicates the total number of procedures and not the total number of re-operations.

Proportion of re-operation procedures

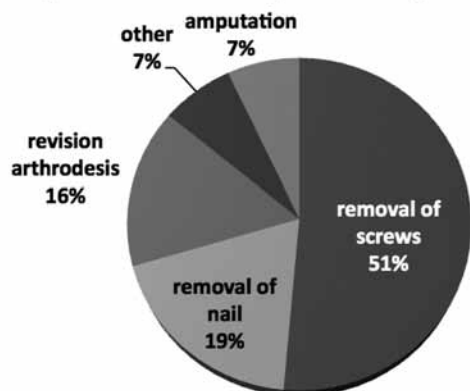


Fig. 2. — Percentages of various revision/additional procedures among all the revision procedures. There were 142 total revision/additional procedures.

is important to note that out of 641 primary arthrodesis procedures only 3.4% required revision arthrodesis. Amputation was noted in 1.5% of all the primary procedures, but made 7% of the revision procedures. Other procedures included: drainage of haematoma or abscesses, metalwork adjustment and wound debridement procedures. Figure 2 shows the proportion of revision or additional procedures.

DISCUSSION

Traditionally the most common method for ankle and hind foot fusion was external fixation (10,13). However, firm internal fixation for hind foot arthrodesis reduces the time for immobilisation. This can possibly reduce the time to return to work as well (17). In the past the TTCA with IM nail was used for severe deformity because in addition to fusion the IM nail helps to maintain the correct alignment of the hind foot (Fig. 3a & 3b). It was commonly used as a salvage procedure for cases with failed fusion, AVN of talus and failed TAR (27,40). With new nail types and improvement in the surgical techniques the indications have expanded to include neuropathic conditions, club foot and arthritis of ankle and subtalar joints (16). The major contraindications for IM nail for TTCA are intact subtalar joint, limited bone stock in

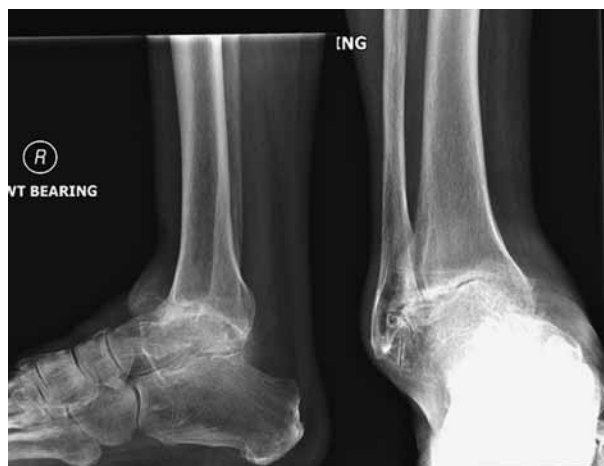

Fig. 3a. — Pre-operative radiographs of a patient showing varus deformity of hind foot secondary to severe osteoarthritis.

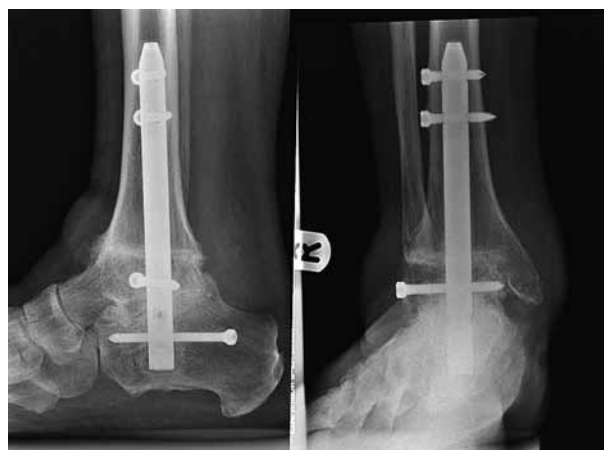


Fig. 3b. — Post-operative radiographs of the patient shown in figure 3a. The patient had tibiototal calcaneal arthrodesis with intramedullary nail. The figure shows neutral alignment and bony union at 6 months after the surgery.

calcaneum with loss of calcaneal height and severe angular deformity of the distal tibia (16,26,29,43). Presence of active infection in the ankle or subtalar joint is another contraindication (43). However, in this review we have found one study where TTCA with retrograde intramedullary nail was performed for tuberculous arthropathy in the quiescent phase of the disease (18).

The other common method for internal fixation to achieve TTCA is use of screws. However the nail is considered biomechanically more stable. The

mechanical bending and torsional properties of IM nail and lag screws were compared in an experimental model of TTCA, and the IM nail was found to be a stiffer construct and maintained better alignment of the hindfoot compared to lag screws (5,15,34). We were unable to find out any good clinical study with intention to compare IM nail to screws for TTCA. Hopgood *et al* (24) performed TTCA using IM nail and screws in unmatched groups. In their study they used IM nail in 10 patients and screws in 5 patients. They achieved 80% union in cases with IM nail, and 20% union in cases where screws were used.

Majority of the patients requiring TTCA with an IM nail have significant comorbidities. The most common comorbidities are diabetes and rheumatoid arthritis. Due to these comorbidities and to the complex nature of the procedure, there is a high rate of complications. Medicino *et al* (33) compared the rate of complications in diabetic and non-diabetic patients: it was 80% in patients with diabetes and 60% in non-diabetic patients. All the major complications were noted in diabetic patients. Poor peripheral neurovascular status combined with compromised immunity is probably the underlying cause for high complication rates in these patients.

The previous studies reported union rates from 74 to 93% (33,38,40). We noted a trend of small studies reporting better union rates compared to the large studies. When the results were analysed on the basis of joints available at final appointment (641) we found a union rate of 86.7%. However, revision arthrodesis is not required in asymptomatic cases of non-union (2,36). In this systematic review, among the 85 cases with non-union only 26% required a revision arthrodesis. The remaining cases were either asymptomatic or the symptoms were not severe enough to require revision arthrodesis. This indicates that the IM nail, to some extent, maintains the alignment and provides stability to help with symptoms even without bony union.

For the surgical approach to ankle and subtalar joints majority of the authors recommended lateral approach with excision of fibula (3,4,22). The advantage of this approach is to allow using a previous scar and to harvest bone graft from the fibula. Kile *et al* (27) recommend a posterior approach. They

argue that the height can be preserved as both the malleoli can be left intact if this approach is used. Thomason *et al* (44) suggested another technique to preserve the height. They used femoral head as an allograft between distal tibia and talus. They reported three cases with successful union at 3 months. Bevernage *et al* (6) reported 3 cases where arthroscopic debridement of both ankle and subtalar joints was carried out before insertion of the retrograde IM nail. All three cases had successful union. While arthroscopy might be feasible in cases without gross deformity, in cases where deformity is significant, arthroscopy alone will not be able to correct the deformity before insertion of the nail. In these cases open surgery becomes necessary to correct the deformity.

It has been argued that the anteroposterior direction is better for insertion of distal locking screws. It gives good bony purchase and prevents any movement in the sagittal plane (31). Some authors suggested use of finned nails for patients with poor bone quality (42). This obviates the need for distal locking screws. In the past the common method of proximal locking was static locking. The only disadvantage of this method is that future dynamization might be required. Pelton *et al* (37) reported 32 cases where dynamic proximal locking screw was used. They reported a union rate of 88% and only one case required dynamization.

This systematic review shows that TTCA with an IM nail has relatively good fusion rates. However it carries a high risk of complications. This might be because of the pre-operative comorbidities. We found that 48.5% of the patients had at least one previous procedure. Some had multiple previous procedures. This can be the cause of poor tissue quality with high risk of complications. However, majority of the complications were related to the metalwork. Such complications might be minimised with better design of the metalwork. Dynamic proximal locking and longer nails are a few suggestions recommended by authors in these studies. Their logic is that the longer nails will minimise the risk of stress fractures, and dynamic screws will reduce the need for dynamization. The review showed that 22% of the cases required at least one further procedure after their operation.

The patients should be fully informed that although this is a salvage procedure, there is future risk of revision arthrodesis and amputation.

REFERENCES

1. **Adams JC.** Arthrodesis of the ankle joint; experiences with the transfibular approach. *J Bone Joint Surg* 1948; 30-B : 506-511.
2. **Alvarez RG, Barbour TM, Perkins TD.** Tibiocalcaneal arthrodesis for nonbraceable neuropathic ankle deformity. *Foot Ankle Int* 1994; 15 : 354-359.
3. **Anderson T, Linder L, Rydholm U et al.** Tibiotalocalcaneal arthrodesis as a primary procedure using a retrograde intramedullary nail: a retrospective study of 26 patients with rheumatoid arthritis. *Acta Orthop* 2005; 76 : 580-587.
4. **Anderson T, Rydholm U, Besjakov J, Montgomery F, Carlsson A.** Tibiotalocalcaneal fusion using retrograde intramedullary nails as a salvage procedure for failed total ankle prostheses in rheumatoid arthritis: A report on sixteen cases. *Foot Ankle Surg* 2005; 11 : 143-147.
5. **Berend ME, Glisson RR, Nunley JA.** A biomechanical comparison of intramedullary nail and crossed lag screw fixation for tibiotalocalcaneal arthrodesis. *Foot Ankle Int* 1997; 18 : 639-643.
6. **Bevernage BD, Deleu PA, Maldague P, Leemrijse T.** Technique and early experience with posterior arthroscopic tibiotalocalcaneal arthrodesis. *Orthop Traumatol Surg Res* 2010; 96 : 469-475.
7. **Boer R, Mader K, Pennig D, Verheyen CC.** Tibiotalocalcaneal arthrodesis using a reamed retrograde locking nail. *Clin Orthop Relat Res* 2007; 463 : 151-156.
8. **Budnar VM, Hepple S, Harries WG, Livingstone JA, Winson I.** Tibiotalocalcaneal arthrodesis with a curved, interlocking, intramedullary nail. *Foot Ankle Int* 2010; 31 : 1085-1092.
9. **Caravaggi C, Cimmino M, Caruso S, Dalla Noce S.** Intramedullary compressive nail fixation for the treatment of severe Charcot deformity of the ankle and rear foot. *J Foot Ankle Surg.* 2006; 45 : 20-24.
10. **Charnley J.** Compression arthrodesis of the ankle and shoulder. *J Bone Joint Surg* 1951; 33-B : 180-191.
11. **Dalla Paola L, Volpe A, Varotto D et al.** Use of a retrograde nail for ankle arthrodesis in Charcot neuroarthropathy: a limb salvage procedure. *Foot Ankle Int* 2007; 28 : 967-970.
12. **De Smet K, De Brauwier V, Burssens P, Van Ovost E, Verdonk R.** Tibiocalcaneal Marchetti-Vicenzi nailing in revision arthrodesis for posttraumatic pseudarthrosis of the ankle. *Acta Orthop Belg* 2003; 69 : 42-48.
13. **Dereymaeker GP, Van Eygen P, Driessen R, De Ferm A.** Tibiotalar arthrodesis in the rheumatoid foot. *Clin Orthop Relat Res* 1998; 349 : 43-47.
14. **Fazal MA, Garrido E, Williams RL.** Tibio-talo-calcaneal arthrodesis by retrograde intramedullary nail and bone grafting *Foot Ankle Surgery* 2006; 12 : 185-190.
15. **Fleming SS, Moore TJ, Hutton WC.** Biomechanical analysis of hindfoot fixation using an intramedullary rod. *J South Orthop Assoc* 1998; 7 : 19-26.
16. **Fox IM, Shapero C, Kennedy A.** Tibiotalocalcaneal arthrodesis with intramedullary interlocking nail fixation. *Clinics in Podiatric Medicine and Surgery* 2000; 17 : 19-31.
17. **Fujimori J, Yoshino S, Koiwa M et al.** Ankle arthrodesis in rheumatoid arthritis using an intramedullary nail with fins. *Foot Ankle Int* 1999; 20 : 485-490.
18. **Gavaskar AS, Chowdary N.** Tibiotalocalcaneal arthrodesis using a supracondylar femoral nail for advanced tuberculous arthritis of the ankle. *J Orthop Surg (Hong Kong)* 2009; 17 : 321-324.
19. **Giza E, Sarcon AK, Kreulen C.** Tibiotalar nonunion corrected by hindfoot arthrodesis. *Foot Ankle Spec* 2010; 3 : 76-9. Epub 2010 Feb 16.
20. **Goebel M, Gerdesmeyer L, Mückley T et al.** Retrograde intramedullary nailing in tibiotalocalcaneal arthrodesis: a short-term, prospective study. *J Foot Ankle Surg* 2006; 45 : 98-106.
21. **Haaker R, Kohja EY, Wojciechowski M, Gruber G.** Tibio-talo-calcaneal arthrodesis by a retrograde intramedullary nail. *Ortopedia, traumatologia, rehabilitacja* 2010; 12 : 245-249.
22. **Hammitt R, Hepple S, Forster B, Winson I.** Tibiotalocalcaneal (hindfoot) arthrodesis by retrograde intramedullary nailing using a curved locking nail. The results of 52 procedures. *Foot Ankle Int* 2005; 26 : 810-815.
23. **Hockenbury RT, Gruttadauria M, McKinney I.** Use of implantable bone growth stimulation in Charcot ankle arthrodesis. *Foot Ankle Int* 2007; 28 : 971-976.
24. **Hopgood P, Kumar R, Wood PL.** Ankle arthrodesis for failed total ankle replacement. *J Bone Joint Surg* 2006; 88-B : 1032-1038.
25. **Johl C, Kircher J, Pohlmann K, Jansson V.** Management of failed total ankle replacement with a retrograde short femoral nail: a case report. *J Orthop Trauma* 2006; 20 : 60-65.
26. **Kamath S, Ramamohan N, Kelly IG.** Tibiotalocalcaneal arthrodesis in rheumatoid arthritis using the Supracondylar nail. *Foot Ankle Surg* 2005; 11 : 75-79.
27. **Kile TA, Donnelly RE, Gehrke JC, Werner ME, Johnson KA.** Tibiotalocalcaneal arthrodesis with an intramedullary device. *Foot Ankle Int* 1994; 15 : 669-673.
28. **Kotnis R, Pasapula C, Anwar F, Cooke PH, Sharp RJ.** The management of failed ankle replacement. *J Bone Joint Surg* 2006; 88-B : 1039-1047.
29. **Laughlin RT, Calhoun JH.** Ring fixators for reconstruction of traumatic disorders of the foot and ankle. *Orthop Clin North Am* 1995; 26 : 287-294.

30. **Lexer E.** Die Verwendung der freien Knochenplastik nebst Versuchen über Gelenkversteifung und Gelenktransplanten. *Langenbecks Arch Klin Chir* 1906 ; 86 : 9-38.
31. **Mader K, Pennig D, Gausepohl T, Patsalis T.** Calcaneotalotibial arthrodesis with a retrograde posterior-to-anterior locked nail as a salvage procedure for severe ankle pathology. *J Bone Joint Surg* 2003 ; 85-A Suppl : 123-128.
32. **Mader K, Verheyen CC, Gausepohl T, Pennig D.** Minimally invasive ankle arthrodesis with a retrograde locking nail after failed fusion. Strategies. *Trauma Limb Reconstr.* 2007 ; 2 : 39-47.
33. **Mendicino RW, Catanzariti AR, Saltrick KR et al.** Tibiotalocalcaneal arthrodesis with retrograde intramedullary nailing. *J Foot Ankle Surg* 2004 ; 43 : 82-86.
34. **Millett PJ, O'Malley MJ, Tolo ET et al.** Tibiotalocalcaneal fusion with a retrograde intramedullary nail : clinical and functional outcomes. *Am J Orthop* 2002 ; 31 : 531-536.
35. **Niinimäki TT, Klemola TM, Leppilahti JI.** Tibiotalocalcaneal arthrodesis with a compressive retrograde intramedullary nail : a report of 34 consecutive patients. *Foot Ankle Int* 2007 ; 28 : 431-434.
36. **Papa JA, Myerson MS.** Pantalar and tibiotalocalcaneal arthrodesis for post-traumatic osteoarthritis of the ankle and hindfoot. *J Bone Joint Surg* 1992 ; 74-A : 1042-1049.
37. **Pelton K, Hofer JK, Thordarson DB.** Tibiotalocalcaneal arthrodesis using a dynamically locked retrograde intramedullary nail. *Foot Ankle Int.* 2006 ; 27 : 759-63.
38. **Pinzur MS, Kelikian A.** Charcot ankle fusion with a retrograde locked intramedullary nail. *Foot Ankle Int* 1997 ; 18 : 699-704.
39. **Pinzur MS, Noonan T.** Ankle arthrodesis with a retrograde femoral nail for Charcot ankle arthropathy. *Foot Ankle Int* 2005 ; 26 : 545-549.
40. **Quill G.E. Jr.** Tibiotalocalcaneal arthrodesis. *Techniques in Orthopaedics* 1996 ; 11 : 269-273.
41. **Russotti GM, Johnson KA, Cass JR.** Tibiotalocalcaneal arthrodesis for arthritis and deformity of the hind part of the foot. *J Bone Joint Surg* 1988 ; 70-A : 1304-1307.
42. **Sekiya H, Horii T, Kariya Y, Hoshino Y.** Arthroscopic-assisted tibiotalocalcaneal arthrodesis using an intramedullary nail with fins : a case report. *J Foot Ankle Surg.* 2006 ; 45 : 266-270.
43. **Tavakkolizadeh A, Klinke M, Davies MS.** Tibiotalocalcaneal arthrodesis in treatment of hindfoot pain and deformity. *Foot Ankle Surg* 2006 ; 12 : 59-64.
44. **Thomason K, Eyres KS.** A technique of fusion for failed total replacement of the ankle : tibio-allograft-calcaneal fusion with a locked retrograde intramedullary nail. *J Bone Joint Surg* 2008 ; 90-B : 885-888.
45. **Thordarson DB, Chang D.** Stress fractures and tibial cortical hypertrophy after tibiotalocalcaneal arthrodesis with an intramedullary nail. *Foot Ankle Int* 1999 ; 20 : 497-500.