

Extra-skeletal Ewing's sarcoma in adults : Presentation of two cases

Samuel M. LIPSKI, Katia CERMAK, Felix SHUMELINSKY,
Thierry GIL, Michael J. GEBHART

From Institut Jules Bordet, Brussels, Belgium

Extrasosseous Ewing's sarcoma represents about 5% of the Ewing family of tumours. Two cases in adult patients are presented, emphasizing the complexity of a multi-modality treatment approach of this tumour. Clinical presentation, chemotherapeutical, surgical and radiotherapeutical approaches are discussed. A thorough literature search was done to correlate our therapeutic attitude with current knowledge of this very rare disease.

Keywords : Ewing's sarcoma ; extraskeletal ; adults.

INTRODUCTION

Ewing's Sarcoma is the second most common primary bone malignancy in children and adolescents with an estimated annual incidence of 0.6 per 1 million (8,11,16).

Extrasosseous Ewing's sarcoma (EES) was first described in 1969 (25), emphasizing the fact that this soft tissue tumour, although similar histologically to the osseous Ewing's sarcoma, has no connections with bone. EES belongs to the family of small round cell tumours, such as Askin tumour and malignant primitive neuroectodermal tumours (PNET), which compose the Ewing family of tumours (EFTs) (26,29). Extrasosseous Ewing's Sarcoma and Ewing's sarcoma of bone are not only defined by routine microscopic findings. Due to advances made over the past three decades in the field of molecular biology and cytogenetics, new

tests have become available. What makes these tumours a common group is the almost universal presence of genetic translocations involving chromosome 22. The immuno-histological features of both tumours are similar : evidence of neuroectodermic differentiation, features of neurodifferentiation and CD99 expression. In order to reliably test new treatments for diseases, large numbers of patients must be studied in randomized controlled clinical trials. This poses a significant problem in EES because of its close association with Ewing's sarcoma of bone. Most of the reported literature

-
- Samuel M. Lipski, Medical Student.
Faculty of Medicine, Université Libre de Bruxelles, Belgium.
 - Katia Cermak, MD, Orthopaedic Surgeon.
Orthopaedic Department, University Hospital Erasme, Brussels, Belgium.
 - Felix Shumelinsky, MD, Orthopaedic Surgeon.
Orthopaedic Department, Institut Jules Bordet, Brussels, Belgium.
 - Thierry Gil, MD, Medical Oncologist.
Oncology Department, Institut Jules Bordet, Brussels, Belgium.
 - Michael J. Gebhart, MD, Orthopaedic Surgeon.
Orthopaedic Department, Institut Jules Bordet, Brussels, Belgium.
- Correspondence : Felix Shumelinsky, Department of Orthopaedic Surgery, Institut Jules Bordet, 121 Boulevard de Waterloo, 1000 Brussels, Belgium.
E-mail : felix.shumelinsky@bordet.be
© 2010, Acta Orthopædica Belgica.
-

regarding EES is taken from single-institution retrospective case reviews. Only one prospective randomized trial is available. Among nearly 3,000 patients with Ewing's sarcoma, 130 (5%) presented with EES (20). It is therefore difficult to evaluate whether EES should be managed using the same therapeutic approaches as classic Ewing's sarcoma of bone. Patients with EES are usually treated by a multi-modality approach, including chemotherapy, surgery, and/or radiation therapy. Currently, most protocols recommend surgical resection rather than radiation therapy if possible, using postoperative radiation only for positive histological margins or overt residual disease.

We describe here two cases of EES recently observed and treated at our Institution.

CASE REPORTS

Case 1

A 42-year-old woman without any past medical history presented to our department because she noticed a mass at the medial aspect of the right thigh 10 days earlier. She did not feel any pain or discomfort. On physical examination, one could feel a slightly mobile firm mass of 10cm in length in the deep portion of the thigh, located in the vicinity of the femur. MRI showed a 12 cm × 5 cm × 4 cm mass in the adductor compartment (fig 1). Further medical work-up included a chest computed tomography which excluded pulmonary metastases. A biopsy was taken, showing small round cells with little cytoplasm and hyperchromatic nucleus. The cells were arranged in "pseudorosettes". Immunohistological examination revealed CD99 expression. The diagnosis was either PNET (Peripheral Neuro Ectodermal Tumour) or extra osseous Ewing's sarcoma. The patient declined ovarian preservation. Neoadjuvant chemotherapy according to the EURO-Ewing protocol consisted in 6 cycles of VIDE (Vincristine, Ifosfamide, Dacarbazine, Etoposide). The tumour was then removed with concomitant resection of the medial cortex of the femur (longitudinal splitting) in order to obtain wide margins. The bone defect was immediately reconstructed with a non-vascularized fibular graft and stabilized by a screw-plate implant (fig 2).

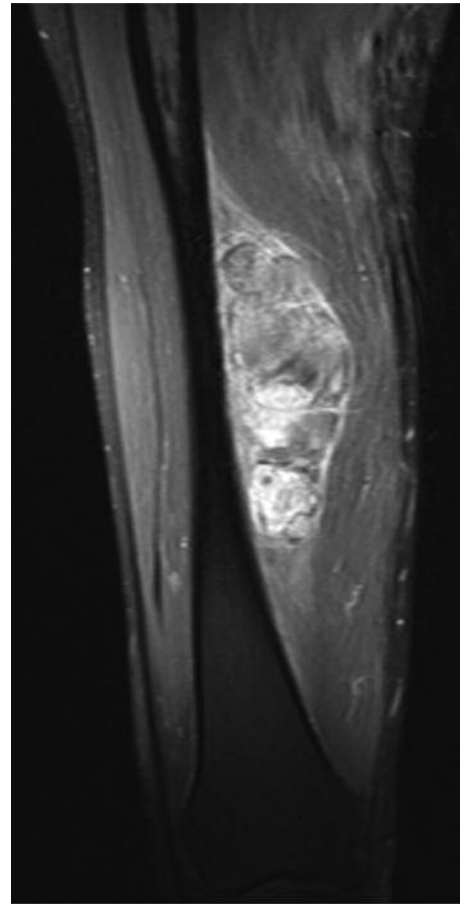


Fig. 1. — T2-weighted MRI showing heterogeneous enhancement of a large mass in the adductor compartment of the right thigh after intravenous contrast injection.

Tumour necrosis was estimated around 60 to 70%. The patient had a very good functional outcome. Adjuvant chemotherapy consisted of 3 cycles of VAI (Vincristine, Adriamycine, Ifosfamide). Because of good histological margins and expected fragility of the bone, no radiation therapy was given. The patient regained normal function and is still disease-free at 30 months follow-up.

Case 2

An 18-year-old woman without any past medical history presented with a quickly growing, painful and mobile soft tissue tumour in the medial aspect of the vastus medialis of the right thigh (fig 3). After diagnostic biopsy showing EES she was sim-

ilarly treated with neoadjuvant chemotherapy according to the E.U.R.O Ewing protocol. The tumour was then removed by an attempted wide resection. Histological examination showed close margins in one small area. The histological response to chemotherapy was stated to be less than

60%. Therefore postoperative radiotherapy was given at a dose of 54Gy to the tumour site and 45Gy to the surrounding area. Post operative chemotherapy was also administered according to the EURO-Ewing protocol. At 29 months follow-up, she is still disease-free and has normal gait function.

DISCUSSION

Extra-osseous Ewing's sarcoma is a very rare pathology. The first case was described in 1921, but without an accurate diagnosis, given the poor knowledge of this entity (1). In 1988, 150 cases of EES had been described (7). The first large series, including 39 cases, was published in 1975 (2). The mean age of patients was 20 which is five years older than patients with Ewing's sarcoma of bone. Male predominance with a sex ratio around 1.5 : 1 was also reported (18). Pain is not the most

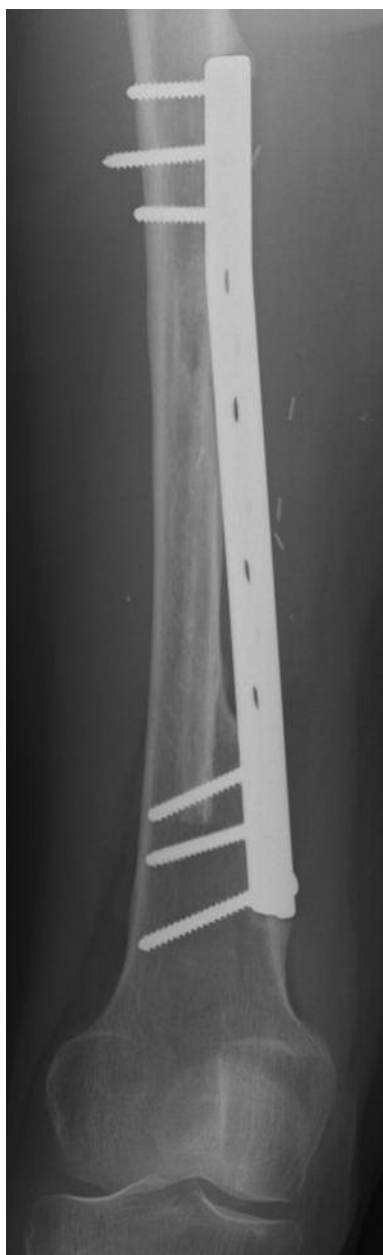


Fig. 2. — Same patient. Anteroposterior radiograph at 30 months follow-up showing very good integration of a fibular graft after screw-plate stabilisation.

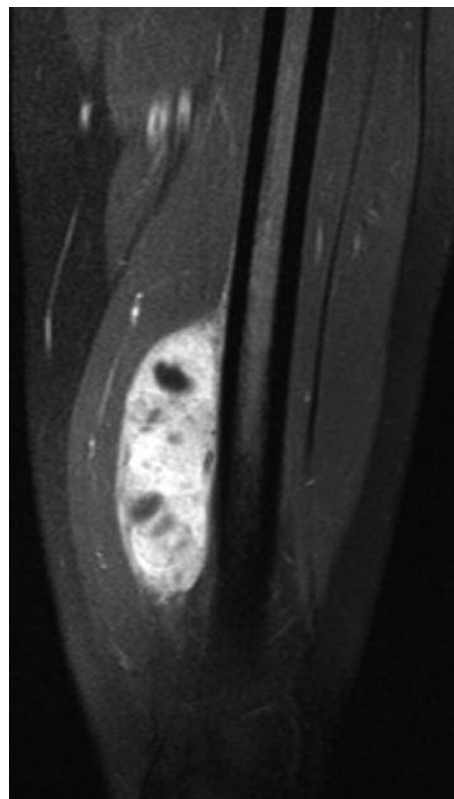


Fig. 3. — T2-weighted MRI showing heterogeneous enhancement of a large mass in the medial aspect of the vastus medialis of the right thigh after intravenous contrast injection.

frequent clinical sign as only one third of EES were painful. Pain can be explained by the inflammatory reaction of the tumour itself or by soft tissue or nerve compression. Most often, patients consult because of the recent appearance of a mass or discomfort. One of our patients felt intense pain whereas the other was alerted by the appearance of a rapidly growing mass. Preferential localisation of this tumour is the lower limb and paravertebral region (2,14,22,24). Both our patients presented indeed with the tumour in their right thigh.

Clinical diagnosis of a soft tissue tumour is easy to establish, but histological examination plays a key role (19). Differential diagnosis of EES includes: neurofibroma, histiocytoma, rhabdomyosarcoma, bone Ewing's sarcoma, liposarcoma, histiofibrosarcoma, hemangiopericytoma, angiosarcoma, neurinoma etc. A regular circumscribed mass surrounded by a capsule hypo- before and hyper-dense after contrast injection at MRI is indeed not specific for this tumour and can be encountered in almost all high-grade soft tissue tumours (18,21). Secondary involvement of bone is very uncommon (15,21). MRI is the method of choice to characterize malignant soft tissue tumours and their extension to other structures like bone, vessels and nerves. CT scan of the thorax is particularly sensitive to detect pulmonary metastases which are the most frequent. Positron Emission Tomography (PET) can be useful in staging the tumour. More recently, PET has been shown to be useful in monitoring preoperative response to chemotherapy long before this response is recorded on clinical or other imaging investigations. Biopsy of the lesion is an essential step to establish diagnosis. Frozen sections are difficult to interpret and do not give the exact diagnosis, but are important to specify the quality of biopsy material to get viable tumour. Pathologic diagnosis of EES used to require standard light and electron microscopy, looking for small, round, blue cells with abundant glycogen and absent cytoplasmic filaments (27). Nowadays the diagnosis is generally made by cytogenetics and immunochemistry, especially by fluorescence *in situ* hybridation (FISH). Immunohistochemical staining for CD99 (MIC2), a cell surface glycoprotein, is helpful (9,28). Almost all EES present a translocation of the q12 segment

of chromosome 22. About 85% have a t(11,22) (q24, q12) translocation and 5 to 10% have a t(21,22) (q21, q12) translocation (5,6,10,12,17,23). Those observations could explain the familial context described since 1995 (7). These histological features of the EES are the same as in Ewing's sarcoma (30). It is widely recognized that EES and EFTs are systemic diseases at presentation, even if documented metastases are not found. Neoadjuvant chemotherapy will not only treat the local tumour, but will also act on disseminated cancer cells. Because EES can also be considered as belonging to malignant mesenchymal tumours (MMTs) some authors recommend the same treatment as for rhabdomyosarcoma, which includes ifosfamide, dactinomycin and vincristine. Nevertheless most authors advise the same regimen as in Ewing's sarcoma of bone (Euro-Ewing) including anthracycline such as doxorubicin in addition to vincristine, ifosfamide and etoposide (4).

The question of optimal local control has not been definitively answered, because no trials comparing radiotherapy or surgery alone or a combination of both have been conducted. Most protocols recommend surgical resection rather than radiation therapy. One of the ultimate goals of surgery is wide histological margins. In order to reach this goal, margin enlarging procedures consisting of longitudinal spitting of the femur are implemented, such as in our patient. The tumour is then removed with the outer cortex. This is decided during operation because of the close relationship of the tumour with the femoral periosteum. In this way, wide histological margins are obtained and it is felt that radiation therapy will not improve local outcome. In our second case, the tumour was much more mobile and was removed with the periosteum of the femur. In this case, radiation therapy was recommended because of closer tumour margins. In the first case, the bone mass was increased by adding a fibular graft, which integrated radiologically after six months and the femur was stabilized by plating. Postoperative radiation is only recommended for positive margins or residual disease (31). Radiotherapy should of course be used for inoperable tumours. Radiotherapy is known to have many side effects such as radiation-induced malignancies, growth deformities, etc.

In our second case, adjuvant radiation therapy was used because of the close margins and the intermediate response to chemotherapy. To improve treatment we would need a prospective trial including a large number of patients. Because of the shortage of patients with EES, most of the reported literature consists of retrospective case reviews. One exception is the Intergroup Rhabdomyosarcoma Studies (IRS). Five percent of the nearly 3,000 patients they studied had EES (n = 130). Follow-up was possible for 88% of patients who had no metastasis. Survival rate at 10 years follow-up for 3 consecutive trials ranged from 61 to 77% (20). Metastases can be present at the time of diagnosis. They most often affect the lungs, sometimes the liver and brain (18). Negative prognostic factors usually include advanced age and tumour extension. Adult patients with EES at highest risk for death are those older than 26 and having metastatic disease or an extraosseous primary tumour (3).

CONCLUSION

Since extraosseous Ewing's sarcoma was identified, much has changed, particularly in the methodology of diagnosis and molecular characterization of this rare malignancy. Treatment leading to survival rates over 70% was performed in the 1980's. There has been no substantial increase in the cure rate since the use of intensive chemotherapy. Ultimately, progress will come from the discovery of targeted therapy similar to those recently discovered for several other cancers. Another potential therapeutic approach would be to target the chimeric gene itself. This has been done in an animal model but is far from clinical use at this point (13). So far the best treatment is tumour resection with large margins, followed by radiation therapy if necessary and an intensive chemotherapy including an anthracycline.

REFERENCES

1. **Allam K, Sze G.** MR of primary extraosseous Ewing sarcoma. *AJNR Am J Neuroradiol* 1994 ; 15 : 305-307.
2. **Angervall L, Enzinger FM.** Extraskelatal neoplasm resembling Ewing's sarcoma. *Cancer* 1975 ; 36 : 240-251.
3. **Baldini EH, Demetri GD, Fletcher CD et al.** Adults with Ewing's sarcoma/primitive neuroectodermal tumor: adverse effect of older age and primary extraosseous disease on outcome. *Ann Surg* 1999 ; 230 : 79-86.
4. **Castex MP, Rubie H, Stevens MC et al.** Extraosseous localized Ewing tumors : improved outcome with anthracyclines--the French society of pediatric oncology and international society of pediatric oncology. *J Clin Oncol* 2007 ; 25 : 1176-1182.
5. **Cenacchi G, Pasquinelli G, Montanaro L et al.** Primary endocervical extraosseous Ewing's sarcoma/PNET. *Int J Gynecol Pathol* 1998 ; 17 : 83-88.
6. **Day SJ, Nelson M, Rosenthal H, Vergara GG, Bridge JA.** Der(16)t(1;16)(q21;q13) as a secondary structural aberration in yet a third sarcoma, extraskelatal myxoid chondrosarcoma. *Genes Chromosomes Cancer* 1997 ; 20 : 425-427.
7. **Enzinger FM, Weiss SW.** *Soft Tissue Tumors. 2nd ed.* Mosby Company, St. Louis, 1988.
8. **Fagnou C, Michon J, Peter M et al.** Presence of tumor cells in bone marrow but not in blood is associated with adverse prognosis in patients with Ewing's tumor. Société Française d'Oncologie Pédiatrique. *J Clin Oncol* 1998 ; 16 : 1707-1711.
9. **Fellinger EJ, Garin-Chesa P, Triche TJ, Huvos AG, Rettig WJ.** Immunohistochemical analysis of Ewing's sarcoma cell surface antigen p30/32MIC2. *Am J Pathol* 1991 ; 139 : 317-325.
10. **Gururangan S, Marina NM, Luo X et al.** Treatment of children with peripheral primitive neuroectodermal tumor or extraosseous Ewing's tumor with Ewing's-directed therapy. *J Pediatr Hematol Oncol* 1998 ; 20 : 55-61.
11. **Hense HW, Ahrens S, Paulussen M, Lehnert M, Jurgens H.** [Descriptive epidemiology of Ewing's tumor – analysis of German patients from (E)CESS 1980-1997.] (in German). *Klin Pädiatr* 1999 ; 211 : 271-275.
12. **Hibshoosh H, Lattes R.** Immunohistochemical and molecular genetic approaches to soft tissue tumor diagnosis : a primer. *Semin Oncol* 1997 ; 24 : 515-525.
13. **Hu-Lieskovan S, Heidel JD, Bartlett DW, Davis ME, Triche TJ.** Sequence-specific knockdown of EWS-FLI1 by targeted, nonviral delivery of small interfering RNA inhibits tumor growth in a murine model of metastatic Ewing's sarcoma. *Cancer Res* 2005 ; 65 : 8984-8992.
14. **Kinsella TJ, Triche TJ, Dickman PS et al.** Extraskelatal Ewing's sarcoma : results of combined modality treatment. *J Clin Oncol* 1983 ; 1 : 489-495.
15. **Kobos J, Grzybowski W.** Extraskelatal Ewing's sarcoma. *Acta Chir Acad Sci Hung* 1980 ; 21 : 301-307.
16. **Maurel J, Rosell R, Lorenzo JC.** Poor prognosis Ewing's sarcoma and peripheral primitive neuroectodermal tumours (PNET). *Cancer Treat Rev* 1996 ; 22 : 425-436.
17. **Nagao K, Ito H, Yoshida H et al.** Chromosomal rearrangement t(11;22) in extraskelatal Ewing's sarcoma and primitive neuroectodermal tumour analysed by fluorescence in situ hybridization using paraffin-embedded tissue. *J Pathol* 1997 ; 181 : 62-66.
18. **O'Keefe F, Lorigan JG, Wallace S.** Radiological features of extraskelatal Ewing sarcoma. *Br J Radiol* 1990 ; 63 (750) : 456-460.

19. **Paoletti H, Colineau X, Acalet L et al.** [Ewing's sarcoma of the soft tissues : a propos of 3 cases and review of the literature.] (in French). *J Radiol* 1999 ; 80 : 477-482.
20. **Raney RB, Asmar L, Newton WA Jr et al.** Ewing's sarcoma of soft tissues in childhood: a report from the Intergroup Rhabdomyosarcoma Study, 1972 to 1991. *J Clin Oncol* 1997 ; 15 : 574-582.
21. **Rose JS, Hermann G, Mendelson DS, Ambinder EP.** Extraskelatal Ewing sarcoma with computed tomography correlation. *Skeletal Radiol* 1983 ; 9 : 234-237.
22. **Rud NP, Reiman HM, Pritchard DJ, Frassica FJ, Smithson WA.** Extrasosseous Ewing's sarcoma. A study of 42 cases. *Cancer* 1989 ; 64 : 1548-1553.
23. **Siebenrock KA, Nascimento AG, Rock MG.** Comparison of soft tissue Ewing's sarcoma and peripheral neuroectodermal tumor. *Clin Orthop Relat Res* 1996 ; 329 : 288-299.
24. **Soule EH, Newton W, Jr, Moon TE, Tefft M.** Extraskelatal Ewing's sarcoma : a preliminary review of 26 cases encountered in the Intergroup Rhabdomyosarcoma Study. *Cancer* 1978 ; 42 : 259-264.
25. **Tefft M, Vawter GF, Mitus A.** Paravertebral "round cell" tumors in children. *Radiology* 1969 ; 92 : 1501-1509.
26. **Thacker MM, Temple HT, Scully SP.** Current treatment for Ewing's sarcoma. *Expert Rev Anticancer Ther* 2005 ; 5 : 319-331.
27. **Triche TJ, Askin FB.** Neuroblastoma and the differential diagnosis of small-, round-, blue-cell tumors. *Hum Pathol* 1983 ; 14 : 569-595.
28. **Weidner N, Tjoe J.** Immunohistochemical profile of monoclonal antibody O13 : antibody that recognizes glycoprotein p30/32MIC2 and is useful in diagnosing Ewing's sarcoma and peripheral neuroepithelioma. *Am J Surg Pathol* 1994 ; 18 : 486-494.
29. **West DC.** Ewing sarcoma family of tumors. *Curr Opin Oncol* 2000 ; 12 : 323-329.
30. **Wigger HJ, Salazar GH, Blane WA.** Extraskelatal Ewing sarcoma. An ultrastructural study. *Arch Pathol Lab Med* 1977 ; 101 : 446-449.
31. **Zagar TM, Triche TJ, Kinsella TJ.** Extrasosseous Ewing's sarcoma : 25 years later. *J Clin Oncol* 2008 ; 26 : 4230-4232.