



Adult osteomyelitis : Debridement versus debridement plus Osteoset T[®] pellets

Wang CHANG, Marco COLANGELI, Simone COLANGELI, Claudia DI BELLA, Enrico GOZZI, Davide DONATI

From the Musculoskeletal Oncology Department of the Rizzoli Orthopaedic Institute, Bologna, Italy

This long-term retrospective study investigated the value of debridement versus debridement and Osteoset T[®] antibiotic-loaded calcium sulphate pellets in the treatment of adult chronic osteomyelitis.

Sixty-five patients were included in the study. The mean follow-up was 75 months (range : 36 to 334). Forty cases were treated by debridement, and 25 by debridement and Osteoset T[®]. The healing rates were 60% and 80%, respectively ; however, the difference was not significant.

In a subgroup of 39 patients with medullary osteomyelitis and a normal immune system (IA according to the Cierny-Mader classification of adult osteomyelitis), 22 patients were treated with debridement, 17 with debridement and Osteoset T[®]. The healing rates were 59% and 94%, respectively ($p < 0.05$).

Twenty-eight patients with *Staphylococcus aureus* osteomyelitis were also studied apart ; 13 were treated with debridement and 15 with debridement and Osteoset T[®]. The healing rates were 46% and 80%, respectively. The difference was not significant.

The results obtained with debridement were less good than with debridement plus Osteoset T[®], but the difference was not significant, except in a single subgroup.

Osteoset T[®] obviates the need for removal, which is the rule after implantation of gentamycin beads. Bony ingrowth is however limited.

Keywords : osteomyelitis ; bone substitute ; local antibiotic delivery ; clinical study.

INTRODUCTION

Osteomyelitis can be defined as bone and bone marrow inflammation caused by a pyogenic organism. The main predisposing factors for the development of osteomyelitis are : trauma and the introduction of bacteria, which usually occurs via the systemic circulation or directly from open-fracture wounds (6, 21). The hallmark of chronic osteomyelitis is infected dead bone within a compromised soft tissue envelope. Bone infections in children are primarily of haematogenous origin, while in adults they are usually secondary to penetrating trauma, surgery, or infection in a contiguous site.

■ Wang Chang, MD, Orthopaedic Surgeon.
Shenzhen Xixiang People's Hospital, Shenzhen Xixiang, China.

■ Marco Colangeli, MD. Orthopaedic Surgeon.

■ Simone Colangeli, MD. Orthopaedic Surgeon.

■ Claudia Di Bella, MD. Orthopaedic Surgeon.

■ Enrico Gozzi, MD. Orthopaedic Surgeon.

■ Davide Donati, Professor.

Musculoskeletal Oncology Department of the Rizzoli Orthopaedic Institute, Bologna, Italy.

Correspondence : Davide Donati, Istituto Ortopedico Rizzoli, Via Pupilli 1, 40126 Bologna, Italy. E-mail : davide.donati@ior.it.

© 2007, Acta Orthopædica Belgica.

Osteomyelitis continues to be a frequent indication for the use of intravenous antibiotic therapy, as well as a major health care cost item.

Medical treatment of osteomyelitis is usually performed in acute onset patients with progressive pain, swelling, fever, and high serum levels of the inflammatory markers (VS, PCR); however, in chronic cases, characterised by recurrent pain, sinus formation and low serum levels of the inflammatory markers, surgical treatment is the rule. The current surgical treatment of osteomyelitis includes debridement, irrigation, obliteration of dead space, osseous repair, adequate soft tissue coverage, and systemic antibiotics (15).

With regard to the filling of dead space, there are several methods available, using living tissue (muscle rotation), autogenous or allogenic cancellous bone grafts, cancellous bone chips impregnated with antibiotic, antibiotic impregnated cement beads, and biodegradable antibiotic-loaded implants, such as Osteoset T[®]. Filling with living tissues provides a direct blood supply to the necrotic area but it is deficient in bone reinforcement and therefore not reliable enough as a space filler. Although the use of cancellous bone chips after extensive curettage is a good way to fill the dead space, this tissue is still not living bone, and it can be involved in a recurrence of infection. The ideal bone filler material should provide good local antibiotics, should be resorbable or biodegradable, thus obviating the need for a second procedure to retrieve non-degradable material, and at the same time promote bone regeneration. Plaster of Paris (calcium sulphate dihydrate) and ready-to-use calcium sulphate pellets, such as Osteoset T[®], are the two main resorbable bone filler materials used in the treatment of osteomyelitis. Plaster of Paris has been used for years and is able to release antibiotics over a 4-week period approximately (2). Calcium sulphate has been advocated as a biodegradable delivery system for the administration of antibiotics in musculoskeletal infection (8). Osteoset T[®] is calcium sulphate with 4% tobramycin added; the diameter of the pellets is 4.8 mm; it is available in bottles of 10 or 20 ml. It can also be used in powder and liquid form, to be mixed with the appropriate antibiotic during operation, directly before

implantation. The authors retrospectively compared classical debridement with debridement plus Osteoset T[®].

MATERIALS AND METHODS

Sixty-five patients with chronic osteomyelitis were included in the study. These patients were treated between November 1977 and April 2003 in a University-based hospital. Their mean age was 39.8 years (range: 18 to 69); 36 patients were men, 29 were women. The site of infection was the femur in 26 cases, the tibia in 32 cases, the humerus in 5 cases, and the radius and ulna in 2 cases. The origin was exogenous trauma in 11 cases, exogenous iatrogenic trauma in 13 cases, and haematogenous in 41 cases. All 65 cases had clinical, biochemical and radiological signs of osteomyelitis; in 47 the diagnosis was confirmed by intraoperative biopsy.

The Cierny-Mader classification of adult osteomyelitis was used (4). Type I is medullary, type II superficial, type III localised, and type IV diffuse osteomyelitis. A-host means normal immune system, B-host immune system compromised locally, BS-host immune system compromised systematically, while C host means that the immune system is so severely compromised that the radical treatment necessary would have an unacceptable risk-benefit ratio.

According to this classification system, 39 cases were type IA, 2 were type IIA, 13 were type IIIA, 1 was type IVA, 4 were type IB, 3 were type IIIB, 2 were type IVB, and 1 was type IC (table I).

The pathogen was *Staphylococcus aureus* in 28 cases, *Pseudomonas aeruginosa* in 7, *Staphylococcus epidermidis* in 3, *Enterobacter cloacae* in 2, *Micrococcus* in 1, coagulase negative *Staphylococcus* in 1, and was not identifiable in 23.

Two methods of treatment were used: debridement without any other local adjuvant in 40 cases, and debridement plus implantation of Osteoset T[®] (fig 1) in 25 cases. Sequestrectomy and curettage were always performed, through a wide cortical window, until there was fresh bleeding bone. In the Osteoset T[®] group the cavity was packed with pellets (from 10 to 80 ml, mean: 29.2 ml). Tobramycin was used in 19 patients; vancomycin 10% in 6 cases, because of proven tobramycin resistance or in case of wide bone involvement by a *Staphylococcus aureus*. In all cases systemic antibiotics were used for at least two weeks postoperatively, based on sensitivity tests. In cases with lower limb infection complete weight bearing was allowed three months after surgery; fractures did not occur.

Table I. — All 65 cases classified according to the Cierny-Mader classification for adult chronic osteomyelitis

Cierny-Mader classification					
(Cases)	Type I	Type II	Type III	Type IV	Total
A-Host	39	2	13	1	55
B-Host	4	0	3	2	9
C-Host	1	0	0	0	1
Total	44	2	16	3	65

Recurrence of infection was marked by one of the following three conditions : (a) presence of a sinus ; (b) swelling associated with local redness and pain ; (c) mild pain associated with elevation of erythrocyte sedimentation rate or CRP.

A subgroup of 39 patients was considered apart : it consisted of type IA patients according to the Cierny-Mader classification (medullary osteomyelitis and a good immune system) ; 22 of these were treated by debridement only and 17 by debridement plus Osteoset T[®].

Finally, a subgroup of 28 patients were studied apart : all were affected by chronic *Staphylococcus aureus* osteomyelitis ; 13 were treated by debridement and 15 by debridement and Osteoset T[®].

In this study we were able to compare the two different methods of treatment statistically, using Student's t-test.

RESULTS

After a mean follow-up of 75 months (range : 36 to 334), 44 cases out of 65 healed (67.7%), while 21 recurred (32.3%). A flaw of the study was the fact that only the two subgroups of the 39 IA patients were comparable as to age and Cierny-Mader classification.

The main group of 65 patients

Of the 40 patients treated with debridement only, 24 healed (60%), while 16 (40%) recurred. Six recurrences were seen with Cierny-Mader condition A, 9 with condition B, and 1 with condition C. Fifteen recurrences healed after one or more further debridements ; the last patient, with condition C, was not re-treated surgically but received antibiotic treatment for 4 weeks after which he healed. Of the 25 patients treated with debridement plus Osteoset

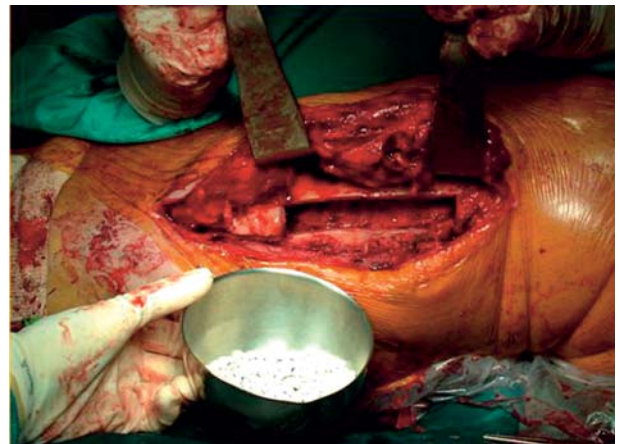


Fig. 1. — Debridement and Osteoset T[®] pellets

T[®], 20 healed (80%), and 5 (20%) recurred. Among the recurred cases, one had Cierny-Mader condition A, two condition B and two condition C. Two recurrences responded to a second debridement, one needed a third debridement. Two patients refused further treatment for their recurrence ; they had mild chronic pain and an elevated sedimentation rate without antibiotic suppression. The difference between both treatment groups was not significant.

The subgroup of 39 patients with Cierny-Mader type IA adult osteomyelitis (medullary osteomyelitis and normal immune system)

Twenty-two cases were treated with debridement only ; 13 (59%) healed, and 9 (41%) recurred. Seventeen cases were treated with debridement plus Osteoset T[®] ; 16 (94%) healed and only one (5%) recurred. This difference was statistically significant ($p = 0.024$). The patient who relapsed after

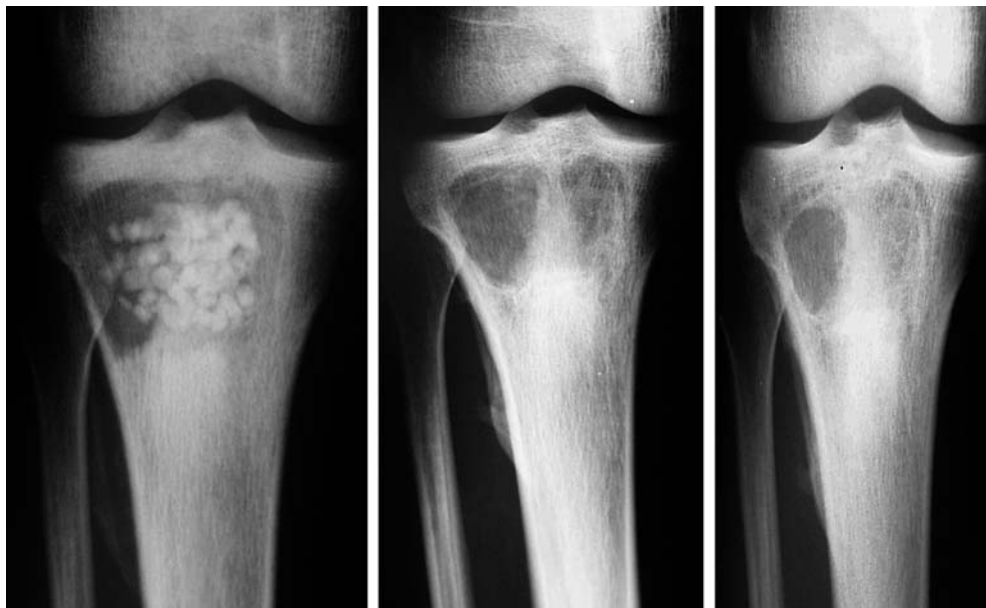


Fig. 2. — AP-views of right tibia : 1, 3 and 6 months after debridement and implantation of Osteoset T[®]. Note early resorption of Osteoset T[®] and only partial ingrowth of bone.

Osteoset T[®] was a 59-year-old woman with methicillin resistant *Staphylococcus aureus* (MRSA). One month after surgery there was a sinus, swelling with local redness, and pain. The patient refused additional surgical treatment. Now she has mild recurrent pain without other signs of local infection.

The subgroup of 28 patients with Staphylococcus aureus osteomyelitis

Thirteen patients were treated with debridement only ; 6 (46%) healed and 7 (53.85%) recurred. Fifteen patients were treated with debridement plus Osteoset T[®] ; 12 (80%) healed and 3 (20%) recurred. Among the 3 recurrences, one had Cierny-Mader condition A, while two had condition B ; all 3 recurrences healed after repeated debridement. The difference between both treatment groups was not significant.

All six cases treated with Osteoset T[®] plus vancomycin healed. In four patients the hardware, or part of it, was left inside and the osteomyelitis healed in 3 of these patients only after a second debridement including complete hardware removal.

Radiographic evolution of patients treated with Osteoset T[®]

In the patients treated with Osteoset T[®], one month after surgery 58% of the implanted pellets had degraded, with only 12% of bone ingrowth. Three months after surgery radiographs and CT-scans showed 96% pellet degradation with an average of 28% bone ingrowth. Six months after surgery there was 100% degradation, with 34% bone ingrowth, and after one year bone ingrowth was approximately 40% (figs 2, 3, 4). These findings are in line with those of other authors : in fact, the calcium sulphate was completely resorbed after a mean period of 2.7 months (11). The authors did not analyse possible side effects, such as hypercalcaemia.

DISCUSSION

The characteristic features of chronic osteomyelitis are : recurrent attacks, persistent chronic infection, thus in some cases lifetime disability. When the bone involvement is important, it is difficult to decide on the extent of debride-

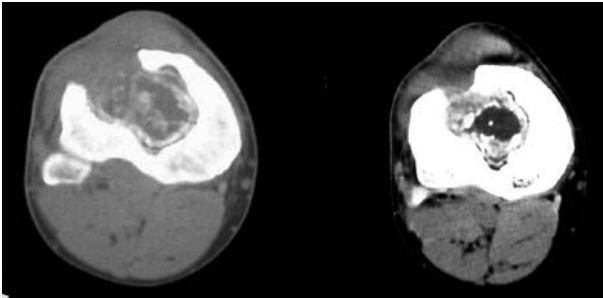


Fig. 3. — CT-scan right tibia 3 months after surgery.
Disappearance of Osteoset T[®].
Only partial ingrowth of bone

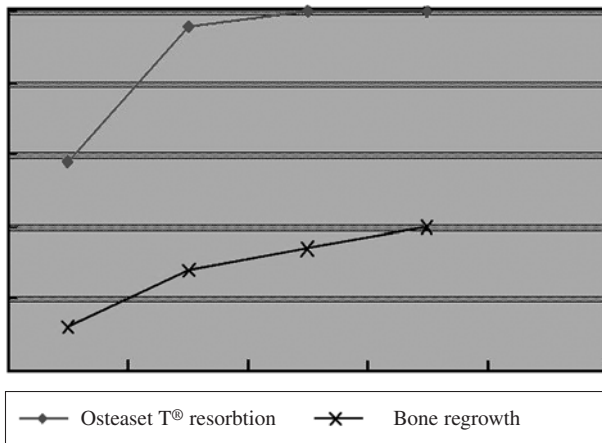


Fig. 4. — Resorption of Osteoset T[®] (upper curve),
and ingrowth of bone (lower curve)

ment (5). Suction irrigation systems are not recommended due to the risk of nosocomial infections ; the best method of treatment remains controversial.

The current study explored the effect of Osteoset T[®] in adult chronic osteomyelitis. Most previous studies on using biodegradable materials to treat adult chronic osteomyelitis have been observational studies, and have not been rigorously analysed from a statistical viewpoint. In this study we were able to compare two different methods statistically.

Despite a tendency to achieve better results with Osteoset T[®] plus debridement versus debridement only (80% vs 60%), in the overall series of 65 cases, the difference was not statistically significant. Also when considering only the 28 patients with *Staphylococcus aureus* infection, no statistical difference in the cure rate was demonstrated

between the two methods of treatment. Only when looking specifically at the 39 cases with type IA osteomyelitis (medullary involvement, good immune system and delivery), debridement and Osteoset T[®] was statistically more efficient than debridement only.

In the past gentamicin beads have been the primary choice for the local treatment of osteomyelitis (10, 19). These antibiotic-impregnated acrylic beads can sterilise and temporarily fill up the dead space. Their major disadvantage is the need to remove them within 2-4 weeks after they have eluded their antibiotics, thus requiring an additional operation (9, 20). The beads may then be replaced with a cancellous bone graft.

Antibiotic-resistant Gram-positive cocci, especially MRSA, are of great concern as they increase mortality rates and duration of hospitalisation (7). Infections with methicillin-resistant *Staphylococcus aureus* and coagulase-negative cocci have become increasingly common despite attempts to limit their spread through strict infection control practices (1, 12). Approximately 90% of staphylococci produce lactamase and are therefore penicillin resistant (16, 17). Vancomycin is a glycopeptide antibiotic which is effective against Gram-positive bacteria which are resistant to penicillins. Our study shows the importance of changing the antibiotic in the resorbable cement targeted at the last culture and susceptibility test. Osteoset T[®] mixed with vancomycin was able to heal all six patients with MRSA.

In a recent report biodegradable antibiotic pellets 3 mm in diameter were used ; they were made of lyophilised sodium alginate mixed with vancomycin, coated with poly-L-lysine (18). Various types of implants have been tested by elution studies (3, 13, 14). The goal is to achieve a complete elution of the antibiotic present in the pellet, as well as new bone generation. In the current study Osteoset T[®] provided a good antibiotic delivery along with a good infection control, however without the counterpart of complete bone regeneration. The protracted pellet resorption time makes the system effective in terms of local delivery, but there is only partial ingrowth of bone. However, when placed inside the medullary canal of a metaphysis the

natural formation of new bone in the cortical window was strong enough to allow the patients full weight bearing 3 months after surgery.

CONCLUSION

This study underlines the value of Osteoset T[®] as a space filler with good antibiotic elution properties in adult chronic osteomyelitis. A better healing rate was observed when Osteoset T[®] was used, compared with leaving the cavity empty after debridement. However, it is important to underline the insufficient ability by Osteoset T[®] to stimulate bone regeneration.

The authors suggest using this material in chronic osteomyelitis after extensive debridement of the infected bone and after hardware removal. In acute disease, or immunocompromised patients, we suggest repeating the procedure after 3-4 weeks. Better results can be achieved with Osteoset T[®] mixed with targeted antibiotic based on the susceptibility test.

REFERENCES

1. **Archer GL.** Staphylococcus epidermidis and other coagulase-negative staphylococci. In : Mandell GL, Bennett JE, Dolin R (eds). *Mandell, Douglas, and Bennett's Principles and Practice of Infectious Diseases*. 5th ed. : Churchill Livingstone, Philadelphia ; 2000, pp 2092-2100.
2. **Benoit MA, Mousset B, Delloye C et al.** Antibiotic-loaded plaster of Paris implants coated with poly lactide-co-glycolide as a controlled release delivery system for the treatment of bone infections. *Int Orthop* 1997 ; 21 : 403-408.
3. **Bowyer GW, Cumberland N.** Antibiotic release from impregnated pellets and beads. *J Trauma* 1994, 36 : 331-335.
4. **Cierny G III, Mader JT, Penninck JJ.** A Clinical staging system for adult osteomyelitis. *Clin Orthop* 2003 ; 414 : 1-24.
5. **Esterhai JL, Sennet B, Gelb H et al.** Treatment of chronic osteomyelitis complicating nonunion and segmental defects of the tibia with open cancellous bone graft, posterolateral bone graft, and soft tissue transfer. *J Trauma* 1990 ; 30 : 49-54.
6. **Gerszten E, Allison MJ, Dalton HP.** An epidemiologic study of 100 consecutive cases of osteomyelitis. *South Med J* 1970 ; 63 : 365-367.
7. **Gleason TG, Crabtree TD, Pelletier SJ et al.** Prediction of poorer prognosis by infection with antibiotic-resistant Gram-positive cocci than by infection with antibiotic sensitive strains. *Arch Surg* 1999 ; 134 : 1033-1040.
8. **Holtom PD, Smith AM.** Introduction to adult posttraumatic osteomyelitis of the tibia. *Clin Orthop* 1999 ; 360 : 6-13.
9. **Jenny G.** Local antibiotic therapy using gentamicin-PMMA chains in post-traumatic bone infections. Short and long-term results. *Reconstr Surg Traumatol* 1988 ; 20 : 36-46.
10. **Marks KE, Nelson CL, Lautenschlager EP.** Antibiotic-impregnated acrylic bone cement. *J Bone Joint Surg* 1976 ; 58-A : 358-364.
11. **McKee MD, Wild LM, Schemitsch EH, Waddell JP.** The use of an antibiotic-impregnated, osteoconductive, bio-absorbable bone substitute in the treatment of infected long bone defects : early results of a prospective trial. *J Orthop Trauma* 2002 ; 16 : 622-627.
12. **National Nosocomial Infections Surveillance System.** National Nosocomial Infections Surveillance (NNIS) system report, data summary from January 1992 to June 2002, issued June 2002. *Am J Infect Control* 2002 ; 30 : 458-475.
13. **Nelson CL, Griffin FM, Harrison BH, Cooper RE.** In vitro elution characteristics of commercially and noncommercially prepared antibiotic PMMA beads. *Clin Orthop* 1992 ; 284 : 303-309.
14. **Nelson CL, Hickmon SG, Harrison BH.** Elution characteristics of gentamicin-PMMA beads after implantation in humans. *Orthopedics* 1994 ; 17 : 415-416.
15. **Nelson CL, McLaren SG, Skinner RA et al.** The treatment of experimental osteomyelitis by surgical debridement and the implantation of calcium sulfate tobramycin pellets. *J Orthop Res* 2002 ; 20 : 643-647.
16. **Pfaller MA, Jones RN, Doern GV, Kugler K.** Bacterial pathogens isolated from patients with bloodstream infection : frequencies of occurrence and antimicrobial susceptibility patterns from the SENTRY antimicrobial surveillance program (United States and Canada, 1997). *Antimicrob Agents Chemother* 1998 ; 42 : 1762-1770.
17. **Raad I, Alrahwan A, Rolston K.** Staphylococcus epidermidis : emerging resistance and need for alternative agents. *Clin Infect Dis* 1998 ; 26 : 1182-1187.
18. **Ueng SW, Yuan LJ, Lee SS et al.** In vivo study of biodegradable alginate antibiotic beads in rabbits. *J Orthop Res* 2004 ; 22 : 592-599.
19. **Walenkamp GH.** Gentamicin PMMA beads and other local antibiotic carriers in two-stage revision of total knee infection : a review. *J Chemother* 2001 ; 13 Suppl 1 : 66-72.
20. **Walenkamp GH, Kleijn LL, de Leeuw M.** Osteomyelitis treated with gentamicin-PMMA beads : 100 patients followed for 1-12 years. *Acta Orthop Scand* 1998 ; 69 : 518-522.
21. **Winters JL, Cahen I.** Acute hematogenous osteomyelitis. A review of sixty-six cases *J Bone Joint Surg* 1960 ; 42-A : 691-704.