

Isolated meniscal repair in the avascular area

George PAPACHRISTOU, Nicolas EFSTATHOPOULOS, Spyros PLESSAS, Constantine LEVIDIOTIS,
Efstathios CHRONOPOULOS, John SOURLAS

The authors present the results of a prospective cohort study carried out in young patients, to evaluate the outcome of meniscal repair in the avascular region of the meniscus. Forty five patients underwent either open (23 patients) or arthroscopic repair (22 patients) between 1982 and 1992. Seventeen men and eight women were included in the present study ; their ages at the time of admission ranged from 16 to 27 years. They all presented with isolated longitudinal tears in the central avascular region of the meniscus. No patient with any kind of concomitant lesion was included in this series. The stitches were usually passed through the injured area and the synovium, and the knots were tightened outside the capsule. Twenty five patients of the total series, were subjected to a clinical examination in 1993, 9 to 54 months after meniscal suture. The Lysholm Knee Rating Score and the Tegner Activity Test were used. During 1999, these patients responded to a written questionnaire, based on the above mentioned rating scales. Among the 25 patients, there were 4 recurrences (16%), 2 fair results (8%) and one partial healing (4%). Eighteen (72%) patients, among which eight were treated using the arthroscopic technique, have shown favourable results, without any symptoms from the tibiofemoral joint, based on clinical examination and on the Lysholm Rating Scale and the Tegner Activity Test.

When confronted with meniscal tears where there is doubt regarding the vascularity of the injured area, surgical repair in the avascular zone appears to provide a reasonable probability of healing, with good clinical outcome.

INTRODUCTION

Meniscal repair is currently the treatment of choice for meniscal lesions located in the peripheral one-third of the meniscus. The lack of vascularity in the medial two-thirds of the menisci led surgeons to avoid any attempt to repair meniscal lesions in this area. This regime is based on King's experiments (18), according to which meniscal lesions in the avascular zone will never heal. King's observations were confirmed by Heatley (14) in 1980. On the other hand, removal of the meniscus will lead to degenerative changes of the joint, according to Fairbank (6), Jackson (16), Tapper and Hoover (33). Petersen and Tillmann (28), investigating the vascularisation of the knee joint menisci, concluded that "the occurrence of well vascularised

From St. Olga Hospital, University of Athens, Greece.

George Papachristou, Associate Professor, Director of the B' Department of Orthopaedics "St. Olga" Hospital, University of Athens.

Nicolas Efstathopoulos, Associate Professor, B' Department of Orthopaedics.

Spyros Plessas, Assistant, B' Department of Orthopaedics.

John Sourlas, Special Investigator, B' Department of Orthopaedics.

Constantine Levidiotis, Assistant, Eugenidion Infirmary, affiliated with Athens University.

Correspondence and reprints : George Papachristou, 4 Moschopoleos Street, 156 69 Papagou, Athens, Greece. E-mail : gcpap@hotmail.com.

© 2003, Acta Orthopædica Belgica.

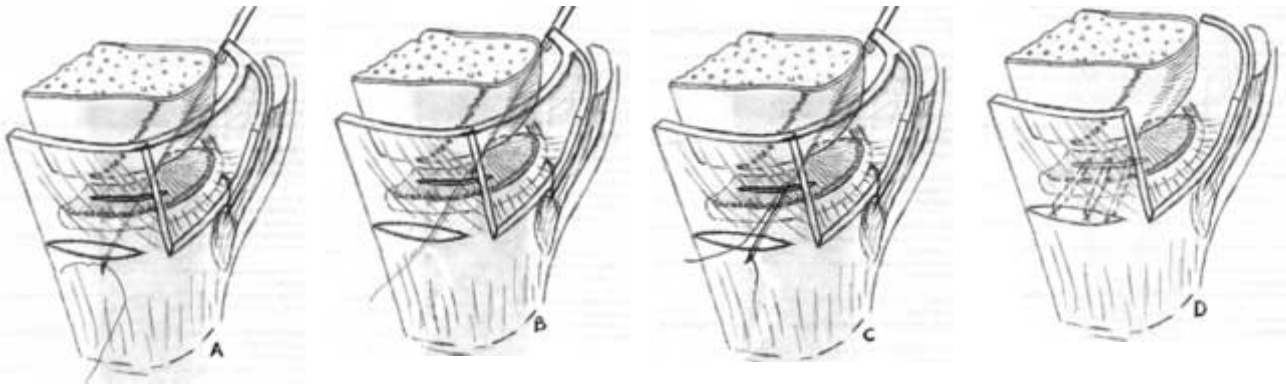


Fig. 1. — Meniscal repair in the avascular area. A+B+C : the needle passes the stiches through the injured area from inside to outside and backwards. D : after the suture of the meniscus in the avascular area has been completed.

dense connective tissue in the external circumference, must be considered as cause for the good healing of peripheral meniscus lesions” The above statement was proved earlier on by Guillquist *et al* (10) and by Hamberg *et al* (13). We have investigated the possibilities of meniscal repair in the avascular zone in white New Zealand rabbits (24), obtaining encouraging results. Considering these findings, we have extended the procedure to a number of young individuals with isolated meniscal lesions resulting from sports injuries. The results of this regime are presented in this paper.

MATERIAL AND METHODS

Forty-five patients presenting with longitudinal meniscal lesions in the avascular zone were treated in our institution between 1980 and 1992. Twenty three patients underwent meniscal repair with the open procedure (of which eight denied further follow-up) and 22 patients with the arthroscopically assisted procedure (of which 12 patients denied further follow-up). Overall, 20 patients (44%) refused to attend the follow-up clinics after the third post-operative month, because they were symptom free. We present the outcome in the remaining 25 patients, all under the age of 27 years, who all underwent direct repair of fresh longitudinal meniscal ruptures in the avascular zone. This is a prospective cohort series. Seventeen patients were males, with an average age of 21.8 years (range : 17 to 27 years), and eight females with an average age of 19.4 years (range : 16 to 23 years). All of them were involved in sports activities

(soccer, basket ball, volley ball, hand ball and running). The inclusion criteria were : isolated longitudinal ruptures in the avascular area, involving only one meniscus, in patients participating in sports. Fifteen patients (60%) were treated with an open procedure following diagnostic arthroscopy. The stiches used were 0.2 vicryl. The stiches were passed through the injured area and the synovium and the knots were tightened outside the capsule. During our early experience with the open procedure, which was performed following diagnostic arthroscopy, only lesions situated in the anterior part and the middle third of the involved meniscus, less than 1.5 cm in length, were repaired. Later on, with the arthroscopic procedure, lesions of the whole body of the meniscus, between 1.5 cm and 2 cm in length were repaired, provided that the injured area was located in the middle third, starting the measurement from the meniscosynovial junction. In the last 10 patients, the inside-out arthroscopic technique of the senior author was used (fig 1). The rehabilitation protocol was started on the first postoperative day, during which only isometric quadriceps drills were advocated. From the 2nd to the 21st post operative day, the patients were encouraged to partial weight bearing, with the leg straight and using crutches, while they continued the quadriceps drills. From the 3rd to the 6th post operative week, the patients were allowed walking with the leg straight and full weight bearing, without crutches. They were also advised to flex their knee while they were sitting. After the 6th post operative week they were instructed to progressively increase their activities until the end of the 3rd post operative month. During that period, the rehabilitation program was continued.

RESULTS

All patients were followed up for a minimum of three months postoperatively. Twenty five were followed up from 9 to 54 months (mean : 36 months). For the remaining 20 patients (44%) only clinical assessment at three months is available. The patients were examined every six months or in case they had symptoms. They were clinically assessed after an average follow-up period of 36 months, using the Lysholm Knee Score rating (33) and the Tegner Activity Test (33).

Objective demonstration of the healing process is provided only for eight patients, who complained of tibiofemoral problems and therefore underwent a second-look arthroscopy. Four (16%) of them have had a recurrence, 9 to 14 months following the initial procedure and a partial meniscectomy was performed ; the meniscal tear was found to be completely healed in three of them, and to be partially healed in one. The assessment of these patients, based on clinical grounds and the Lysholm Score is : excellent 10 patients (40%), good to excellent 8 patients (32%), fair to good one patient (4%) fair two patients (8%) and four patients were considered as failures (16%). The two patients with fair results complained of increased pain during sports activities and they had to reduce their level of performance. They have both refused to undergo a second look arthroscopy. Among the 15 patients who underwent an open procedure (10 medial menisci and 5 lateral), there were three recurrences and one fair result, while there were one recurrence and one fair result among the 10 who underwent an arthroscopically assisted procedure (7 medial menisci and 3 lateral). Fifteen patients (60%) were free of symptoms and regained their pre-injury level of activity ; they were fully satisfied and refused a second look arthroscopy. The Tegner Activity Test for the 18 patients (72%) ranged from level 6 to level 7.

Finally, in 1999, these patients responded to a written questionnaire, based on the Lysholm Rating Knee Score and the Tegner Activity Test. No differences were noted between the previous and the last assessment. At the time of the written questionnaire (1999), the average age of the patients

was 30.6 years (range : 24 to 42 years). Four patients (16%) were free of symptoms but, due to their increased age, they had to abandon soccer, handball and running and could only participate in jogging, at least four times weekly.

DISCUSSION

The semilunar cartilages are vital structures for the function of the knee joint (11). Their total or partial removal alters the biomechanical behaviour of the joint and considerably disturbs the load distribution and contact stresses (2, 7), and postoperative degenerative changes are noted in a high proportion of cases (19). These findings are in line with those of Fairbank (6) and Jackson (16).

The vascular supply of the meniscus changes with age, from 100% vascularity at 3 months to only the peripheral one-third after the 10th year of life (3). King's investigation (18) in 1936, confirmed by Heatley (14), suggesting that rupture of the meniscus in the avascular zone will never heal, dominated the field for quite a long time, until Gillquist *et al* (10) and Hamberg *et al* (13) successfully attempted to repair acute and old peripheral ruptures of the human menisci.

The lack of vascularity rises the question of the healing process, which should be similar to that of other connective tissues : exsudation, organisation, vascularisation, cellular proliferation and remodelling, providing the clot formation in the injured area. Chen *et al* (14) referring to the repair process of the articular cartilage, stated that "chondrocytes are unable to adequately proliferate, migrate and synthesise high-quality tissue in response to blunt, superficial, or deep penetrating trauma". According to McDevitt and Webber (21), "the fibrochondrocytes contain abundant endoplasmic reticulum and Golgi complex. Mitochondria are occasionally visualised, suggesting that the major pathway for energy production for the fibrochondrocytes in their avascular milieu is probably anaerobic glycolysis". Weber *et al* (35) stated that "chondrocytes responded to platelet-derived growth factor by synthesising more matrix constituents". Papachristou *et al* (24, 27) have experimented with white New Zealand rabbits, whose menisci are totally

avascular. According to investigations with Smooth Muscle Actin (SMA), an immunohistochemical staining to study the vascularity of the rabbit's menisci, blood vessels are only traced in the meniscus in the vicinity of the synovium, while the rest of it is totally avascular. The last authors came to the following explanation, concerning the healing process : Around the injured and sutured area, an increased number of meniscal chondrocytes is noted. These chondrocytes produce basic matrix, by which the repair procedure of the involved area is accomplished. This procedure will fail if the meniscal fragments are unstable. A stable environment is achieved by suturing the meniscal fragments and if these fragments are situated in the avascular area, the healing process might be slow or diminished. Modulation of this newly formed reparative tissue into normal appearing fibrocartilage, may require longer than three months.

Limited data are available concerning the results of repair of meniscal tears in the avascular area in humans. Kumagai (19), found that "proteoglycan synthesis by cells from the inner two-thirds, was higher than that by cells from the outer one-third of the meniscus, with no difference in the collagen synthesis". Also, he found that "proteoglycan synthesis by meniscus cells and articular chondrocytes was stimulated by TGF-beta 1 in a dosage-dependent manner". Papachristou *et al* (26), obtained very good results in 60% of 28 patients, with meniscal repair in the avascular zone, based on clinical grounds. Hough and Webber (15) reported that "intensive clinical and experimental experimentation suggests that serum-derived growth factors are necessary for meniscal healing".

In order to overcome the lack of vascularity and to promote healing, various investigators have employed different techniques such as : **a.** removal of the peripheral part of the injured meniscus and repair of the avascular area with the synovium, proposed by Weth *et al* (34), **b.** trephination of the periphery of the meniscus, in order to increase blood supply to the injured area, proposed by Zhang *et al* (36), and Gao (8), **c.** use of fibrin clots between the injured parts of the meniscus, by Arnoczky *et al* (1), Roeddecker *et al* (29, 30), and Isoda *et al* (17), although DeHaven (5) stated in

1990, that "stimulation of healing in the avascular zone of the meniscus by vascular-enhancement and fibrin-clot techniques remains under active experimental investigation", and **d.** direct repair with the stitches through the synovium and the involved area, in order to facilitate the invasion of blood elements and, on the other hand, to stabilise meniscal fragments, by Papachristou *et al* (24, 25, 26, 27), Noyes *et al* (22, 23), and Rudman *et al* (31).

The explanation Papachristou *et al* (27) gave about the healing process in the avascular zone, is based on two factors : **a.** the stitches are passing through the involved area and the synovium, acting in two ways : first stabilising the meniscal fragments and, second, acting as bridges, connecting the synovium with the injured area and promoting the proliferation of mesenchymal cells, **b.** the increased number of chondrocytes, brought together in the involved area and around the stitches produce basic matrix for the healing process. In other words, a stable environment in the injured area is essential and favourable for the production of basic matrix by the fibrochondrocytes, in order to complete the healing process.

An important factor, that needs further research, is the distance between the stitches. Most of the investigators are in favour of a distance close to 5mm. Since we are seeking for good stability, in order to promote sufficient repair by the basic matrix, produced by the increased number of chondrocytes and based on our results, we are proposing to reduce the distance between the stitches close to 3 mm.

In any case, the importance of preserving the meniscus to avoid post-traumatic changes in the joint, convinced us to repair it, even in the avascular zone. Based on our own findings, which show acceptable results following meniscal repair in the avascular zone, we are encouraging direct repair in cases where the physician is unable to distinguish if the lesion is situated or not in the avascular area.

REFERENCES

1. Arnoczky SP, Warren RF, Spivak JM. Meniscal repair using an exogenous fibrin clot. *J Bone Joint Surg* 1988 ; 70-A : 1209-1217.

2. **Baratz ME, Fu FU, Mengato R.** Meniscal tears : the effect of meniscectomy and of repair on intraarticular contact areas and stress in the human knee. A preliminary report. *Am J Sports Med* 1986 ; 14 : 270-275.
3. **Clark CR, Ogden JA.** Development of the menisci of the human knee joint. *J Bone Joint Surg* 1983 ; 65-A : 538-547.
4. **Chen FS, Frenkel SR, Di-Cesare PE.** Repair of articular cartilage defects : part I. Basic science of cartilage healing. *Am J Orthop* 1999 ; 28 : 31-33.
5. **DeHaven KE.** Decision-making factors in the treatment of meniscus lesions. *Clin Orthop* 1990 ; 252 : 49-54.
6. **Fairbank TJ.** Knee joint changes after meniscectomy. *J Bone Joint Surg* 1948 ; 30-B : 664-670.
7. **Fukubayashi T, Kurosawa H.** The contact area and pressure distribution pattern of the knee. A study of normal and osteoarthrotic knee joints. *Acta Orthop Scand* 1980 ; 51 : 871-879.
8. **Gao Z.** {Experimental study on healing of old tear in the avascular portion of menisci in dogs}. (Article in Chinese). *Zhonghua Wai Za Zhi* 1990, 28 : 726-729.
9. **Ghadially FN, Wedge JH, Lalonde J-MA.** Experimental methods of repairing injured menisci. *J Bone Joint Surg* 1986 ; 68-B : 106-110.
10. **Gillquist J, Hamberg P, Lysholm J.** Reattachment of the meniscus in acute and old ruptures of the meniscocapsular attachment. AAOS 1981, New Orleans 49th meeting.
11. **Ghosh T, Taylor TK.** The knee joint meniscus. A fibrocartilage of some distinction. *Clin Orthop* 1987 ; 224 : 52-63.
12. **Gray JC.** Neural and vascular supply of the menisci of the human knee. *J Sports Phys Ther* 1999 ; 29 : 23-30.
13. **Hamberg P, Gillquist J, Lysholm J.** Suture of acute and old peripheral meniscus tears. Third Congress of the International Society of the knee. Scotland, 1983.
14. **Heatley FM.** The meniscus-can it be repaired ? An experimental investigation in rabbits. *J Bone Joint Surg* 1980 ; 62-B : 397-402.
15. **Hough A, Webber RJ.** Pathology of the meniscus. *Clin Orthop* 1990 ; 252 : 32-40.
16. **Jackson JP.** Degenerative changes in the knee after meniscectomy. *Brit Med J* 1968 ; 2 : 525-527.
17. **Isoda K, Saito S.** In vitro and in vivo fibrochondrocyte growth behaviour in fibrin gel : an immunohistological study in the rabbit. *Am J Knee Surg* 1998 ; 11 : 209-216.
18. **King D.** The healing of semilunar cartilages. *J Bone Joint Surg* 1936 ; 18 : 332.
19. **Kumagai Y.** {Proteoglycan and collagen synthesis of cultured fibrochondrocytes from the human knee joint meniscus}. *Nippon Seikeigeka Gakkai Zasshi* 1994 ; 68 : 858-894.
20. **Lynch MA, Herring CE, Click KR Jr.** Knee joint surface changes. Long-term follow-up : meniscus tear treatment in anterior cruciate ligament reconstruction. *Clin Orthop* 1983 ; 172 : 148-153.
21. **McDevitt C, Webber R.** The ultrastructure and biochemistry of meniscal cartilage. *Clin Orthop* 1990 ; 252 : 8-18.
22. **Noyes FR, Barber-Westin SD.** Arthroscopic repair of meniscal tears extending into the avascular zone with or without anterior cruciate ligament reconstruction in patients 40 years of age and older. *Arthroscopy* 2000 ; 16 : 822-829.
23. **Noyes FR, Barber-Westin SD.** Arthroscopic repair of meniscal tears extending into the avascular zone in patients younger than twenty years of age. *Am J Sports Med* 2002 ; 30 : 589-599.
24. **Papachristou G.** Experimental repair of semilunar cartilage. In : Papachristou G., Agoropoulos Z. (ed). *Current Concepts in Orthopaedic Surgery and Traumatology*. Athens, 1982, pp 122-127.
25. **Papachristou G, Agoropoulos Z, Beris A.** Experimental repair of semilunar cartilage and its clinical application. VII International Congress of Orthopaedics and Traumatology of the Mediterranean and Middle East Countries, Rome, 1982, pp 437-438.
26. **Papachristou G, Agoropoulos Z, Fragiadakis E, Levidiotis C.** Possibilities of a healing process in the avascular area of menisci. *Acta Orthop Scand* 1992 ; 23 Suppl 248, p 64.
27. **Papachristou G, Mandrecas J, Liapi G, Efstathopoulos N, Bouropoulou V, Levidiotis C.** Healing of the meniscus in the avascular area. *Lo Scalpello* 1997 ; 11 : 57-60.
28. **Petersen W, Tillmann B.** Structure and vascularization of knee joint menisci. *Z Orthop Ihre Grenzgeb* 1999 ; 137 : 31-37.
29. **Roeddecker K, Nagelschmidt M, Koebke J, Guensche K.** Meniscal healing : a histological study in rabbits. *Knee Sports Traumatology, Arthroscopy* 1993 ; 1 : 28-33.
30. **Roeddecker K, Muennich U, Nagelschmidt M.** Meniscal healing : a biomechanical study. *J Surg Res* 1994 ; 56 : 20-27.
31. **Rudman MH, Noyes FR, Barber-Westin SD.** Arthroscopic repair of meniscal tears that extend into the avascular zone. A review of 198 single and complex tears. *Am J Sports Med* 1998 ; 26 : 87-95.
32. **Tapper EM, Hoover NW.** Late results after meniscectomy. *J Bone Joint Surg* 1969 ; 51-A : 517-526.
33. **Tegner Y, Lysholm J.** Rating systems in the evaluation of knee ligament injuries. *Clin Orthop* 1985 ; 196 : 43-49.
34. **Veth RPH, Den Herrton GJ, Jansen HWB, Nielsen HKL.** An experimental study of reconstructive procedures in lesion of the meniscus : use of synovial flap and carbon fibre implants for artificially made lesions in the meniscus of the rabbit. *Clin Orthop* 1983 ; 181 : 250-254.
35. **Webber RJ, Harris M, Hough AJ.** Cell culture of rabbit meniscal fibrochondrocytes : Proliferative and synthetic response to growth factors and ascorbate. *J Orthop Res* 1985 ; 3 : 36-41.
36. **Zhang Z, Arnold JA, Williams T, McCann B.** Repairs by trephination and suturing of longitudinal injuries in the avascular area of the meniscus in goats. *Am J Sports Med* 1995 ; 23 : 35-41.