



Fracture management in osteopetrosis : an intriguing enigma A guide for surgeons

Hitesh DAWAR, Vinayak MUGALAKHOD, Jahangir WANI, Deepak RAINA, Surbhit RASTOGI, Sayim WANI

From the Indian Spinal Injuries Centre, New Delhi, India

Osteopetrosis is a disorder of diminished bone resorption with hard and brittle bones resulting in high rates of perioperative complications during an operative intervention. We present a series of 4 Subtrochanteric fractures treated surgically in 3 patients of Osteopetrosis in a tertiary level Orthopaedic centre over the last 3 years with an aim to highlight our preparation and technique, especially as a guide to other surgeons, to minimise the complication rates and optimise the results. The patients had a mean Harris Hip Score of 85, at a mean follow up of 21.5 months ; the fractures united and all patients successfully returned to their normal activities of daily living.

Keywords : Osteopetrosis ; Marble bone disease ; Subtrochanteric Fractures ; Locking plates.

INTRODUCTION

Osteopetrosis is a group of bone disorders of diminished bone resorption due to osteoclastic abnormality resulting in hard and brittle bones. The disorder was first described by Albert Schonberg in 1904 (1) (thus the eponym – Albers-Schonberg's disease), and just over 300 cases have been reported in literature.

It has been classified into 3 types (18) ; Type 1 Autosomal Recessive which is extremely aggressive and frequently fatal during the initial years of childhood. It shows a failure of bone marrow

production, and the child eventually succumbs from infection and septicemia, or from bleeding, or both. Type 2 Intermediate Autosomal Recessive appears during early childhood itself, but is usually non-malignant in its course. Type 3 is Autosomal Dominant, the patient has usually a full life expectancy complicated by multiple orthopaedic, neurological and other clinical problems. There is another type described as a subtype of type 2, that is associated with renal tubular acidosis and cerebral calcification secondary to deficiency of carbonic anhydrase (8). There is another type of Osteopetrosis described in literature, Iatrogenic Osteopetrosis (21) which follows bisphosphonate toxicity during childhood that can impair skeletal modelling and remodelling with structural changes that evolve and carry into adult life.

■ Dr. Hitesh Dawar , Consultant,
■ Dr. Vinayak Mugalakhod, Senior Registrar,
■ Dr. Jahangir Wani, Senior Registrar,
■ Dr. Deepak Raina, Senior Consultant,
■ Dr. Surbhit Rastogi, Consultant,
■ Dr. Sayim Wani, Senior Specialist Registrar
Department of Orthopaedics, Indian Spinal Injuries Centre,
New Delhi, India

Correspondence : Dr. Hitesh Dawar Consultant, Department of Orthopaedics, Indian Spinal Injuries Centre, New Delhi, India ; House No. 184, Ground Floor, Sector 22, Gurgaon 122015, Haryana, India. Phone - +91-9873157651

E-mail : hiteshdawar@gmail.com

© 2017, Acta Orthopaedica Belgica.

*No benefits or funds were received in support of this study.
The authors report no conflict of interests.*

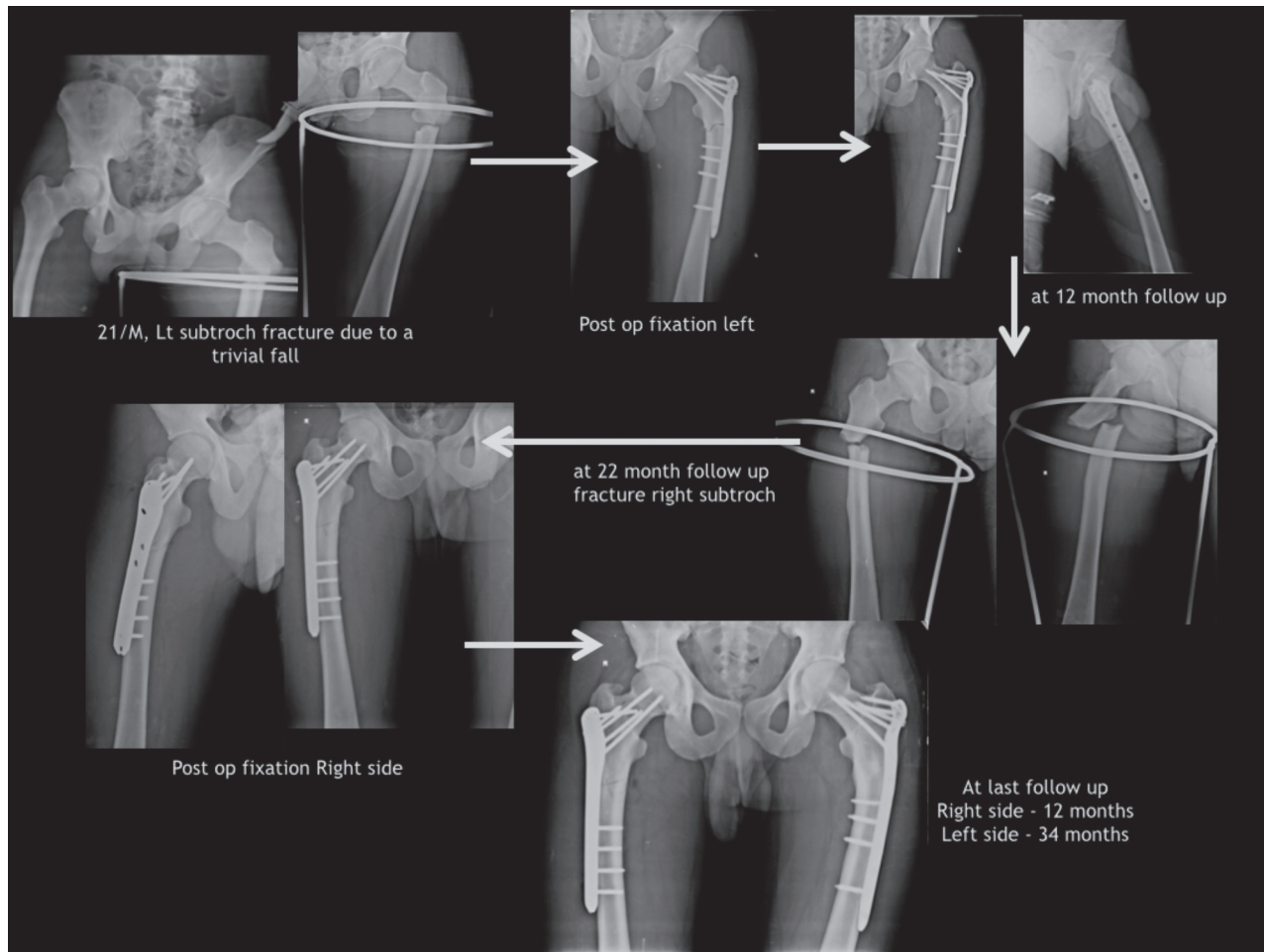


Fig. 1. — Radiographs of Patient 3 – managed for bilateral subtrochanteric fracture over 22 month interval.

Orthopaedic manifestations include back pain, bone pain and increased and recurrent fractures which may result from a trivial trauma, deformities (bowed long bones, coxa vara), hip and knee degenerative arthritis and osteomyelitis. Neurologic concerns include cranial nerve compression (visual loss due to optic nerve compression, hearing loss due to auditory nerve compression, and facial paresis etc.), hydrocephalus, seizures and mental retardation (18,21).

Subtrochanteric area and inferior neck of femur are quite susceptible to fractures in osteopetrosis (16) because these are areas of high stress. Management plan has to be individualised according to the presentation of the patient and the surgeon expertise and the available resources as there is no single method for treating such fractures (14). Operative

intervention has a high rate of intra operative and post operative complications (5,8,16), and the healing response is variable (10).

MATERIAL AND METHODS

Four subtrochanteric fractures in three patients (Table I) were operated in a tertiary care orthopaedic institute over the last 3 years were included in our study, which was a retrospective case series with a level of evidence as Level IV.

Case 1 was a 56 years male patient who sustained a subtrochanteric fracture after fall from a couple of stairs. He was managed surgically with Proximal Femur Locking plate fixation. Case 2 was a 45 years male patient, the younger sibling of the first patient with the history of a trivial fall about

Table I. – Clinical Details of Patients included in the study

| S. No. | Age (years) | Sex | Clinical Details | Management Details | Total Follow up (months) | Complications | Radiological Outcome | Clinical Outcome (HHS) |
|--------|-------------|------|--|---|--------------------------|--|----------------------|------------------------|
| 1 | 56 | Male | Subtrochanteric Fracture Right Femur after a Trivial fall | Surgery – ORIF with Proximal Femur Locking Plate | 30 | None | United | 91 |
| 2 | 45 | Male | Subtrochanteric Fracture after a Trivial fall – DHS cut out intraoperatively for a surgery done for the same elsewhere | Surgery – ORIF with Proximal Femur Locking Plate | 10 | None | United | 84 |
| 3 | 21* | Male | Subtrochanteric fracture Left hip following a trivial fall | Surgery – Implant removal with ORIF with Proximal Femur Locking Plate | 34 | Fracture on the other side 22 months later | United | 86 |
| 4 | 23* | Male | Subtrochanteric fracture Right hip following a trivial fall (implant in situ for Left Subtrochanteric fracture) | Surgery – ORIF with Proximal Femur Locking Plate | 12 | None | United | 79 |

* S No 3 and 4 in same patient – 22 months apart.

25 days back and was diagnosed as subtrochanteric fracture and operated for the same; Dynamic Hip Screw fixation was attempted but the Hip screw cut out of the head during the surgery itself. The surgery was abandoned and patient came to us. We removed the implant and did an open reduction and internal fixation with proximal femur locking plate.

Patient 3 was a 21 years old male patient (Fig. 1) with a history of trivial fall during which he injured his left hip and suffered a subtrochanteric fracture, which was managed surgically with proximal femur locking plate. 22 months later he again had a trivial fall and suffered from a subtrochanteric fracture on the right hip, which was again managed surgically with proximal femur locking plate fixation.

In all cases, the drains were removed on the first post op day; peri op antibiotic prophylaxis consisted of a single immediate preoperative antibiotic shot with a broad spectrum antibiotic followed by a single shot on the evening of the day of surgery, and another shot on the next day morning; all

the patients were mobilised and put on weight bearing as tolerated on the second post op day itself; Compression stockings and a daily dosage of Aspirin 75mg was used as a prophylaxis against deep venous thrombosis for a period of 6 weeks ; sutures were removed on 15th postoperative day; patients were followed up and Xrays were done on 6 week, 12 weeks, and 6 month follow up ; Harris Hip Score was calculated on 6 month follow up and again after every subsequent 6 month followup visit. The data was tabulated and analysed.

RESULTS

All the patients underwent operative management for the subtrochanteric fractures of femur with proximal femoral locking plating. (Table I)

Case 1 patient has been followed up for 2 ½ years (30 months) shows radiological union has good functional range of motion and a good activity, with a harris hip score of 91.

Case 2 had painless range of motion of left hip with harris hip score of 84 at 10 months followup, with fracture union visible on the last Xray.

Patient 3 Had bilateral subtrochanteric fractures (Fig. 1), united radiologically, left subtrochanteric fracture united in slight varus deformity with good functional range of motion with a harris hip score of 86 on the Right side (total of 34 months followup) & 79 on the left side (total of 12 months follow up)

The mean Harris Hip score was 85 at a mean follow up of 21.5 months.

DISCUSSION

Osteopetrosis is a rare condition, and there is relatively limited literature pertaining to fracture management in patients with osteopetrosis. Normal bone growth is achieved by a balance between bone formation by osteoblasts and bone resorption by osteoclasts. In this condition, the osteoclasts, irrespective of their number, are functionally abnormal, leading to a universal failure of bone remodelling process. The insufficient resorption results in excessive accumulation of bone matrix causing hard, dense bones with loss or narrowing of medullary canal (15). The bone growth is also affected, resulting in short and broad, or long and thin brittle bones (9).

Long bone fractures are common in Osteopetrosis (7), with a lifetime prevalence of 1 to 10 fractures per patient with the congenital form of the condition (9). Fractures in osteopetrotic bones generally occur at a right angle to the cortex (20). This was attributed to the weak resistance to tensile stresses when put on the brittle osteopetrotic bone, which usually resists compressive stresses well.

The features of fracture healing and bone remodelling in osteopetrosis are controversial. Some authors believe that the bone healing and remodelling is normal, but rather slow (16). Other authors believed that fracture callus itself was pathological (13). De palma et al in their study on a 27 year old man with osteopetrosis who suffered from and was operated for a subtrochanteric fracture of the right femur after a trivial trauma, described in detail the fracture callus histology at various stages

of healing. They obtained tissue samples from the fracture site and the surrounding normal bone at the time of initial fracture fixation, and then at 1 year at the time of implant removal, and then again after a couple of months when the patient sustained a fracture through one of the removed screw holes in the diaphysis. They reported that ten days after the fracture, the callus was histologically more or less normal. Twenty days after the fracture, immature osteoid tissue was frequently observed, and there were fewer vessels and fewer osteoclast-like cells than than the normal. They also observed that the major peculiarities in the fracture healing were observed 1 year after the fracture; even though the fracture was radiographically healed and clinically stable, histology showed unorganised tissue, and only small areas of lamellar tissue in woven bone containing randomly distributed osteocytic lacunae that were almost always empty, with rare visibility of cartilage islands, and no osteoclastic presence. The authors suggested that unlike the normal bone, which is able to reduce the stresses concentrated in the microfractures and macroscopic defects (like screw holes), in osteopetrotic bone, these micro and macroscopic defects tend to propagate along the areas of lower resistance such as cement lines, lacunae and the Haversian canals (10).

Various non-operative treatment regimens have been reported in the past (19); the earliest reports of conservative management given by Alexander et al (2) of a plaster cast used to manage a peritrochanteric fracture in an adult female which resulted in pseudoarthrosis. Hasenhault et al. (12) reported fracture union at 10 weeks following use of Russell traction for management of a peritrochanteric fracture in a 27 year male. Similarly, Dahl et al. (9), Armstrong et al. (4), and Gupta et al. (11) described successful treatment of fractures in Osteopetrosis conservatively with plaster casts and traction.

Srivastav et al. (19) in their study extensively reviewed the available literature on operative treatment in Osteopetrotic fractures in adults; they reported a non union rate of 12%, infection rate of 12%; a 29% rate of hardware failure and an incidence of periprosthetic fracture of 14% in the patients with peritrochanteric fracture. They also reported their results of use of distal femur LCP of

Table II. — A guide for surgeons : pearls to remember

| Serial No. | Clinical Situation/Problem | Suggested Pearls |
|------------|---|--|
| 1 | Mode of Union Aimed at – Primary or Secondary | Secondary union is preferable as bridging mode fixation is much more easier to obtain as compared to achieving compression across the fracture site. Advisable to use a longer plate with adequate number of locking screws proximally and distally, and to leave the fracture site bridged accordingly. |
| 2 | Choice of Implant – Extra-medullary vs Intramedullary | Extramedullary preferable as intramedullary extremely difficult to insert. The canal is extremely narrow, and with the hard sclerotic bone – Reaming will be an extremely difficult task, with a very high chances of Osteonecrosis |
| 3 | Choice of Plate – Locking vs Non Locking | Locking much preferable as construct will be stronger, especially if a longer plate in bridging mode is used |
| 4 | Drilling in Hard Sclerotic Bone | Arrange for multiple drill bits; special tungsten tipped drill bits; frequent cleaning of the drill bit off bone, sometimes multiple times even during a single hole; avoid any toggle to prevent breakage – patience while drilling is the key. |
| 5 | Heat Osteonecrosis while Drilling | Continuous irrigation suction with saline while drilling. |
| 6 | Difficulty while screw insertion | Always use a Tap prior to insertion of a cortical screw; A good screw driver and a good screw always – never use a screw even with a slight damage; always check for the required size with measuring device – extremely difficult to exchange a screw if the wrong size is inserted |
| 7 | Screw breakage while insertion | Use a screw with a larger core diameter – i.e Cortical or a Locking screw – avoid cancellous screw which has a lesser core diameter and might break while insertion; avoid any toggle while inserting screw; use of power system while screwing in will minimise surgeon fatigue and avoid mistakes. |
| 8 | Brittle Bone – How to avoid fracture around the plate | Stress distribution – the last screw should be a unicortical screw, or should be inserted at an obtuse angle directed away from the fracture site to distribute the stress at the terminal end of the plate. |
| 9 | Increase in fracture healing time | Fixation must be such that it stays stable during the time required. Locking plates are advisable for a stable construct. |
| 10 | Non Union/Delayed Union | Bone grafting might not work – the defect in bone remodelling will hamper the process of bone graft incorporation |
| 11 | Implant Removal | Avoid if possible. Screw tract will leave a stress riser which might be a site for another fracture. |
| 12 | Total Hip Replacement | Uncemented Arthroplasty; Creation of medullary canal by using multiple sequential drills and reamers of increasing size. |
| 13 | Total Knee Replacement | Extramedullary alignment; Sharp Blades for the Oscillating saw. |
| 14 | Impaired vascularity and hampered immunity | Appropriate antibiotic coverage; reduce surgical time and wound exposure as much as possible; respect of soft tissue while dissection and fixation. |

the contralateral side for fixation subtrochanteric fractures in 2 adult females with osteopetrosis.

In our cases, we believed that the Proximal Femur LCP would be the best suited implant for the patients, as the locked screw would offer the most stable construct. We preserved biology

and minimised the soft tissue dissection as much as possible to maintain good biological healing potential. The fractures were anatomically reduced by the use of clamps and traction carefully so as to prevent any iatrogenic fracture. We were prepared with multiple drill bits of varying sizes, with atleast

3 of each size, and also procured the industrial tungsten tipped drill bits from the local hardware shops and autoclaved them before the surgery; extreme care was taken while drilling with use of high speed power systems and avoidance of toggle while drilling. The drills were regularly cleaned and the bone removed, sometimes several times during each drill hole; continuous saline irrigation was done to clear off the debris and bring prevent heat osteonecrosis. While one drill was being cleared off the removed bone, the second used one was kept in the cold saline solution to bring down the temperature of the heated drill bit, and the third was used for drilling; this cycle was maintained throughout the process of drilling for screws. Power system was used to insert the screws which were self tapping as manual insertion would have been extremely difficult and possibly could have induced an iatrogenic fracture or screw breakage due to fatigue induced toggle. Spare battery for the power system was kept on standby. We used long plates and bridging mode of fixation, and applied appropriate number of screws on both the sides of fracture. We believe that the last screw should be either unicortical or should be inserted at an angle so that stress is less on the end of the construct, to prevent peri-implant fracture; this principle was not used at the time of operating the patients in this series and this insight has been gained later by experience. (Table-II).

We were fortunate enough not to encounter any complications with our patient series; though many complications like intraoperative drill breakage, screw breakage, and postoperative implant failure, infection, delayed union and non-union have been reported by multiple authors (4,8,10,19).

Various authors have also suggested many tips and techniques to manage the difficulties encountered during the surgical fixation of fractures in osteopetrotic bones; Farfan et al suggested drilling at slow speed and in spaced cycles, and avoiding the use of mallet, as well as any torsional or bending stresses to prevent intraoperative fractures (22). RK Sen et al suggested the use of metal cutting drill bit in osteopetrotic bones, with a low velocity high torque drill system (23). Bhargava et al. emphasized that it should be borne in mind

that it may not be possible to add supplementary autologous cancellous grafts in delayed or non-union because of absence of available cancellous bone (5).

There are basic science studies available to suggest that 1,25 dihydroxyvitamin D (calcitriol) and parathyroid hormone can increase the number and function of osteoclasts in osteopetrotic mice (17). There also is clinical evidence that high-dose calcitriol may decrease the symptoms of osteopetrosis (18). In addition, clinical data exists supporting the use of recombinant parathyroid hormone to enhance fracture healing in general (3). However, we did not use any of these measures to augment the fracture healing in our patients.

CONCLUSIONS

It is essential to be aware of this rare condition of osteopetrosis in a patient presenting with a fracture, and treat it as a special entity. A meticulous preoperative surgical planning, an adequate preparation in terms of availability of instrumentation and implants, a good surgical technique, anticipation of intraoperative technical difficulties, preparedness to handle a long postoperative course and high risk of infections are imperative for successful management of these cases.

REFERENCES

1. **Albers-Schonberg HE**, Rontgenbilder einer seltenen, Knochenkrankung. *Meunch Med Wochenschr* 1904 ; 51 : 365-8.
2. **Alexander W**. Report of a case of so-called "marble bones" with a review of literature and translation of an article. *AM J Roentgenol* 1923 ; 10 : 280-301.
3. **Alkhiary YM, Gerstenfeld LC, Krall E et al**. Enhancement of experimental fracture-healing by systemic administration of recombinant human parathyroid hormone (PTH 1-34). *J Bone Joint Surg*. 2005 ; 87A : 731-741.
4. **Armstrong DG, Newfiel JT, Gillespie R**. Orthopedic management of osteopetrosis: result of a survey and review of the literature. *J Pediatr Orthop* 1999 ; 19 : 122-32.
5. **Bhargava A, Vagela M, Lennox C.M.E**. "Challenges in the management of fractures in osteopetrosis"! Review of literature and technical tips learned from long-term management of seven patients. *Injury* 2009 ; 40 : 1167-71.

6. **Bollerslev J, Andersen PE Jr.** Radiological, biochemical and hereditary evidence of two types of autosomal dominant Osteopetrosis. *Bone*. 1988 ; 9(1) : 7-13.
7. **Bollerslev J, Andersen PE Jr.** Fracture patterns in two types of autosomal-dominant osteopetrosis. *Acta Orthop Scand*. 1989 ; 60 : 110-112.
8. **Chhabra A, Westerlund LE, Kline AJ, McLaughlin R.** Management of proximal femoral shaft fractures in Osteopetrosis: a case series using internal fixation. *Orthopaedics* 2005 ; 28 : 587-92.
9. **Dahl N, Holmgren G, Holmberg S, Ersmark H.** Fracture pattern in malignant Osteopetrosis (Albers-Schonberg disease). *Arch Orthop Trauma Surg* 1992 ; 111 : 121-3.
10. **De Palma L, Tulli A et al.** Fracture Callus in Osteopetrosis. *Clin Orthop Relat Res* 1994 ; 85-9.
11. **Gupta R, Gupta N.** Femoral fractures in Osteopetrosis: case reports. *J Trauma* 2001 ; 59 : 997-9.
12. **Hasenhultl K.** Review of literature and comparative studies on a case with 24 years follow up. *J Bone Joint Surg* 1962 ; 44A : 359-370.
13. **Kirkpatrick Jr JA.** Orthopedic disease, physiology, pathology, radiology. Philadelphia, *WB Saunders Company* 1968 ; 161-169.
14. **Kumar D, Jain VK, Lal H, Arya RK, Sinha S.** Metachronous bilateral subtrochanteric fracture of femur in an osteopetrotic bone: A case report with technical note. *J Clin Orthop Trauma*. 2012 ; 3 : 103-106.
15. **Marks Jr SC.** Congenital Osteopetrotic mutations as probes of the origin , structure and function of osteoclasts. *Clin Orthop Relat Res* 1984 ; 189 : 239-63.
16. **Milgram JW, Jasty M.** Osteopetrosis: a morphological study of 21 cases. *J Bone Jt Surg Am*. 1982 ; 64 : 912-929.
17. **Peura SR, Marks SC Jr.** Colony-stimulating factor 1 when combined with parathyroid hormone or 1,25-dihydroxyvitamin D can produce osteoclasts in cultured neonatal metatarsals front toothless (tl-osteopetrotic) rats. *Bone*.1995 ; 16 : 335S-340S.
18. **Shapiro F.** Osteopetrosis. Current Clinical Considerations. *Clin Orthop Relat Res*. 1993 ; 34-44.
19. **Srivastav A, Agarwal S, Mittal V, Srivastav S, Nadkarni B.** Fixation of subtrochanteric fractures in two patients with osteopetrosis using a distal femoral locking compression plate of the contralateral side. *Eur J Tr Em Surg* 2010 ; 36 : 263-9.
20. **Suzuki S, Awaya G.** Stress fracture of vertebral arch in osteopetrosis. *Clin Orthop* 1986 ; 213 : 232-6.
21. **Whyte MP, McAlister WH et al.** Bisphosphonate-Induced Osteopetrosis: Novel Bone Modeling Defects, Metaphyseal Osteopenia, and Osteosclerosis Fractures After Drug Exposure Ceases. *J Bone Miner Res* 2008 ; 23 : 1698-1707.
22. **MA Farfan, CM Olarte et al.** Recommendations for fracture management in patients with osteopetrosis : case report. *Arch Orthop Trauma Sur* 2015 ; 135 : 351-6.
23. **Sen RK, Gopinathan NR, Kumar R, Saini UC.** Simple reproducible technique in treatment for osteopetrotic fractures. *Musculoskelet Surg* 2013 ; 97 : 117-21.