



Limits of indications of the morrison wrap-around procedure in thumb reconstruction

Jens DE VOS, Wim VANHOVE, Nadine HOLLEVOET

From the Orthopaedic Department, University of Ghent.

The thumb contributes approximately 40 percent of hand function. In the case of an amputation, where replantation/revascularisation is impossible, a reconstruction should be planned as the second best treatment. Morrison described in 1980 the technique of a wrap-around partial great toe transfer. According to Morrison, the technique is best suited for reconstruction of the thumb distal to the metacarpophalangeal joint (MCPJ). In this study, we retrospectively report on 10 thumb reconstructions using the wraparound flap from the great toe. Functional results according to the level of amputation are compared. We found in our limited series, that although better results are achieved when the amputation was distal to the MCPJ, the 'wraparound' reconstruction technique still yielded acceptable functional results and outcome in amputation levels through or proximal to the MCPJ

Keywords : thumb reconstruction, thumb amputation, wrap-around flap, wraparound flap

INTRODUCTION

The thumb is indispensable in power and precision grips and as such contributes approximately 40 percent of hand function. Thumb amputation therefore constitutes a strong indication for replantation or revascularization as this yields the best possible result. In cases where this proves to be impossible, a reconstruction should be planned as the second best treatment (2,17). The reconstruction

of a thumb is a challenging surgical endeavor and many surgical techniques have been described since the first vascularised toe to hand transfer in humans by Cobbett in 1969 (3).

In 1980, Morrison described the technique of a wrap-around partial great toe transfer, which is a customized thumb reconstruction, with a minimum sacrifice of the great toe (<1.5 cm). The reconstruction provides length, stability and adequate sensibility to the esthetically pleasing thumb replica allowing for functional pinch and grasp (4,5) According to Morisson's advice the technique is best suited for reconstruction of the thumb distal to the metacarpophalangeal (MCPJ)

joint (15). The "ideal" indication is a deglovement injury distal to MCPJ, with in intact interphalangeal (IP) joint (17,23)

Lee et al. reported that amputation of the thumb proximal to the MCPJ is not a contraindication for the wraparound toe transfer.

We retrospectively report on 10 thumb reconstructions using the wraparound flap from the great toe. We compared functional results according to the level of amputation (15).

-
- Jens De Vos,
 - Wim Vanhove,
 - Nadine Hollevoet

Orthopaedic department, University of Ghent

Correspondence: Jens De Vos, *Orthopaedic department, University of Ghent.*

E-mail :devosjens@gmail.com

© 2017, Acta Orthopædica Belgica.

*No benefits or funds were received in support of this study.
The authors report no conflict of interests.*

MATERIALS AND METHODS

Following institutional review board approval, a consecutive series of patients who underwent a free wraparound big toe flap reconstruction for thumb loss were reviewed retrospectively. A fairly consistent surgical technique was used in all patients by the second author as single surgeon. Patients were invited by phone for a clinical evaluation. In the period from 1996 till 2011, 10 patients had a thumb reconstruction using a wraparound free flap from the great toe. All patients were male. The mean age at the time of surgery was 36.1 years (range 16-53). The level of amputation was at the level of the proximal phalanx (P1) in 4 cases (group 1) and at or proximal to MCPJ in 6 cases (group 2). In 6 cases, the dominant side was involved. Two patients had suffered an injury of the contralateral hand : one had severe burning injuries, and the other was wearing a myo-electrical hand prosthesis following a distal forearm amputation. All of the patients underwent soft-tissue surgery at the thumb consisting of either debridement, skin grafting or flap surgery (McGregor, posterior interosseus or local skin flap) prior to the reconstruction. We compared the results according to the level of amputation.

Surgical procedure

The surgical technique has been described in detail before hence a brief recapitulation should suffice. (4,5,6,16,18). The procedure is done in five steps. First the recipient site is prepared. The skin incision is planned to accommodate the flap and when limited extra skin is needed a PIO flap is considered. Large skin deficits should be dealt with by preparatory flap surgery according to McGregor either by free flap surgery.- The bone is prepared to accept an autologous corticospongious bone graft from the iliac crest. The digital nerves, the sensitive branches of the radial nerve, the radial artery and the commitant veins are identified. The second step is the harvesting of the composite soft tissue flap. The big toe, including the nail, is degloved, preserving a innervated medial skin strip extending around the tip of the toe (Fig. 1). The tip of distal phalanx is cut distal to the insertion of the

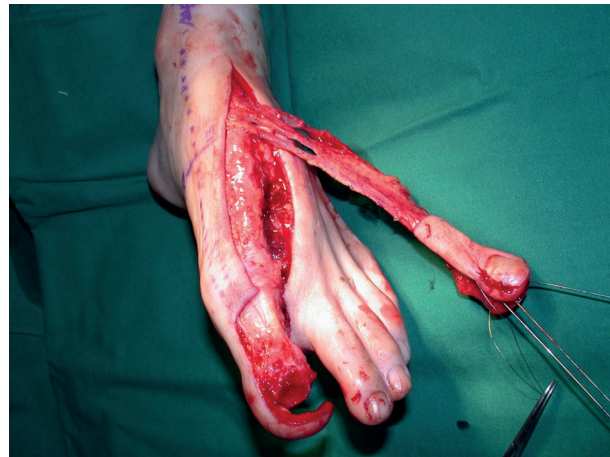

Fig. 1. — Harvesting of the composite soft tissue flap from the great toe.

terminal extensor tendon. The dorsal venous system is carefully dissected up to the saphenous vein. The dorsal arterial system (dorsalis pedis and first dorsal metatarsal artery) is explored and dissected if adequate, otherwise a more tedious dissection of the plantar metatarsal artery system is performed. The third step is insertion and fixation of the bicortical iliac bone graft on the remaining thumb skeleton using K-wires and cerclages. The iliac bone is shaped as large as the covering flap allows for to compensate for subsequent bone resorption. In the fourth step, the flap is transferred and wrapped around the iliac bone graft. Revascularisation is achieved by anastomosing the dorsalis pedis artery end to side on the radial artery. The saphenous vein is anastomosed end to end with the cephalic vein and if the opportunity arises a supplementary vein on a radial commitant vein. The plantar digital nerves are connected to the digital nerves or the sensitive branches of the radial nerve, according to the level of amputation. The skin is partially closed and usually a split thickness graft (STG) is applied to avoid any pedicle congestion. Finally, a cross toe flap of the second toe is used to close the donor big toe on the plantar side and an STG on its dorsal aspect. The cross toe flap is divided usually 3 months later (Fig. 2).

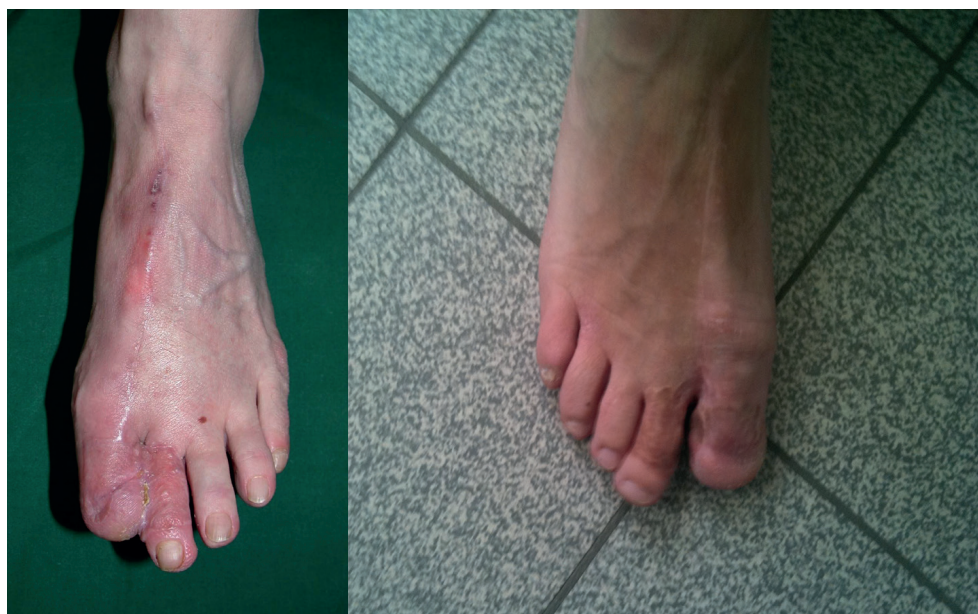

Fig. 2. — cross toe flap from the big toe (a) and after division 3 months post-op (b)

Evaluation of the functional results

We evaluated the range of motion of the reconstructed thumb in the carpometacarpal joint (CMC) and MCPJ using a goniometer. Opposition of the reconstructed thumb was scored according to the Kapandji opposition score. This opposition test consists of touching the four long fingers with the tip of the thumb : the score is 1 for the lateral side of the second phalanx of the index finger, 2 for the lateral side of the third phalanx, 3 for the tip of the index finger, 4 for the tip of the middle finger, 5 for the ring finger and 6 for the little finger. Then, moving the thumb proximally along the volar aspect of the little finger, the score is 7 when it touches the DIP crease, 8 on the PIP crease, 9 on the proximal crease of the little finger and 10 when it reaches the distal palmar crease of the hand.

Grip strength in both hands was measured with the Jamar dynamometer with the subject in the standard sitting position (90 degrees elbow flexion and neutral forearm rotation). The average of three successive trials in the handle positions 2 and 3 were recorded for each hand.

Key pinch strength was measured using the Jamar hydraulic pinch gauge, again by recording the average of three successive trials with each hand.

The sensory function was assessed with Semmes-Weinstein monofilaments, and by the static two-point discrimination test using a caliper at the tip of the new thumb.

Health related quality of life was assessed by questionnaires : the Disabilities of the Arm, Shoulder and Hand score (DASH), the Michigan Hand Outcomes Questionnaire (MHQ) and the Foot and Ankle Disability Index (FADI). The DASH symptom score measures pain and function in the upper limbs and is based on a 0 to 100 scale, with 0 indicating the best score. The MHQ covers the following domains for each hand : overall hand function ; ADL ; pain ; work performance ; aesthetics ; and patient satisfaction with the hand function. A higher score indicates more pain on the pain scale of the MHQ. Otherwise, higher scores indicate better hand performance in the other five scales (overall hand function, ADL, work performance, aesthetics, patient satisfaction with hand function) of the MHQ. The FADI was designed to assess functional limitations related to foot and ankle conditions, and is scored as a percentage, with 100% representing no dysfunction.

Several VAS (visual analogue scale) scores were used to measure the pain and cold intolerance in the hand, the foot and pelvis donor sites respectively

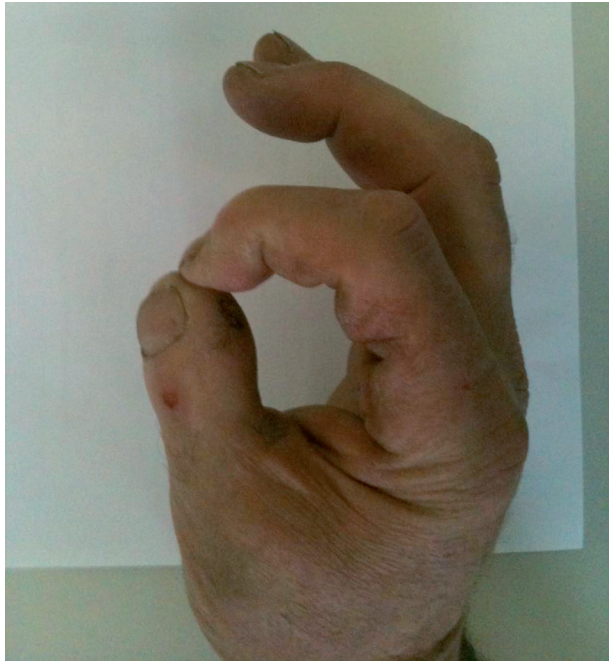


Fig. 3. — full opposition to the index was feasible in all patients who had normal long fingers.

and patient satisfaction with the cosmesis of the hand and foot. The VAS is a subjective scoring method for pain or dissatisfaction from 0 (best value = no pain / very satisfied) to 10 (worst value = the most severe pain ever / very dissatisfied) on a 10-cm scale

Statistical analysis

The study was approved by the institutional review board. Informed consent was obtained from all patients. Statistical analysis was performed using SPSS. The Wilcoxon paired rank test was used to compare the variables between the operated and the non-operated hand. To compare between the 2 study groups (MCPJ preserved or lost), the Mann-Whitney test was used.

RESULTS

All of the flaps survived. Table I summarizes the post-operative problems and secondary procedures. Four out of ten had problems at the foot. Two patients developed a hammer toe, which needed operative

correction. One patient developed a hallux valgus, and one patient had a decreased mobility of MTP 1. In group 1 (P1 level) there were no post-operative complications of the hand. In group 2 (MCPJ lost) 4 patients had problems/complications of the hand, which needed a re-intervention (scar revision surgery, reduction plasty of the pulp, curettage of a pseudarthrosis, revision of the venous anastomosis, osteosynthesis for a traumatic fracture). One patient had a post-operative infection at the harvest site of the iliac crest, which needed drainage.

The webspan of the hand as measured from the tip of the thumb, to the tip of the index was 12.47 cm (± 3.63), compared to 18.03 cm (± 2.03) in the non operated hand. In group 1, the webspan was 13.77 cm (± 3.08) compared to 10.37 cm (± 4.46) in group 2.

Fifty percent of the patients returned to their normal work. Standing on the toes was not a problem for any patient. Two patients had difficulties walking tip-toe, and found shoeing troublesome. Every patient would have the surgery again considering the hand.

Mobility

In tables II and III, the mobility of the reconstructed thumb is compared with that of the normal contralateral thumb and between the 2 groups. Two patients had only a thumb and opposition could not be assessed according to Kapandji's method. All the other patients could oppose the new thumb to the middle finger, or further. In group 1, the thumb reached to the little finger, in group 2 to the middle finger. There was no significant difference in mobility of the CMC-joint between the 2 groups.

Sensory recovery

The sensory recovery was assessed with the static 2-point discrimination test and with Semmes Weinstein monofilaments. There was a slightly better recovery in the group who had a reconstruction at P1 level. The static 2-point discrimination in group 1 was 8 mm (± 2.94) vs 12 mm in group 2. The test results for the Semmes Weinstein monofilament test were comparable in both groups varying from

Table I. — number of complications and re-interventions according to level of amputation

	Foot complications	Hand complications/problems	Complications pelvis	Re-operation hand
Group 1 (P1)	2	0	0	1
Group 2 (MCP)	2	6	1	4

Table II. — Comparison of mobility between the operated and non-operated hand

N= 10	CMC* Palmar abduction	CMC* Radial abduction	CMC* Radial adduction	CMC Retropulsion (kapandji)	Kapandji opposition score
Wrap-around	40 (± 7.801)	44.22 (± 13.581)	6.00 (± 9.333)	2.56 (± 0.882)	4.89 (± 3.180)
Contralateral hand	52 (± 15.213)	55.44 (± 9.684)	3.11 (± 11.136)	2.78 (± 0.882)	8.89 (± 0.333)
P- value (%)	0.047	0.016	0.625	0.438	0.08

* in degrees

Kapandji opposition: score from 1 to 10 depending on thumb mobility in opposition

Kapandji retropulsion: score from 1 to 3 depending on thumb mobility in retropulsion from the plane of the hand palm

Table III. — Comparison of mobility according to the level of amputation

	CMC Palmar abduction	CMC Radial abduction	CMC Radial adduction	CMC Retropulsion (kapandji score)	Kapandji opposition score	MCP Flexion	MCP Extension	ROM MCP
Group 1 N=4	37.00° (± 8.524)	45.50° (± 18.788)	8.50° (± 14.457)	2.75 (± 0.957)	6.50 (± 2.082)	35.25° (± 13.769)	-5.00° (± 16.000)	30.25° (± 16.091)
Group 2 N=6	41.67° (± 8.042)	39.33° (± 13.054)	5.00° (± 8.357)	2.17 (± 0.983)	3.67 (± 3.141)	/	/	/

‘texture sensation’ over ‘protective sensation’ to ‘insensate’.

Motor strength

Motor recovery was evaluated by measuring grip strength and pinch power. The grips strength of the reconstructed hand recovered up to 78.18% and 84.77% compared to the opposite normal hand for position 2 and 3 of the Jamar dynamometer respectively. Key pinch strength recovered up to 55.66% compared to the normal contralateral hand. (table IV and V) There were no statistically significant differences in grip nor pinch strength between the 2 groups according to level of reconstruction.

Functional scores

Details of the several functional scores are listed in table VII. The DASH score in group 1 was 13.25 \pm 12.78 compared to 36.97 \pm 29.74 in group 2. The

results of the different scales of the MHOQ are listed in table 5. The MHOQ score for the reconstructed hand was 64.28 % \pm 25.33%, compared to 84.60% \pm 12.08% in the opposite hand. One patient had an overuse injury of the opposite hand, when he was questioned. Another had severe burns at the opposite hand, and a third one was wearing a mechanical prosthesis on the opposite side. There were no significant differences between the MHOQ scores of the groups according to level Also the FADI scores in both groups were relatively equal. , 86.30% \pm 8.15% and 83.97% \pm 12.65%, in group 1 and 2, respectively.

The results of the VAS scores are illustrated in table VI.

DISCUSSION

The goals of reconstruction are a stable, sensate and esthetically pleasing thumb with adequate length, and capable of a functional pinch and grasp.

Table IV. — comparison of grip and pinch strength between operated and non-operated hand

KgF	Key pinch	Grip strength (Jamar 2)	Grip strength (Jamar3)
Wrap-around	5.02 (± 3.71)	37.98 (± 21.68)	39.93 (± 16.51)
Contralateral hand	9.018 (± 2.07)	48.58 (± 15.29)	47.10 (± 14.05)
%	55.66	78.18	84.77

Table V. — comparison of strength between 2 groups

	Key pinch	Grip strength (Jamar 2)	Grip strength (Jamar3)
MCP	2.80 (± 3.13)	32.20 (± 23.24)	43.30 (± 5.66)
P1	7.26 (± 3.21)	42.16 (± 22.88)	38.24 (± 20.79)

Table VI. — VAS scores

	VAS cold intolerance	VAS pain hand	VAS pain foot	VAS disfiguration hand	VAS disfiguration foot	VAS pelvis
MCP	4.35 (± 3.93)	4.5 (± 2.85)	4.38 (± 3.67)	4.59 (± 3.72)	4.00 (± 4.73)	0.67 (± 1.63)
P1	3.55 (± 2.11)	1.75 (± 1.87)	5.03 (± 2.77)	3.50 (± 4.36)	4.00 (± 4.24)	1.00 (± 2.00)

Table VII. — MHOQ data comparing toe transfer hands with the contralateral hand, and comparison between the 2 study groups

MHOQ scales	wraparound	Contralateral hand	Difference	Group 2	Group 1	difference
Function	57.78 (± 33.18)	91.11 (± 13.87)	33.33	39.17 (± 30.23)	77.50 (± 23.63)	38.33
ADL	47.78 (± 36.58)	97.22 (± 8.33)	49.44	26.67 (± 30.77)	68.75 (± 33.510)	42.08
Aesthetics	61.81 (± 34.58)	90.97 (± 19.54)	31.35	54.17 (± 29.22)	70.31 (± 39.98)	16.14
Satisfaction	59.26 (± 29.15)	94.44 (± 9.32)	35.18	46.53 (± 24.36)	73.96 (± 27.72)	27.43
Work	69.00			59.17 (± 35.70)	83.75 (± 15.52)	24.58
Pain	33.05			40.92 (± 22.69)	21.25 (± 20.16)	19.67
MHOQ score	64.28 (± 25.33)	84.60 (± 12.08)	20.32	50.28 (± 24.04)	76.00 (± 25.15)	25.72

Thumb replantation offers superior results with respect to all of the stated goals of reconstruction, without any donor-site morbidity (20). When replantation is not possible, the potential options for thumb reconstruction are bone lengthening and web deepening procedures, pollicisation, composite tissue transfer from the foot or provision of a prosthetic thumb with or without an osseointegrated implant. (4,10,19,21)

Pollicisation of the index or middle finger, although originally described for reconstruction a hypoplastic or an absent thumb, is also suitable for reconstructing defects proximal to the MCPJ, when the thenar muscles can be preserved. (8,16,20).

To avoid the sacrifice of an entire big toe, a technique of partial prelevation under the form of a 'wraparound flap' from the big toe was proposed by Morrison et al. (15) Because of the acceptable

discomfort and limited disfiguration at the donor site, this procedure has been widely used. However some reservations were made to use this technique in amputations at or proximal to the MCPJ, because after a 'Morrison wraparound' for a transmetacarpal amputation there is only one single mobile thumb joint at the CMC level left for all thumb movement. An extra mobile MCPJ yields a better functional recovery of the thumb. (4,5,14,16)

The purpose of this study was to assess a sample of patients who had a thumb amputation, followed by reconstruction with wraparound toe transfer, and to compare the results of patients who either kept or lost their MCPJ. Clinical tests and validated outcome questionnaires were used to evaluate the function and impact of toe transfers. There were no statistical differences found between the two groups, possibly by the low sample size.

Our data showed that the reconstructed thumbs with an MCPJ had a better mobility. This difference in mobility is best seen, when the Kapandji opposition score of the 2 groups is compared. To obtain maximum thumb mobility in transmetacarpal amputations a classic big toe transfer is apparently better than a second toe transfer according to the Finnish series of Kotsankalo et al. : Patients who had a reconstruction with a big toe had on average 10° more active movement and 21° less extension lag in the IP joint, when compared to second toe transfer (12).

The grip strength we measured in both groups was satisfactory, being 84.77% of the opposite hand. Patients with distal amputations tended to have a stronger pinch. Chung et al reported paradoxical results when measuring strength following thumb reconstruction using toes : pinch strength was generally lower in the toe transfer hands compared to the contralateral hands but grip strength was higher in the toe transfer hands than in the normal contralateral hands. Grip strength for big toe transfers and second toe transfers were quite similar (2). Doi et al. reported satisfactory grasp and pinch power in their series with an intact MCPJ. Half of their patients returned to heavy labour (5). In a toe to thumb transfer series consisting of 85% second toe transfers Kotkansalo et al. reported a median key pinch and grip strength of 62 and 67%

respectively, compared to the contralateral uninjured hand. They found that a strong correlation between a strong key pinch and the other primary subjective and objective outcome measures (12).

These results are quite comparable with those of Dong Huang et al. They reported a grip strength that was 78% of the opposite hand for the wraparound procedure, and 68% for the second toe transfer (7).

Another series of wraparound thumb reconstructions distal to the MCPJ recorded a pinch strength that was 51% of the unaffected normal hand, and a 2-point discrimination of 7.6mm, which was often greater than for the same area on the opposite foot (6). In our series, the 2-point discrimination in the group who had amputation at the MCPJ was 12 mm. There was also a diminished protective sensation in this group, as measured by the Semmes Weinstein monofilament test

Don Huang et al. report a 2-point discrimination of 7.8mm after a wraparound procedure for amputations at IP joint and 7.6mm after second toe transfer for amputation at MCPJ level (7). According to the results of Kotkansalo et al. the number of nerves reconnections did not have a significant influence on the achieved sensation of the transfer. However, patient with less reconnections scored worse on functional tests (12).

In our study the DASH score was higher in the transmetacarpal group, (36.97) compared to amputations distal to the MCPJ (13.25), which means that more proximal amputations retain a higher level of disability following wraparound reconstruction. It is reported by Parvizi et al. that the average Manchester modified DASH score in patients with an amputated thumb is 32.77, however the sample size in their report was also low (n = 11) and in all cases the amputation was at the level of the proximal phalanx (19). The MHOQ scores show that the patients with an amputation distal to MCP score better in each subscore. The differences are the greatest when it comes to ADL and function. When comparing pain, cosmesis, work and satisfaction, the differences are less obvious. Chung et al reported higher overall MHOQ scores in patients who had a big toe transfer, compared to second toe transfer. Big toe transfer patients also had a higher mean score in the aesthetic scale than second toe

patients (2). In the report of Kotkansalo et al., all the patients who had thumb reconstruction by big or a second toe scored markedly well in the ADL questionnaires, most activities were considered easy or quite easy, and most patients had no or minor complaints during ADL. Activities that required fine manipulation such as buttoning-up and using a screwdriver were difficult, but not impossible (12).

When we compare the different VAS scores that were measured in our study group, we noted no big differences when it comes to cold intolerance, pain in the donor foot or pelvis nor cosmesis. According to the level of amputation, patients with preservation of the MCPJ or thenar muscle function tend to perform better than more proximally amputated patients. Unsurprisingly, patients with multiple fingers injured in addition to the thumb amputation performed worse following toe transfer than the isolated thumb amputations (12). Our data supports these findings.

Lee et al. made a comparative study similar to ours and reported that amputation at or proximal to the MCPJ is not a contraindication to a wraparound reconstruction. They found no differences between groups concerning pinch or grasp power. The average 2 point discrimination was better in the group with the level of amputation distal to the MCPJ ($9.04\text{mm} \pm 2.2\text{mm}$ versus $11.2 \pm 1\text{mm}$). They further studied the position of the iliac bone graft and found that the group, in which the bone graft was fixed in 30° of flexion and 45° of internal rotation, had a better opposition of the thumb (15).

Complications of the technique are similar as in any microvascular procedure. Kvernmo reported in a retrospective review of 87 toe-to hand transfers that there was an improved vascular patency and survival, compared to a report that was published 27 years earlier (98% overall survival versus 91% overall survival). They also reported fewer re-explorations and secondary procedures (11% and 51% versus 33% and 65%, respectively (13). Technique specific complications include fracture and resorption of the bone graft and donor site morbidity. Bone graft resorption invariably occurred in the early procedure, as described by Morrison, because only the periosteum of the distal phalanx was transferred. In the updated version a

viable piece of distal phalangeal bone of the toe is transferred which contributes to revascularisation of the bone graft minimizing bone resorption in the graft. Fracture of the bone graft should still be considered a major problem in heavy laborers (4,14). Donor site morbidity includes wound problems and difficulties in walking upon slopes and or uneven ground. There is a weaker push-off, and a decreased running speed (4,16,17). Kotkansalo et al. evaluated long-term donor site consequences following (second) toe transfer and observed an increased risk to develop a hallux valgus deformity after toe transfer, which was associated with worse functional scores. However, these patients did not report inferior patient-reported outcomes (11). They therefore concluded that the donor site defect was in most cases of minor inconvenience and that the patient satisfaction remained at a high level. The majority recovered to normal donor foot function within 6 months. The length of the second metatarsal included in the single second toe transfer, and the number of nerves harvested nerves did not influence donor site morbidity. The patient-reported and functional results seemed generally better in patients who had second toe transfer compared to great toe transfer. (2,11) In our series there was no restriction in ordinary ambulatory activities. Two patients had difficulties walking tip-toe, and found shoeing troublesome.

Recent reports have identified an osseointegrated thumb prosthesis as a stable long-term reconstructive option when a donor toe is not available as in post septicemia amputations or if refused by the patient (1,9,22). Brånemark et al. measured 70% of grip-strength and 95% of hand function in a cohort of 13 unilateral transmetacarpal thumb amputees. A measurable sensation via the osseointegrated prosthesis was found in all patients (1). The need for lifelong maintenance of the screw-on exoprostheses is a drawback and potential infectious and mechanical complications need to be reckoned with (1, 22).

CONCLUSION

Traumatic loss of the thumb causes significant disability, and appropriate reconstruction is generally recommended. A number of investigators

reported that reconstruction of the thumb using a wraparound free flap from the big toe is less appropriate for amputation levels at or proximal to the MCP joint. We found in our limited series (N=10) that although better results are achieved when the amputation was distal to the MCPJ, the 'wraparound' reconstruction technique still yielded acceptable functional results and outcome in amputation levels through or proximal to the MCPJ. Such proximal thumb amputation levels therefore still constitute an acceptable indication for the wraparound technique in fully grown patients when they are suitable for microsurgical reconstruction and willing to accept some donor site morbidity in the foot and potentially at the iliac crest. The operative technique is demanding and complications need to be dealt with but the resulting new thumb is overall very functional and esthetically quite pleasing. The result can be expected to last a life time.

REFERENCES

1. **Brånemark R, Kulbacka-Ortiz K, Caine-Winterberger K.** Treatment of patients with transmetacarpal I amputation using osseointegrated percutaneous implants: A retrospective follow up. 6th International Conference: Advances in Orthopaedic Osseointegration, Henderson, NV, USA March 26-27, 2015. Paper 25
2. **Chung KC, Arbor A, Wei FC.** An outcome study of thumb reconstruction using microvascular toe transfer. *J Hand Surg* 2000 ; 25A : 651-658
3. **Cobbett JR. Free digital transfer.** Report of a case of transfer of a great toe to replace an amputated thumb. *J Bone Joint Surg Br.* 1969 ; 51 : 677-679
4. **Doi K, Hattori Y, Dhawan V.** The wrap-around flap in thumb reconstruction. *Tech Hand Up Extrem Surg* 2002 ; 6 : 124-132.
5. **Doi K, Kuwata N, Kawai S.** Reconstruction of the thumb with a free wrap-around flap from the big toe and an iliac-bone graft. *J Bone Joint Surg Am.* 1985 ; 67 : 439-45.
6. **Hahn SB, Park HJ, Kang HJ, Kang ES.** Finger reconstruction with a free neurovascular wrap-around flap from the big toe. *J Reconstr Microsurg* 2001 ; 17 : 319-23
7. **Huang D, Wang HG, Wu WZ, Zhang HR, Lin H.** Functional and aesthetic results of immediate reconstruction of traumatic thumb defects by toe-to-thumb transplantation. *Int Orthop* 2011 ; 35 : 543-47
8. **Ishida O, Taniguchi Y, Sunagawa T, Suzuki O, Ochi M.** Pollicization of the index finger for traumatic thumb amputation. *Plast Reconstr Surg* 2006 ; 117 : 909-914
9. **Jönsson S, Caine-Winterberger K, Brånemark R.** Osseointegration amputation prostheses on the upper limbs : methods, prosthetics and rehabilitation. *J Prosthet Orthot Int* 2011 ; 35 : 190-200
10. **Kumta SM.** Unfavourable results in thumb reconstruction. *Indian J Plast Surg* 2013 ; 46 : 294-302.
11. **Kotkansalo T, Elo P, Luukkaala T, Vilkki SK.** Long-term effects of toe transfers on the donor feet. *J Hand Surg* 2014 ; 39 : 966-976
12. **Kotkansalo T, Vilkki S, Elo P and Luukkaala T.** Long-term functional results of microvascular toe-to-thumb reconstruction. *J Hand Surg* 2011 ; 36 : 194-204
13. **Kvernmo HD, Tsai TM.** Posttraumatic reconstruction of the hand : a retrospective review of 87 toe-to-hand transfers compared with earlier report. *J Hand Surg* 2011 ; 36A : 1176-81
14. **Lee KS, Che IJ.** Thumb reconstruction with a free neurovascular wrap-around flap from the big toe : long term follow up of thirty cases. *Microsurgery* 1995 ; 16 : 692-7
15. **Lee KS, Park JW, Chung WK.** Thumb reconstruction with a wraparound free flap according to the level of amputation. *J Hand Surg* 2000 ; 25A : 644-650.
16. **Morrison WA, O'Brien BM, MacLeod AM.** Thumb reconstruction with a free neurovascular wrap-around flap from the big toe. *J Hand Surg* 1980 ; 5 : 575-583.
17. **Muzaffar AR, Chao JJ, Freidrich JB.** Posttraumatic thumb reconstruction. *Plast Reconstr Surg* 2005 ; 116 : 103e-121e.
18. **Nunley J, Goldner RD, Urbaniak J.** Thumb reconstruction by the wrap-around method. *Clin Orthop Relat Res* 1985 ; 195 : 97-103.
19. **Parvizi D, Koch H, Friedl H, Spendel S, Hubmer M, Parvizi I, Prandl E, Rappl T, Haas F.** Analysis of functional outcome after posttraumatic thumb reconstruction in comparison to nonreconstructed amputated thumbs at the proximal phalanx of the thumb ray : a mid-term follow-up with special attention to the Manchester-modified M2 DASH questionnaire and effect size of Cohen's d. *J Trauma Acute Care Surg* 2012, 72 : 33-40
20. **Pet MA, Ko JH, Vedder NB.** Reconstruction of the traumatized thumb. *Plast Reconstr Surg* 2014 ; 134 : 1235-45
21. **Sabapathy SR, Venkatramani H, Bhardwaj P.** Reconstruction of the thumb amputation at the carpometacarpal joint level by groin flap and second toe transfer. *Injury* 2013 ; 44 : 370-5
22. **Sierakowski A, Watts C, Thomas K, Elliot D.** Long-term outcomes of osseointegrated digital prostheses for proximal amputations. *J Hand Surg* 2011 ; 36E : 116-125
23. **Wei FC, Chen HS, Chuang CC, Chen SHT.** Microsurgical thumb reconstruction with toe transfer : selection of various techniques. *Plast Reconstr Surg* 1994 ; 93 : 345-351