



Greater tuberosity sclerosis: a radiographic sign of rotator cuff Tear?

Tarek Mohamed GHANDOUR, Sherif Ahmed ELGHAZALY, Ahmed Mohamed GHANDOUR

From the Ain Shams University, Faculty of Medicine, Orthopedic Department, Cairo, Egypt

The study had been carried out to investigate the relation of sclerosis of the greater tuberosity to cuff tear, or whether this may signify partial or complete tear. This retrospective study conducted on 425 patients, 250 Females (58.8%) and 175 males (41.2%). Dominant side was affected in 342 Patients (80%). The average age in males was 46 years (24-68 years) and 54.5 years in Females (44-65 years). Greater tuberosity sclerosis had 93.5% sensitivity for rotator cuff tear, 67.5% specificity, 90.4% positive predictive value (PPV), 51.9% negative Predictive value (NPV) and 85.2% accuracy. Greater tuberosity sclerosis had both high sensitivity and positive Predictive value for rotator cuff tears; however, more in-depth evaluation was required to better understand the relation between greater tuberosity sclerosis and rotator cuff tear. Level of evidence III.

Key words : MRI, rotator cuff, tear greater tuberosity, sclerosis

INTRODUCTION

Radio-graphic findings of the shoulder joint had been reported in patients with rotator cuff tear. Greater tuberosity changes were among the most reported. Some authors only mention upward migration of the humeral head and acromial spurring. However, Knipe et al. (3) mentioned that radio-graphic signs of rotator cuff tear may include secondary degenerative changes as sclerosis, subchondral cysts, osteolysis, and notching or pitting of the greater tuberosity. In chronic rotator cuff disease, with or without a tear, there may be

sclerosis of the greater tuberosity and cyst formation along with subacromial spurring. (7)

A scapular outlet view was essential in the work-up of a suspected rotator cuff tear. Findings include subacromial sclerosis “eyebrow sign”, sclerosis and cyst formation of the greater tuberosity and narrowing of the acromio-humeral distance (AHD) (<7mm). (6)

No formal study had been carried out to investigate the relation of sclerosis of the greater tuberosity to cuff tear, or whether this may signify partial or complete tear. The purpose of this current study to determine the relation between sclerosis of the greater tuberosity and rotator cuff Tear and significance of this radio-graphic sign supported our hypothesis that there is indeed a relation between greater tuberosity sclerosis and rotator cuff tear.

PATIENTS AND METHODS

This study was conducted from July 2009 until May 2013 in a retrospective fashion and included 425 patients, 250 females (58.8%) and 175 males

- Tarek Mohamed Ghandour, M.D
- Sherif Ahmed Elghazaly, M.D.
Ain Shams University, faculty of medicine, orthopedic department.
- Ahmed Mohamed Ghandour, M.D.
Ain Shams University, faculty of medicine, radio-diagnosis department.

Correspondence : Tarek Mohamed Ghandour

Email : tarekghndr@yahoo.com

© 2017, Acta Orthopædica Belgica.

*No benefits or funds were received in support of this study.
The authors report no conflict of interests.*

(41.2%). Dominant side was affected in 342 patients (80%). The average age in males was 46 years (24-68 years) and 54.5 years in females (44-65 years). Inclusion criteria were : shoulder pain for six months or more with difficulty in moving the shoulder, painful limited abduction and forward flexion on examination, no improvement on physical therapy or local injection and no prior surgery. All patients underwent true anteroposterior and supraspinatus outlet plain radio-graphs. Patients who were not responding to 6 weeks of medical treatment underwent magnetic resonance imaging. The exclusion criteria were glenohumeral or acromioclavicular arthritis, shoulder instability, history of previous surgery or shoulder joint fracture and severe neurological deficit.

M.R.I. of the shoulder was performed with a 1.5 T superconducting unit (Magnetom Espree, Syngo, MR B15, Siemens, Erlangen, Germany) using a phased-array multi-coil.

No specific preparation was required nor contrast agents used. Shoulder MRI Scan was performed for all patients as follows : GRE sequence in axial plane, PD fat sat sequence in axial, coronal and sagittal planes, T2 fat sat sequence in coronal plane and T1 sequence in coronal plane.

Greater tuberosity sclerosis was defined as cortical thickening and subchondral sclerosis, extending from the articular cartilage of humeral head to the lateral humeral cortex on a true AP Shoulder radio-graph.

Radio-graphs were examined for greater tuberosity sclerosis by the first two authors independently. Later, M.R.I. scans were examined by the last two authors independently for cuff Tear.

One hundred patients (23.5%) agreed to undergo arthroscopic shoulder surgery, confirming the presence of partial or complete rotator cuff tears. These were repaired back to bone using two or three anchors.

Statistically, positive predictive value was calculated as : The number of true positives divided by the number of true positives plus the number of false positive. Negative predictive value was calculated as the number of true negatives divided by the number of true negatives plus the number of false negatives.

Sensitivity was calculated as the number of true positives divided by the number of true positives plus the number of false negatives. Specificity was calculated as the number of true negatives divided by the number of true negatives plus the number of false positives.

RESULTS

Sclerosis was detected in 398 cases (93.6%). Of those, 360 (90%) were found to have a tear of the rotator cuff documented on M.R.I.

One hundred patients had been operated by arthroscopy and a tear documented intra-operative. We found that greater tuberosity sclerosis had 93.5% sensitivity for rotator cuff tear, 67.5% specificity, 90.4% positive predictive value (PPV), 51.9% negative predictive value (NPV), and 85.2% accuracy (Table I).

Despite being more prominent with large-sized tears, no statistical relation was found between sclerosis of the greater tuberosity and the site or size of the tear. We noticed that in partial tear degree of sclerosis was less than complete tear for further evaluation.

There was direct relation between the duration of symptoms and the degree of greater tuberosity sclerosis. But there was no relation between the age of the patient and the degree of greater tuberosity sclerosis.

DISCUSSION

Rotator cuff disease was the most common cause of shoulder pain and dysfunction in adults.

Effective treatment of cuff disease requires an efficient diagnosis of cuff pathology. Although, M.R.I remains the gold standard for cuff evaluation, plain radio-graphs may point to rotator cuff Pathology. The ability to efficiently correlate radio-graphic signs to cuff pathology may increase the index of suspicion, and allow early diagnosis of cuff tears.

Among the plain radio-graphic signs that were related to cuff tear, greater tuberosity cystic changes (Fig. 1, 2) osteopenia and notching had been mentioned.

Table I. — Diagnostic efficiency of greater tuberosity sclerosis for rotator cuff tear

Sensitivity	93.5%
Specificity	67.5%
PPV	90.4%
NPV	51.9%
Accuracy	85.2%

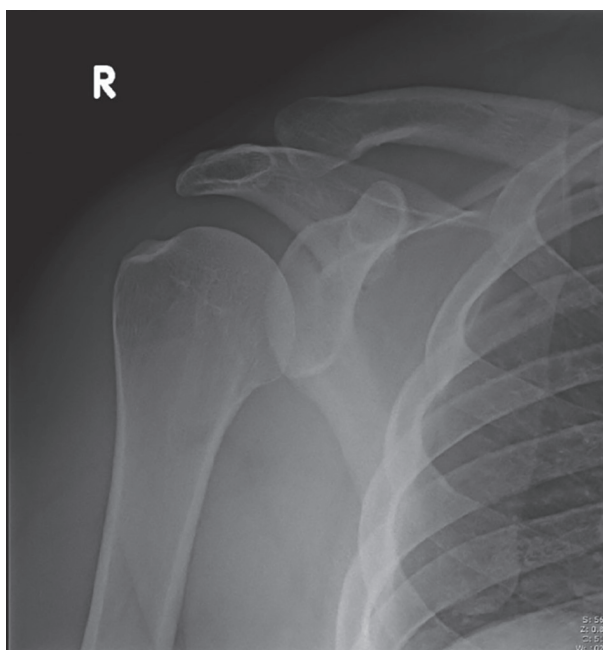


Fig. 1. — Plane X-ray of the right shoulder joint AP view showing greater tuberosity sclerosis.

Sclerosis of the greater tuberosity had been suggested (Fig. 3, 4 & 5, 6), but no formal study had been performed.

Sonographic examination of shoulders had been carried out to detect the Significance of irregularities of the greater tuberosity. (9)

This study showed a significant relationship between irregular tuberosities and cuff tear and it to be independent of age. (9)

Results of this study also showed 90 % sensitivity and 89 % specificity for irregularities of the greater tuberosity as shown by ultrasound.

On plain radio-graphs, greater tuberosity excavation was seen to correspond to areas of irregularity. Some institutions primarily use ultrasound for detection of rotator cuff tears.

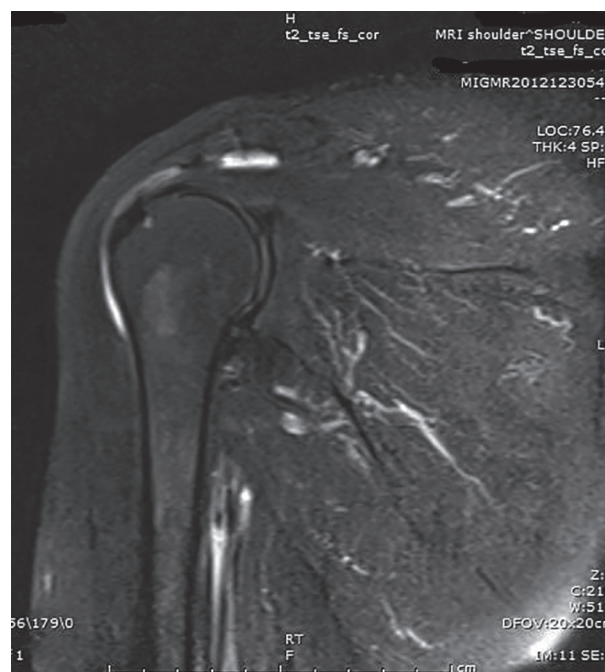

Fig. 2. — MR T2W TSE fat-sat coronal image of the right shoulder joint showing Partial -external surface- rotator cuff tear with a cyst in the greater tuberosity.

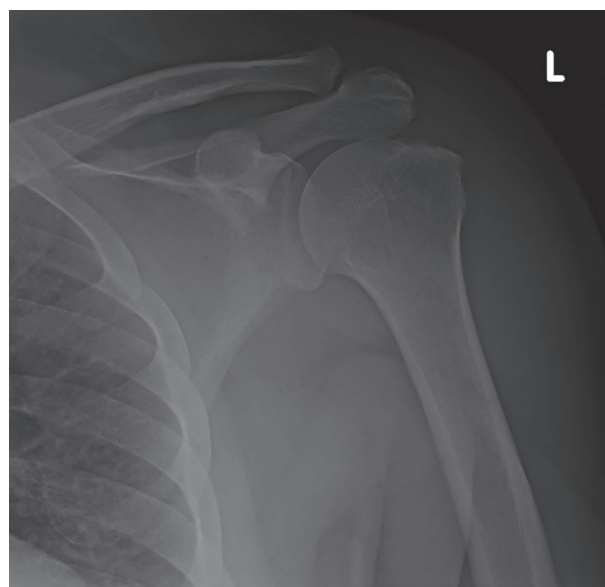


Fig. 3. — Plane X-ray of the left shoulder joint AP view showing greater tuberosity excavation (Irregularity).

Chronic cuff tear may be related to several radiographic findings : narrow acromio-humeral space, greater tuberosity cystic changes and reversed inferior acromial convexity.

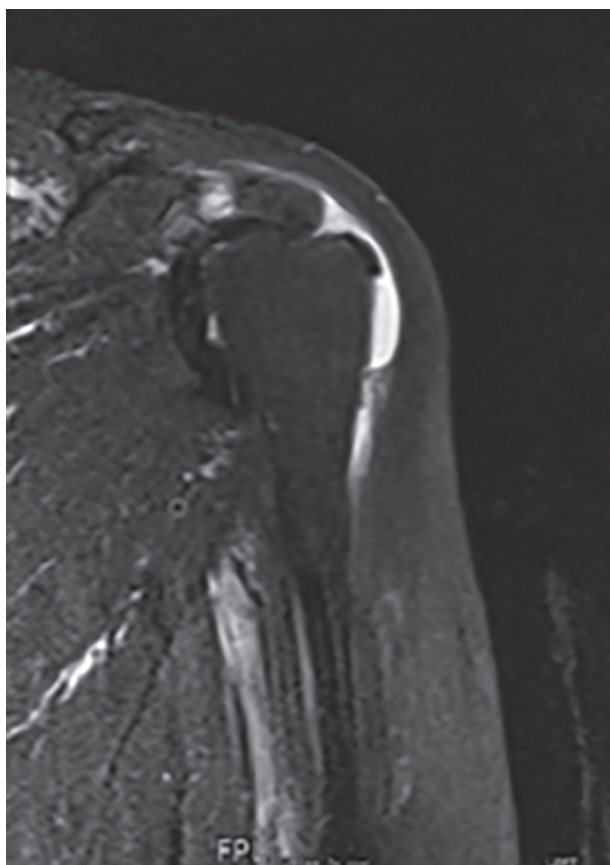


Fig. 4. — MR T2W TSE fat-sat coronal image of the left shoulder joint showing full thickness rotator cuff tears.

According to Wohlwend et al., when evaluating a shoulder, the greater tuberosity should be carefully examined ; if abnormal, the level of suspicion should be high while if normal, this had a high predictive value that the cuff was intact. (9)

Mack et al. (4) found bilateral affection in 6 % of their symptomatic patients.

In the current study, we found bilateral affection in 86 cases (21.6%).

Most literature studies were of a retrospective design, similar to the present study.

Plain radio-graphic findings were commonly associated with cuff 116 tears.

Cysts of the greater and lesser tuberosity were increasingly reported. In the study by Wissman et al., (8) lesser tuberosity cysts were associated with partial or complete subscapularis tear. Cyst location was related to the severity of pathology, with cysts

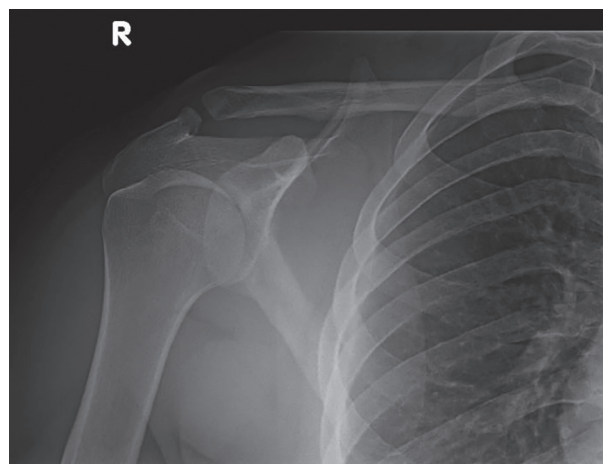


Fig. 5. — Plane X-ray of the right shoulder joint AP view showing greater tuberosity sclerosis.

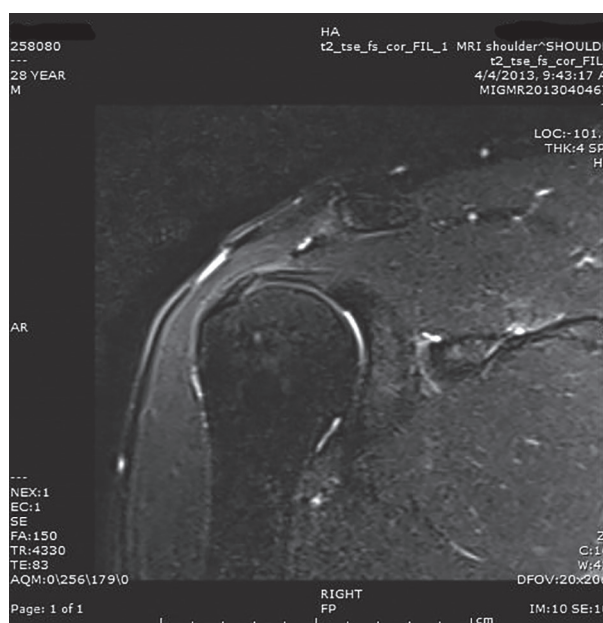


Fig. 6. — MR T2W TSE fat-sat coronal image of the right shoulder joint showing Partial – external surface – rotator cuff tear.

located in the tuberosity associated with more severe tendon tears. (8)

Abnormally decreased acromion-humeral distance was reported to be associated with cuff tear. Patients with rotator cuff disease also presented with osteopenic changes of the greater tuberosity. Injury to one or all of the cuff tendons may lead to disuse of the arm, which leads to osteopenia.

Greater osteopenic changes were seen with chronic and more severely retracted tendons. (1) Disuse had been hypothesized as the cause of osteopenia by Neer et al., (5) and Wolf's law could be used to explain this since bone remodels in response to stress. Cysts and sclerosis of the greater tuberosity were noted in patients with subacromial impingement.

In the current study, we showed a clear relation since 90% of the patient in the study was found to have both sclerosis on true AP shoulder radiographs, and M.R.I. evidence of cuff tear. We believed the explanation for sclerosis was bony abutment between the tuberosity and the under surface of the acromion.

However, we agreed with most authors that MRI still remains the gold standard for evaluation of Cuff tear and degree of retraction before surgery. (1)

Quintana et al. found that greater tuberosity changes and AHD change were found to have 78% Sensitivity and 98% specificity. (6)

In the present study, greater sclerosis alone was found to have 93.5% sensitivity and 67.5% specificity. Also, we noticed the combination of sclerosis and cyst increased the sensitivity for cuff pathology.

Huang LFI et al. (2) compared a group of normal population with a group of patients and found that cortical thickening and subcortical sclerosis were not seen more frequently in shoulders with rotator cuff disease than in normal shoulders ; however, their inter-observer agreement for the radio-graphic findings was poor to fair : Kappa values ranged from .06 to .41, which signifies the need for more comprehensive study regarding bony changes of the shoulder joint.

This study had some limitations. It was a retrospective study. Radio-graph analysis was done by two of the authors, yet inter-observer variability was not assessed.

CONCLUSION

Greater tuberosity sclerosis had both high sensitivity and positive predictive value for rotator cuff tear ; however, more in-depth evaluation with elimination of the before mentioned limitations of

the study is required to better understand the relation between greater tuberosity sclerosis and rotator cuff tear.

REFERENCES

1. **Cadet ER, Hsu JW, Levine WN, Bigliani LU, Ahmad CS.** The relationship between greater tuberosity osteopenia and the chronicity of rotator cuff tears. *J Shoulder Elbow Surg* 2008 ; 17 :73-77.
2. **Huang LFI, Rubin DA, Britton CA.** Greater tuberosity changes as revealed by radiography : lack of clinical usefulness in patients with rotator cuff disease. *Am J Roentgenol* 1999 ; 172 :1381-8.
3. **Knipe H, Jha P.** Rotator cuff tears. www.radiopaedic.org/articles/rotator-cuff-tears.
4. **Mack LA, Gannon MK, Kilcoyne RF, Matsen RA.** Sonographic evaluation of the rotator cuff. Accuracy in patients without prior surgery. *Clin Orthop Relat Res* 1988 ; 234 :21-27.
5. **Neer CS.** Anterior acromioplasty for the chronic impingement syndrome in the shoulder : a preliminary report. *J Bone Joint Surg Am* 1972 ; 54 : 41-50.
6. **Quintana EC, Kulkarni R, Sinert RH et al.** Rotator Cuff Injuries Workup. E-medicine : <http://emedicine.mHYPERLINK> "http://emedicine.medscape.com/article/827841-workup
7. **Wheeles CR.** X-ray findings in rotator cuff tears. *Wheeles Textbook of Orthopedics*. http://www.wheelesonline.com/ortho/x_ray_findings_in_rotator_cuff_tears_impingement_syndrome.
8. **Wissman RD, Kapur S, Akers J, Crimmins J, Ying J, Laor Tal.** Cysts within and adjacent to the lesser tuberosity and their association with rotator cuff abnormalities. *AJR* 2009 ; 193 : 1603-1606.
9. **Wohlwend JR, Holsbeeck M, Craig J et al.** The association between irregular greater tuberosities and rotator cuff tears : a sonographic study. *Am J Roentgenol* 1998 ; 171 : 229-33.