



Prevalence of Bilateral Involvement in Patients with Discoid Lateral Meniscus: a Systematic Literature Review

W.-X. LIU, J.-Z. ZHAO, X.-Q. HUANGFU, Y.-H. HE, X.-G. YANG

From the Department of Orthopedics, Shanghai Jiao Tong University Affiliated Sixth People's Hospital, Shanghai, 200233, China

We assessed the prevalence of bilateral discoid lateral meniscus (BDLM), as well as its subtypes, among patients with symptomatic DLM. Medline, Cochrane, EMBASE, and Google Scholar were searched until September 18, 2015. All studies evaluating patients with BDLM who underwent MRI, macroscopic observation, and/or arthroscopy for the diagnosis of discoid meniscus/menisci were included. Eight clinical studies with a total of 583 DLM patients examined including 103 cadavers. There was a male predominance and average age of BDLM patients ranged from 10.4 to 39.9 years. The reported prevalence was higher in East Asian countries (72.7 to 97%) than rest of the world (6.8 to 90%). Homotypes were much more common than heterotype, and ranged from 82.9 to 91.7% of all BDLM patients. The actual prevalence of BDLM is likely higher. The findings provide a glimpse of the wide spread this disorder potentially has in East Asia.

Key words : discoid meniscus ; discoid menisci ; bilateral discoid lateral menisci ; arthroscopy ; MRI or magnetic resonance imaging.

INTRODUCTION

Discoid meniscus, the most common anatomic variant of the meniscus of the knee, can change the biomechanics of the knee joint resulting in injury (5,23,29,32), and is often located on the lateral aspect of the knee, i.e., a discoid lateral meniscus (DLM).

The prevalence of DLM varies greatly depending on the population studied, with a reported prevalence ranging from 0.4 to 5% in Europe and 5.8 to 17% in Asia (9,17,27,28,31).

Although arthroscopy has long been considered the golden standard in the diagnosis of knee abnormalities, magnetic resonance imaging (MRI) is rapidly becoming a favored alternative due to its widespread availability and non-invasive nature (3,4,15). In addition to its use for examining symptomatic knees, MRI can also be used to assess DLM in the asymptomatic contralateral knee. Based on the MRI images, the diagnostic criteria for DLM include a tie-like configuration on more than three contiguous sagittal 5-mm-thick slices (due to a connection between anterior and posterior horns

-
- Wen-Xin Liu, M.D.
 - Jin-Zhong Zhao
 - Xiao-Qiao Huangfu
 - Yao-Hua He
 - Xing-Guang Yang

Department of Orthopedics, Shanghai Jiao Tong University Affiliated Sixth People's Hospital, Shanghai, 200233, China.

Correspondence : Jin-Zhong Zhao Department of Orthopedics, Shanghai Jiao Tong University Affiliated Sixth People's Hospital, Shanghai, 200233, China Tel.: +86-13917396491; Fax: +86-21-64701361

E-mail: jinzhong4@sogou.com

© 2017, Acta Orthopædica Belgica.

No benefits or funds were received in support of this study. The authors report no conflict of interests.

of the meniscus), and the presence of a meniscal body greater than 15 mm wide or extending into the intercondylar notch on coronal images with a ratio of meniscal body area to area of lateral tibial plateau greater than 50% (17,34). If a meniscus covers the entire lateral tibial plateau on coronal images, it is defined as a complete DLM; if the lateral tibial plateau is not completely covered, the DLM is considered incomplete (1,3).

According to the MRI classification method proposed by Ahn *et al.* (1), each lateral meniscus can be classified as one of three types: either normal (NM), incomplete discoid (ICDM), or complete discoid meniscus (CDM). Kaplan (19) and later Kato *et al.* (20) further described the absence of the posterior meniscal attachment, the Wrisberg-ligament type, and theorized that a normal-shaped hypermobile meniscus could become disk-shaped as a result of biomechanical factors. In 1998, a fourth type of DLM, a ring-shaped lateral meniscus, was described (26,40).

Watanabe *et al.* (37) described discoid meniscus as being either complete, incomplete, or of the Wrisberg type. This system combining elements of two previous classification schemes (i.e., Smillie (Smillie 1978) and Kaplan (19)) has become widely accepted.

Although a significant body of literature reported the prevalence of DLM in various populations, few studies reported the prevalence of bilateral DLM (BDLM) (2,13). This is primarily due to the high proportion of asymptomatic DLM patients who don't need treatment and would not have been assessed for bilateral involvement.

The purpose of this study was to perform a literature review to provide an estimation of prevalence of BDLM as well as its subtypes, in patients receiving treatment for symptomatic DLM.

METHODS

Medline, Cochrane, EMBASE, and Google Scholar were searched until September 18, 2015 using combinations of the keywords discoid meniscus, discoid menisci, bilateral discoid lateral menisci, arthroscopy, or MRI. Prospective or retrospective studies evaluating patients with BDLM

who underwent MRI, macroscopic observation, and/or arthroscopy for the diagnosis of discoid meniscus/menisci were included. Reference lists of relevant studies were also searched. Only English language publications were included. Letters, comments, editorials, comments, and case reports were excluded.

Studies were identified by two independent reviewers using the search strategy. Where there was uncertainty regarding eligibility, a third reviewer was consulted. The following data were extracted from studies that met the inclusion criteria: name of the first author, year of publication, study design, number of participants in each group, participants' age and gender, prevalence of DLM, DLM subtypes, bilateral DLM, and subtypes of bilateral DLM.

RESULTS

Literature Search

A flow diagram of study selection is shown in Figure 1. Of 35 records identified through the database searches, 11 were excluded after review of the title/abstract for not meeting the inclusion criteria. Twenty-four full text articles were then reviewed, and 16 were excluded for not reporting the prevalence of BDLM. Thus, 8 articles were included in this study (1,5,10,11,20,24,29).

Study characteristics

The characteristics of the studies are presented in Table 1. Of the studies, 8 clinical studies included a total of 583 patients including 103 cadavers. There was a male predominance, and the average age of the participants with BDLM ranged from 10.4 to 39.9 years.

Prevalence of BDLM and percentage of subtypes

The reported prevalence of BDLM in all studies ranged widely from 5.9 to 97%. The frequency of BDLM in East Asia (Japan (20), Korea (1,5), China (24)) ranged from 72.7 to 97%, and was higher than that of other countries (10,11,29,32) where it ranged from 5.9 to 90%.

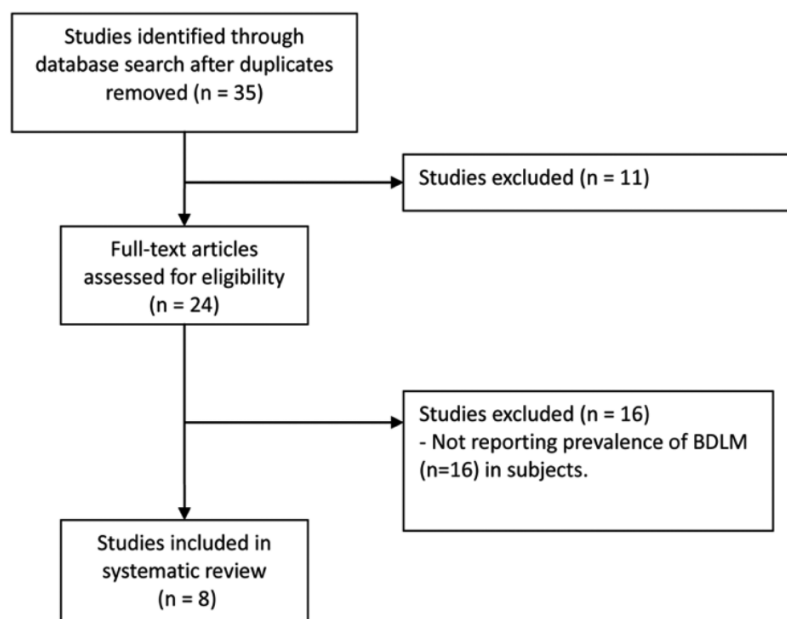


Fig. 1. — Study selection flow chart.

All BDLM prevalence data, except for that from cadaveric Japanese study by Kato *et al.* (20), were from patients with at least one symptomatic DLM came for treatment. The true prevalence of BDLM is likely higher as there is a population of patients with asymptomatic DLM who could not be assessed for bilateral involvement. Only the study by Kato *et al.* (20) examined the prevalence in cadavers taken from the general population.

Based on the four studies from East Asia which evaluated BDLM subtypes (1,5,20,24), the prevalence of homotype (i.e., either CDM/CDM or ICDM/ICDM) ranged from 82.9 to 91.7%, and the heterotype (CDM/ICDM) prevalence ranged only from 8.3 to 14.6%. Only one study evaluating BDLM reported a ring-shaped meniscus with and prevalence was 2.4% (3).

Prevalence of DLM subtypes

Six studies (1,5,20,24,29,32) evaluated DLM subtypes in all knees including CDM, ICDM, ring-shaped, and the Wrisberg variant. The prevalence of the CDM subtype of all knees ranged from 7.5 to 84.6%, and the prevalence of ICDM ranged

from 15.4 to 92.5%. Only one study (29) reported the Wrisberg subtype with a prevalence of 5.4%. Among BDLM knees, the prevalence of CDM subtypes ranged from 7.7 to 85.9%, and that of ICDM ranged from 14.1 to 92.3%.

But if cadaveric data from Kato *et al.* (20) were not used, and only symptomatic DLM knees were considered, the prevalence of CDM among symptomatic DLM patients would range from 43.0 to 84.6%, and that of ICDM would range from 15.4 to 51.6%. Among BDLM knees, the prevalence of CDM would range from 54.9 to 85.9%, and that of ICDM would range from 14.2 to 68.3%.

DISCUSSION

Based on the studies included in this review involving patients from Canada, Japan, India, the US, China, and Korea, the reported prevalence of BDLM ranged from 72.7 to 97% in East Asian countries, and from 5.9 to 90% in rest of the world, among patients seeking treatment for symptomatic DLM. In studies that reported BDLM subtypes, the frequency of patients with homotype (same type) BDLM ranged from 82.9 to 91.7%, and

Table 1. — Study characteristics

Author (publication year)	Nationality/ethnicity of patients	Study sample	Examination technique	Groups	Number of patients (% of all DLM)	Male (%)	Age, y [†]
Liu (2015)	Chinese Han	A total of 110 patients receiving arthroscopy for symptomatic DLM. Contralateral knee examined by MRI	Arthroscopy, MRI	BDLM UDLM	80 (72.7) 30 (27.3)	50 (45) *	21.9±12.8 *
Bae (2012)	Korean	Fifty-two patients receiving surgery for symptomatic DLM in one knee, and consented to have the contralateral knee examined	Arthroscopy	BDLM UDLM	41 (79) 11 (21)	31 (75.6) *	25.4±14.5*
Patel (2012)	US	Retrospective, medical records of 76 patients	MRI in all except 9 patients	BDLM UDLM	16 (21) 60 (79)	9 (56) 26 (43)	10.4 (2,14) 12.5 (3,18)
Ahn (2010)	Korean	Thirty-three soldiers receiving surgery for symptomatic DLM, MRI done on contralateral asymptomatic knees	Both radiography & MRI were used	BDLM	32 (97)	33 (100)	22.4 (19,35)
Rao (2007)	India	A total of 165 patients receiving surgery for painful DLM	Arthroscopy	BDLM	12 (7.2)	5 (41.7)	12.3 (5,12)
Kato (2004)	Japanese	Bilateral knees examined in 279 cadavers, 103 had DLM in at least one knee	Macroscopic observation	BDLM UDLM	84 (81.5) 19 (18.5)	53.2%*	77.15±11.25*
Davidson (2003)	Canadian	Thirty-four children treated for symptomatic DLM	MRI in 7 + radiography in 34 (squared-off appearance of the distal femur in 1 and increased joint space in 6)	BDLM UDLM UDMM	2 (5.9) 31 (91.1) 1 (2.9)	12 (35.3) *	11.3 (6.2,18.5) *
Connolly (1996)	Canadian	Twenty children, of which 10 received bilateral knee imaging	MRI + arthroscopy	BDLM UDLM	9 (90) 1 (10)	8 (40) *	9 (4.5, 16) *

Table 1. — Study characteristics

Bilateral DLM Subtypes, n (% of all BDLM)		DLM types in ALL knees, n (% of respective knees)			
Homotype C/C + IC/IC (%)	Heterotype C/IC or ring-shaped (%)	C	IC (or ring-shaped)	Wrisberg variant	MT
68 (61+7) (85%)	12 (15%)	134 (83.7) NA	26 (16.3) NA		
34 (19+15) (82.9%)	7 (6 + 1 ring-shaped) (17.1%)	45 (54.9) 7 (63.6)	37 (45.1) 4 (36.4)	0	
		21 (65.6) 18 (30)	7 (21.9) 41 (68.3)	4 (12.5) 1 (1.7)	23 (72) 54 (90)
29 (26 + 3) (90.6%)	3 (9.4%)	55 (85.9)	9 (14.1)		
		14 (58.3)	9 + 1 ring-shaped (41.7)		
77 (6+71) (91.7%)	7 (8.3%)	13 (7.7) 1 (5.3)	155 (92.3) 18 (94.7)		

C, complete, IC, incomplete, MT, meniscal tears, DLM, discoid lateral meniscus, BDLM, bilateral discoid lateral meniscus, MRI, magnetic resonance imaging, NA, not available, UDMM, unilateral discoid medial meniscus; UDLM, unilateral discoid lateral meniscus.

† Age was presented as mean ± standard deviation or median (range).

* These were combined data of all groups.

that of heterotype ranged 8.3 to 17.1%. However, as previously noted all BDLM prevalence data except for that from the cadaveric Japanese study by Kato *et al.* (20) are from patients with at least one symptomatic unilateral DLM; the true prevalence of BDLM is likely to be higher as there is likely a population of patients with BDLM that are asymptomatic. These data may encourage orthopedic surgeons to examine the contralateral knee for any evidence of a DLM when one has been diagnosed and help to advise patients with respect to physical activity and/or surgery in whom a DLM has been found.

Few studies have reported the frequency of BDLM, and there is wide variation in the few reported prevalences of BDLM from different parts of the world. Thus far, the reported prevalence of BDLM has been relatively low in Europe and other countries outside of Asia (between 2.2% and 20%) (2,6,16,29,30,36), and more prevalent in East Asia (between 72.7% (24) and 97% (1)). The study by Lu *et al.* (25) reported 57 Chinese patients with symptomatic DLM tears, five of which were bilateral meniscal tears, but they did not examine the possibility of asymptomatic contralateral DLM in those with unilateral DLM tears, so there was potential for underestimating the prevalence of BDLM and their data were not used.

In a study in India, Rao *et al.* (32) reported 177 DLM from 165 patients among 3,167 knee arthroscopies, and 12 were BDLM with a prevalence of 7.2%. Aichroth *et al.* (2) reported 10 (16.1%) BDLMs out of a total of 62 DLM cases in British children. Wasser *et al.* (36) reported two (11.1%) cases of BDLMs out of 18 cases of DLMs in French children in. In another French study, Bellier *et al.* (6) reported three BDLM in 16 children (prevalence, 18.8%; average age, 10.5 years). Pellaci *et al.* (30) reported an prevalence of BDLM in one (2.2%) out of 46 Italians. Hart *et al.* (16) reported BDLM in American children was present in approximately 10%-20% of patients.

On the other hand, an even higher prevalence of BDLM has been reported among patients from East Asia. In a recent Korean study, Chung *et al.* (8) reported that 89.5% of patients (34 of 38) had bilateral complete DLM and 84.2% had bilateralism

with an identical shape. Bae *et al.* (5) performed arthroscopy in asymptomatic contralateral knees in 52 Korean DLM patients who presented with symptomatic DLM and reported a frequency of BDLM of 79% (41 of 52 contralateral knees), and 82.9% of patients (34 pairs of knees) had the same DLM type. Ahn *et al.* (1) examined the contralateral knees of 33 Korean male soldiers receiving single-knee DLM surgery during the period from 2006 to 2008 and found that BDLM were present in 97% of the patients.

A study by Kato *et al.* (20) which evaluated both knees of 103 Japanese cadavers and found 84 (81.5%) had BDLM, of which 77 (91.7%) were of the same morphology. Our finding was similar to the report by Chung *et al.* (8) among East-Asian patients.

The reported prevalence of unilateral DLM among all patients with knee problems is also lower in Europe (1.5% to 5.8%) (12,31,35) than in East Asia (14% to 16.6%) (17,21). Smillie *et al.* (35), after completing 10,000 cases of meniscectomy, reported 467(4.6%) cases of DLM. Dickason *et al.* (12) evaluated 14,731 menisci and found 102 (1.5%) DLM in 6,691 lateral menisci. In a study done in India, 95(5.8%) of 1643 knees were diagnosed with DLM (31). On the other hand, Kim *et al.* (21) reported that between 1990 and 1992, 77 (14%) of 534 arthroscopy cases were found to have DLM. Over a 20-year period in Japan, Ikeuchi (17) noted that a prevalence of 16.6% DLM on arthroscopic examination. Studies of the DLM in asymptomatic subjects are even fewer. To determine the prevalence of asymptomatic DLM in the general population, Fukuta *et al.* (14) examined 115 Japanese asymptomatic volunteers (13 to 76 years of age) using MRI and reported a 13% frequency of DLM and the frequency was similar regardless of age group.

Based on at least one study (10), children with symptomatic DLM are more likely to have a DLM in the contralateral knee. The average ages of BDLM patients among our other included studies were also quite young. The study by Connolly *et al.* (10) examined both knees of 10 children and found 9 of them with BDLM, which was much higher than other studies conducted outside East Asia. The

ethnicities of these children were not disclosed, however.

When MRI was compared to arthroscopy for diagnosing DLM, there is a good specificity but a somewhat lower sensitivity. Some disagreement persists in this area, as Yoo *et al.* (39) reported that preoperative MRI could not accurately predict a DLM tear in children, except in those showing grade 3 signal changes. Bouju *et al.* (7) reported that the MRI sensitivity was 70% and 64%, and specificity was 80% and 90% for the first and second readings, respectively, for diagnosing DML in children. Yilgor *et al.* (38) reported MRI to be 100% specific and 97.8% sensitive for determining the presence or absence of a discoid meniscal tear, with a negative predictive value of 85.7% and a positive predictive value of 100%. But Yilgor's study was retrospective and all patients with MRI images had symptomatic discoid meniscal tears, and they also noted that it could not accurately detect tear subtypes. Kocher *et al.* (22) reported a MRI sensitivity and specificity to be 72% and 93%, respectively, for diagnosing intra-articular knee disorders including discoid menisci in children and adolescents. In a prospective study, Ryu *et al.* (33) reported that MRI had a positive predictive value of 92% for discoid meniscus, and 57% for discoid meniscal tear in a population comprised of adults and children. There is yet no clear evidence on how good MRI is or whether it alone is sufficient in identifying the Wrisberg variant of DLM (18,41).

There are a number of limitations to the study, with the major one being the very small number of studies examining BDLM in the literature, and there were even fewer studies that reported subtype data (i.e., homotype or heterotype). Heterogeneity was noted among studies with respect to examination technique, i.e., MRI, arthroscopy, and direct observation (in the one cadaveric study) which makes the study comparison difficult. One unavoidable limitation of most included studies is selection bias, since only individuals with knee symptoms serious enough to impair daily function would seek treatment and to be assessed for BDLM. Only the Japanese cadaveric study collected study samples from the population (20). The true prevalence of BLDM among all DLM patients is

likely higher than those reported. Furthermore, the lower sensitivity and specificity of MRI compared to arthroscopy, using MRI as the sole diagnostic procedure would also underestimate the prevalence.

In conclusion, the reported prevalence of BDLM among symptomatic DLM patients in East Asian countries was higher than that reported by rest of the world. Homotype BDLM also appears much more common than heterotype. Certainly more and larger epidemiological studies are needed to consolidate these findings. But they provide a glimpse of the wide spread this disorder potentially has.

REFERENCES

1. Ahn J H, Lee S H, Yoo J C, Lee H J, Lee J S. Bilateral discoid lateral meniscus in knees: evaluation of the contralateral knee in patients with symptomatic discoid lateral meniscus. *Arthroscopy* 2010 ; 26 : 1348-56.
2. Aichroth P M, Patel D V, Marx C L. Congenital discoid lateral meniscus in children. A follow-up study and evolution of management. *Bone Joint J* 1991 ; 73 : 932-6.
3. Araki Y, Ashikaga R, Fujii K, Ishida O, Hamada M, Ueda J, et al. MR imaging of meniscal tears with discoid lateral meniscus. *Eur J Radiol* 1998 ; 27 : 153-60.
4. Auge W K, 2nd, Kaeding C C. Bilateral discoid medial menisci with extensive intrasubstance cleavage tears: MRI and arthroscopic correlation. *Arthroscopy* 1994 ; 10 : 313-8.
5. Bae J H, Lim H C, Hwang D H, Song J K, Byun J S, Nha K W. Incidence of bilateral discoid lateral meniscus in an Asian population: an arthroscopic assessment of contralateral knees. *Arthroscopy* 2012 ; 28 : 936-41.
6. Bellier G, Dupont J Y, Larrain M, Caudron C, Carlizo H. Lateral discoid menisci in children. *Arthroscopy* 1989 ; 5 : 52-6.
7. Bouju Y, Carpentier E, Bergerault F, De Courtivron B, Bonnard C, Garaud P. The concordance of MRI and arthroscopy in traumatic meniscal lesions in children. *OTSR* 2011 ; 97 : 712-8.
8. Chung J Y, Roh J H, Kim J H, Kim J J, Min B H. Bilateral occurrence and morphologic analysis of complete discoid lateral meniscus. *Yonsei med J* 2015 ; 56 : 753-9.
9. Clark C R, Ogden J A. Development of the menisci of the human knee joint. Morphological changes and their potential role in childhood meniscal injury. *Bone Joint J* 1983 ; 65 : 538-47.
10. Connolly B, Babyn P S, Wright J G, Thorner P S. Discoid meniscus in children: magnetic resonance imaging characteristics. *Can Assoc Radiol J* 1996 ; 47 : 347-54.
11. Davidson D, Letts M, Glasgow R. Discoid meniscus in children: treatment and outcome. *CJS* 2003 ; 46 : 350-8.

12. Dickason J M, Del Pizzo W, Blazina M E, Fox J M, Friedman M J, Snyder S J. A series of ten discoid medial menisci. *Clin Orthop Relat Res* 1982 ; 168: 75-9.
13. Dickhaut S C, DeLee J C. The discoid lateral-meniscus syndrome. *Bone Joint J* 1982 ; 64 : 1068-73.
14. Fukuta S, Masaki K, Korai F. Prevalence of abnormal findings in magnetic resonance images of asymptomatic knees. *J Orthop science* 2002 ; 7 : 287-91.
15. Hamada M, Shino K, Kawano K, Araki Y, Matsui Y, Doi T. Usefulness of magnetic resonance imaging for detecting intrasubstance tear and/or degeneration of lateral discoid meniscus. *Arthroscopy* 1994 ; 10 : 645-53.
16. Hart E S, Kalra K P, Grottkau B E, Albright M, Shannon E G. Discoid lateral meniscus in children. *Orthopedic nursing* 2008 ; 27 : 174-9; quiz 80-1.
17. Ikeuchi H. Arthroscopic treatment of the discoid lateral meniscus. Technique and long-term results. *Clin Orthop Relat Res* 1982 ; 167: 19-28.
18. Jose J, Buller L T, Rivera S, Carvajal Alba J A, Baraga M. Wrisberg-variant discoid lateral meniscus: current concepts, treatment options, and imaging features with emphasis on dynamic ultrasonography. *Am J Orthopedics* 2015 ; 44 : 135-9.
19. Kaplan E B. Discoid lateral meniscus of the knee joint; nature, mechanism, and operative treatment. *The J Bone Joint Surg (Am)* 1957 ; 39-A: 77-87.
20. Kato Y, Oshida M, Aizawa S, Saito A, Ryu J. Discoid lateral menisci in Japanese cadaver knees. *Modern rheumatology / the Japan Rheumatism Association* 2004 ; 14 : 154-9.
21. Kim S J, Lee Y T, Kim D W. Intraarticular anatomic variants associated with discoid meniscus in Koreans. *Clin Orthop Relat Res* 1998 ; : 202-7.
22. Kocher M S, DiCanzio J, Zurakowski D, Micheli L J. Diagnostic performance of clinical examination and selective magnetic resonance imaging in the evaluation of intraarticular knee disorders in children and adolescents. *Am J Sports Med* 2001 ; 29 : 292-6.
23. Kocher M S, Klingele K, Rassman S O. Meniscal disorders: normal, discoid, and cysts. *The Orthopedic clinics of North America* 2003 ; 34 : 329-40.
24. Liu W X, Zhao J Z, Huangfu X Q, He Y H, Yang X G. Prevalence of bilateral Discoid Lateral Menisci (DLM) in patients operated for symptomatic DLM with a follow-up study on their asymptomatic contralateral knees: a Magnetic Resonance Imaging (MRI) assessment. *BMC musculoskeletal disorders* 2015 ; 16: 172.
25. Lu Y, Li Q, Hao J. Torn discoid lateral meniscus treated with arthroscopic meniscectomy: observations in 62 knees. *Chin Med J* 2007 ; 120 : 211-5.
26. Monllau J C, Leon A, Cugat R, Ballester J. Ring-shaped lateral meniscus. *Arthroscopy* 1998 ; 14 : 502-4.
27. Nathan P A, Cole S C. Discoid meniscus. A clinical and pathologic study. *Clin Orthop Relat Res* 1969 ; 64: 107-13.
28. Papadopoulos A, Karathanasis A, Kirkos J M, Kapetanos G A. Epidemiologic, clinical and arthroscopic study of the discoid meniscus variant in Greek population. *Knee Surg Sports Traumatol Arthrosc* 2009 ; 17 : 600-6.
29. Patel N M, Cody S R, Ganley T J. Symptomatic bilateral discoid menisci in children: a comparison with unilaterally symptomatic patients. *J Pediatr Orthop B* 2012 ; 32 : 5-8.
30. Pellacci F, Montanari G, Prosperi P, Galli G, Celli V. Lateral discoid meniscus: treatment and results. *Arthroscopy* 1992 ; 8 : 526-30.
31. Rao P S, Rao S K, Paul R. Clinical, radiologic, and arthroscopic assessment of discoid lateral meniscus. *Arthroscopy* 2001 ; 17 : 275-7.
32. Rao S K, Sripathi Rao P. Clinical, radiologic and arthroscopic assessment and treatment of bilateral discoid lateral meniscus. *Knee Surg Sports Traumatol Arthrosc* 2007 ; 15 : 597-601.
33. Ryu K N, Kim I S, Kim E J, Ahn J W, Bae D K, Sartoris D J, et al. MR imaging of tears of discoid lateral menisci. *AJR* 1998 ; 171 : 963-7.
34. Samoto N, Kozuma M, Tokuhisa T, Kobayashi K. Diagnosis of discoid lateral meniscus of the knee on MR imaging. *Magnetic resonance imaging* 2002 ; 20 : 59-64.
35. Smillie I. Injuries of the knee joint. New York: Churchill Livingstone 1978.
36. Wasser L, Knorr J, Accadbled F, Abid A, Sales De Gauzy J. Arthroscopic treatment of discoid meniscus in children: clinical and MRI results. *OTSR* 2011 ; 97 : 297-303.
37. Watanabe M, Takeda S, Ikeuchi H. Atlas of arthroscopy. 3rd edition. Tokyo: *Igakushoin* 1979.
38. Yilgor C, Atay O A, Ergen B, Doral M N. Comparison of magnetic resonance imaging findings with arthroscopic findings in discoid meniscus. *Knee Surg Sports Traumatol Arthrosc* 2014 ; 22 : 268-73.
39. Yoo W J, Lee K, Moon H J, Shin C H, Cho T J, Choi I H, et al. Meniscal morphologic changes on magnetic resonance imaging are associated with symptomatic discoid lateral meniscal tear in children. *Arthroscopy* 2012 ; 28 : 330-6.
40. Youm T, Chen A L. Discoid lateral meniscus: evaluation and treatment. *Am J. Orthop* 2004 ; 33 : 234-8.
41. Yue B W, Gupta A K, Moorman C T, 3rd, Garrett W E, Helms C A. Wrisberg variant of the discoid lateral meniscus with flipped meniscal fragments simulating bucket-handle tear: MRI and arthroscopic correlation. *Skeletal radiology* 2011 ; 40 : 1089-94.