



Reversed shoulder arthroplasty as treatment for late or ancient chronic glenohumeral dislocation

Alexander VAN TONGEL, Thomas CLAESSENS, Bram VERHOFSTE, Lieven DE WILDE

From the University Hospital Ghent, Ghent, Belgium

Chronic glenohumeral dislocation is a rare entity and several treatment options have been proposed. The aim of this study is to report the long-term follow-up of the reversed shoulder arthroplasty in patients with chronic glenohumeral dislocation.

A retrospective analysis of all patients between January 2002 and December 2012 that were treated with a reversed shoulder arthroplasty for chronic anterior glenohumeral dislocations was performed. Pre-operative CT evaluation of the bone loss and fatty degeneration of the rotator cuff muscles was performed. Pre- and postoperative Constant-Murley score was evaluated.

6 patients (4 males and 2 females) with anterior glenohumeral dislocations were evaluated. Average age was 73 years (between 65-86 years). The average time of dislocation was 18 weeks (between 4 and 52 weeks). Average time of follow-up was 39 months (between 12 and 90 months).

The CM improved from 33 (between 17 and 45) pre-op to 76 postop (between 55 and 89). No postoperative complications were observed.

Reversed shoulder arthroplasty gives good results in case of chronic glenohumeral dislocation.

Keywords: Chronic anterior shoulder dislocation; reversed arthroplasty.

INTRODUCTION

A chronic dislocation of the shoulder is defined when the diagnosis is delayed by more than

3 weeks (1,14). The dislocation can be anterior or posterior. The diagnosis and management is challenging because these dislocations usually occur in debilitated patients (2). Those patients often have poor bone quality and a decreased rehabilitation potential (2,11). The outcome of treatment is influenced by the delay of (the recognition of the condition) diagnosis and the implementation of appropriate surgical technique. An open reduction is almost always necessary to restore the glenohumeral relationship (1,2,9,11,12). Open reduction, after resection of the intra-articular fibrotic tissue, is a reliable treatment with a good postoperative function when only minor structural lesions such as labral tears are present (1). Postoperatively the glenohumeral joint needs to be temporarily immobilized with trans-articular K-wires to maintain and restore a centered glenohumeral joint (1,6). Associated fractures and

-
- Alexander Van Tongel, MD PhD.
 - Thomas Claessens (medical student).
 - Bram Verhofste (medical student).
 - Lieven De Wilde, MD, PhD.

Department of Orthopaedic Surgery and Traumatology, Ghent University Hospital, De Pintelaan 185, 9000 Gent, Belgium.

Correspondence: Alexander Van Tongel, Department of Orthopaedic Surgery and Traumatology, Ghent University Hospital, De Pintelaan 185, 9000 Gent, Belgium.

E-mail: Alexander.vantongel@uzgent.be

© 2016, Acta Orthopædica Belgica.

No benefits or funds were received in support of this study. The authors report no conflict of interests.

Acta Orthopædica Belgica, Vol. 82 - 3 - 2016

neurovascular lesions, which are frequently seen (14), reduce the effectiveness of this treatments with unpredictable clinical results (15,16). The aim of this study is to evaluate the long-term follow-up of the use of a reversed shoulder arthroplasty in patients with a chronic anterior glenohumeral dislocation. A permission of the ethical committee was obtained (B670201420560).

MATERIALS AND METHODS

Methods : All patients between January 2006 and December 2012 that were treated with a reversed shoulder arthroplasty for anterior glenohumeral dislocations, that lasted for a minimum of 3 weeks, were retrospectively evaluated.

All patients were clinically evaluated pre- and postoperatively at three months and one year and at latest follow-up with the Constant-Murley score. All patients had a pre-operative CT-scan. The scapula and the humeral head were 3D reconstructed and the glenoid bone loss was measured using the technique described by Provencher *et al* (13). The presence or absence of peri-articular ossification was evaluated. The rotator cuff muscles were quantified using the Goutallier classification (7). Radiographic analysis evaluating scapular notching (17), humeral loosening (18) and new peri-articular ossification was performed the first day postoperatively, at three months, at one year and at latest follow-up.

Surgical technique

All patients were installed in the beach chair position under general anesthesia. The deltopectoral approach was used. The 4 tendons of the rotator cuff were checked for a full-thickness tendon tear. No attempt was made to forcefully reduce the joint, but instead we consistently identified the rotator cuff interval by following the biceps tendon proximally. The rotator cuff interval was opened and a tenodesis of the long head was established at the pectoralis major tendon. Next the intra-articular part of the long head was resected and a tenotomy of the subscapularis at the tendino-osseous transition was performed and the arm was progressively brought in external rotation. If intra-articular fibrosis hindered this external rotational movement further humeral sided releases were performed. If the reduction was unobtainable with this maneuver, gentle lateral traction using a hook was exerted on the humeral head to obtain a normal glenohumeral relationship. Resection of the whole supra-

spinatus tendon also significantly eased the reduction of the humeral head. Once the humeral head was freed, the endomedullary canal was reamed starting from the top. Osteotomy of the humeral head was then made (according to the manufacturer's advice of) in 10 degrees of retroversion with the inclination guide of 155°. The shoulder was reconstructed with a one Delta 3.1 and five Delta Xtend™ [DePuy International Ltd]. Exposure of the posterior capsule was largely improved after removing the osteomized humeral head and this capsule was always completely released. This release was then extended completely around the rim of the glenoid. Special care was taken to release the inferior part of the glenoid, in casu, the long head of the triceps tendon. Doing so, the inferior bony rim of the glenoid and the lateral pillar of the scapulae could be identified. This allows positioning of the glenoid baseplate distally in an attempt to minimize scapular notching. The glenoid plane was then reamed until the subchondral bone was reached without removing it. If an anterior glenoid defect was present care was taken not to weaken or to deepen this defect. A bone graft, harvested from the resected humeral head, was only necessary if the glenoid fracture extends more than one third of the inferior circular glenoid plane. On the other hand, if a 'step like neo-glenoid' was formed, no attempt was made to remove this extra bone formation. It is advised to ream, or to reconstruct if necessary, the glenoid plane perpendicular to the scapular plane to minimize the rocking horse phenomenon. The superior tubercle of the glenoid was nibbled or reamed with the appropriated reamer. Once the glenoid plane was smoothly reamed, the central hole of the base plate is drilled guided by the K-wire. Next the central plot of the baseplate was introduced and firmly tapered onto the glenoid. This fixation was optimized with two to four angulated stable screws. Afterwards the glenosphere (always size 42 mm – to ensure as much stability as possible) was assembled to the baseplate by hammering several times in an effort to prevent an impaction default of the Morse taper. At the humeral side, reaming of the proximal humerus was done with the appropriate reamers to prepare either an uncemented or cemented humeral prosthesis. The thickness of the polyethylene inlay was determined by means of a trial reduction. The shoulder was peroperatively tested for stability and passive range of motion. If necessary, the length was adapted to increase stability or a tuberoplasty was performed to prevent subacromial or subcoracoidal impingement.

Finally, the joint was thoroughly rinsed and closure of the wound is done around a suction drain without an attempt to reinsert the subscapularis tendon.

Table I. — Pre- and peroperative demographics

	age	side	Bone defect	Peri-articular ossification	Pre-op Goutallier classification				Peroperative evaluation rotator cuff			
					subscap	supra	infra	teres minor	subscap	supra	infra	teres minor
1	81	right	9%	yes	1	1	1	0	no tear	no tear	no tear	no tear
2	69	right	0%	yes	1	1	1	0	no tear	full tickness tear	no tear	no tear
3	76	right	90%	no	1	2	2	1	full tickness tear	full tickness tear	full tickness tear	full tickness tear
4	61	left	25%	no	0	0	0	0	no tear	no tear	no tear	no tear
5	86	right	0%	no	1	1	1	1	no tear	no tear	no tear	no tear
6	65	right	12%	no	1	1	2	1	no tear	full tickness tear	no tear	no tear

Starting the day after, the postoperative regime always consisted of aggressive active rehabilitation in the functional range of movement. Strengthening of the shoulder muscles was started in the pain free range of movement. All patients were stimulated to utilize the arm as soon and as much as possible during activities of daily living.

RESULTS

6 patients (4 males and 2 females) were evaluated and the diagnosis of chronic anterior dislocation was made in all patients. The average age was 73 years (between 61 and 86). The average time from dislocation to surgical treatment was 18 weeks (between 4 and 52 weeks). Average time of follow-up was 39 months (between 12 and 90 months).

Pre-operatively 1 patient had severe bone loss, 3 patients had mild bone loss and 2 patients had an intact glenoid (Table I) (Fig. 1-2). An allograft was used in the patient with severe bone loss. 2 patients showed signs of peri-articular ossification (Fig. 3). This was not resected during surgery. Pre-operative, no patients showed signs of fatty degeneration grade 3 or 4 (Table I).

Peroperatively one patient with severe bone loss had a massive cuff tear. Three patients had a degenerative full-tickness tear of the supraspinatus tendon.

The CM improved from 33 (between 17 and 45) preoperatively to 76 (between 55 and 89) postoperatively (Table II). No early or late complications were observed.

Postoperative radiographs at latest follow-up showed no sign of scapular notching, humeral or glenoid loosening or heterotopic ossification.

DISCUSSION

The definition of a chronic dislocation of the shoulder is variable and also varies according to the literature but a minimum of 3 weeks is generally accepted (6,14,16). In this series the duration of the shoulder dislocation had a mean of 18 weeks (between 4 and 52 weeks) but this did not influence the functional outcome of our treatment.

Satisfactory outcomes in patients with chronic anterior dislocation can be achieved by many therapeutic options, be it surgically (1) or conservatively (8,20).

Recently reversed shoulder arthroplasty has been proposed as a treatment option (9,12,20) but no follow-up studies have been described to our knowledge.

Macaulay *et al* described two cases of ancient chronic anterior glenohumeral dislocation treated

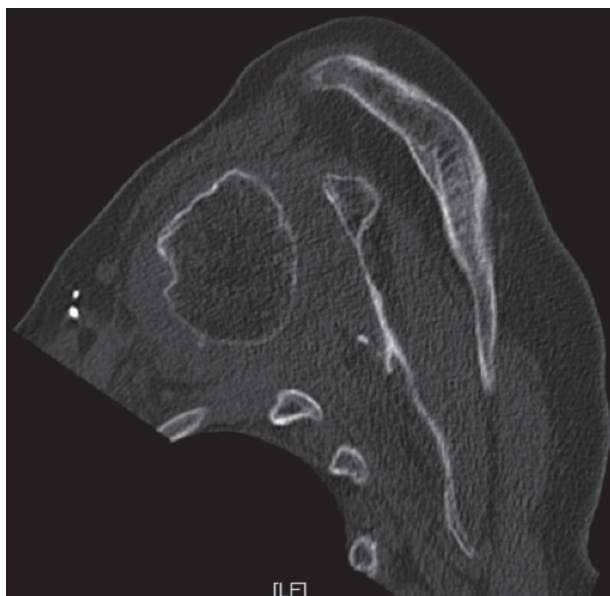


Fig. 1a. — Axial CT image chronic dislocation and large glenoid bone defect.

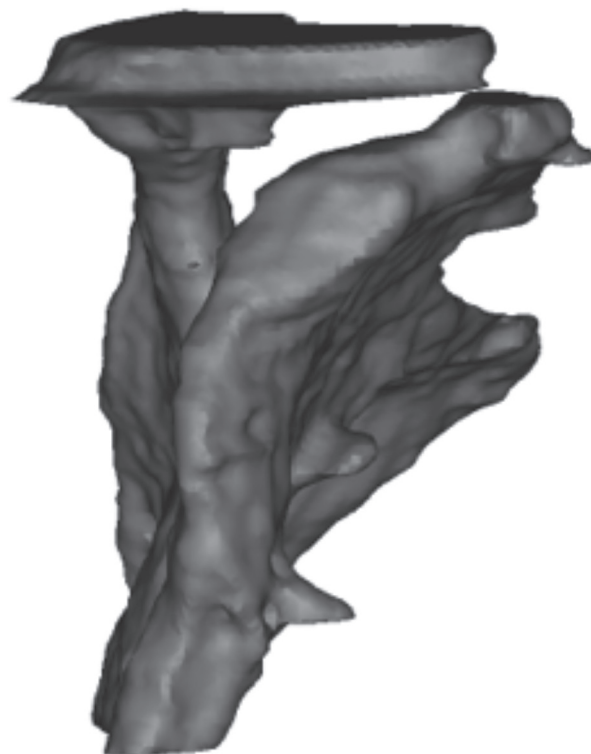


Fig. 1b. — 3D reconstruction of scapula with large glenoid bone defect.

with reversed shoulder arthroplasty with good clinical results one year postoperatively (12).

Verhaegen *et al* described a case of a late anterior dislocation (20). Postoperative rehabilitation was uneventful and the patient achieved good function of her upper limb without pain but experienced weakness during rotational movements. Hyun *et al* described this treatment option that was used in 5 patients with chronic anterior dislocation. Although they were not formally studied, their motion and pain showed improvement and all but 1 were satisfied with the result (9).

In our experience treatment of chronic anterior dislocated shoulders with a reverse total shoulder arthroplasty yields good predictable functional results. In case of important bony defect of the glenoid, we suggest the use of the humeral head as an autograft. This autograft can be fixed using a step off technique in an effort to increase the primary stability of the baseplate and the graft (10).

Table II. — Postoperative demographics

	follow-up (months)	pre-op CS	postop CS 3m	postop CS 1 year	postop CS latest follow-up	X-ray		
						scapular notching	humeral loosening	new heteretopic classification
1	90	45	75	80	86	grade 0	—	—
2	34	17	39	53	56	grade 0	—	—
3	42	33	26	50	55	grade 0	—	—
4	25	47	60	70	90	grade 0	—	—
5	29	25	69	79	79	grade 0	—	—
6	12	33	89	88	88	grade 0	—	—

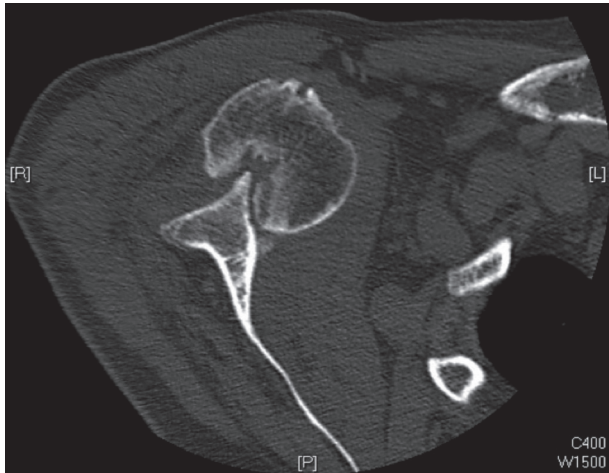


Fig. 2a. — Axial CT image of chronic dislocation with no glenoid bone defect.

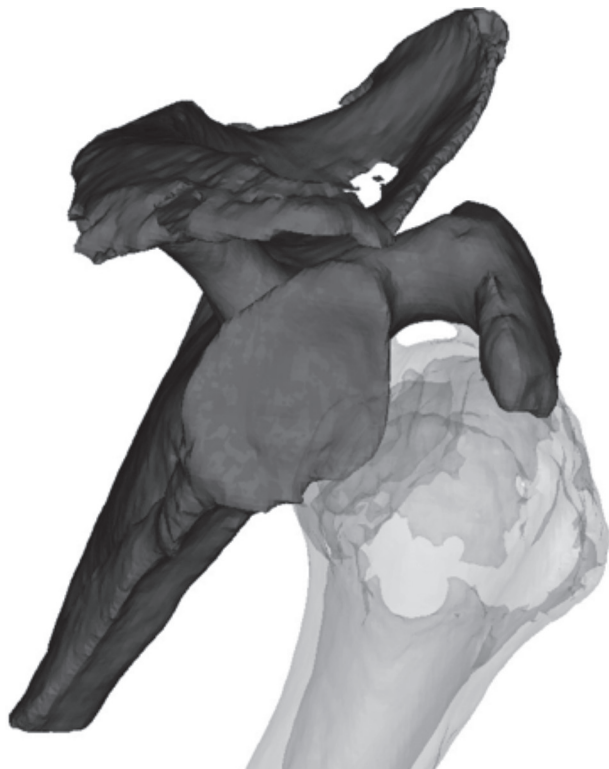


Fig. 2b. — 3D reconstruction of scapula with no glenoid bone defect.

In this series we only had to use a bone graft once and experienced no problems. At that time, no long central peg was available but we strongly advise to use a long peg base plate if the bony defect is impor-

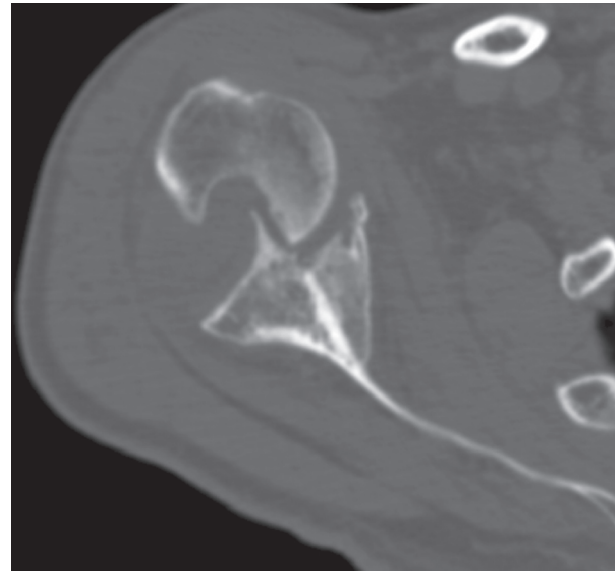


Fig. 3. — Axial CT image of chronic dislocation and peri-articular ossification.

tant. This central peg should perforate the native glenoid cortex to increase the primary stability and care should be taken to position this long peg in line with the scapular plane to overcome a rocking horse phenomenon at the glenosphere.

Predictable results can be obtained similar to the literature of the reverse prosthesis in trauma of the proximal humerus. We were consistently able to start an active and aggressive rehabilitation in all patients from the first postoperative day onward.

In our opinion the only preoperative examination necessary is a CT-scan. This examination allows for an accurate assesment of the bony deficit at the glenoid and the muscular status of the rotator cuff. We believe that this type of treatment is not indicated if an axillary nerve lesion is clinically present. It needs to be mentioned that this nerve pathology is the most frequent associated lesion of an anterior shoulder dislocation (3). But an axillary nerve lesion after a shoulder dislocation is mainly an axonotmesis and generally heals uneventfully with time. The diagnosis of a dysfunctional deltoid is a clinical one which can be easily performed by the orthopaedic surgeon (5).

Despite the success of this treatment, one must be cautious for the possible complications of the reverse total shoulder prosthesis.

CONCLUSION

To conclude, this small series of chronic dislocations, a rather rare pathology, indicates that good predictable functional results can be obtained with a reverse total shoulder arthroplasty without adverse effects. A careful preoperative CT planning and surgical technique seems of important to achieve good functional results at the longer term.

REFERENCES

1. Akinci O, Kayali C, Akalin Y. Open reduction of old unreduced anterior shoulder dislocations : a case series including 10 patients. *European Journal of Orthopaedic Surgery & Traumatology* 2010 ; 20 : 123-129.
2. Bezer M, Guven O, Karahan M. [Chronic dislocations of the shoulder]. *Acta Orthop Traumatol Turc* 2005 ; 39 Suppl 1 : 90-95.
3. De Laat E, Visser C, Coene L, Pahlplatz P, Tavy D. Nerve lesions in primary shoulder dislocations and humeral neck fractures. A prospective clinical and EMG study. *Journal of Bone & Joint Surgery, British Volume* 1994 ; 76 : 381-383.
4. De Wilde LF, Poncet D, Middernacht B, Ekelund A. Prosthetic overhang is the most effective way to prevent scapular conflict in a reverse total shoulder prosthesis. *Acta Orthop* 2010 ; 81 : 719-726.
5. Fujihara Y, Doi K, Dodakundi C, Hattori Y, Sakamoto S, Takagi T. Simple clinical test to detect deltoid muscle dysfunction causing weakness of abduction – “akimbo” test. *J Reconstr Microsurg* 2012 ; 28 : 375-379.
6. Goga I. Chronic shoulder dislocations. *Journal of shoulder and elbow surgery* 2003 ; 12 : 446-450.
7. Goutallier D, Postel J-M, Bernageau J, Lavau L, Voisin M-C. Fatty muscle degeneration in cuff ruptures : pre-and postoperative evaluation by CT scan. *Clinical Orthopaedics and Related Research* 1994 ; 304 : 78-83.
8. Hejna W, Fossier C, Goldstein TB, Ray R. Ancient anterior dislocations of the shoulder. *J Bone Joint Surg [Am]* 1969 ; 51 : 1030-1031.
9. Hyun YS, Huri G, Garbis NG, McFarland EG. Uncommon Indications for Reverse Total Shoulder Arthroplasty. *Clinics in Orthopedic Surgery* 2013 ; 5 : 243-255.
10. Iannotti JP, Lappin KE, Klotz CL, Reber EW, Swope SW. Liftoff resistance of augmented glenoid components during cyclic fatigue loading in the posterior-superior direction. *J Shoulder Elbow Surg* 2013 ; 22 : 1530-1536.
11. Loebenberg MI, Cuomo F. The treatment of chronic anterior and posterior dislocations of the glenohumeral joint and associated articular surface defects. *Orthop Clin North Am* 2000 ; 31 : 23-34.
12. Macaulay AA, Greiwe RM, Levine WN. Reverse Total Shoulder Replacement in Patients with Severe Glenoid Bone Loss. *Operative Techniques in Orthopaedics* 2011 ; 21 : 86-93.
13. Provencher MT, Bhatia S, Ghodadra NS, Grumet RC, Bach BR Jr, Dewing CB, LeClere L, Romeo AA. Recurrent shoulder instability : current concepts for evaluation and management of glenoid bone loss. *J Bone Joint Surg Am* 2010 ; 92 Suppl 2 : 133-151.
14. Rowe CR, Zarins B. Chronic unreduced dislocations of the shoulder. *J Bone Joint Surg Am* 1982 ; 64 : 494-505.
15. Sahajpal DT, Zuckerman JD. Chronic glenohumeral dislocation. *Journal of the American Academy of Orthopaedic Surgeons* 2008 ; 16 : 385-398.
16. Schulz TJ, Jacobs B, Patterson RL Jr. Unrecognized dislocations of the shoulder. *J Trauma* 1969 ; 9 : 1009-1023.
17. Sirveaux F, Favard L, Oudet D, Huquet D, Walch G, Mole D. Grammont inverted total shoulder arthroplasty in the treatment of glenohumeral osteoarthritis with massive rupture of the cuff. Results of a multicentre study of 80 shoulders. *J Bone Joint Surg Br* 2004 ; 86 : 388-395.
18. Sperling JW, Cofield RH, O'Driscoll SW, Torchia ME, Rowland CM. Radiographic assessment of ingrowth total shoulder arthroplasty. *Journal of shoulder and elbow surgery* 2000 ; 9 : 507-513.
19. Van Hoof T, Gomes GT, Audenaert E, Verstraete K, Kerckaert I, D'Herde K. 3D computerized model for measuring strain and displacement of the brachial plexus following placement of reverse shoulder prosthesis. *Anat Rec (Hoboken)* 2008 ; 291 : 1173-1185.
20. Verhaegen F, Smets I, Bosquet M, Brys P, Debeer P. Chronic anterior shoulder dislocation : aspects of current management and potential complications. *Acta Orthop Belg* 2012 ; 78 : 291-295.