



## Influence of pelvic postural angle change on acetabulum implantation in total hip arthroplasty

Kegui LIU, Qunhui HE, Guangjun LIAO, Gang KONG, Cheng WANG

*From the Department of Orthopaedic Surgery, Yantai Shan Hospital, China.*

The current study investigated the relationship between the implantation angle of the acetabular component and the change in the pelvic postural angle during hip arthroplasty surgery. One pelvis with a left lower limb prosthesis was used. Total hip arthroplasty on the left pelvis was simulated with the help of a computer-assisted navigation system. The pelvis revolved around the horizontal, longitudinal and sagittal axes at different angles, and the anteversion and abduction of the acetabular component were measured. The changing angle of the pelvis rotating around the horizontal and longitudinal axes greatly influenced acetabular component anteversion. The changing angle of the pelvis rotating around the sagittal axis had a relatively great influence on the acetabular component abduction angle. The change in the postural angle of the pelvis had a great influence on the installation angle of the acetabular component. It is important to standardize posture prior to the operation.

**Keywords :** total hip arthroplasty ; computer navigation system ; pelvic angle ; acetabular anteversion ; acetabular abduction

### INTRODUCTION

With the recent popularization and development of total hip arthroplasty, stability has become the critical factor influencing the life span of hip prostheses and the quality of life of patients.

The accurate alignment angle of the acetabular component is important for the stability of the artificial hip joint. Whether the acetabular component can be positioned optimally is a key factor influencing the short-term and long-term effects of the operation. Lewinnek et al. described a “range” (5-25° anteversion and 30-50° abduction) for safe acetabular component positioning (9). Implants outside this range have a dislocation rate four times higher than for those within the range (6% versus 1.5%) (5, 8). In addition to decreasing the dislocation rate, achieving the optimal acetabular component positioning angle has a great influence on relieving partial stress transformations of the acetabular component, osteolysis, wearing of the polyethylene liner material and aseptic loosening (10, 14, 17).

Numerous factors can affect the accurate

- Kegui Liu<sup>1</sup>
- Qunhui He<sup>2</sup>
- Guangjun Liao<sup>1</sup>
- Gang Kong<sup>1</sup>
- Cheng Wang<sup>3</sup>

<sup>1</sup>Department of Orthopaedic Surgery, Yantai Shan Hospital, Yantai 264000, China;

<sup>2</sup>Anesthesiology Department, Yantai Yuhuangding Hospital, Yantai 264000, China;

<sup>3</sup>Orthopaedics Department, Shandong University Qilu Hospital, Jinan 250012, China

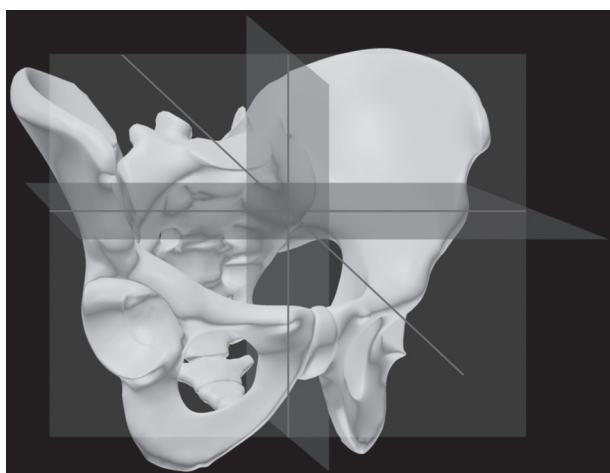
Correspondence: Cheng Wang Shandong University Qilu Hospital No.107 Wenhua west road Jinan 250012, China  
Tel: +086-15963504106 E-mail: chengwangcn@126.com

© 2016, Acta Orthopaedica Belgica.

*No benefits or funds were received in support of this study. The authors report no conflict of interests.*

Acta Orthopaedica Belgica, Vol. 82 - 3 - 2016

positioning of the acetabular component during total hip arthroplasty, among which pelvic posture is an important one. Pelvic posture can change in three directions (Fig. 1): 1) The angle at which the pelvis rotates around the horizontal axis (the bilateral anterior superior iliac spine connection line) is called pelvic inclination. Forward and backward rotation of the tail bone are referred to as anteversion and hypsokinesis, respectively. This angle is the pelvic inclination angle (inclination of the pelvis, PI); 2) The angle at which the pelvis rotates around the longitudinal axis (the line that is vertical to the horizontal axis and passes the line connecting the center of the bilateral pubic symphysis) is called pelvic rotation. This parameter is divided into right and left rotation (the hip rotates forward and backward), and the angle is referred to as the pelvic rotation angle (rotation of the pelvis, PR); 3) The angle at which the pelvis rotates around the sagittal axis (which is vertical to the horizontal and longitudinal axes and passes the joint of the two axes) is called pelvic obliquity (7). This parameter is divided into left and right obliquity, and the angle between these obliquities is referred to as the pelvic skew angle (skew of the pelvis, PS). For surgeons lacking experience, when the pelvic position is improper or the acetabular wall is impaired, visual measurement may lead to serious deviation of the acetabular component installation



**Fig. 1.** — Three dimensions of the pelvis. The red, green, and white planes represent the horizontal, sagittal, and coronal planes of the pelvis, respectively.

(22). These outcomes may result from the physician overlooking a change in pelvic posture in the lateral position. Eilander reported that supine THR provides reliable freehand acetabular component placement and, in most patients, a small reclination of the pelvis from supine to standing causes a small increase in anteversion of the acetabular component (3). Although surgeons can achieve acceptable prosthesis positions with intraoperative fluoroscopy, variations in pelvic tilt, pelvic rotation, and inclination alter acetabular orientation (16), and this issue remains to be further explored.

Computer navigation can be used to position the acetabular cup precisely in a planned orientation relative to predefined bony landmarks in order to increase the function and longevity of THA (4, 11, 15). In a randomized, controlled, matched, prospective study (13), operations were performed on two groups of thirty patients each comparing the computer-assisted system with freehand insertion of the acetabular component. Their results showed that the computer navigation system provided a large advantage in terms of spatial location.

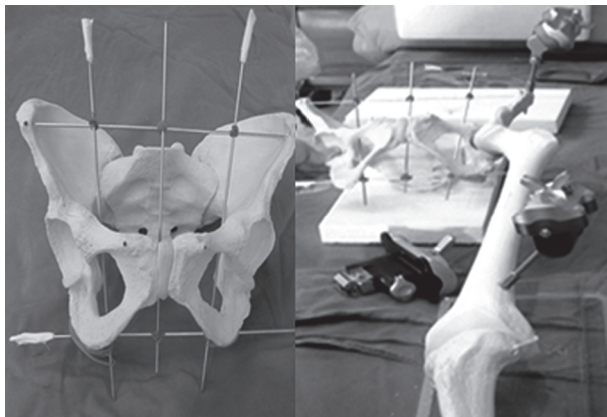
In this study, total hip arthroplasty was simulated with the help of the computer-assisted navigation system, and we measured the anteversion and abduction angles of the acetabular component when the pelvis rotated around the horizontal, longitudinal and sagittal axes at different angles. We then determined their changing trends and characteristics. The findings of this study may provide a reference for the accurate positioning of the acetabular component in total hip arthroplasty.

## MATERIALS AND METHODS

### Materials

One whole pelvis with a left lower limb prosthesis was used (Fig. 2). Two 2-mm Kirschner wires were drilled separately into the bilateral anterior superior iliac spine and bilateral pubic tubercle in parallel. The Kirschner wire that was drilled through the anterior superior iliac spine as a horizontal axis was removed, and another Kirschner wire was fixed to the former two Kirschner wires with

elastic. This latter wire coincided with the midpoint of the pubic symphysis and was vertical to the horizontal axis. This Kirschner wire was placed along the longitudinal axis of the pelvis, and another Kirschner wire was placed vertically to the longitudinal and horizontal axes. This wire was fixed to the prosthesis and considered the sagittal axis. A foam board was used (30-cm long, 20-cm wide, 5-mm thick). An inclinometer drill hole was made in the foam board with a 2-mm Kirschner wire; the holes were vertical to the board. A hole was drilled in the center of the board. This hole was considered to be the center, and a radius of 5 cm was defined. An additional margin hole was generated. Separated by  $5^\circ$  between adjacent edges of the holes, the position was located with an HY-S005-400B (400 mm) leveling instrument (the operation table was kept in the horizontal position), and the angle was measured with an inclinometer (accuracy of  $1^\circ$ ) and a computer navigation system (accuracy of  $1^\circ$ ).



**Fig. 2.** — A whole pelvis with a left lower limb prosthesis was used for computer navigation analysis.

### Pelvic postural angle

#### *Horizontal axis.*

The foam board was placed horizontally on the operating table and measured with a leveling instrument. The left side of the Kirschner wire was drilled through the bilateral anterior superior

iliac spine into the center hole of the board. One Kirschner wire was fixed to the anterior pelvic plane (bilateral anterior superior iliac spine and bilateral pubic tubercle plane) parallel to the horizontal axis and 5 cm away from the horizontal axis. This Kirschner wire was drilled into the corresponding marginal hole. The pelvic rotation angle around the horizontal axis could then be adjusted. Two holes were used to draw a line parallel to the vertical axis of the operating table. Forward and backward rotation of the tailbone were denoted as anteversion and hypsokinesis, respectively. The operation was illustrated in Figure 3A.

#### *Longitudinal axis.*

The foam board was placed on the operating table lengthwise, and the Kirschner wire was drilled and represented the longitudinal axis in the center hole. Another Kirschner wire was fixed to the former plane of the pelvis. In parallel to the longitudinal axis, the wire was positioned 5 cm away from the longitudinal axis and drilled into the corresponding marginal hole. The pelvic rotation angle around the longitudinal axis could then be adjusted. Two holes were used to draw a line that was vertical to the operating table. Rotation to the left was considered left rotation (hip backward) and to the right was right rotation (hip forward). The operation was illustrated in Figure 3B.

#### *Sagittal axis.*

The foam board was placed on the operating table lengthwise, and the Kirschner wire representing the sagittal axis was drilled into the center hole. Another Kirschner wire was fixed to the vertical plane of the former plane of the pelvis. It was positioned 5 cm away from and parallel to the sagittal axis and was drilled into the corresponding marginal hole. The pelvic rotation angle around the sagittal axis could then be adjusted. Two holes were used to draw a line that was vertical to the operating table. Rotation of the tail bone to the left was called left inclination (in the Trendelenburg position) and to the right was called right inclination (in the dorsal elevated position). The operation was illustrated in Figure 3C.

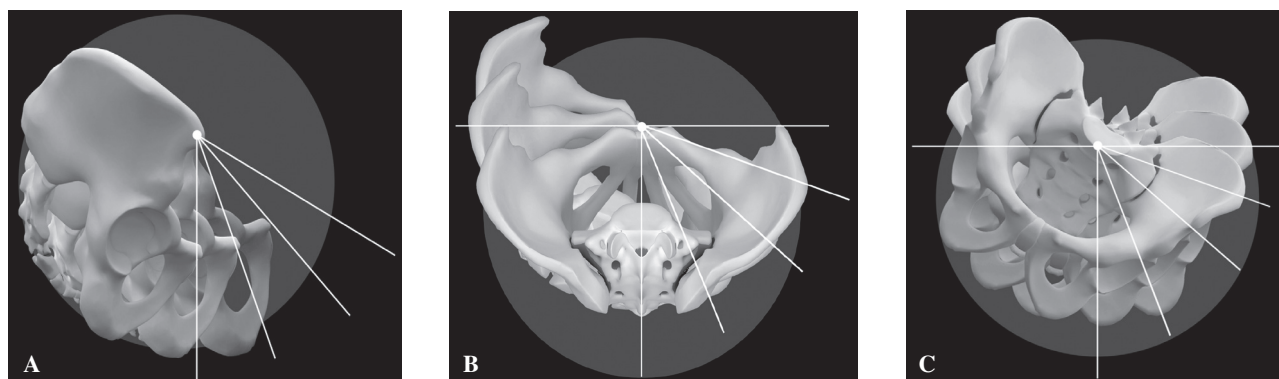


Fig. 3. — Pelvic rotations. A, around the horizontal axis. B, around the longitudinal axis. C, around the sagittal axis.

### Computer navigation system (CNS)

The computer navigation system used was Navigation System II-CartREF7700-100-000 from Stryker.

### Operating procedure.

One fixed piton with a connecting link was drilled into the anterior superior iliac spine, and one was drilled into the distal femur. One track was fixed to the side of the acetabulum, and another was fixed to the side of the femur. Registration was completed according to the computer instructions. The center position of the pelvis and caput femoris was located. The indicator was used to collect information about the acetabular fossa and acetabular rim to determine the depth and diameter of the acetabulum. The acetabular cup mold was positioned with an acetabular impactor equipped with a positioning tracker and conventional locator. The acetabular cup mold was mounted at an angle of  $0^\circ$ , and its acetabular anteversion and abduction angles were generated in a safe range. The pelvic angle was then adjusted gradually. Each time the angle was adjusted, the installment of the acetabular cup mold (mounted according to the standard lateral position) could be located using a conventional locator. The acetabular anteversion and abduction angles tested by the computer navigation system were recorded.

A senior physician was blinded to complete the simulation according to the above operations five times, and the average values of the data collected were analyzed.

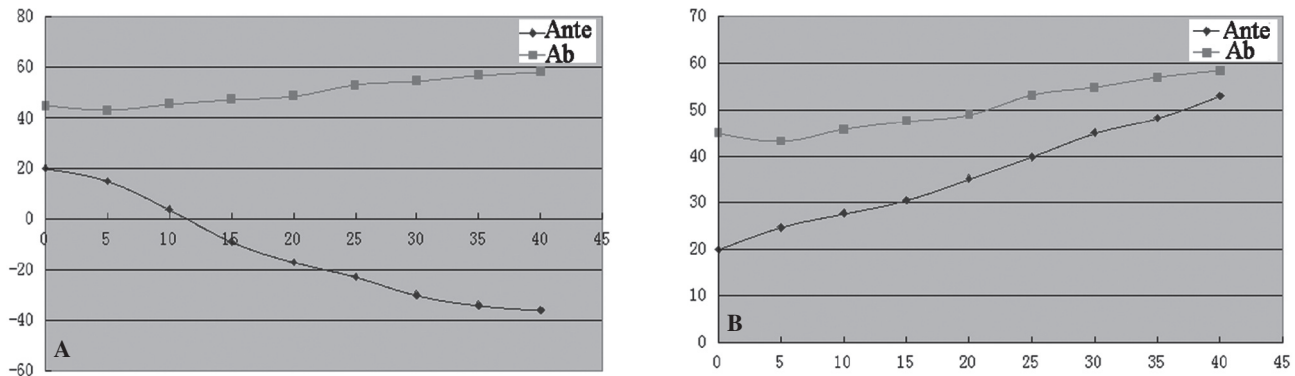
### Statistical analysis

Using SPSS 20.0, linear regression was performed to study the relationships of the rotation angles of the pelvis around the horizontal, longitudinal, and sagittal axes with the acetabular anteversion and abduction angles.

## RESULTS

### Horizontal axis

The changing trends in the acetabular component acetabular anteversion and abduction angles when the pelvis was inclined at different angles around the horizontal axis are shown in Figure 4. When the pelvis was inclined forward along the horizontal axis and the inclination angle increased, the acetabular anteversion and abduction angles displayed linear decreasing and linear increasing trends, respectively (Fig. 4A). When the pelvis was rotated around the horizontal axis each time the pelvic inclination angle increased  $5^\circ$ , the acetabular component anteversion angle decreased approximately  $7^\circ$ , and the abduction angle increased approximately  $2^\circ$ . Each time the pelvis inclined forward by  $10^\circ$ , the acetabular anteversion angle decreased approximately  $15^\circ$ , and the abduction angle increased approximately  $4^\circ$ . Figure 4B shows the changing trend in the acetabular component acetabular anteversion and abduction angles when the pelvis was inclined backward at different angles around the horizontal axis. When the pelvis was



**Fig. 4.** — The changing trend of the acetabular component with the inclination of the pelvis at different angles around the horizontal axis. A, forward. The respective linear regression equations were established as follows: acetabular anteversion angle  $Y = -1.51X + 17.96$ ; acetabular abduction angle  $Y = 0.40X + 42.54$ . B, backward. The linear regression equations were established as follows: acetabular anteversion angle  $Y = 0.82X + 19.66$ ; Abduction angle  $Y = 0.40X + 42.54$ . Ante, anteversion angle. Ab, abduction angle.

inclined backward along the horizontal axis and the inclination, acetabular anteversion and abduction angles were increased, a linear increasing trend was observed. Each time the pelvis was rotated around the horizontal axis, it inclined backward by 5°. In addition, the acetabular component anteversion angle increased approximately 4°, and the abduction angle increased approximately 2°. Each time the pelvis inclined backward by 10°, the acetabular anteversion angle increased approximately 8°, and the abduction angle increased approximately 4°.

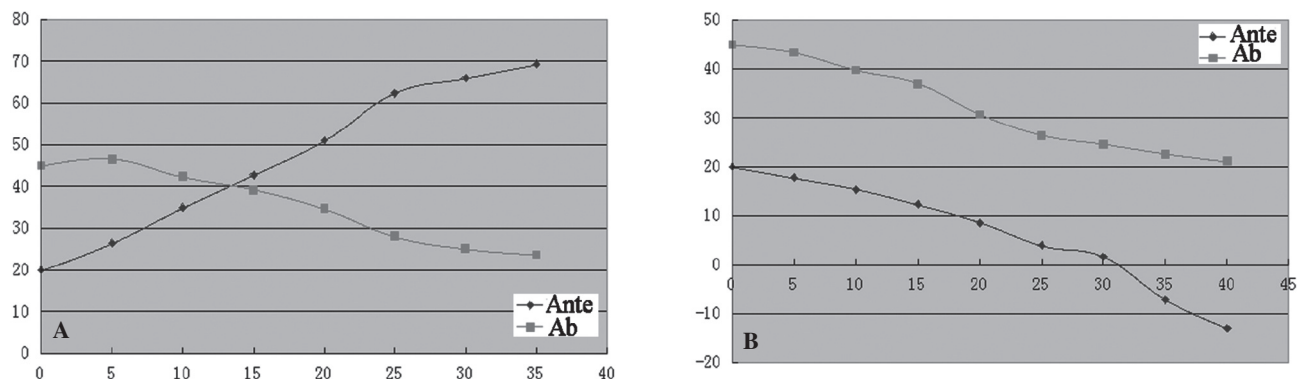
**Longitudinal axis**

The changing trends in the acetabular component acetabular anteversion and abduction angles with the rotation of the pelvis at different angles around the longitudinal axis are shown in Figure 5. When the pelvis was rotated to the left along the longitudinal axis with an increasing rotation angle, the acetabular anteversion and abduction angles displayed linear increasing and linear decreasing trends, respectively (Fig. 5A). Each time the pelvis was rotated backward around the longitudinal axis by 5°, the anteversion angle increased approximately 7°, and the abduction angle decreased 3°. Each time the pelvis was rotated backward by 10°, the anteversion angle increased 16°, and the abduction angle decreased 7°. When the pelvis was rotated forward along the longitudinal axis with an

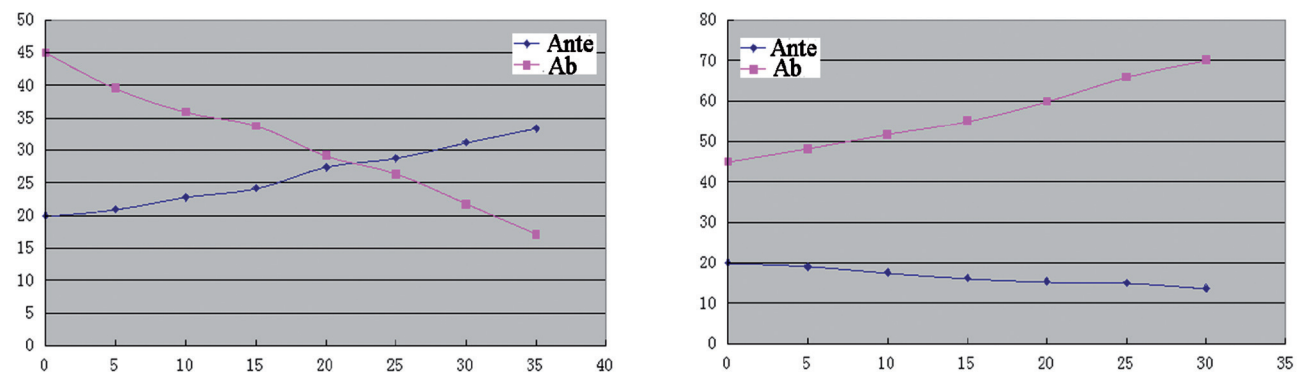
increasing rotation angle, the acetabular component anteversion and abduction angles displayed linear decreasing trends (Fig. 5B). Each time the pelvis was rotated forward around the longitudinal axis by 5°, the anteversion angle decreased 4°, and the abduction angle decreased 3°. Each time the pelvis was rotated backward by 10°, the anteversion angle decreased approximately 8°, and the abduction angle decreased 6°.

**Sagittal axis**

The changing trends in the acetabular component acetabular anteversion and abduction angles are shown in Figure 6. When the pelvis was inclined to the right (in the Trendelenburg position) along the sagittal axis with an increasing inclination angle, the acetabular anteversion angle displayed a linear increasing trend, and the abduction angle showed a linear decreasing trend (Fig. 6A). Each time the pelvis was inclined to the right around the sagittal axis by 5°, the anteversion angle increased 2°, and the abduction angle decreased 4°. Each time the pelvis was inclined to the right by 10°, the anteversion angle increased 4°, and the abduction angle decreased 8°. When the pelvis was inclined to the left (in the dorsal elevated position) along the sagittal axis with an increasing inclination angle, the acetabular anteversion and abduction angles displayed linear decreasing trend and linear



**Fig. 5.** — The changing trends in the acetabular component with the rotation of the pelvis at different angles around the longitudinal axis. A, backward. The linear regression equations were established as follows: acetabular anteversion angle  $Y=1.51X+20.27$  and abduction angle  $Y=-0.72X+48.25$ . B, forward. The linear regression equations were established as follows: acetabular anteversion  $Y=-0.81X+22.82$  and abduction angle  $Y=-0.66X+45.55$ . Ante, anteversion angle. Ab, abduction angle.



**Fig. 6.** — The changing trends in the acetabular component when the pelvis was inclined around the sagittal axis. A, to the right (in the Trendelenburg position). The linear regression equations were established as follows: acetabular anteversion angle  $Y=0.40X+19.18$  and abduction angle  $Y=-0.75X+44.33$ . B, to the left (in the dorsal elevated position). The linear regression equations were established as follows: acetabular anteversion angle  $Y=-0.21X+19.8$  and abduction angle  $Y=0.85X+43.84$ . Ante, anteversion angle. Ab, abduction angle.

increasing trends, respectively (Fig. 6B). Each time the pelvis was inclined to the left around the sagittal axis by  $5^\circ$ , the anteversion angle decreased approximately  $1^\circ$ , and the abduction angle increased approximately  $4^\circ$ . Each time the pelvis inclination angle increased by  $10^\circ$ , the anteversion angle decreased approximately  $2^\circ$ , and the abduction angle increased approximately  $8^\circ$ .

## DISCUSSION

The accurate position of acetabular component is of great importance in total hip arthroplasty. Although cross-table lateral fluoroscopy is

commonly used to measure acetabular components during THA surgery, navigation, which has become widely used in the last decade, greatly enhances the precision of cup positioning, thus eliminating malpositioning. With the assistance of a navigation system during the hip replacement procedure, images can reflect the position and direction of the bones, acetabular component and other surgical instruments. The surgeon can adjust the angle, direction and position of the acetabular component according to the reflected data (21), which provides a direct method for the accurate installment of the acetabular cup. However, many authors have complained that the pelvic posture of the patient

is difficult to measure and easy to change during the operation, which can lead to considerable deviation of the acetabular component orientation. Kalteis et al. revealed considerable inaccuracies in conventional cup implantation by experienced and trainee surgeons and demonstrated the influence of pelvic tilt on acetabular cup alignment (6). Tannast et al. claimed that difficulty in locating the pelvic position in the traditional acetabular cup positioning procedure is the key factor responsible for inaccurate orientation of the acetabular cup (20). To improve the accuracy of acetabular cup positioning, surgeons should evaluate whether the pelvic position is accurate prior to and during the operation.

Our research has recognized and studied the ability of pelvic rotation to lead to an obvious change in the acetabular component positioning angle, which coincided with results from X-ray measurements (19). Zhu studied pelvic sample anatomical measurements and found that each time the pelvis was inclined by  $10^\circ$ , the acetabular component anteversion angle decreased  $6^\circ$  (23). Lembeck et al. found that each time the pelvic anteversion angle increased by  $1^\circ$ , the acetabular component acetabular anteversion decreased  $0.7^\circ$  (8). Dorr et al. demonstrated that each time the pelvic anteversion inclined forward by approximately  $1^\circ$ , the acetabular component anteversion angle decreased  $0.8^\circ$  (2). Each time the pelvis inclined backward by approximately  $1^\circ$ , the acetabular component anteversion angle increased approximately  $0.8^\circ$ . All of the above findings are similar to the results obtained herein. In addition, data analysis in the present study was conducted to evaluate the influence of the abduction angle, which enriched the study by determining the actual influence of the three pelvic directions on the acetabular angle. According to the results of the present study, we propose that surgeons should pay close attention to the change in pelvic position during total hip arthroplasty. Furthermore, prior to placement of the acetabular component during the operation, surgeons should recheck the posture of the pelvis, attempt to maintain the pelvic bilateral anterior superior iliac spine vertical to the ground, and properly control the three rotation directions of

the pelvis in order to accurately mount the abduction and anteversion of the acetabular component. The results of this study demonstrate the importance of the standard pelvic lateral position in total hip arthroplasty. The design of a more effective method to locate the pelvis requires further effort in a future study.

We also believe that the reference plane of the computer navigation system is the anterior pelvic plane; when the pelvic position changes, its anterior plane will not change. Therefore, application of the computer navigation system to the placement of the acetabular cup will increase its accuracy. This effect has been demonstrated in many clinical cases (1, 12). However, this procedure is expensive and complicated. In addition, it has not been widely used in hospitals, and its man-made risk and system risk is high, which may increase the operation risk. If the pelvic position changes during the operation, then post-operation impact, dislocation and other complications will occur even if the computer-assisted navigation system is used with the anterior pelvic plane as a reference to determine the angle and position of the acetabular cup.

The limitation of this study is the use of an idealized and simplified change in pelvic position. During clinical procedures, changes in the postural angle of the pelvis typically occur in three directions. When the pelvis rotated around two or three axes, we could not detect its influence on the orientation of the acetabular component.

In conclusion, the change in the pelvic postural angle has a great influence on the installation angle of the acetabular component. With the help of a computer navigation system, the influence of the pelvic postural angle change on the acetabular component installation angle will decrease. The findings of this study may provide useful data for the accurate positioning of the acetabular component in total hip arthroplasty.

## REFERENCES

1. Digiioia AM, Jaramaz B, Blackwell M, et al. The Otto Aufranc Award: Image guided navigation system to measure intraoperatively acetabular implant alignment. *Clin Orthop Relat Res* 1998; 35: 8-22.

2. **Dorr LD, Malik A, Wan Z, et al.** Precision and bias of imageless computer navigation and surgeon estimates for acetabular component position. *Clin Orthop Relat Res* 2007; 465: 92-99.
3. **Eilander W, Harris SJ, Henkus HE, Cobb JP, Hogervorst T.** Functional acetabular component position with supine total hip replacement. *Bone Joint J* 2013; 95-B: 1326-1331.
4. **Gandhi R, Marchie A, Farrokhyar F, Mahomed N.** Computer navigation in total hip replacement: a meta-analysis. *Int Orthop* 2009; 33: 593-597.
5. **Hirakawa K, Mitsugi N, Koshino T, et al.** Effect of acetabular cup position and orientation in cemented total hip arthroplasty. *Clin Orthop* 2001; 388: 135-142.
6. **Kalteis TA, Handel M, Herbst B, et al.** In vitro investigation of the influence of pelvic tilt on acetabular cup alignment. *J Arthroplasty* 2009; 24: 152-157.
7. **Kosak R, Kralj-Iglic V, Iglic A, Daniel M.** Polyethylene wear is related to patient-specific contact stress in THA. *Clin Orthop Relat Res* 2011; 469: 3415-3422.
8. **Lembeck B, Mueller O, Reize P, et al.** Pelvic tilt makes acetabular cup navigation inaccurate. *Acta Orthop* 2005; 76: 517-523.
9. **Lewinnek GE, Lewis JL, Tarr R, et al.** Dislocations after total hip replacement arthroplasties. *J Bone Joint Surg (Am)* 1978; 60: 217-220.
10. **Little NJ, Busch CA, Gallagher JA, Rorabeck CH, Bourne RB.** Acetabular polyethylene wear and acetabular inclination and femoral offset. *Clin Orthop Relat Res* 2009; 467: 2895-2900.
11. **Manzotti A, Cerveri P, De Momi E, Pullen C, Confalonieri N.** Does computer-assisted surgery benefit leg length restoration in total hip replacement? Navigation versus conventional freehand. *Int Orthop* 2011; 35: 19-24.
12. **Nogler M, Kessler O, Prassl A, et al.** Reduced variability of acetabular cup positioning with use of an imageless navigation system. *Clin Orthop Relat Res* 2004; 426: 159-163.
13. **Parratte S, Argenson JN.** Validation and usefulness of a computer-assisted cup-positioning system in total hip arthroplasty. A prospective, randomized, controlled study. *J Bone Joint Surg Am* 2007; 89: 494-499.
14. **Patil S, Bergula A, Chen PC, Colwell CW Jr, D'Lima DD.** Polyethylene wear and acetabular component orientation. *J Bone Joint Surg Am* 2003; 85-A Suppl 4: 56-63.
15. **Renkawitz T, Dendorfer S.** Orthopedic navigation technology and biomechanical evaluation for total hip replacement. *Proc Inst Mech Eng H* 2012; 226: 897-898.
16. **Sariali E, Lazennec JY, Khiami F, Gorin M, Catonne Y.** Modification of pelvic orientation after total hip replacement in primary osteoarthritis. *Hip Int* 2009; 19: 257-263.
17. **Schmalzried TP, Guttman D, Grecula M, et al.** The relationship between the design, position, and articular wear of acetabular components inserted without cement and the development of pelvic osteolysis. *J Bone Joint Surg (Am)* 1994; 76: 677-688.
18. **Tang JS, Shen HQ.** The effect of the acetabular abduction by the pelvic obliqueness and its clinical significance. *Journal of Medical Postgraduates* 2007; 20: 173-175.
19. **Tannast M, Langlotz U, Siebenrock KA, et al.** Anatomic referencing of cup orientation in total hip arthroplasty. *Clin Orthop Relat Res* 2005; 436: 144-150.
20. **Tannast M, Murphy SB, Langlotz F, et al.** Estimation of pelvic tilt on anterior X-rays—a comparison of six parameters. *Skeletal Radiol* 2006; 35: 149, 155.
21. **Wang JQ, Sun L, Wang MY.** Application and progress in computer assisted orthopaedic surgery. *Chinese Journal of Orthopaedic Trauma* 2004; 6: 110-114 (in Chinese with English abstract).
22. **Zhu JF, Shen HQ.** New advances in Research on the positioning system and its application in total hip replacement. *Chinese Journal of Orthopaedic Trauma* 2005; 7: 567-570 (in Chinese).
23. **Zhu TY.** Dynamic measurement of acetabular abduction and anteversion angles and its clinical significance. *Chinese Journal of Orthopaedics* 1995; 15: 497-499.