



Combination of transpedicular enucleation and Plate-Rod System for single-stage correction of progressive hemivertebral scoliosis

Kuang ZHENGDA, Wang GUANJUN, Ye QIBIN, Ji HUIRU, Zhang XINYU, Du MINGKUI

From the Third Department of Orthopedics, General Hospital of Armed Police Forces, Beijing, China

The purpose of this study is to report the effectiveness of transpedicular enucleation and Plate-Rod System for Scoliosis (PRSS) fixation for the treatment of hemivertebral (HV) scoliosis. 16 patients with progressive HV scoliosis underwent the combined procedure. The technique involves excision of cancellous bone to eliminate the blood supply of the cartilaginous endplate and destroy the superior and inferior vertebral end plates, followed by PRSS fixation to correct the main curve and compensatory curve. The mean age at operation was 8.125 ± 1.82 years. The scoliosis curve was corrected from average $55.06 \pm 25.68^\circ$ preoperatively to $21.25 \pm 15.51^\circ$ postoperatively. At the latest follow-up, the Cobb angle was $24.38 \pm 16.44^\circ$, and there was no significant difference compared with immediate postoperative angle ($P > 0.05$). No surgical complication of neurological deficits occurred in any patients. Combined use of transpedicular enucleation and PRSS fixation is a safe and effective single-stage method for the management of HV scoliosis in growing children.

Keywords : congenital scoliosis ; hemivertebra ; transpedicular enucleation ; Plate-Rod System for Scoliosis.

INTRODUCTION

Congenital scoliosis caused by a hemivertebra has the strong potential for progression and being nonresponsive to bracing, especially a full segmental unincarcerated hemivertebra. Adolescence marks

the most rapid progression curve growth spurt which only stops at skeletal maturity. The majority of congenital scoliosis cases caused by a hemivertebra require surgical treatment, and the surgery should be performed at the earliest possible age before the deformity becomes severe and extends to the adjacent segments resulting in compensatory structural deformation. The goal of the surgery is to remove the growth potential from the convex side of the hemivertebra and allow for gradual correction with continued growth of the concave side.

Hemivertebra excision was first performed in 1921 by Royle (7), and since then a number of transpedicular procedures have been developed for the surgical treatment of congenital hemivertebral (HV) scoliosis (1,3,5).

-
- Kuang Zhengda.
 - Wang Guanjun.
 - Ye Qibin.
 - Ji Huiru.
 - Zhang Xinyu.
 - Du Mingkui.

Third Department of orthopedics, General Hospital of Armed Police Forces, Beijing, China.

Correspondence : Kuang Zhengda and Wang Guanjun, Third Department of Orthopedics, General Hospital of Armed Police Forces, 69 Yongding Road, Haidian District, 100039 Beijing, China. E-mail : qibinye06@sina.com

Kuang Zhengda and Wang Guanjun contributed equally to this study.

© 2016, Acta Orthopædica Belgica.

No benefits or funds were received in support of this study. The authors report no conflict of interests.

Acta Orthopædica Belgica, Vol. 82 - 1 - 2016

This paper describes a new combined method of transpedicular enucleation and Plate-Rod System for Scoliosis (PRSS) fixation for the correction of HV scoliosis. The plate-rod system for scoliosis (PRSS) was developed by Peking Union Medical College Hospital in 1998 for the purpose of scoliosis therapy, and has shown effective results after several years of clinical use (9,10,11). The PRSS stretches as a child's spine grows, and can be removed when the spine is fully grown; at this point the shape and the behaviour of the spine will have returned to normal status. This result cannot be obtained with traditional therapies.

MATERIALS AND METHODS

In this retrospective study, we reviewed the medical records of 16 patients with progressive HV scoliosis who received surgical correction at PUMC Hospital and General Hospital of the Chinese Armed Police Forces During the period from June 2003 to April 2009. Preoperative evaluation consisted of radiographic imaging included standing anteroposterior (AP) and lateral views of the full spine. A three-dimensional model of the spine is helpful to plan the operative procedure to increase the accuracy of determining the segmentation of an involved vertebra and the presence or absence of a bony bar. Magnetic resonance imaging (MRI) of the spine was performed to assess the neuroanatomy and exclude intrathecal abnormalities.

All patients received radiographs taken immediately postoperative, and at follow-up visits. Radiographs were analyzed using the Cobb method, including the total main scoliosis and the compensatory curve.

This study was approved by the Institutional Review Board of the hospital, and all patients and their legal guardians provided informed consent at the time of surgery for the procedures performed.

All the operations were performed by the senior author. A standard posterior midline approach was used, and limited subperiosteal dissection was performed to expose the posterior element of the spine. Identified the pedicle and a "T" awl conformed the position within the pedicle of the affected hemivertebra. These procedures were performed with C-arm fluoroscopic guidance. A small curette was used to cannulate the pedicle and was then inserted into the HV body to remove the cancellous bone. An electric drill and larger curette were alternately used to enlarge and deepen the channel. These maneuvers facilitated the turning of the curved curette to de-

stroy the superior and inferior endplate of the HV until the wall of the HV became soft. The lamina and pedicle were partially removed; the internal and lateral walls were left in place to protect the dural tube and reduce the risk of developing a pneumothorax.

Next, the PRSS was used to correct the main and compensatory curves (9). It is composed of four components: the plate-rod, the rod, the screw-hook and the connectors. The components are made of titanium alloy. Screw-Hooks are fixed on the lamina, the screws at the end vertebrae are linked with the end connector. The plate-rod and the cylindrical rod are connected by the upper and lower connectors. Plate-rod is placed on convex side by way of lateral sidewise push to provide asymmetrical stress on both sides of the vertebral endplates, another rod on concave side and connected by connectors forming a strong frame-like setup.

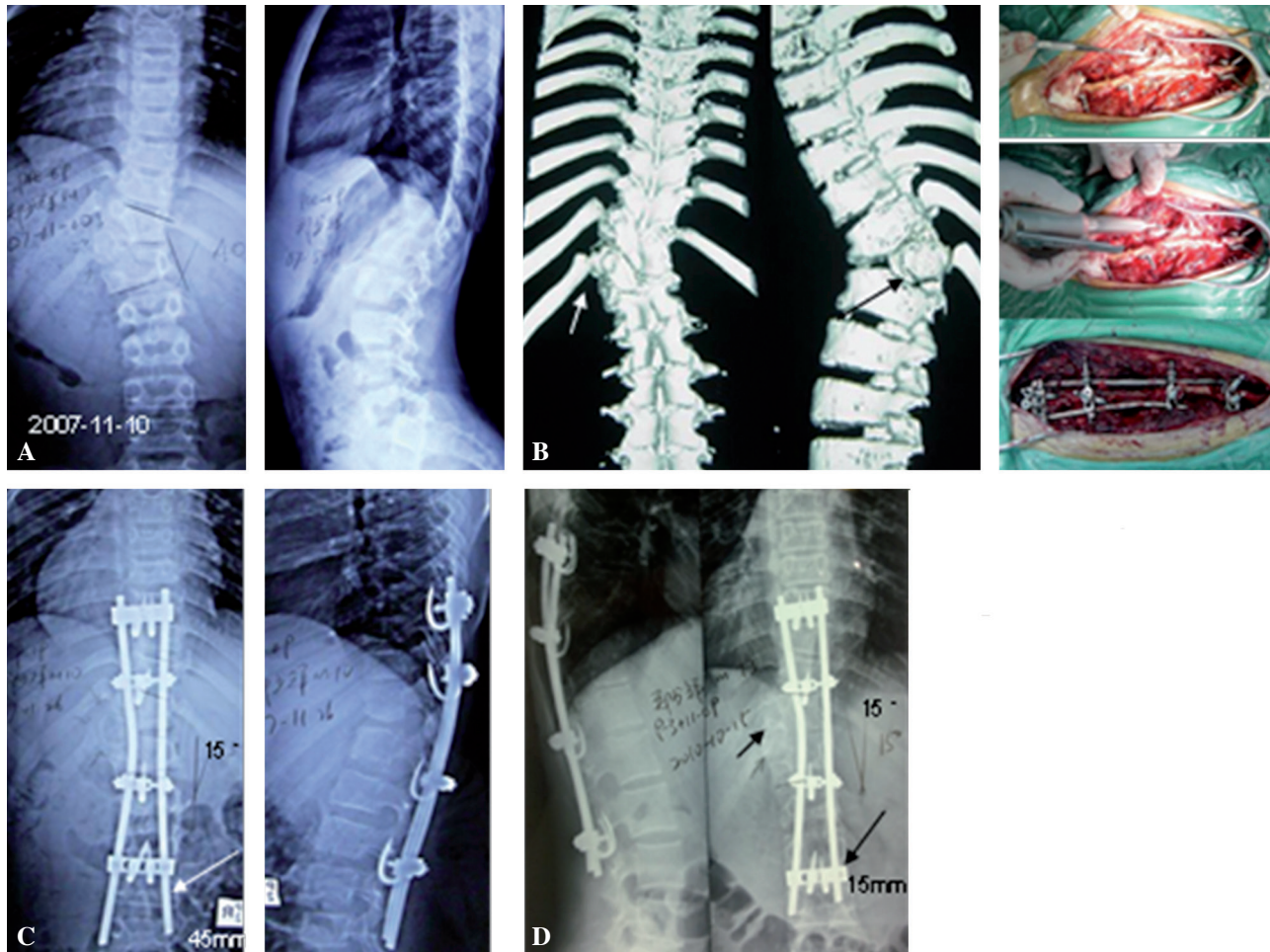
The corrective force is provided by the lateral sidewise push of the plate-rod. There is no distractive force during surgical correction, hence, the risk of cord damage caused by over-correction seldom occurs. A certain length of the lower ends of the rods amounting to 1/5 of the estimated growth length of the children is left to pass through the holes of the lower connector and lies freely in the hole. This will allow upward migration of the rods to keep up with the longitudinal growth of the instrumented spinal column after operation. The upper end of the plate rod on the convex side and the rod on the concave side are tightly fixed in place by the upper connector.

Bony fusion is not required, essentially normal spine can be obtained after removing the implants when the skeletal growth terminated.

The plate-rod provides compressive stress on the convex side to partially close the posterior gap created by enucleating the HV, thus achieving curve correction during the growing years. No bony fusion was performed. All patients were allowed weight-bearing the third day after surgery. Images of a representative case are shown in Figure 1.

RESULTS

A total of 16 patients with a mean age of 8.13 ± 1.82 years (range, 4-10 years) were included in the study. Unincarcerated fully segmented hemivertebrae were present in 12 patients (2 cases of double HV), incarcerated segmented hemivertebrae in 2, and incarcerated partially segmented hemivertebrae in 2. Intrathecal abnormalities were found in 3 patients, each one with diastematomyelia,



COLOR PRINT? An additional fee will be charged (contact Luc.desmet@uz.kuleuven.ac.be)

Fig. 1. — **A.** A 10-year-old male with hemivertebra scoliosis of 40°. **B.** A posterior midline approach was used. A small curette and an electric drill were used to cannulate the pedicle and remove cancellous bone from the hemivertebra body. The spine was fixed with the PRSS. **C.** Postoperatively, the scoliosis angle was 15°. The lower end of the rod was 45 mm (long arrow). **D.** At 3-months postoperatively, the angle of scoliosis was maintained at 15°. Good bone fusion was noted (short arrow). The lower end of the rod was 15 mm (long arrow) indicating the instrumented spine growth of 30 mm.

dipomyelia, and syringomyelia. The average intraoperative blood loss was 250 ml.

Postoperative bracing was used for 3 months only. The average preoperative Cobb angle was $55.06 \pm 25.68^\circ$ (range, 25°-110°). The average follow-up period was 37.25 ± 22.24 months (range, 24 to 84 months). The scoliotic curve was corrected from average $55.06 \pm 25.68^\circ$ preoperatively to an average of $21.25 \pm 15.51^\circ$ immediately postoperatively, with corrective rate 60.5%. At the latest follow-up, the Cobb angle was $24.38^\circ \pm 16.44^\circ$, and compared with immediate postoperative angle there was no significant difference ($P > 0.05$), indicating

no significant loss of correction. Spontaneous convex arthrodesis was founded in 6 cases around the HV area. No neurological deficits were noted in any patients.

DISCUSSION

Congenital HV scoliosis is progressive. Nasco *et al* (6) reported an average progression of 4° per year with a range of 1 to 30°. The 60 patients with various deformities due to HV and nonresponsive to bracing, operative treatment is the mainstay of care. A number of procedures have been reported for the

treatment of congenital HV scoliosis, and the 3 basic operations are fusion *in situ*, convex growth arrest (epiphysiodesis), and HV resection. However, the most effective treatment remains uncertain.

Isolated posterior fusion with or without instrumentation is no longer recommended for young children because correction is limited, and the crankshaft phenomenon occurs in 15% of patients, especially when the age at surgery is less than 4 years (2). Anterior fusion is needed for skeletally immature patients, and posterior fusion alone is also not appropriate for severe curves, especially those with kyphosis.

Combined anterior and posterior hemiepiphysiodesis is the treatment of choice for mild and moderate curves, and removing the growth potential from convex side of the hemivertebra allows for gradual correction with continued growth on concave side. This procedure must be done early (before 5 years old), and before the curve has progressed beyond 50° or 60°. The addition of posterior instrumentation is necessary to slow or arrest the progression of deformities.

Combined anterior excision of the hemivertebrae and posterior fusion adds the benefit of better correction. It also decreases the likelihood of pseudarthrosis and prevents the crankshaft phenomenon by removing the growth plates. The improvement rate has been reported to vary from 34.3% to 71.1% (4). The disadvantage of this technique is the need for an anterior and posterior approach, and significant blood loss that makes it impossible to perform in some children whose condition cannot tolerate the operative trauma. In addition, convex arthrodesis via the anterior or posterior approach alone cannot achieve curve correction or affect gradual correction. More recent studies such as by Ruf *et al* (8) reported posterior HV resection and convex compression by using a screw-rod system. Mikles *et al* (5) reported transpedicular hemiepiphysiodesis (eggshell technique) and posterior instrumentation to treat HV scoliosis. These techniques allow immediate correction of scoliosis, and eggshell technique offers the advantage of a single-stage procedure. The primary effect of these techniques is to eliminate the growth potential of the hemivertebrae. However, in many cases re-interventions are needed

due to curve progression despite HV resection, which suggest that further correction is needed during the later growth years.

Ginsburg *et al* (1) reported a transpedicular hemiepiphysiodesis technique in which posterior instrumentation was only used on the convex side of the HV to perform a short segmental fusion. As is known, one-side short segmental fusion does not affect gradual spontaneous correction with time in moderate and severe scoliotic curves because it cannot control the progression of the cranial and caudal compensatory curves associated with the affected hemivertebra. Thus, we used the PRSS system to extend the corrective level to include 2 to 3 segments above and below the hemivertebra to maximize spontaneous correction after the operation. The unique design of the PRSS provides normalization of spine growth and gradual realignment of the spine curvature in the later growing period (1). We used a curette to destroy the superior and inferior vertebral endplates from the inner side of the HV body. This transpedicular enucleating technique avoids the morbidity of the retroperitoneal or transthoracic approach associated with anterior and posterior HV excision, and decreases the operation time and blood loss. This approach requires no exposure of the spinal cord or neural roots, which decrease the risk of neurological injury. The blood supply of the cartilaginous endplate comes from the cancellous bone in the inner side of the HV body, which is eliminated after transpedicular enucleating. Therefore, growth potential on the convex side of the HV is arrested.

In our prior study (9), we showed that scoliotic curve correction continued after PRSS instrumentation, indicating that the system modulated spinal growth. That is, it promotes concave growth and arrests convex growth in the main curve and compensatory curve in the later growth period due to the asymmetrical stress provided by the PRSS system. When the PRSS system is placed, asymmetrical stress is created by the lateral sidewise push of the plate-rod, which acts on both sides of the endplates of the vertebrae. Compressive stress is exerted over the convex side, while tensile stress is exerted over the concave side of curvature. Asymmetrical stress produced in this manner affects the growth over

both sides of the vertebral cartilaginous endplate, which subsequently leads to asymmetrical growth of the scoliotic vertebrae and realignment of the spine curvature in the later growing period. Thus, the scoliotic curvature becomes straight (9,10).

CONCLUSION

Combination of transpedicular enucleation and Plate-Rod System for Scoliosis (PRSS) is a safe and effective method for single-stage correction of progressive hemivertebral scoliosis. The major advantage of this method is that it can not only eliminate or decrease the growth potential of the affected hemivertebra, but also offer immediate correction and gradual spontaneous correction in the subsequent growing period.

REFERENCES

1. **Ginsburg G, Mulconrey DS, Browdy J.** Transpedicular hemiepiphysiodesis and posterior instrumentation as a treatment for congenital scoliosis. *J Pediatr Orthop* 2007 ; 27 : 387-391.
2. **Kesling KL, Lonstein JE, Denis F, Perra JH, Schwender JD, Transfeldt EE, Winter RB.** The crankshaft phenomenon after posterior spinal arthrodesis for congenital scoliosis : a review of 54 patients. *Spine* 2003 ; 28 : 67-271.
3. **Keller DM, Lindseth RE, Derosa GP.** Progressive congenital scoliosis treatment using a transpedicular convex anterior and posterior hemiepiphysiodesis : a preliminary report. *Spine* 1994 ; 19 : 1933-1939.
4. **Klemmme WR, Polly DWJR, Orehowski JR.** Hemivertebral resection for congenital scoliosis in very young children. *J Pediatr Orthop* 2001 ; 21 : 761-764.
5. **Mikles M, Gragiano G, Hensinger R.** Transpedicular eggshell osteotomies for congenital scoliosis using frameless stereotactic guidance. *Spine* 2001 ; 26 : 2289-2296.
6. **Nasca HR, Stelling FH, Steel HH.** Progression of congenital scoliosis due to hemivertebrae with bars. *J Bone Joint Surg Am* 1975 ; 57 : 456-466.
7. **Royle ND.** The operative removal of an accessory vertebra. *Med J Aust* 1928 ; 1 : 467-468.
8. **Ruf M, Harms J.** Posterior hemivertebra resection with transpedicular instrumentation : early correction in children aged 1 to 6 years. *Spine* 2003 ; 28 : 2132-2138.
9. **Ye QB, Wang YP, Zhang J, Weng XS.** A new spinal instrumentation without fusion for the treatment of progressive idiopathic scoliosis in growing children. *J Musculoskel Res* 2003 ; 7 : 201-209.
10. **Ye QB, Pang X, Kuang Z, Wang W.** Plate-rod spinal system (PRSS) in the management of progressive early onset scoliosis. *J Musculoskel Res* 2008 ; 11 : 201-209.
11. **Zang YL, Yang S, Wang QM, Zhang ZW, Ye QB, Zeng YJ.** Stress analysis of a plate-rod system for scoliosis correction. *J Med Eng Technol* 2010 ; 34 : 437-42.