



## The Accessory muscles of the Axilla

F. VERHAEGEN, P. DEBEER, M. MOYAERT

From the KU Leuven, Division of orthopaedics, University Hospitals Leuven (campus Pellenberg) Belgium

The axilla is a region of clinical and surgical importance with plenty of anatomical variations. One of these is the presence of accessory muscles. The literature was reviewed in order to identify the different supernumerary muscles that are described in the axilla. Variant muscle slips arising from the pectoral muscle or latissimus dorsi muscle have been described. There still remains controversy regarding the phylogenetic origin of these different muscles. We described the most frequently reported muscles, their origin, and course. Further research is required regarding the innervation and influence on glenohumeral and scapulothoracic kinematics.

**Keywords :** supernumerary ; chondroepitrochlearis ; chondrofacialis ; pectoralis quartus ; axillary arch ; Langer ; atavistic remnants.

### INTRODUCTION

Variant muscle slips arising from the pectoral muscle or latissimus dorsi muscle have been described. These anomalies have usually been found incidentally at post-mortem examinations.

Despite their usually asymptomatic characteristics, they are a potential cause of neurovascular problems<sup>38</sup> as they cross over the axillary nerves and vessels. Furthermore the knowledge of these muscle variations may be of special importance to anaesthesiologist, physiotherapist and surgeons. In this paper we will review and describes the different accessory muscle slips in the axilla.

*No benefits or funds were received in support of this study. The authors report no conflict of interests.*

### MATERIALS AND METHODS

The literature was reviewed in order to distinguish the different supernumerary muscles that pass through the axilla. Using appropriate keywords and MESH headings we selected the most reliable reports, and recorded the frequency, the innervation and the main anatomical features of these accessory muscles.

### Different supernumerary muscles

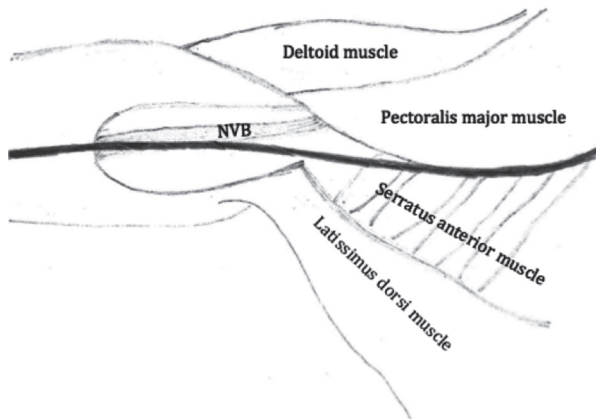
Chondroepitrochlearis muscle (Fig. 1A/B) is a rare atavistic remnant muscle that arises from one or more ribs, the pectoral major or even from the aponeurosis of the external oblique muscle, crosses the axilla, and inserts into medial humeral epicondyle. Some reports noticed this supernumerary muscle insertion into the median intermuscular septum or medial brachial fascia. In other articles the muscle is referred to as the 'costoepitrochlearis', 'chondrohumeralis' (6,15), 'thoracoepicondylaris' (21)

- Verhaegen Filip, MD.
- Debeer Philippe, MD, PhD.
- Moyaert Maximiliaan, medical student.

*Department of Development and Regeneration, KU Leuven, Division of orthopaedics, University Hospitals Leuven (campus Pellenberg), Belgium.*

Correspondence : Verhaegen Filip, Department of Development and Regeneration, KU Leuven, Division of orthopaedics, University Hospitals Leuven (campus Pellenberg), Belgium.  
E-mail : filip.verhaegen@uzleuven.be

© 2016, Acta Orthopædica Belgica.

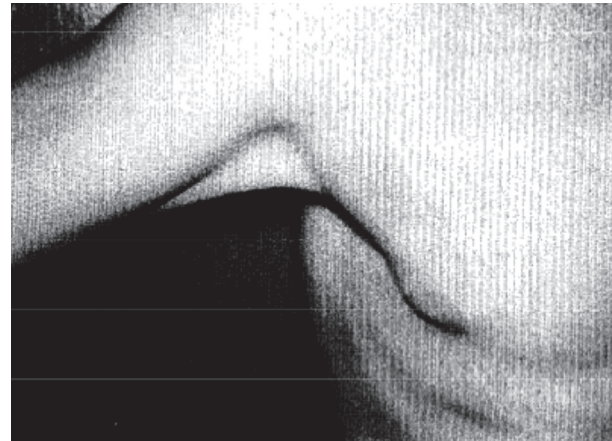


**Fig. 1A.** — An illustration of the chondroepitrochlearis muscle (the muscle is painted black). (NVB : neurovascular bundle) (“Springer and the *Breast Cancer Res Treat*, 2010, 120 : 77-82, Abnormal muscles that may affect axillary lymphadenectomy : surgical anatomy, Natsis K, Vlasis K, Totlis T *et al*, figure number 1.c, original copyright notice is given with kind permission from Springer Science and Business Media”).

or ‘pectoroepicondylaris’ (19). Some reports described nerve entrapment or restriction of arm movements due to these muscles (38,42). Like the pectoral major muscle, this muscle is an adductor (15,38). Given the dimensions of the muscle and its tendon it has probably no functional importance (15). The muscle is innervated through the medial pectoral nerve (15,16) although a case report (38) described a dual innervation : one from the median nerve and the other from the medial pectoral nerve. Some reports describe it as a unilateral finding (15,16), whereas others report bilateral occurrence (15).

Another variation is the chondrofacialis muscle (5,30), (Fig. 2A/B, 3A/B, 4A/B/C/D). It was originally described in 1875 (26) as a muscle that extends from the chondrocostal insertion of the pectoral major to the medial intermuscular septum of the arm. Nerve supply through the medial pectoral nerve.

Langer’s axillary arch (Fig. 5A/B) or axillary arch muscle is the most common variation in the axilla (11). Also called ‘pectorodorsal’ or ‘axillopectoral’ muscle (9,16,41). Although the first description of the axillary arch is attributed to Langer (24), it was Ramsay (31) in 1795 that first described this



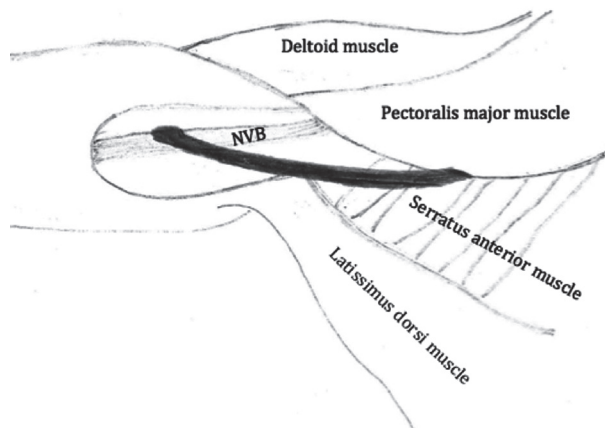
**Fig. 1B.** — Photo taken in clinics, patient with a chondroepitrochlearis muscle. “Reprinted from *J Hand Surg Br*, 16 (3), Spinner RJ, Carmichael SW, Spinner M., Infraclavicular ulnar nerve entrapment due to a chondroepitrochlearis muscle, 315, Copyright (1991), with permission from Elsevier”.

transverse muscle of the axilla (26). The incidence of the arch muscle in the general population has been reported as ranging from 0.25% to 7% (9,27,33,35). The supernumerary muscle can be unilateral or bilateral.

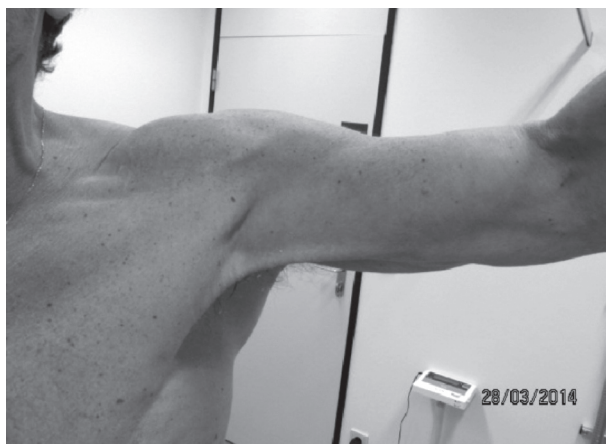The axillary arch muscle arises from the latissimus dorsi, either directly or with an interposed tendon (26). The axillary arch muscle may rarely originate from the serratus anterior muscle. The muscle has a variable insertion from the pectoral major (9) to the pectoral minor (20), coracobrachialis (36,41), short head of the biceps brachii, teres major, coracoid process (41), axillary fascia or the brachial fascia.

Testut (40) classified the axillary arch muscles as the complete (extending to the insertion of the pectoral major) and the incomplete form (extending to other structures). Important to note is that multiple insertions do exist, the existence of two (5), three or up to four (11,23) fascicles has been noted.

Nerve supply is highly variable and different patterns of innervation are described (12) : the medial pectoral nerve (36,41), the lateral pectoral nerve (2,10), the second and third intercostal nerves (35,36), the thoracodorsal nerve (17,41), the medial cutaneous nerve (35,36), the ansa pectoral and the median

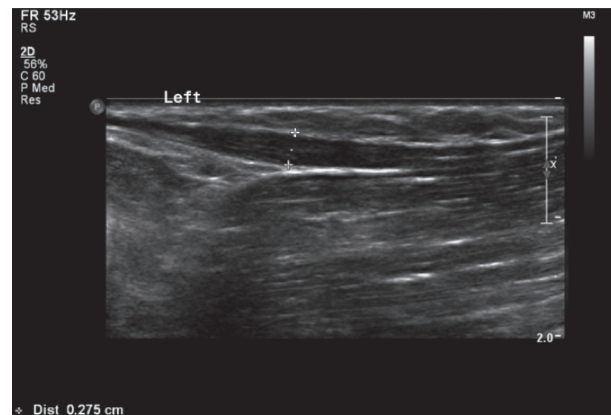


**Fig. 2A.** — An illustration of the chondrofascialis muscle (the muscle is painted black). (NVB : neurovascular bundle).

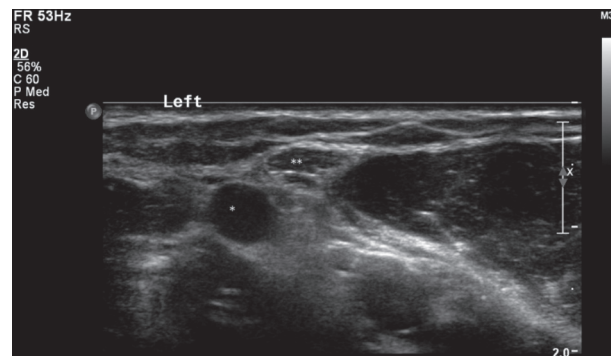


**Fig. 2B.** — Photo taken in clinics at campus Pellenberg (University Hospitals, Leuven, Belgium). Patient presented with a chondrofascialis muscle.

nerve. Using SSEMG (surface stimulodetection electromyography) Snoeck *et al* (37) wanted to investigate if there is a discordance regarding the innervation detected during dissections and the *in vivo* innervation of the axillary arch muscle. Using a small-scale patient population they described that the thoracodorsalis nerve innervated the vast majority of the axillary arch muscles. The authors (12) described that in 85% of the patients with an axillary arch, a co-contraction could be found with the latissimus dorsi muscle.

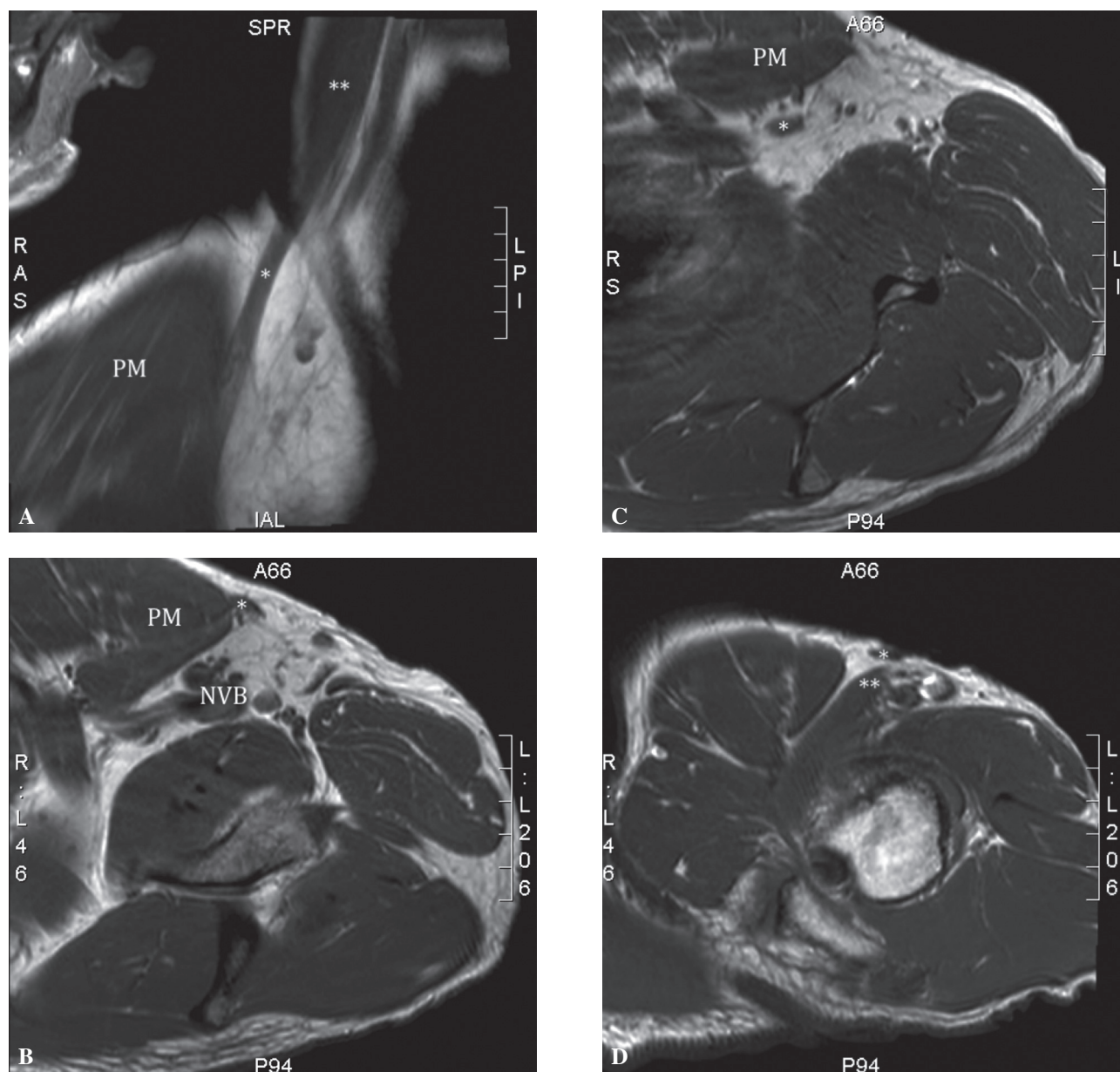


**Fig. 3A.** — An image taken when performing the ultrasound. The muscle slip measured 2.75 mm.



**Fig. 3B.** — Another sonography image, depicting the chondrofascialis muscle (marked by the white ‘\*\*’) and its relation to the neurovascular bundle (marked by the white ‘\*’).

The pectoralis quartus muscle (Fig. 6) courses along the lateral edge of the pectoral major muscle (5). Other reports are referring to ‘an abdominal part of the pectoral major’ (19). The pectoral quartus muscle, when present, has constant features, this in contrast to the axillary arch muscle with its variable origin and insertion. The muscle originates from the costochondral junctions of the fifth and sixth ribs (28), from the lateral border of the pectoral major, or from the rectus sheath (5). Then the slip runs separately or loosely connected to the pectoral major and inserts in or near the deep layer of the pectoral major tendon (5,19). There is some variation regarding the insertion. Arican *et al* (2) noted an insertion as an aponeurosis into the lateral lip of the



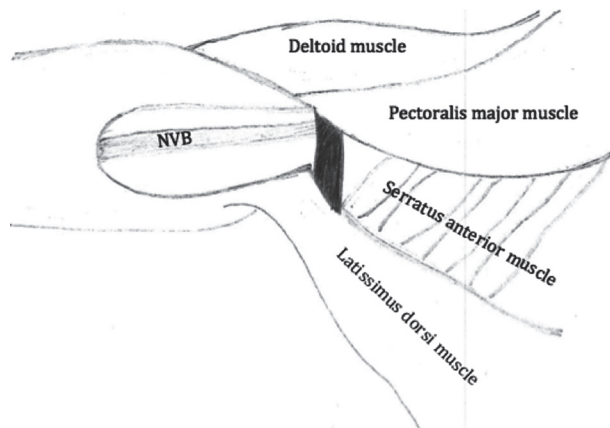
**Fig. 4.** — MRI images of the chondrofascialis muscle.

**A.** Frontal plane of the axilla, with PM : pectoral major muscle ; white “\*” : chondrofascialis muscle ; white “\*\*” : short head of biceps brachii muscle. **B.** Transversal plane of the body, with PM : pectoral major muscle ; NVB : neurovascular bundle ; white “\*” : chondrofascialis muscle. **C.** Transversal plane of the body, with PM : pectoral major muscle ; white “\*” : chondrofascialis muscle. **D.** Transversal plane of the body, with white “\*” : chondrofascialis muscle ; white “\*\*” the short head of biceps brachii muscle. The chondrofascialis muscle eventually forms a fascia and flows over into the fascia of the biceps muscle.

intertubercular groove, and also as a tendon into the short head of the biceps brachii muscle (19). The muscle is innervated by fibers of the medial pectoral nerve (8). A single report describes the innervation of the muscle by the fourth intercostal nerve (17).

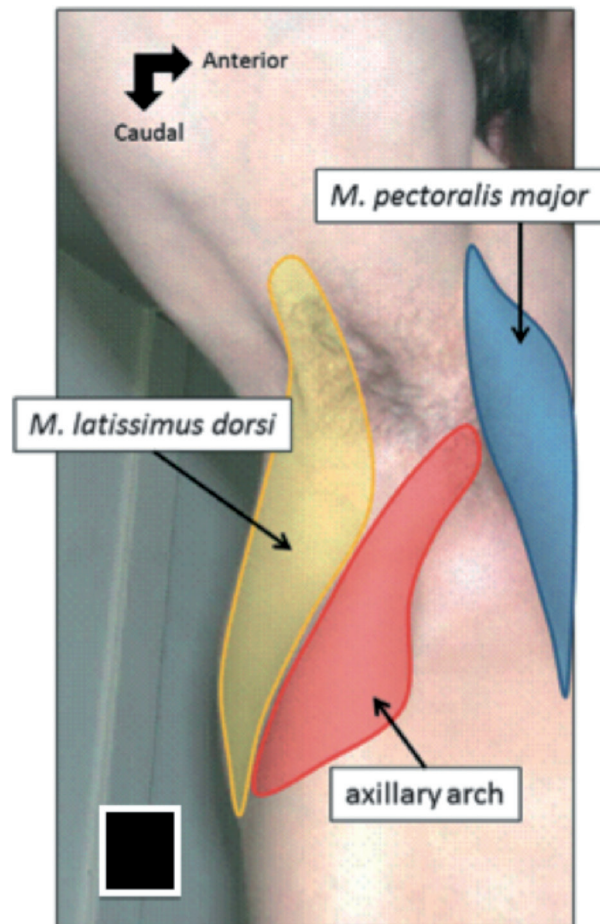
### Clinical implications

Signs and symptoms consistent with upper extremity neurovascular compression, similar to thoracic outlet syndrome can occur (33), especially



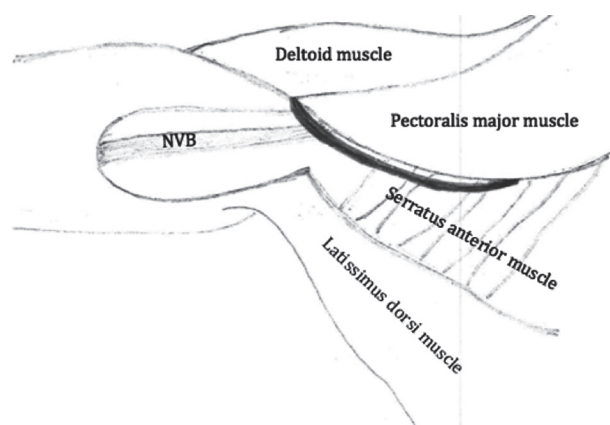
**Fig. 5A.** — An illustration of the axillary arch muscle, the complete form(37) (the muscle is painted black). (NVB : neurovascular bundle) (“Springer and the *Breast Cancer Res Treat*, 120, 2010, 77-82, Abnormal muscles that may affect axillary lymphadenectomy : surgical anatomy, Natsis K, Vlasis K, Totlis T *et al*, figure number 1.a, original copyright notice is given with kind permission from Springer Science and Business Media”).

when there is an anterior crossing of the axillary neurovascular bundle (23,33,41). In this situation an abduction and external rotation of the shoulder would compress the bundle. Logically a test consistent with a Tinel test that can reproduce the symptoms should be introduced in the skills of a clinician. A few reports make note of axillary vein compression with resulting swelling, discoloration and subsequent upper extremity lymphedema (24,31). Occurrence of the muscle slip may falsely lead to believe there is a subcutaneous tumour (34) or give the impression of swollen axillary lymph nodes. Clinicians should be aware of the presence of the anomalous muscle, when there are visible and palpable changes, such as a fullness of the axilla, with loss of the normal concavity of the axilla in abduction or elevation (33). The arch muscle is found incidentally during an axillary lymphadenectomy (16). Thorough knowledge of these aberrant muscles is important as to perform safe axillary surgery. Through their course they cover the lateral group of nodes, therefore inadequate clearance of the nodes can occur, the latter having a serious implication for local recurrence and local morbidity, namely lymphedema. When noticed during surgery, the dividing of the aberrant muscle is considered the best solution to prevent further compression problems or



**Fig. 5B.** — Photo taken in clinics, patient presenting with an axillary arch muscle. (Reprinted from [The innervation of the axillary arch determined by surface stimulodetection electromyography. / Snoeck T, Balestra C, Calbersson F, Pouders C and Probyn S. / *J Anat* 212/Issue p 275-278. Copyright (c) [2012] [copyright owner as specified in the Journal and John Wiley and Sons]).

limitation of shoulder movement due to contracture (25). Another clinical implication of the axillary arch muscle presents itself when taking mammograms for breast cancer screening. The muscle is frequently seen as a thick band-like structure of the axilla, overlapped with the pectoral major on a medio-lateral oblique projection. Some muscles resemble an ovoid density that could confuse the clinician into believing it's an aberrant mass. It's important that these normal variants are recognized. If concerned, and there are no clinical symptoms or



**Fig. 6.** — An illustration of the pectoralis quartus muscle (the muscle is painted black). (NVB : neurovascular bundle) (“Springer and the *Breast Cancer Res Treat*, 2010, 120 : 77-82, Abnormal muscles that may affect axillary lymphadenectomy : surgical anatomy, Natsis K, Vlasis K, Totlis T *et al*, figure number 1.b, original copyright notice is given with kind permission from Springer Science and Business Media”).

signs, a CT or MRI is helpful for further investigation (18). Another important note is the implication of supernumerary muscle in reconstructive surgery. The latissimus dorsi muscle is extremely useful as a reconstructive tool. Its versatility in transfer as a muscular or myocutaneous flap permits the surgeons to close a variety of difficult and complex wounds of the trunk and arm (23). Variations of the latissimus dorsi muscle may cause problems during or after surgery if overlooked.

### Phylogenetic origin

Accessory muscles of the axilla have mainly been ascribed as an abnormal development of the pectoral mass or latissimus dorsi (30). The pectoral musculature is derived from the dorsal limb bud masses. The myoblasts arise from the C4-C8 myotomes during the fifth week of development. After splitting into pectoral minor and the sternocostal part, the muscles are finally formed through a process of migration, fusion, but also apoptosis of cell precursors (1,39).

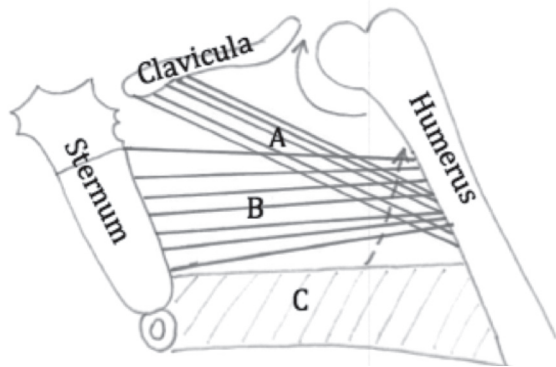
It is clear that during the different stages of myogenesis, accessory muscles could be formed due to altered migration of muscle cell precursors or incomplete apoptosis (21). We assembled proof that

this hypothesis, addressing accessory muscles as atavistic remnants present in lower mammal quadrupeds, reveals most likely the origin.

In lower mammal quadrupeds the pectoral minor inserts largely onto the superior end of the humerus, with the pectoral major extending along the humerus and reaching the medial epicondyle. Through evolution muscles are redefined in humans. The process can be summarised as followed (Fig. 7) : a cranial migration of the pectoral minor muscle towards the coracoid process. Therefore the most caudal part of insertion of the pectoral major migrated to replace the minor muscle onto the superior part of the humerus.

This explains the twisted tendon insertion of the pectoral major muscle. The chondroepitrochlearis is then in fact a remnant of the most inferior insertion part of the pectoral major, it thereby explains why a common feature noticed with these aberrant slips is the absence of the tendon twist of the pectoral major muscle (15,22) as these caudal fibres are in fact the same fibres that normally twist beneath the clavicular part of the pectoral major to insert high on the humerus (30). The chondroepitrochlearis muscle was dissected at autopsy in patients with chromosomal defects (trisomy 13 with a D/D translocation (3) and trisomy 18 (7)). The patients with trisomy 13 had several supernumerary muscles, including muscles like pectoro-dorsalis and chondroepitrochlearis. We could assume that the genetic code for these muscles is repressed during embryogenesis and that these chromosomal defects cause the unblocking and activation of these genetic loci (3,4).

The other hypothesis contributes the supernumerary muscles as homologous to muscles found in birds : the extensor plicae alaris (29). The extensor plicae alaris muscle consist in fact of two muscles called *tensores patagii longus* and *brevis*, and have a different innervation in comparison to the chondroepitrochlearis muscle. The chondroepitrochlearis is innervated by the medial pectoral nerve (derived from the anterior division). The *tensores patagii* muscles are innervated by fibres from the posterior division (14,30). Another opinion is that the accessory muscles are derived from a *panniculus carnosus* muscle. The *panniculus carnosus* muscle



**Fig. 7.** — Illustration of the cranial migration of the pectoralis minor muscle presented by the full arrow. A is the clavicular part of the pectoralis major muscle, B the sternocostal and C is the most caudal origo of the muscle. The interrupted arrow shows the superior migration of the caudal part of the pectoralis major muscle (represented by C).

is defined as a layer of striated skin-associated muscle, beneath the subcutaneous adipose tissue (34). In humans the platysma muscle of the neck, palmaris brevis in the hand, and the dartos muscle in the scrotum are described as a discrete muscle of the panniculus carnosus. When regarding the supernumerary muscle as the panniculus carnosus some notes can be made. The latter has no deep insertion (21,30,32) and no reason can be given why there would be a shift from the undersurface of the skin to the medial epicondyle. Discussion remains, as some authors regard another supernumerary muscle, the axillary arch muscle as a remnant of the panniculus. A remnant of the panniculus carnosus muscle originates embryological from the pectoral muscles, yet most axillary arch muscles are innervated through the fibres of the thoracodorsalis nerve, considering a derivation from the posterior division. Though it seems obvious, further phylogenetic research needs our attention.

## CONCLUSION

The axilla is a relatively small pyramidal compartment between the thoracic wall and the arm, which contains muscles and vital neurovascular bundles. This area is known for its variable presentation in vessels, nerves and muscles. A sound

anatomical knowledge of the different structures is important for assessing its clinical and morphological influences. The different types of anomalous muscles should be born in mind when patients present themselves with compression neuropathies and syndromes related to the upper arm, in surgical interventions involving the axillary fossa, and in experimental studies aimed at alternative use of the latissimus dorsi muscle in many clinical applications.

## REFERENCES

1. **Al Qattan MM, Yong Y, Kpin SH.** Embryology of the upper limb. *J Hand Surg* 2009 ; 34 : 1342.
2. **Arıcan RY, Coskun N, Sarıkcıoğlu L, Sindel M, Oguz N.** Co-existence of the pectoralis quartus and pectoralis intermedius muscles. *Morphologie* 2006 ; 90 : 157-159.
3. **Aziz MA.** Anatomical defects in a case of trisomy 13 with a D/D translocation. *Teratology* 1980 ; 22 : 217-227.
4. **Barash BA, Freedman L, Opitz JM.** Anatomical studies in the 18-trisomy syndrome. *Birth defects, Original Article Series* 1970 ; V1, 3-15.
5. **Barcia JM, Genovés JM.** Chondrofascialis Versus Pectoralis Quartus. *Clin Anat* 2009 ; 22 : 871-872.
6. **Bergman RA, Thompson SA, Afifi AK, Saadeh FA.** Compendium of Human Anatomic Variation. München, Baltimore : Urban & Schwarzenberg, 1988.
7. **Bersu ET, Ramirez-Castro JL.** Anatomical analysis of the developmental effects of aneuploidy in man--the 18-trisomy syndrome : II. Anomalies of the upper and lower limbs. *Am J Med Genet* 1978 ; 2 : 285-306.
8. **Birmingham A.** Homology and innervation of the achselbogen and pectoralis quartus, and the nature of the lateral cutaneous nerve of the thorax. *J Anat Physiol* 1889 ; 23 : 206-223.
9. **Bonastre V, Rodriguez-Niedenführ M, Choi D, Sanudo JR.** Coexistence of a Pectoralis Quartus Muscle and an unusual axillary arch : case report and review. *Clin Anat* 2002 ; 15 : 366-370. doi : 10.1002/ca.10053
10. **Clarys JP, Provyn S, Cattrysse E, Snoeck TH, Van Roy P.** The role of the axillary arch (of Langer) in the management and the kinesiology of the overhead shoulder mobility. *J Sports Med Phys Fitness* 2008 ; 48 : 455-465.
11. **Daniels IR, Querci della Rovere G.** The axillary arch of Langer – the most common muscular variation in the axilla. *Breast Cancer Res Treat* 2000 ; 59 : 77-80.
12. **Dubreuil-Chambardel L.** De l'innervation de quelques muscles de la région thoracique. *Bull Mem Soc Anthropol Paris* 1926 ; 7 : 121-125.
13. **Dunlap SS, Aziz MA, Rosenbaum KN.** Comparative anatomical analysis of human trisomies 13, 18 and 21 : 1. The forelimb. *Teratology* 1986 ; 33 : 159-86.

14. **Fisher H.** Adaptations and comparative anatomy of the locomotor apparatus of the New World vultures. *Am Midl Nat* 1946 ; 35 : 545-727.
15. **Flaherty G, O'neill MN, Folan-Curran J.** Correspondence : case report : bilateral occurrence of a chondroepitrochlearis muscle. *J Anat* 1999 ; 194 : 313-315.
16. **Jaijesh P.** Unilateral appearance of a chondro-epitrochlearis muscle – a case report. *Indian J Plast Surg* 2005 ; 38 : 164-166.
17. **Kalaycioglu A, Gtimitisalan Y, Ozan H.** Anomalous insertional slip of latissimus dorsi muscle : arcus axillaris. *Surg Radio Anat* 1998 ; 20 : 73-75.
18. **Ko K, Han BK, Shin JH et al.** Case report : the axillopectoral muscle seen on mammography. *Clinical Radiology* 2006 ; 61 : 625-629.
19. **Kotian SR, Kumar MR.** Pectoro-epicondylaris : a rare extension of the pectoralis major muscle. *Rev Arg de Anat Clin* 2013 ; 5 : 29-32.
20. **Kutiyanawala MA, Stotter A, Windle R.** Anatomical variants during axillary dissection. *Br J Surg* 1998 ; 85 : 393-394.
21. **Lama P, Tamang BK.** A common insertion of thoraco-epicondylaris and an axillary arch of Langer : a case report. *IJAV* 2010 ; 3 : 63-64.
22. **Landry SO.** The phylogenetic significance of the chondroepitrochlearis muscle and its accompanying pectoral abnormalities. *J Anat* 1958 ; 92 : 57-61.
23. **Langer C.** Zur Anatomie des Musculus latissimus dorsi (Schluss). *Oesterreichische Med Wochenschrift* 1864b ; 16 : 486-491.
24. **Langer C.** Zur Anatomie des Musculus latissimus dorsi. *Oesterreichische Med Wochenschrift* 1864a ; 15 : 454-458.
25. **Lin C.** Contracture of the chondroepitrochlearis and the axillary arch muscles. *J Bone Joint Surg Am* 1988 ; 70A : 1404-1406.
26. **Macalister A.** Additional observations on muscular anomalies in human anatomy with a catalogue of the principal muscular variations hitherto published (third series). *Trans Roy Irish Acad Sci* 1875 ; 25 : 1-134.
27. **Merida-Velasco JR, Rodriguez Vazquez JF, Merida-Velasco JA, Sobrado Perez J, Jimenez Collado J.** Axillary arch : potential cause of neurovascular compression syndrome. *Clin Anat* 2003 ; 16 : 514-519.
28. **Natsis K, Vlasis K, Totlis T et al.** Abnormal muscles that may affect axillary lymphadenectomy : surgical anatomy. *Breast Cancer Res Treat* 2010 ; 120 : 77-82.
29. **Perrin JB.** Notes on some variations of the pectoralis major, with its associate muscles. *J Anat Physiol* 1871 ; 5 : 233-244.
30. **Porzionato A, Macchi V, Stecco C et al.** Surgical anatomy of the pectoral nerves and the pectoral musculature. *Clin Anat* 2012 ; 25 : 559-575.
31. **Ramsay A.** Account of unusual conformations of some muscles and vessels. *Edinburgh Med Surg J* 1812 ; 8 : 281-283.
32. **Ruge G.** Der Hauttrumpfmuskel des Menschen. *Gegenbaur's Morphol Jahrb.* 1914 ; 48 : 1-57.
33. **Sachatello CR.** The axillopectoral muscle (Langer's axillary arch) : a cause of axillary vein obstruction. *Surgery* 1977 ; 81 : 610-612.
34. **Saitta GF, Baum V.** Langer's axillary arch. An unusual cause of axillary mass. *JAMA* 1962 ; 180 : 690.
35. **Serpell JW, Baum M.** Significance of 'Langer's axillary arch' in axillary dissection. *Aust N Z J Surg* 1991 ; 61 : 310-312.
36. **Smith AR, Cummings JP.** The axillary arch : anatomy and suggested clinical manifestations. *J Orthop Sports Phys Ther* 2006 ; 36 : 425-429.
37. **Snoeck T, Balestra C, Calberson F, Pouders C, Provyn S.** The innervation of the axillary arch determined by surface stimulodetection electromyography. *J Anat* 2012 ; 212 : 275-278.
38. **Spinner RJ, Carmichael SW, Spinner M.** Infraclavicular ulnar nerve entrapment due to a chondroepitrochlearis muscle. *J Hand Surg Br* 1991 ; 16 : 315-7.
39. **Sweeney LJ.** Basic concepts in embryology. *McGraw-Hill* 1998, 136-138.
40. **Testut L.** Les anomalies musculaires chez l'homme expliquées par l'Anatomie Comparée et leur importance en Anthropologie. *Paris :Masson* 1884, 107-116.
41. **Turgut HB, Peker T, Gülekon Nja, Anil A, Karaköse M.** Axillopectoral Muscle (Langer's Muscle). *Clin Anat* 2005 ; 18 : 220-223.
42. **Voto SJ, Weiner DS.** The chondroepitrochlearis muscle. *J Pediatr Orthop* 1987 ; 7 : 213-214.