



Evaluation of the metaphyseal ulnar shortening technique according to Sennwald

Joris BECKERS, Bertram THE, Ilse DEGREEF, Luc DE SMET

From the Department of Orthopaedic Surgery, University Medical Center Leuven, Belgium

The outcome of a metaphyseal ulnar shortening osteotomy, reported by Sennwald as an alternative option for ulnar abutment syndrome, was evaluated with regard to the functional results, pain relief and incidence of complications.

Methods : We conducted a review of 12 patients ; measured parameters were DASH score, PRWE, VAS for pain, grip force and wrist motion.

Results : Only disability improved significantly with a DASH score of 42 ($p = 0.03$). The function and pain assessment scores did not improve in 3 patients. We found no correlation between change in functional scores and other measured variables. Six patients were reoperated for prominent screw heads or new-onset distal radioulnar joint osteoarthritis.

Conclusion : All osteomies healed fast and uneventfully and disability improved in most patients but 25% did not improve and 50% were re-operated. Further investigation is needed to evaluate the value of the metaphyseal osteotomy as an alternative treatment for ulnar abutment syndrome.

Keywords : ulnar abutment ; metaphyseal ; diaphyseal ; ulnar shortening.

INTRODUCTION

Ulnar impaction or abutment syndrome is a degenerative condition characterized by ulnar-sided wrist pain, decreased grip strength and sometimes a reduced range of movement, related to excessive loads and impingement across the ulnocarpal joint (3,4,5,8). Although abutment syndrome may occur in any wrist, it is usually associated with a positive ulnar variance, either congenital or acquired (12).

Joint decompression in ulnar abutment usually is considered if the ulna is longer than the radius and the lunate bone shows signs of abutment. Ulnar abutment is most typically identified by edema on an MRI scan or chondral lesions in wrist arthroscopy. Arthroscopic triangular fibrocartilage complex (TFCC) debridement alone has a success rate of 70-75%. TFCC debridement and removal of the distal ulna (Feldon wafer resection) has an 85% chance of excellent outcome with good pain relief, most

-
- Joris Beckers, MD, Resident Orthopaedic Surgery.
 - Bertram The, MD, PhD, Fellow Hand Surgery.
 - Ilse Degreef, MD, PhD, Surgeon-in-chief.
 - Luc De Smet, MD, PhD, Surgeon-in-chief.
- Department of orthopaedic surgery, University Medical Center Leuven.*
- Correspondence : Joris Beckers, Spaanse Lindebaan 162, 1850 Grimbergen, Belgium.
E-mail : joris.beckers@student.kuleuven.be
© 2016, Acta Orthopædica Belgica.
-

All named authors hereby declare that they have no conflicts of interest to disclose.

This research received no specific grant from any funding agency in the public, commercial, or not-for-profit sectors. This study has been considered scientifically relevant and has been ethically approved by the commission on medical ethics of the University of Leuven.

reliably in isolated cases without a history of wrist fracture (1,7).

An alternative which does not violate the distal ulnar articular surface, as well as the TFCC is the ulnar shortening osteotomy.

Different techniques for extra-articular ulnar shortening osteotomy have been described. Transverse and oblique diaphyseal ulnar shortening osteotomies each have their specific problems: rotational control is difficult to obtain using transverse cuts and gliding problems or difficulty to get the exact desired amount of shortening have been reported with oblique cuts (3,11). Darlis *et al* suggested a step-cut diaphyseal ulnar osteotomy, which prevents rotational problems and permits the combined use of a lag screw and plating but requires careful handling to avoid fractures at the site of the hemi-section of the ulna (2).

A more general downside of diaphyseal ulnar osteotomy techniques is the necessity to plate the ulna. The hardware needs to be removed in 25-88% of all the cases because of persisting plate-related symptoms (16). In one of our previous cohorts comparing arthroscopic wafer resection to diaphyseal ulnar shortening for ulnar impaction syndrome 5 out of 25 patients needed plate removal due to persisting pain, 3 other patients needed iliac crest bone grafting due to nonunion (15).

Sennwald introduced a curved metaphyseal osteotomy for open TFCC repair in 1995. He based his technique on the similar ulnar lengthening technique as described by Comtet in 1981 and reported improved results of open TFCC repair if shortening of the ulna was added. In addition, the curved aspect of the osteotomy prevents translation of the distal fragment. Recently, Sennwald reported his results in 16 patients and compared them with 13 patients treated with a step-cut diaphyseal ulnar osteotomy. Healing was faster in the metaphyseal osteotomy (7 weeks) as compared to the diaphyseal osteotomy (3 months). The plates were routinely removed in the diaphyseal group, whereas no screws were removed in the metaphyseal group. However, the proportion of patients with good or excellent results was similar in both groups defined by surgery. On top, shortening was significantly greater in the metaphyseal group (13).

Aim of the study

The aim of this retrospective study was to evaluate the outcome of Sennwald's metaphyseal ulnar shortening osteotomy in our patient population, since we found no other independent papers on this new technique.

METHODS AND MATERIALS

Patients

We invited all patients who were treated with the metaphyseal ulnar shortening between July 2010 (when we introduced this new technique at our department) and February 2013 in our institution to participate in this follow-up study. A total of 16 patients (7 males, 9 females) were contacted. One patient was lost to follow-up. In order to attain a homogenous cohort, 3 patients with ulnar abutment symptoms due to other, more complex pathologies (e.g. Essex-Lopresti lesion, radiocapitellar joint arthroplasty) were excluded. Nine patients (Patient 1-9) agreed to participate in the clinical part of our study. Three patients (Patient 10-12) were not able to be present at the study consultation but filled in the postoperative QuickDASH form. Mean follow-up was 25 months (range 8-40). The average age was 36 years (range 22-64). All patients had established ulnar abutment syndrome as demonstrated with MRI or arthroscopy. Two patients were active smokers. In 3 patients both wrists were treated. Six patients suffered a minor trauma prior to the onset of the ulnar abutment syndrome. Five patients underwent wrist arthroscopy prior to the ulnar shortening osteotomy.

The results were graded using the mean Disabilities of the Arm, Shoulder, and Hand (QuickDASH) and Patient Rated Wrist Evaluation (PRWE) score, a Visual Analogue Scale (VAS) score for pain, range of motion, grip strength using a Jamar dynamometer (Lafayette Instrument Company, Inc, Indiana, USA) and return to work.

Patients who were not able to join us for the postoperative study consultation were contacted by telephone to obtain their QuickDASH score. Postoperative QuickDASH scores implicate the scores that were obtained after the last performed surgical procedure (e.g. removal of prominent screws).

Since the routine postoperative consultations included X-rays until consolidation of the osteotomy site, no complementary imaging was required.

Preoperative and postoperative ulnar variances were measured using the method of perpendiculars and sigmoid notch inclination was determined for each wrist. Following this method of perpendiculars, the ulnar variance is the distance between the distal cortical rim of the ulnar head and a line, perpendicular to the longitudinal axis of the radius (10,14). Any complication following the osteotomy was recorded.

Operation technique

Either a regional block or general anaesthesia was used. The patient was positioned supine with his arm resting on an arm table and an upper arm tourniquet. A longitudinal skin incision centred over the dorsum of the ulnar head was used. The extensor retinaculum was incised to expose the tendon of the extensor digiti minimi which was retracted radially. The extensor carpi ulnaris (ECU) was left undisturbed while mobilizing its com-

partment, retracting it ulnarwards. The joint capsule was opened and the ulnar head exposed. An oblique osteotomy was performed with a small oscillating saw, after the ulnar styloid process and the DRUJ were identified. The resulting distal fragment was then shifted proximally. Two self-tapping lag screws (1.5 or 2 mm) were used depending upon clinical estimation of the size of the ulnar head (Fig. 1).

After layered closure of capsula, retinaculum and skin, a sterile dressing was applied (13). Patients were encouraged to use active non-resistive exercises of the entire upper limb within the limits of comfort from the first postoperative day on. At 6 weeks, resistive activities were allowed, with unrestricted use at 12 weeks.

Statistics

To compare the two sample groups, defined as failure (postoperative QuickDASH score greater than

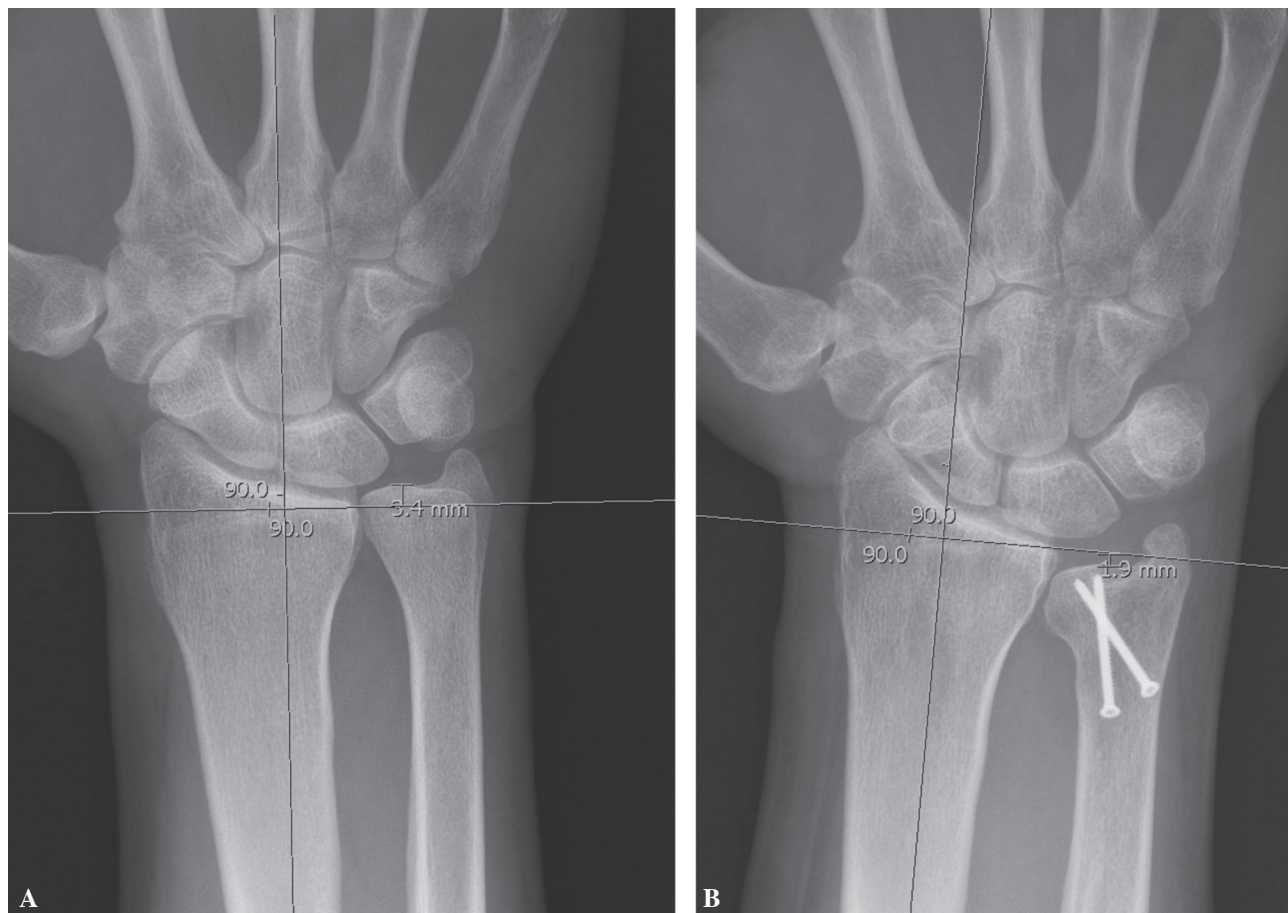


Fig. 1. — Ulnar variance postoperatively (B) versus preoperatively (A)

Table I. — VAS (0-10), DASH (0-100), PRWE (0-100). Low scores indicate less pain (VAS) and better functionality (DASH, PRWE)

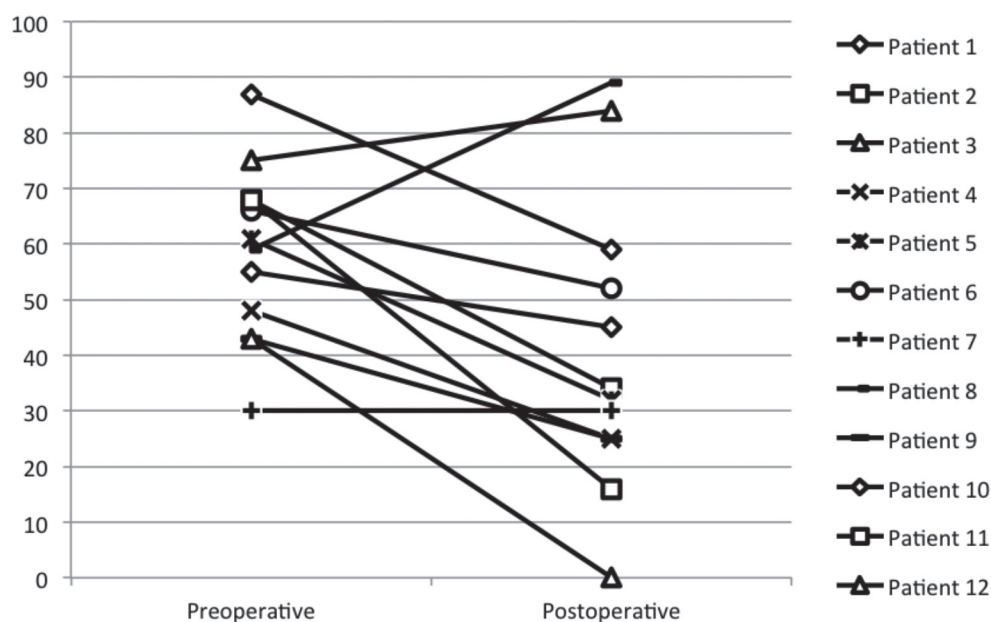
1.	7	55	45	47
	5	/	/	/
2.	5	68	34	54
3.	7	75	84	80
4.	5	48	25	40
5.	2	61	32	40
6.	5	66	52	49
	/	/	/	/
7.	2	30	30	38
8.	9	59	89	84
9.	6	43	25	42
10.	/	87	59	/
11.	/	68	16	/
12.	/	43	0	/
Mean	5	59	41	53

preoperative QuickDASH score) and success (postoperative QuickDASH score less than preoperative QuickDASH score), we used a 2 sample t-test for equal means and Chi-square tests. The variables were compared using the Pearson correlation coefficient. A p-value lower than 0,05 was considered significant.

RESULTS

VAS, PRWE and pre- and postoperative QuickDASH scores are summarized in table I, the shift from pre- to postoperative QuickDASH scores has been outlined in graph I. The mean postoperative VAS score was 5 (SD 2.1), mean preoperative QuickDASH-score 55 (SD 15.1), mean postoperative QuickDASH score 42 (SD 23.01) (p-value 0.03) and mean PRWE score 53 (SD 16.4). No correlation was found between improvement in QuickDASH score and any other variable. A subgroup analysis between the unsuccessful patients (defined by either no improvement or deterioration of the QuickDASH score) and the successful patients revealed no differences with regard to age, BMI, length of follow-up, traumatic origin of symptoms, frequency of and number of previous surgical treatments, preoperative ulnar variance or postoperative amount of shortening, or DRUJ inclination. All osteotomies united within 12 weeks after surgery.

Postoperative grip strength and range of motion were measured in relation to the uninvolved side (Table II). Mean postoperative grip strength was 77% in comparison to the uninvolved side.



Graph I. — Shift from pre- to postoperative QuickDASH scores

Table II. — Data of the involved side in relation to the uninvolved side (in percent). Patient 1 and 7 have been operated bilaterally; the first treated wrist was compared to the last treated wrist

Patient	Grip strength	Flexion	Extension	Uln. Dev.	Rad. Dev.	Pronation	Supination
1.	83	100	109	57	100	100	100
2.	92	93	86	100	100	100	100
3.	83	136	70	83	200	94	108
4.	46	100	100	100	100	88	100
5.	109	88	88	88	83	100	94
6.	89	88	93	100	100	88	78
7.	48	100	67	33	50	69	53
8.	49	80	100	100	50	81	100
9.	95	94	100	88	100	72	100
Mean	77	98	90	83	98	88	93

Radiologic findings are summarized in table III. Mean shortening was 3.4 mm, calculated with the method of perpendiculars.

Six patients have had a reoperation because of prominent screw heads ; unfortunately this resulted

in pain relief in only 2 of them. Two patients developed severe DRUJ-arthritis, 1 of them was successfully treated with a DRUJ prosthesis.

Two patients were not able to return to their initial level of employment. Eight patients returned

Table III. — Variances in mm, sigmoid notch inclination in degrees (positive values mean that the distal end of the sigmoid notch is oriented towards the radius)

Patient	Preoperative variance	Postoperative variance	Shortening	DRUJ inclination
1.	1.5	-0.3	1.8	6
	1.95	-3.2	5.15	4.8
2.	1.75	-1.55	3.3	4
3.	1.75	-1.3	3.05	-8.6
4.	0.45	-3.45	3.9	0.2
5.	3.75	0.85	2.9	6.1
6.	0	-1.85	1.85	15.1
	3	-2.4	5.4	16.4
7.	2.65	0.9	1.75	18.7
8.	2.9	-1.7	4.6	-2.2
9.	3.35	-0.9	4.25	2.2
10.	1.4	-1.1	2.5	0.8
11.	2.1	-1.8	3.9	1.5
12.	0.5	-1.6	2.1	2.8
	3.7	1.3	2.4	14.8
Mean	2.1	-1.2	3.3	5.5

to work after a mean recovery period of 3 months. Two patients were unemployed pre- and postoperatively.

DISCUSSION

Our goal was to evaluate the results of the metaphyseal ulnar shortening osteotomy in our patient population suffering from ulnar abutment syndrome. Taking the pre- and postoperative Quick-DASH-score into account, the postoperative outcome was unsatisfying in 25% of the patients (3 in 12). Unfortunately, we were unable to identify a single variable to predict a poor result. For instance, no significant difference in postoperative outcome was seen in congenital or acquired (i.e. traumatic) ulna plus variance and no evidence was found for any impact of sigmoid notch inclination.

The lag screws were removed in 6 patients due to prominent screw heads. One patient was successfully treated with a DRUJ prosthesis due to new onset DRUJ arthritis and instability. Sennwald reported an excellent outcome in 13 of 16 patients without any need for secondary surgery.

The strength of this study is that it is an independent report (not involving the original author of this technique) on a new technique. The study population, although as limited in numbers as were the previous reports by Sennwald, was followed clinically and radiologically with a mean 2 year follow-up. Every included patient had proven ulnar impaction syndrome (MRI or arthroscopy). Patients suffering from ulnar abutment due to complex posttraumatic pathologies were excluded to attain a homogenous patient cohort. A weakness is the small study population.

More conventional methods such as arthroscopic TFCC debridement and arthroscopic wafer resection have been proven very successful and less invasive for isolated cases with established TFCC tears, minimal positive ulna variance and absence of previous wrist fractures (1,7).

In our population 5 out of 12 patients underwent wrist arthroscopy previous to the metaphyseal ulnar shortening osteotomy, postoperative DASH-scores decreased in 4 out of 5 patients.

Other metaphyseal shortening osteotomies (e.g. closing wedge osteotomy or distal ulnar hook plate (6,9) have shown their value in the treatment of ulnar abutment syndrome but to our knowledge no randomised trial to compare the different osteotomy techniques for ulnar abutment is available yet.

CONCLUSION

In our population, a modest improvement in functional scores was obtained but 1 in 4 patients did not improve after surgery. We could not identify a variable that was predictive of a good or poor result. In all cases however union was uneventfully and wrist motion was preserved. Prominence of the screw heads and penetration into the DRUJ is a frequent complication and cautious screw orientation is mandatory in order to prevent persisting pain and the need for reoperation. Further investigation is needed to evaluate the metaphyseal distal ulnar shortening osteotomy as a valuable first-line alternative to more common treatment options.

REFERENCES

1. **Bickel KD.** Arthroscopic treatment of ulnar impaction syndrome. *J Hand Surg Am* 2008 ; 33 : 1420-3.
2. **Darlis NA, Ferraz IC, Kaufmann RW, Sotereanos DG.** Step-cut distal ulnar-shortening osteotomy. *J Hand Surg Am* 2005 ; 30 : 943-8.
3. **Darrow JC Jr, Linscheid RL, Dobyns JH, Mann JM 3rd, Wood MB, Beckenbaugh RD.** Distal ulnar recession for disorders of the distal radioulnar joint. *J Hand Surg Am* 1985 ; 10 : 482-91.
4. **Friedman SL, Palmer AK.** The ulnar impaction syndrome. *Hand Clin* 1991 ; 7 : 295-310.
5. **Friedman SL, Palmer AK, Short WH, Levinsohn EM, Halperin LS.** The change in ulnar variance with grip. *J Hand Surg Am* 1993 ; 18 : 713-6.
6. **Hammert WC, Williams RB, Greenberg JA.** Distal Metaphyseal Ulnar-Shortening Osteotomy : Surgical Technique. *J Hand Surg Am* 2012 ; 37 : 1071-7.
7. **Meftah M, Keefer EP, Panagopoulos G, Yang SS.** Arthroscopic wafer resection for ulnar impaction syndrome : prediction of outcomes. *Hand Surg* 2010 ; 15 : 89-93.
8. **Moermans A, Degreef I, De Smet L.** Ulnar shortening osteotomy for ulnar idiopathic impaction syndrome. *Scand J Plast Reconstr Surg Hand Surg* 2007 ; 41 : 310-314.
9. **Nunez FA Jr1, Barnwell J, Li Z, Nunez FA Sr.** Metaphyseal ulnar shortening osteotomy for the treatment

- of ulnocarpal abutment syndrome using distal ulna hook plate : case series. *J Hand Surg Am* 2012 ; 37 : 1574-9.
10. **Palmer AK, Glisson RR, Werner FW.** Ulnar variance determination. *J Hand Surg Am* 1982 ; 7 : 376-9.
 11. **Rayhack JM, Gasser SI, Latta LL, Ouellette EA, Milne EL.** Precision oblique osteotomy for shortening of the ulna. *J Hand Surg Am* 1993 ; 18 : 908-18.
 12. **Sammer DM, Rizzo M.** Ulnar impaction. *Hand Clin* 2010 ; 26 : 549-57.
 13. **Sennwald G, Della Santa D, Beaulieu JY.** A comparison of diaphyseal and metaphyseal techniques of ulna shortening. *J Hand Surg Eur Vol* 2013 ; 38 : 542-9.
 14. **Steyers CM, Blair WF.** Measuring ulnar variance : a comparison of techniques. *J Hand Surg Am* 1989 ; 14 : 607-12.
 15. **Vandenberge L, Degreef I, Didden D, Moermans A, Koorneef P, De Smet L.** Ulnar shortening or arthroscopic wafer resection for ulnar impaction syndrome. *Acta Orthop Belg* 2012 ; 78 : 323-326.
 16. **Wehbé MA, Cautilli DA.** Ulnar shortening using the AO small distractor. *J Hand Surg Am* 1995 ; 20 : 959-64.