



## Press-fit versus threaded acetabular cups in total hip arthroplasty : Functional and radiological results after five years

Martin ELLENRIEDER, Rainer BADER, Philipp BERGSCHMIDT, Wolfram MITTELMEIER

*From the Department of Orthopaedics, University Medicine Rostock*

**Prospectively the outcome after total hip replacement with a new threaded acetabular cup design was compared to an established press-fit cup.**

**After 1, 2 and 5 years, the 36-item Short Form Health Survey, Western Ontario and McMaster University Osteoarthritis Index and Harris Hip Score revealed no significant differences between the two groups (each group : n = 42 patients), except for a higher Harris Hip Score in the threaded cup group after five years (p = 0.02). After five years, one threaded cup had a mild radiolucent line without further signs of loosening. All other cups of both groups (98.6%) showed a full osseous integration. The cup inclination angle ranged from 41-58° (threaded cups) to 39-77° (press-fit cups). The new threaded cup provides equivalent clinical outcomes and osseous integration but more precise implant positioning compared to the press-fit design. No complications typically ascribed to threaded cups (acetabular fractures, bone resorption, nerve impairment) occurred.**

**Keywords :** hip ; prosthesis ; cup ; cementless ; outcome.

### INTRODUCTION

Cementless acetabular cups were introduced in the 1970s to avoid the aseptic loosening found in cemented polyethylene (PE) cups which has been attributed to 'cement disease' (29). However, revision surgery after total hip replacement (THR) due to complications with the acetabular cup is currently

more than twice as frequent as that involving the femoral stem (13).

The third generation of cementless cups consist of a metallic acetabular shell with a rough surface to improve osseous integration and therefore long-term survival (8,20,24). Combining these cups with highly cross-linked PE inserts and modern ceramic heads should avoid high wear rates and the specific risks of ceramic-ceramic bearings (1,5,6,15,19,25). Primary fixation of the acetabular component can be achieved by various means (8,21), but is usually provided by threads or press-fit with or without additional screws. The primary stability of acetabular cups before bony ingrowth depends on many factors such as the geometry of the cup, design of the threads or rims, implant material and surface finishing (8,16,18,21,22,26,28). Experimental studies have shown that threaded cups have higher primary stability compared to press-fit cups with respect to

- Martin Ellenrieder.
  - Prof. Dr. med. Dipl.-Ing. Rainer Bader.
  - Prof. Dr. med. habil. Wolfram Mittelmeier.
  - PD Dr. med. habil. Philipp Bergschmidt.
- University Medicine Rostock Department of Orthopaedic, Germany.*

Correspondence : Dr. med. M. Ellenrieder, Department of Orthopaedics, University Medicine Rostock, Doberaner Str. 142, 18057 Rostock, Germany.

E-mail : martin.ellenrieder@uni-rostock.de

© 2016, Acta Orthopædica Belgica.



**Fig. 1.** — The PSL (left) and TC (right) cementless acetabular cups. The dome hole is sealed with a flat screw before insertion of the PE liner. The PSL cup offers additional screw options.

lever-out forces and interface micromotions (18,22, 26,28). Despite their biomechanical advantages, threaded cups continue to raise concern because of their variable clinical results (6,13,21,24,25,27). Complications reported for their first two generations include early loosening, cup breakage and soft tissue damage as well as local strain concentrations followed by osteonecrosis caused by the thread teeth (8,9,12,21,30). A new hemispherical cup with a relatively low thread relief and special flute design (Fig. 1) may address these concerns. The new thread design may avoid soft tissue complications and allow bone-preserving intraoperative unscrewing and cup repositioning. This should facilitate insertion, resulting in a more reproducible component position and high contact area between the bone stock and implant. However, to date no data are available to indicate whether the new threaded cup design provides primary stability, osseous integration and a clinical outcome comparable to the well-established press-fit cup.

Hence, the first objective of this prospective clinical study was to evaluate clinical and radiological outcomes after uncemented THR in patients receiving either the press-fit or the threaded acetabular cup design. Preoperative and postoperative data (1, 2 and 5 years postoperatively) were analysed to evaluate the outcome of THR within and between the two groups of patients. A second objective was

to evaluate primary stability and osseointegration by means of X-ray analysis at the same time points. Finally, complications possibly related to the threaded and press-fit cup designs were analysed.

## PATIENTS AND METHODS

### Patients

A total of 84 patients aged between 18 and 75 years were enrolled in a prospective comparative study between August 2005 and February 2008. The patients underwent total hip arthroplasty; the first 42 patients received the press-fit cup design (PSL) and the subsequent 42 patients received a threaded cup (TC). Demographic data are shown in Table I. The main criterion for inclusion in the study was indication for primary cementless THR due to osteoarthritis, avascular necrosis or posttraumatic arthritis. The Local Ethical Committee approved the study (Number: II HV 19/2005; HV-2007-0005) and informed consent was obtained from each patient included.

Exclusion criteria included THR on the contralateral side within the previous or following 6 months, massive obesity (BMI > 35), disabling neurological or systemic disease, pregnancy, history of infection or tumour disease, preceding osteotomies of the proximal femur, or withdrawal of consent for study participation. After five years follow-up five patients of the TC group and four PSL patients were excluded from the study. One male patient of the TC group and two patients (one male, one

Table I. — Demographics of the patients enrolled in the threaded cup and press-fit groups

Demographic	Threaded cup (TC)	Press-fit cup (PSL)
Number of patients included	42	42
Male / Female	18 (43%) / 24 (57%)	23 (55%) / 19 (45%)
Mean age ( $\pm$ 1SD* ; min-max)	65.8 years ( $\pm$ 9.1y; 44-75 yr)	64.9 years ( $\pm$ 7.8y; 49-76 yr)
Mean BMI ( $\pm$ 1SD*)	29.0 ( $\pm$ 3.05)	28.5 ( $\pm$ 3.66)

\* one standard deviation.

female) of the PSL group had a THR on the contralateral side within 6 months. One female patient of the TC group was lost to follow-up after 2 years. Three TC patients and two PSL patients were excluded due to complications related to the hip stem (see Results). All other patients received radiological and clinical follow-up for 60 months postoperatively.

## Implants

Both the press-fit cup (Trident™ PSL, Stryker GmbH, Duisburg, Germany) and the threaded cup (Trident™ TC, Stryker GmbH, Duisburg, Germany) have a hemispheric metal back consisting of a Ti6Al4V titanium alloy (Fig. 1). The PSL cup achieves primary stability by two parallel peripheral rims whereas the TC cup is equipped with self-cutting threads. The PSL cup offers additional screw-interlocking options to enhance primary stability (Fig. 1). Only one (cranial) screw was used in the present study. The PSL cups were combined with a Crossfire™ liner (first-generation highly cross-linked polyethylene, HX-PE) and the TC cups with a X3™ liner (second-generation HX-PE) (both liners : Stryker GmbH, Duisburg, Germany). All patients received a 36 mm alumina ceramic head (BILOX® forte, Stryker GmbH, Duisburg, Germany) and a cementless straight stem (Hipstar®, Stryker GmbH, Duisburg, Germany).

## Surgical procedure and follow-up examination

All surgeries were performed using an anterolateral approach and patients received a standardised postoperative treatment regimen. All patients underwent assessment using the Harris Hip Score (HHS), the 36-item Short Form Health Survey (SF-36) and the Western Ontario and McMaster University Osteoarthritis Index (WOMAC) preoperatively and 1, 2 and 5 years postoperatively. Radiological follow-up consisted of a symphysis-centred anterior-posterior view of the pelvis and an

axial view and was done at the same times. The cup position in relation to the pelvis was determined by measuring the vertical and horizontal distances between the tip of the pelvic tear drop and the centre of the projected ellipsoidal inlet plane of the metal back. The cup inclination and anteversion angles were measured according to the modified method of Pettersson (23). The acetabular periprosthetic bone stock was analysed for osteolysis and radiolucent lines (7) as well as osseous integration of the cup (10). Heterotopic ossifications were evaluated according to the classification of Brooker *et al* (3). Furthermore, radiolucent lines and the stability of the femoral component were assessed (11,14).

## Statistical analysis

Comparisons between groups (PSL and TC cup) evaluated differences in the functional results and quality of life (by using HHS, WOMAC and SF-36 score) and in radiological cup positioning. Descriptive statistics were computed for continuous and categorical variables. Significant differences between the groups were identified using the Kruskal-Wallis test (KW) and the Mann-Whitney U-test (MW) as non-parametric tests for comparison of independent samples. Comparisons within groups of clinical and radiological evaluations were made using the Friedman test (FR) and the Wilcoxon test (WI). All p-values resulted from two-sided statistical tests and values of  $p < 0.05$  were considered to be statistically significant. Data were stored and analysed using the SPSS statistical package 15.0 (SPSS Inc. Chicago, Illinois, USA).

## RESULTS

### Clinical and radiological follow-up examination

Preoperatively patients of both groups showed a significant impairment of their hip function (HHS, WOMAC) and a reduced health-related quality of

Table II. — Mean score value (points)  $\pm$  one standard deviation for the HHS, WOMAC and SF-36 preoperatively, and after 1, 2 and 5 years follow-up. P-values are of the statistical comparison between follow-up data and preoperative status

Type of cup	TC cup			PSL cup		
	HHS	WOMAC	SF-36	HHS	WOMAC	SF-36
Preoperatively	59.2 $\pm$ 15.8	50.8 $\pm$ 15.9	57.2 $\pm$ 20.1	54.6 $\pm$ 15.8	44.7 $\pm$ 11.5	57.5 $\pm$ 13.4
1 year	80.8 $\pm$ 15.1	74.8 $\pm$ 15.8	65.6 $\pm$ 22.3	84.7 $\pm$ 16.8	71.0 $\pm$ 19.7	67.8 $\pm$ 16.9
<b>1 yr vs. preop.</b>	<b>p &lt; 0.001</b>	<b>p &lt; 0.001</b>	<b>p &lt; 0.139</b>	<b>p &lt; 0.001</b>	<b>p &lt; 0.001</b>	<b>p = 0.184</b>
2 years	86.7 $\pm$ 13.0	78.6 $\pm$ 13.0	68.1 $\pm$ 19.9	84.5 $\pm$ 13.5	76.5 $\pm$ 14.2	72.2 $\pm$ 16.8
<b>2 yr vs. preop.</b>	<b>p &lt; 0.001</b>	<b>p &lt; 0.001</b>	<b>p &lt; 0.097</b>	<b>p &lt; 0.001</b>	<b>p &lt; 0.001</b>	<b>p = 0.002</b>
5 years	91.1 $\pm$ 11.5	81.0 $\pm$ 14.5	70.0 $\pm$ 22.3	84.1 $\pm$ 13.8	80.0 $\pm$ 16.7	72.7 $\pm$ 18.2
<b>5 yr vs. preop.</b>	<b>p &lt; 0.001</b>	<b>p &lt; 0.001</b>	<b>p &lt; 0.009</b>	<b>p &lt; 0.001</b>	<b>p &lt; 0.001</b>	<b>p = 0.002</b>

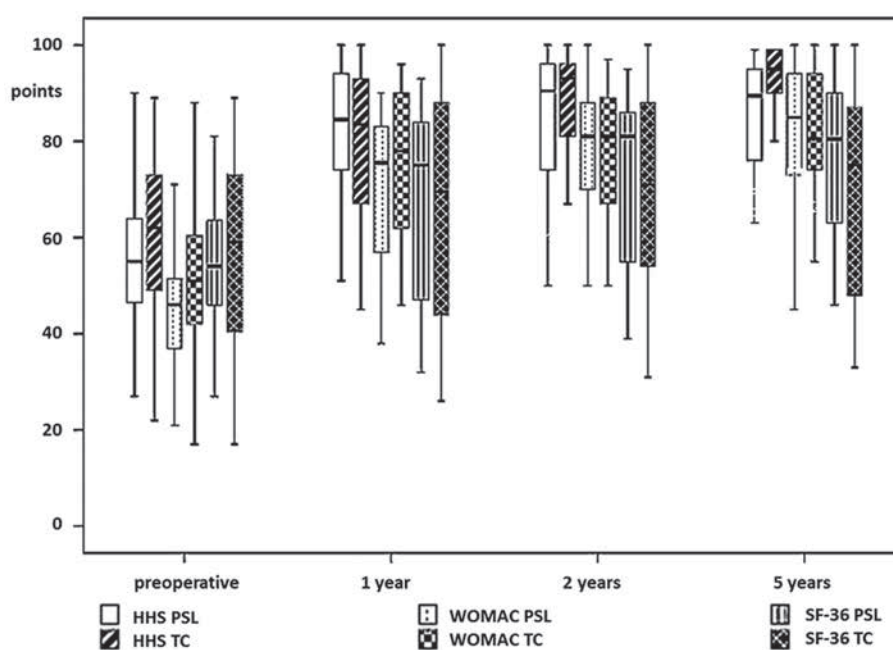


Fig. 2. — Boxplot showing a significant improvement in the clinical scores of the TC and PSL patient groups after 60 months compared to the preoperative status. No significant difference between the TC and PSL patients except for the HHS at 5 years (favours TC group).

life (SF-36) (Table II). There were no differences in the preoperative HHS, WOMAC and SF-36 scores between the TC and PSL patient groups.

After 1, 2 and 5 years the functional scores (HHS, WOMAC) in both patient groups showed a significant improvement compared to their preoperative status ( $p < 0.001$ ; Table II, Fig. 2). After 5 years the mean HHS and WOMAC scores had increased by 31.9 and 30.2 points (TC group), and 29.5 and 35.3 points (PSL group), respectively (Table II).

The improvement of the SF-36 score was only statistically significant after 2 years in the PSL group and after 5 years in the TC group (Table II). There were no differences between patient groups, except for the HHS at 5 years (Table III).

After 5 years, radiographs showed no migration of the cup centre or change in component orientation in either group. However, cup orientation differed significantly between the TC and PSL patients (Table IV). After 5 years, radiolucent lines in zone

Table III. — P-values resulting from the statistical comparison of the HHS, WOMAC and SF-36 scores of the PSL and TC groups

	PSL cup versus TC cup		
	HHS	WOMAC	SF-36
Preoperatively	0.244	0.071	0.938
1 year	0.245	0.377	0.657
2 years	0.513	0.530	0.364
5 years	0.020*	0.804	0.535

\*favours TC group.

2 were evident in five patients in the PSL group (< 1 mm : 4 cups ; 1-2 mm : 1 cup) and two cups had radiolucent lines in zone 1 (1-2 mm). In the TC group radiolucent lines in zone 2 were evident in five patients (< 1 mm : 4 cups ; 1-2 mm : 1 cup). One TC cup showed a radiolucent line in zone 1 (< 1 mm) and zone 2 (1-2 mm).

### Complications

Seventeen minor and five major complications requiring exchange of the hip stem occurred within 60 month follow-up. None of the complications appeared to be related to the acetabular cup design.

Two male and one female patient of the TC group needed a stem revision due to aseptic loosening after 3 to 5 years. In one male PSL patient a material breach of the hip stem occurred after 4 years. In all four patients revision surgery of the stem was performed leaving the well-fixed acetabular cups in situ. One other stem revision is impending (PSL group, female) due to aseptic loosening. This PSL cup also shows full osteointegration.

Two patients (2.3%) in the PSL group who were suffering from insulin-dependent diabetes mellitus and chronic myeloid leukaemia, respectively, required local wound revisions due to prolonged secretion/haematoma without signs of a deep infection. Implant components were not exchanged and wound healing after revision was uncomplicated. Three patients suffered fractures of the tip of the greater trochanter (3.5% ; two females with a TC cup and one female with a PSL cup), but none required osteosynthesis. Fragment dislocation was mild in two patients (full weight-bearing) and mod-

erate in one patient (limited weight-bearing for 6 weeks) but there was no further dislocation during follow-up. After two years postoperatively the three patients achieved good hip function (HHS : 87, 92 and 94 points) without any signs of gluteal insufficiency. One patient (1.1%) in the TC group had a deep vein thrombosis postoperatively and was treated with weight-adapted low-molecular weight heparin. After five years heterotopic ossifications were recorded in five PSL patients (Brooker I° : 4 patients, Brooker II° : 1 patient) and six TC patients (Brooker I° : 5 patients, Brooker II° : 1 patient) but without impairment of range of motion (ROM) or clinical function. No dislocation or deep infection occurred.

### DISCUSSION

Our study comprises a five-year follow-up using the SF-36, WOMAC and HHS scores to provide general information on physical and mental health, as well as joint function. Several previous studies have only recorded some of these details (4,20,25). The significant improvement we found in scores in the PSL and TC groups (Table II) is comparable to previous studies using a Trident® press-fit acetabular cup (Table II) (4,6,21). Sayeed *et al* followed 50 patients with a thin X3™ liner and 50 patients with a standard-thickness X3™ liner combined with another press-fit acetabular shell and reported a mean HHS of 90 and 91 respectively after 26 months (21). Meftah *et al* reported on 63 patients (72 hips) with a WOMAC score of  $30.4 \pm 8$  after  $2.9 \pm 0.5$  years (20). No other studies reporting on clinical outcomes of the Trident® TC threaded cup are available so far. However, the clinical outcomes of our TC group are comparable to those of Suckel *et al* who reported a mean HHS of 88 points after 15 years for the relatively successful Zweymüller threaded cup (27). Even though our 5-year post-operative HHS results favour the TC group ( $p = 0.02$ ), the WOMAC score and the absolute difference between preoperative and 5-year HHS (TC : + 31.9 points ; PSL : + 29.5 points) suggest that the positive effect of the THR on the patient's hip function is equivalent between the groups. Similar to the HHS and WOMAC scores, most of the

Table IV. — Mean inclination and anteversion for the TC and PSL groups of the present study. Comparison data from other studies (non-navigated THR) ; nv = no value

Study	Patients (hips)	Cup*	Inclination mean ( $\pm$ 1SD ; min-max)	Anteversion mean ( $\pm$ 1SD ; min-max)
Present study	42 (42)	Trident™ TC	48.4° ( $\pm$ 4.21° ; 41°-58°)	17.3° ( $\pm$ 2.61° ; 9°-22°)
Present study	42 (42)	Trident™ PSL	54.4° ( $\pm$ 8.50° ; 39°-77°)	22.1° ( $\pm$ 6.29° ; 10°-38°)
Campbell <i>et al</i> (4)	(19)	Trident™ PSL	45.6° ( $\pm$ nv ; 39°-58°)	nv
Meftah <i>et al</i> (20)	63 (72)	Trident™ PSL	41° ( $\pm$ 3° ; 35°-52°)	nv
D'Antonio <i>et al</i> (6)	(149)	Trident™ PSL	45.1° ( $\pm$ 6.9° ; < 30°-72°)	16.1° $\pm$ 7.3°

\*Stryker Orthopaedics.

improvement of the SF-36 score was registered within the first postoperative year. Nevertheless, the increase of the SF-36 score was significant only after  $\geq 2$  years (Table II). This may be due to the variety of factors that enter into the calculation of the SF-36. Splitting our SF-36 data up into the physical and mental component summaries, the postoperative improvement is mainly due to changes in the physical component. After 2 and 5 years the physical component summary improved compared to the preoperative status by 45% and 54% (PSL group) and 25% and 29% (TC group), respectively. The mental component summary score improved by 22% and 9.9% (PSL group) and 8.7% and 21% (TC group) after 2 and 5 years.

The radiological evaluation after 5 years showed no significant difference in the osseous integration of the cups between groups. Seven (14.9%) PSL cups and five (11.9%) TC cups showed a small radiolucent line in one zone (zone 2). One TC cup showed a radiolucent line that extended from zone 2 into zone 1. No radiolucent lines were progressive after the postoperative and 1-year follow-up and all seemed to be due to incomplete contact between implant and bone stock after insertion (10). There were no clinical signs of loosening, component migration or alterations in cup orientation in any of the acetabular cups. Hence all PSL cups and 98% of the TC cups met the radiological criteria for osseous fixation (10). In particular, there were no signs of acetabular bone resorption possibly relating to local stress concentration around the thread teeth (9,30). Therefore, the TC cup equalled the radiological osseointegration results of the PSL cup, confirming findings by other authors (4,6,20,25).

For the radiological analysis of the acetabular component position a cup inclination of 45° and an

anteversion angle of 15° should be recommended based on recent research results (2) and the criteria of Lewinnek (17). In terms of the optimum implant position the TC group showed excellent positioning, whereas the PSL cups were oriented at a steeper ( $p < 0.001$ ) and more anteverted ( $p < 0.001$ ) angle (Table IV). There was no apparent reason for this difference, although the thread teeth may stabilise the implant orientation during insertion. In the PSL group there were three outliers with a cup inclination of 77°, 69° and 66°. Nevertheless, all three cups showed complete osseous integration after 5 years with no signs of excessive PE liner wear. In comparison with the PSL group and the literature, the component positioning of the TC cup showed high precision and reproducibility (Table IV). In addition, other authors have reported several PSL cups with an inclination angle (range : less than 30° to 72°) outside the interval of our TC group (range : 41° to 58°) (4,6,20).

Our reported complications were not related to the type of acetabular component. No complications typically ascribed to threaded cups, such as vascular/nerve lesions or osteolysis around the threads (8,9,30), were observed in our study. These favourable results may be due to the relatively low relief of the threads of the Trident™ TC acetabular component.

The study has two major limitations. First, consecutive patients were included in the both study groups and the patients were informed already preoperatively about the implants. Hence our study could not reach the evidence level of blinded randomized trials. Nevertheless a good comparability of the two groups was achieved in the present study since a single-center prospective comparative design as well as standardized conditions concerning

surgical technique, hip stem, ceramic head diameter (36 mm), aftercare and follow-up are provided. Second, the PSL and TC groups received different types of PE liner (first versus second generation HXLPE). Both were found to exhibit very low linear wear rates (0.036 mm/y vs. 0.015 mm/y with first vs. second generation) compared to conventional PE (4,6). Since our study was not focused on PE wear rates, the accuracy ( $\pm 0.1$  mm,  $\pm 0.1^\circ$ ) of our software measurement tool did not allow detecting potential differences in the head penetration after 5 years. Nevertheless, the evaluation of radiolucent lines and osteolysis, which are not only a result of volumetric wear but also from implant biomechanics and biological activity of particles, could not reveal a significant difference between the PSL and TC patients. In conclusion, our clinical and radiological results with a new threaded cup were comparable to good functional results of a THR with a press-fit cup. The TC cup had superior cup orientation to our PSL group and published data on patients with the PSL cup. None of the typical complications of threaded cups reported in the literature were observed in our study, possibly due to the advanced design of the threads. After five years, we observed none of the typical signs of accelerated wear, such as femoral head displacement  $> 0.2$  mm, osteolysis or component loosening in the TC cup and second-generation HX-PE liner compared to the PSL cup with first-generation HX-PE liner. On the basis of the presented data, the new threaded cup design provides excellent primary stability and clinical and radiological outcomes after 5 years postoperatively. Nevertheless the relatively high failure rates of the straight hip stem used in both groups will be the focus of further investigation.

#### Acknowledgements

The authors wish to thank MA Susanne Finze for her assistance in the statistical analysis.

## REFERENCES

- Affatato S, Modena E, Toni A, Taddei P.** Retrieval analysis of three generations of Biolo<sup>x</sup>® femoral heads: spectroscopic and SEM characterisation. *J Mech Behav Biomed Mater* 2012 ; 13 : 118-128.
- Bader R, Steinhauser E, Gradinger R, Willmann G, Mittelmeier W.** [Computer-based motion simulation of total hip prostheses with ceramic-on-ceramic wear couple. Analysis of implant design and orientation as influence parameters]. *Z Orthop Ihre Grenzgeb* 2002 ; 140 : 310-316.
- Brooker AF, Bowerman JW, Robinson RA, Riley LH.** Ectopic ossification following total hip arthroplasty. Incidence and a method of classification. *J Bone Joint Surg* 1973 ; 55 : 1629-1632.
- Campbell DG, Field JR, Callary SA.** Second-generation highly cross-linked X3<sup>TM</sup> polyethylene wear : a preliminary radiostereometric analysis study. *Clin Orthop Relat Res* 2010 ; 468 : 2704-2709.
- Capello WN, D'Antonio JA, Ramakrishnan R, Naughton M.** Continued improved wear with an annealed highly cross-linked polyethylene. *Clin Orthop Relat Res* 2011 ; 469 : 825-830.
- D'Antonio JA, Capello WN, Ramakrishnan R.** Second-generation annealed highly cross-linked polyethylene exhibits low wear. *Clin Orthop Relat Res* 2012 ; 470 : 1696-1704.
- DeLee JG, Charnley J.** Radiological demarcation of cemented sockets in total hip replacement. *Clin Orthop Relat Res* 1976 ; 121 : 20-32.
- Effenberger H, Imhof M, Richolt J, Rehart S.** [Cement-free hip cups. Current status]. *Orthopade* 2004 ; 33 : 733-750 (in German).
- Effenberger H, Witzel U, Lintner F, Rieger W.** Stress analysis of threaded cups. *Int Orthop* 2001 ; 25 : 228-235.
- Effenberger H, Weber M, Dorn U, Hofer H.** [Roentgen criteria and radiological results of the Hofer-Imhof (H-I) threaded acetabular cup in first time implantation]. *Z Orthop Ihre Grenzgeb* 1997 ; 135 : 434-443.
- Engh CA, Massin P, Suthers KE.** Roentgenographic assessment of the biologic fixation of porous-surfaced femoral components. *Clin Orthop Relat Res* 1990 ; 257 : 107-128.
- Garcia-Cimbrelo E, Martinez-Sayanes JM, Minuesa A, Munuera L.** Mittelmeier ceramic-ceramic prosthesis after 10 years. *J Arthroplasty* 1996 ; 11 : 773-781.
- Garellik G, Kärrholm J, Rogmark C, Herbert P.** The Swedish Hip Arthroplasty Register. Annual Report 2009. Department of Orthopaedics, Sahlgrenska University Hospital, SE-413 45 Göteborg, Sweden. 2010 ; 1-107
- Gruen TA, McNeice GM, Amstutz HC.** Modes of failure of cemented stemtype femoral components : a radiographic analysis of loosening. *Clin Orthop* 1979 ; 141 : 17-27.
- Kurtz SM, Gawel HA, Patel JD.** History and systematic review of wear and osteolysis outcomes for first-generation highly crosslinked polyethylene. *Clin Orthop Relat Res* 2011 ; 469 : 2262-2277.
- Le Cann S, Galland A, Parratte S, Rosa B, Argenson JN, Chabrand P.** Biomechanical testing of the primary stability of macro and micro-roughnesses acetabular cups : a numerical and an experimental study. *Comput Methods Biomech Biomed Engin* 2012 ; 15 : 350-352.

17. Lewinnek GE, Lewis JL, Tarr R, Compere CL, Zimmerman JR. Dislocations after total hip-replacement arthroplasties. *J Bone Joint Surg Am* 1978 ; 60 : 217-220.
18. Litsky AS, Pophal S. Initial mechanical stability of acetabular prostheses. *Orthopedics* 1994 ; 17 : 53-57.
19. Lombardi AV Jr, Berend KR, Seng BE, Clarke IC, Adams JB. Delta ceramic-on-alumina ceramic articulation in primary THA : prospective, randomized FDA-IDE study and retrieval analysis. *Clin Orthop Relat Res* 2010 ; 468 : 367-374.
20. Meftah M, Ebrahimpour PB, He C, Ranawat AS, Ranawat CS. Preliminary clinical and radiographic results of large ceramic heads on highly cross-linked polyethylene. *Orthopedics* 2011 ; 34 : 133.
21. Morscher EW. Current status of acetabular fixation in primary total hip arthroplasty. *Clin Orthop Relat Res* 1992 ; 274 : 172-193.
22. Olory B, Havet E, Gabrion A, Vernois J, Mertil P. Comparative in vitro assessment of the primary stability of cementless press-fit acetabular cups. *Acta Orthop Belg* 2004 ; 70 : 31-37.
23. Pettersson H, Gentz CF, Lindberg HO, Carlsson AS. Radiologic evaluation of the position of the acetabular component of the total hip prosthesis. *Acta Radiol Diagn (Stockh)* 1982 ; 23 : 259-263.
24. Reigstad O, Siewers P, Røkkum M, Espehaug B. Excellent long-term survival of an uncemented press-fit stem and screw cup in young patients : follow-up of 75 hips for 15-18 years. *Acta Orthop* 2008 ; 79 : 194-202.
25. Sayeed SA, Mont MA, Costa CR, Johnson AJ, Naziri Q, Bonutti PM, Delanois RE. Early outcomes of sequentially cross-linked thin polyethylene liners with large diameter femoral heads in total hip arthroplasty. *Bull NYU Hosp Jt Dis* 2011 ; 69 : 90-94.
26. Schwarz ML, Scheller G, Effenberger H. Primary stability of threaded cups in THR — an experimental study. *Biomed Tech (Berl)* 2003 ; 48 : 334-338.
27. Suckel A, Geiger F, Kinzl L, Wulker N, Garbrecht M. Long-term results for the uncemented Zweymuller/Alloclassic hip endoprosthesis. A 15-year minimum follow-up of 320 hip operations. *J Arthroplasty* 2009 ; 24 : 846-853.
28. Wetzel R, Simmacher M, Scheller G. [Initial stability of press-fit acetabular cups – an in-vitro study]. *Biomed Tech (Berl)* 2005 ; 50 : 400-403.
29. Willert HG, Puls P. [The reaction of bone to bone-cement in the replacement of the hip joint]. *Arch Orthop Unfallchir* 1972 ; 72 : 33-71.
30. Witzel U, Rieger W, Effenberger H. Three-dimensional stress analysis of threaded cups – a finite element analysis. *Int Orthop* 2008 ; 32 : 195-201.