



The impact of patellofemoral arthritis on unicompartmental knee arthroplasty

Jiaji YUE, Li ZHANG, Chunxi YANG

From Department of Orthopedics, Shanghai Tenth People's Hospital, Tenth People's Hospital of Tongji University, Shanghai, China

Unicompartmental knee arthroplasty (UKA) is an efficient surgical treatment for osteoarthritis or avascular osteonecrosis by resurfacing the medial or lateral compartment of the tibiofemoral joint. If compared to total knee arthroplasty (TKA), UKA can reach the same long-term curative effect, but superiority in less invasive soft tissue dissection, preservation of bone stock, minimal blood loss, faster post-operative rehabilitation and less complications. For the last 15 years, the Oxford Knee phase 3 has been implanted through a minimally invasive approach, and multicenter studies using this approach have reported high survival rates at long-term follow-up. Up to now, UKA has accounted for a significant portion of the patients who need knee replacement. However, there remain some controversies on UKA indications, such as the debate regarding associated patellofemoral arthritis as a contraindication for UKA. As clear indications for UKA are usually rare, surgeon's experience seems to be the key factor for a successful selection of patients. Better understanding of indications may add to improved outcome of UKA. This narrative review aims to summarize the current pros and cons to eliminate patellofemoral arthritis (PFA) as a contraindication for UKA.

Keywords : unicompartmental knee arthroplasty ; patellofemoral arthritis.

INTRODUCTION

Unicompartmental knee arthroplasty (UKA) is an accepted surgical treatment for osteoarthritis or avascular osteonecrosis by resurfacing the medial or lateral compartment of the tibiofemoral joint. By retaining the cruciate ligaments, the patellofemoral joint, the contralateral compartment and the meniscus, UKA is able to restore the kinematics of the damaged compartment and to function together with the undamaged compartment.

Compared with total knee arthroplasty (TKA), UKA has obtained the similar long-term curative effect, providing good results with 10- and 15-year survival rates of 94% to 97% and 87%, respectively (23), UKA differentiates itself by less invasive

-
- Jiaji Yue^{1,2}.
 - Li Zhang^{1,3}.
 - Chunxi Yang^{1,4}.

¹Department of Orthopedics, Shanghai Tenth People's Hospital, Tenth People's Hospital of Tongji University, Shanghai, China.

²Tongji University School of medicine, Shanghai, China.

³Nanjing Medical University, Nanjing, Jiangsu, China.

Correspondence : Chunxi Yang, Department of Orthopedics, Shanghai Tenth People's Hospital, Tenth People's Hospital of Tongji University, Shanghai, China.

E-mail : chunxi_yang@163.com

© 2015, Acta Orthopædica Belgica.

No benefits or funds were received in support of this study.
The authors report no conflict of interests.

Acta Orthopædica Belgica, Vol. 81 - 4 - 2015

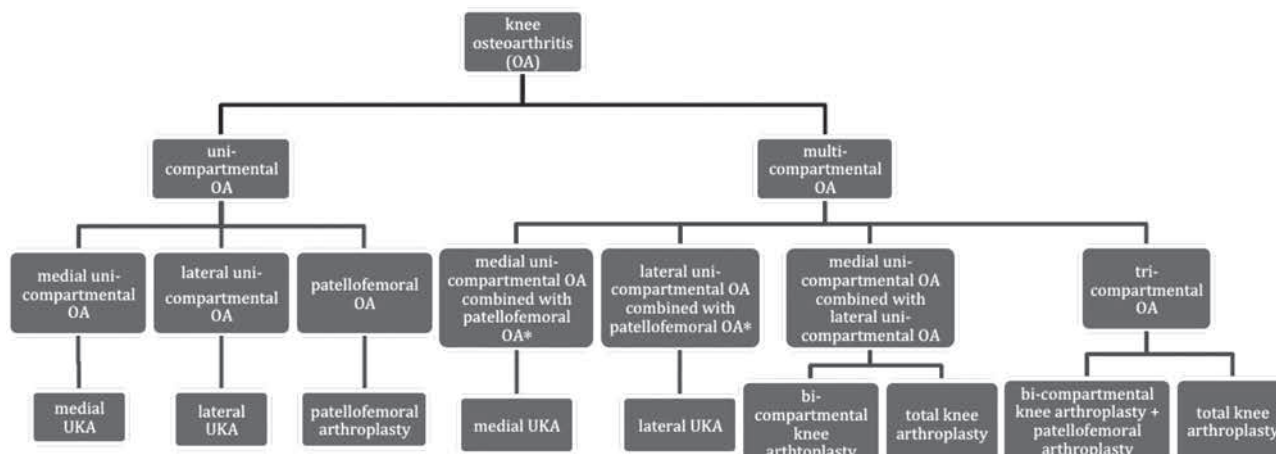


Fig. 1. — Surgeons can choose different surgical treatments for different knee osteoarthritis.

* When the patellofemoral arthritis is verified as lateral subluxation of the patella, patients should preferably be offered a total knee replacement.

soft tissue dissection, preservation of bone stock, minimal blood loss, minimally, faster post-operative rehabilitation and a reduction of complications (14,26,27).

Standard surgical criteria for UKA exclude patients who weigh more than 82 kg (187 lbs), patients aged < 60 years, and patients with more than minimal erosive changes in the patellofemoral articulation, indicated clinically by anterior knee pain (5). The belief that arthritis of the patellofemoral joint is likely a contraindication to UKA is common. This view was expressed by Kozinn and Scott in 1989 (21), reinforced by Stern, Becker and Insall (33), and has been persisted, despite some evidences suggest that the state of the patellofemoral joint was unrelated to the outcome. Stern *et al* regarded the degeneration of patellofemoral joints and pain in anterior knee as the contraindication (33). The research reported on patients with isolated unicompartmental disease who don't have clinical symptoms or radiographic evidence of patellofemoral arthritis, the primary mode of failure was progressive patellofemoral arthritis, the similar point of view is also presented by Sierra *et al* (32) that the four most common reasons for failure of the UKA were femoral or tibial loosening (55%), progressive arthritis of the lateral or patellofemoral joints (34%), polyethylene failure (4%) and infection (3%).

However, the bicompartamental study of the Oxford knee by Goodfellow and O'Connor in 1986 (13) found no relationship between the state of the patellofemoral joint, as seen at operation, and the outcome in a series of 125 patients. This finding formed the basis for the recommendation made by the Oxford Group that the state of the patellofemoral joint should be ignored when deciding whether or not to implant a UKR. Furthermore, Sébilo (31) believed that age, sex and BMI have slight impact on the outcomes of UKA, and the three factors above are not the contraindications. Many other studies have more supportive findings of UKA to be a successful treatment option regardless of age, patellofemoral osteoarthritis or obesity (25,30). In April 2004, the US Food and Drug Administration approved the Oxford phase III unicompartmental prosthesis for implantation during unicompartmental knee arthroplasty. These standard preoperative contraindications had no influence on the successful outcome of the procedure using the Oxford phase 3 device (5).

Patellofemoral arthritis is a relatively common condition, affecting up to 24% of women and 11% of men over the age of fifty-five years who have symptomatic osteoarthritis of the knee. Whereas, isolated patellofemoral arthritis is not prevalent and has been reported to occur in 9% of radiographs of symptomatic knees in individuals over the age of

forty years (34). The most common complaint is anterior knee pain, made worse while getting up or down the stairs or walking on inclines.

Normally, patellofemoral arthritis is diagnosed by cartilage loss, anterior knee pain, chondrosis in the patellofemoral joint at surgery and radiograph. The criteria above are widely used in literatures of unicompartmental tibiofemoral arthritis combined with PFA. For the epidemiology, morbidity of isolated patellofemoral arthritis is lower than tibiofemoral arthritis, and most of that exists as the comorbidity of tibiofemoral arthritis in medial compartment. The statistics above show that there is still a wide need of UKA and the challenges still exist.

In the following discussion, this review synthesizes the currently collected pros and cons to exclude the patellofemoral arthritis as the contraindication; the different patellofemoral joint conditions as well as the impacts on the outcome of UKA are enumerated as well as analyzed.

PROS

(1) The impact of cartilage loss at the patellofemoral joint on Oxford UKA outcome

The Oxford Group examined patellofemoral joints in 824 knees of 793 patients undergoing medial UKA for osteoarthritis. All patients were assessed independently by physiotherapists using the American Knee Society score (AKSS) (18). The severity of the degeneration at any of the intra-articular locations had no influence on outcome. The authors concluded that, provided there is no bone loss and grooving of the lateral facet, damage to the articular cartilage of the patellofemoral joint to the extent of full-thickness cartilage loss is not a contraindication for the Oxford mobile-bearing medial unicompartmental knee replacement (3).

A report based on data from the Swedish Knee Arthroplasty Register (20), which does not recount the indications for the use of the Oxford UKR, describes the implantation of 699 Oxford UKRs, for which 50 revisions were required. Only one revision was considered to be related to the patellofemoral joint. The data suggest that the main reason for the failure of long-term of UKA is not full-thick-

ness cartilage loss of the patellofemoral joint and the hypothesis of full-thickness cartilage loss in the patellofemoral joint as the contraindication to UKR can be ignored.

Postmortem studies have shown that in the patellofemoral joint of elderly people cartilage damage and full-thickness cartilage loss is very common (11). Hence, much of the damage seen in the patellofemoral joint may not be symptomatic and would not influence the outcome. However, the mechanical benefits of UKR on the patellofemoral joint may influence outcome (3). Between the battered medial femoral condyle and the degenerated surfaces of the patellofemoral joint, in high flexion, the pain in articulation would be alleviated by the new contact surface provided by the UKR. Secondly, achieved by UKA, the correction of the alignment can reduce the overload of the patellofemoral joint from varus deformity and therefore relieve the pain from the lesion-side of the tibiofemoral joint, slow the progression of patellofemoral arthritis. Furthermore, osteophytes on the both of femoral condyle and tibia plateau may damage the medial part of the patellofemoral joint, so the removal of these at operation would no longer cause irritation as well as relieving the pain.

(2) The impact of anterior knee pain or radiologically demonstrated medial patellofemoral joint degeneration on Oxford UKA curative effect

Beard *et al* (4) reported 100 knees (91 patients) in which Oxford unicompartmental knee replacements were undertaken for anteromedial osteoarthritis, pre-operative radiological status of the patellofemoral joint were defined. The radiographs were scored for severity of arthritis using the Ahlback (1) grading and Altman (2) scoring system, and the Oxford knee score (OKS) (10) to judge the pain in anterior knee.

After two years follow-up, the clinical outcome was independent of the presence or absence of pre-operative degenerative changes of the patellofemoral joint and had a similar outcome to those without. Obliteration of the medial patellofemoral joint space radiologically is confirmed as cartilage loss at intraoperative. Berend (6) presented the same

result that preoperative radiographic changes in the patellofemoral joint can be safely ignored when considering patients for medial UKA without compromising survivorship.

In most reports on patients with medial knee osteoarthritis, anterior pain from the patellofemoral joint is not clearly distinguished from pain from the femorotibial joint (17) and anterior knee pain is also a poorly defined entity. The Oxford Group asked their patients to specify whether their pain was medial, anterior, lateral, or generalized. 55% had preoperative anterior knee pain but only 3% had lateral pain, and they found no difference in OKS outcome between the groups with and without preoperative anterior knee pain (4). Based on this, it is approved by Oxford Group that preoperative anterior knee pain does not correlate with the result after Oxford UKA. Munk *et al* (24) found that 16% of the patients had preoperative posterocentral knee pain, and this was a predictor of good outcome. The reason for this is uncertain. It may be due to soft tissue-related disorders. To sum up, anterior pain in the knee is imprecise to locate, which provides difficulty in comparison between the experimental group and control group. From the perspective of data, anterior pain has no impact on the results of UKA; furthermore, the specific impact, which is the precise pain location in different part of knee, on the efficacy of UKA still need further study.

CONS

(1) Impact of Lateral subluxation of the patella on UKA

The Oxford Group assessed preoperative subluxation of the patella on the skyline radiographs, but did not report any analysis of outcome (4), and a recent study by Pandit *et al* (28) claimed subluxation to be a contraindication to UKA but did not address it in the study. However in Stig Munk *et al*'s study (24), 7 patients had lateral subluxation of the patella on the preoperative skyline radiographs, and it has a highly significant predictor of poor outcome. Chang *et al* (9) found that lateral patellar translation of the patella and difficulty in rising from a chair was predictive of increased anterior knee pain in

osteoarthritic knees after total knee replacement. They suggested that patellofemoral malalignment and abnormal tracking might be an important cause of postoperative pain. Stress radiography of the patellofemoral joint with and without quadriceps contraction is a simple low-cost method to evaluate patellar shift (12), and could be a screening method for lateral subluxation.

Recommendation is presented that, Patellofemoral degeneration should not be considered a contraindication to Oxford UKA, whereas, lateral subluxation of the patella have an increased risk of a poor result after UKA and should preferably be offered a total knee replacement (24).

(2) The progression of patellofemoral arthritis after medial unicompartmental replacement

Literatures about this impact on the UKA curative effect were found paradoxical

A study includes 513 consecutive potential knee replacements reports failure mechanisms and progression of patellofemoral arthritis. Progressive patellofemoral arthritis was the primary mode of failure of 59 patients with isolated unicompartmental disease. Four patients (10%) had moderate or severe patellofemoral symptoms at final follow-up; two were revised to a primary total knee replacement at 7 and 11 years for progressive patellofemoral degeneration (7). At up to 15 years, UKA yielded good clinical results; however, progressive patellofemoral arthritis was the primary mode of failure.

However, Kupier *et al* (22) could not associate patellofemoral arthritis as a reason for poor outcome after medial UKA and need for revision in medium-term follow-up. Numerous studies corroborated this finding and identified that this is true for medial compartmental disease of the patellofemoral compartment (3,4,15,19). This is thought to be due to unloading of the medial facet when varus deformity of the knee joint is corrected by medial unicompartmental knee arthroplasty (3,4). Beard *et al.* hypothesized that lateral patellofemoral facet disease may be worsened by medial UKA as it may overload after correction of varus deformity (3,4). Up to now, much more studies has resulted that outcomes in patients with or without disease in other compartments

or patellar disease in the presence of radiographic or intra-operative evidence of patellar disease equals (3, 4,15,19,29).

CONCLUSION

Comparing the outcomes and postoperative complications after total knee arthroplasty with patellar resurfacing or nonresurfacing, reoperation for patellofemoral problems was significantly more likely in the nonresurfacing group, however, there was no difference between the two groups in terms of anterior knee pain rate, knee pain score, knee society score and knee function score. The results indicate that patellar resurfacing would reduce the risk of reoperation after total knee replacement, but it seems that the benefits are limited (16). The largest randomized controlled trial of patellar resurfacing reported to date does not show any advantage of patellar resurfacing over not replacing the patellar articular surface (8).

Resurfacing is also doable at surgery for UKA without dislocation of patella. The surgeon is able to not only remove the osteophytes on the tibia to relieve the anterior pain, but also restore the patellofemoral joint. Degeneration of the articular cartilage of the patellofemoral joint to the extent of full-thickness cartilage loss is not a contraindication to the Oxford mobile-bearing medial unicompartmental knee replacement, however, lateral subluxation of the patella and lateral patellofemoral facet disease may be worsened by medial UKA as it may overload after correction of varus deformity. Furthermore, trochlea is replaced in the TKA whereas the UKA is unable to resurface the trochlea, whether to take into consideration of the preoperational condition of patellofemoral joint should be discussed systematically.

OUTLOOK

(1) TKA can be partly replaced by UKA of the lesion-side of tibiofemoral joint and patellofemoral arthroplasty

Patellofemoral replacement (PFR) is known to be a viable solution to end-stage patellofemoral arthri-

tis. Bio-compartmental osteoarthritis (OA) affecting the medial tibiofemoral and the patellofemoral compartment (medio-patellofemoral OA) is often treated with total knee arthroplasty (TKA). It was hypothesized that medio-patellofemoral OA can successfully be treated with bicompartamental arthroplasty. The main idea behind these resurfacing solutions is tissue preservation with conservation of bone stock and both cruciate ligaments. Selective resurfacing can be considered as tissue-sparing surgery keeping unaffected parts of the joint intact and especially keeping both cruciate ligaments intact. This is the only real 'Minimally Invasive Surgery' and that conservation of the noble structures of the knee would lead to superior results.

(2) Curative effect of resurfacing the patellar of patellofemoral joint needs further prove

In above-mentioned discussion, degeneration of the articular cartilage of the patellofemoral joint to the extent of full-thickness cartilage loss is not a contraindication to the Oxford mobile-bearing medial unicompartmental knee replacement, and remove of the osteophytes on the both of femoral condyle and tibia plateau may alleviate irritation on the patellar as well as relieving the pain. However, more precise randomized controlled trial research is needed to prove the curative effect of resurfacing the patellar, whether resurfacing the patellar will improve the outcome of UKA or not need more studies. Literature data do not allow for a precise statement about the possible influence of patellofemoral arthritis on the outcome after unicompartmental knee replacement. With proper patient selection, good results can be achieved despite patellofemoral osteoarthritis.

Acknowledgments

This work was supported by grants from the National Natural Science Foundation of China (81101344/HO604), the outstanding young talent training plan of Tenth People's Hospital, Shanghai Tongji University School of Medicine (11RQ104) and the Climb talent training plan of Tenth People's Hospital, Shanghai Tongji University School of Medicine (04.01.13023).

REFERENCES

1. **Ahlback S.** Osteoarthrosis of the Knee. A Radiographic Investigation. *Acta Radiol Diagn (Stockh)* 1968 ; Suppl 277 :277-272.
2. **Altman RD, Fries JF, Bloch DA et al.** Radiographic Assessment of Progression in Osteoarthritis. *Arthritis Rheum* 1987 ; 30 : 1214-1225.
3. **Beard DJ, Pandit H, Gill HS et al.** The Influence of the Presence and Severity of Pre-Existing Patellofemoral Degenerative Changes on the Outcome of the Oxford Medial Unicompartmental Knee Replacement. *J Bone Joint Surg Br* 2007 ; 89 : 1597-1601.
4. **Beard DJ, Pandit H, Ostlere S et al.** Pre-Operative Clinical and Radiological Assessment of the Patellofemoral Joint in Unicompartmental Knee Replacement and Its Influence on Outcome. *J Bone Joint Surg Br* 2007 ; 89 : 1602-1607.
5. **Berend KR, Lombardi AV Jr, Adams JB.** Obesity, Young Age, Patellofemoral Disease, and Anterior Knee Pain : Identifying the Unicondylar Arthroplasty Patient in the United States. *Orthopedics* 2007 ; 30 : 19-23.
6. **Berend KR, Lombardi AV Jr, Morris MJ et al.** Does Preoperative Patellofemoral Joint State Affect Medial Unicompartmental Arthroplasty Survival ? *Orthopedics* 2011 ; 34 : e494-496.
7. **Berger R, Della Valle C, Jacobs JJ et al.** The Progression of Patellofemoral Arthrosis after Medial Unicompartmental Replacement : Results at 11 to 15 Years. *Clin Orthop Relat Res* 2006 ; 452 : 285-286.
8. **Breeman S, Campbell M, Dakin H et al.** Patellar Resurfacing in Total Knee Replacement : Five-Year Clinical and Economic Results of a Large Randomized Controlled Trial. *J Bone Joint Surg Am* 2011 ; 93 : 1473-1481.
9. **Cicuttini FM, Baker J, Hart DJ et al.** Association of Pain with Radiological Changes in Different Compartments and Views of the Knee Joint. *Osteoarthritis Cartilage* 1996 ; 4 : 143-147.
10. **Dawson J, Fitzpatrick R, Murray D et al.** Questionnaire on the Perceptions of Patients About Total Knee Replacement. *J Bone Joint Surg Br* 1998 ; 80 : 63-69.
11. **Emery IH, Meachim G.** Surface Morphology and Topography of Patello-Femoral Cartilage Fibrillation in Liverpool Necropsies. *J Anat* 1973 ; 116 : 103-120.
12. **Fukui N, Nakagawa T, Murakami S et al.** A Modified System of Stress Radiography for Patellofemoral Instability. *J Bone Joint Surg Br* 2003 ; 85 : 1128-1133.
13. **Goodfellow JWO, Connor J.** Clinical Results of the Oxford Knee. Surface Arthroplasty of the Tibiofemoral Joint with a Meniscal Bearing Prosthesis. *Clin Orthop Relat Res* 1986 : 21-42.
14. **Hall MJ, Connell DAM, Morris HG.** Medium to Long-Term Results of the Unix Uncemented Unicompartmental Knee Replacement. *Knee* 2013 ; 20 : 328-331.
15. **Hauptmann SM, Kreul U, Mazoochian F et al.** [Influence of Patellofemoral Osteoarthritis on Functional Outcome after Unicondylar Knee Arthroplasty]. *Orthopade* 2005 ; 34 : 1088, 1090-1083.
16. **He JY, Jiang LS, Dai LY.** Is Patellar Resurfacing Superior Than Nonresurfacing in Total Knee Arthroplasty ? A Meta-Analysis of Randomized Trials. *Knee* 2011 ; 18 : 137-144.
17. **Inaba Y, Numazaki S, Koshino T et al.** Provoked Anterior Knee Pain in Medial Osteoarthritis of the Knee. *Knee* 2003 ; 10 : 351-355.
18. **Insall JN, Dorr LD, Scott RD et al.** Rationale of the Knee Society Clinical Rating System. *Clin Orthop Relat Res* 1989 : 13-14.
19. **Kang SN, Smith TO, Sprenger De Rover WB et al.** Pre-Operative Patellofemoral Degenerative Changes Do Not Affect the Outcome after Medial Oxford Unicompartmental Knee Replacement : A Report from an Independent Centre. *J Bone Joint Surg Br* 2011 ; 93 : 476-478.
20. **Knutson K, Lewold S, Robertsson O et al.** The Swedish Knee Arthroplasty Register. A Nation-Wide Study of 30,003 Knees 1976-1992. *Acta Orthop Scand* 1994 ; 65 : 375-386.
21. **Kozinn S, Scott R.** Unicondylar Knee Arthroplasty. *J Bone Joint Surg Am* 1989 ; 71 : 145-150.
22. **Kuipers BM, Kollen BJ, Bots PC et al.** Factors Associated with Reduced Early Survival in the Oxford Phase Iii Medial Unicompartment Knee Replacement. *Knee* 2010 ; 17 : 48-52.
23. **Lisowski LA, van den Bekerom MP, Pilot P et al.** Oxford Phase 3 Unicompartmental Knee Arthroplasty : Medium-Term Results of a Minimally Invasive Surgical Procedure. *Knee Surg Sports Traumatol Arthrosc* 2011 ; 19 : 277-284.
24. **Munk S, Odgaard A, Madsen F et al.** Preoperative Lateral Subluxation of the Patella Is a Predictor of Poor Early Outcome of Oxford Phase-Iii Medial Unicompartmental Knee Arthroplasty. *Acta Orthop* 2011 ; 82 : 582-588.
25. **Murray DW.** Mobile Bearing Unicompartmental Knee Replacement. *Orthopedics* 2007 ; 30 : 768-769.
26. **Murray DW, Goodfellow JWO, Connor JJ.** The Oxford Medial Unicompartmental Arthroplasty : A Ten-Year Survival Study. *J Bone Joint Surg Br* 1998 ; 80 : 983-989.
27. **Naudie D, Guerin J, Parker DA et al.** Medial Unicompartmental Knee Arthroplasty with the Miller-Galante Prosthesis. *J Bone Joint Surg Am* 2004 ; 86-A : 1931-1935.
28. **Pandit H, Jenkins C, Gill HS et al.** Minimally Invasive Oxford Phase 3 Unicompartmental Knee Replacement : Results of 1000 Cases. *J Bone Joint Surg Br* 2011 ; 93 : 198-204.
29. **Pandit H, Jenkins C, Gill HS et al.** Unnecessary Contraindications for Mobile-Bearing Unicompartmental Knee Replacement. *J Bone Joint Surg Br* 2011 ; 93 : 622-628.
30. **Price AJ, Webb J, Topf H et al.** Rapid Recovery after Oxford Unicompartmental Arthroplasty through a Short Incision. *J Arthroplasty* 2001 ; 16 : 970-976.

31. **Sébiló A, Casin C, Lebel B et al.** Clinical and Technical Factors Influencing Outcomes of Unicompartmental Knee Arthroplasty : Retrospective Multicentre Study of 944 Knees. *Orthop Traumatol Surg Res* 2013 ; 99 : S227-234.
32. **Sierra RJ, Kassel CA, Wetters NG et al.** Revision of Unicompartmental Arthroplasty to Total Knee Arthroplasty : Not Always a Slam Dunk ! *J Arthroplasty* 2013 ; 28 : 128-132.
33. **Stern SH, Becker MW, Insall JN.** Unicompartmental Knee Arthroplasty. An Evaluation of Selection Criteria. *Clin Orthop Relat Res* 1993 : 143-148.
34. **Walker T, Perkinson BM, Halko WM.** Patellofemoral Arthroplasty : The Other Unicompartmental Knee Replacement. *Instr Course Lect* 2013 ; 62 : 363-371.