



## One-year follow-up of platelet-rich plasma infiltration to treat chronic proximal patellar tendinopathies

Jean-François KAUX, Olivier BRUYERE, Jean-Louis CROISIER, Bénédicte FORTHOMME,  
Caroline LE GOFF, Jean-Michel CRIELAARD

*From Physical Medicine and Sports Traumatology Department, University and University Hospital of Liège, Liège, Belgium*

**Infiltration of Platelet-Rich Plasma (PRP) may be considered as a recent therapeutic option for chronic tendinopathies. The aim of this study is to evaluate the clinical status and the return to sports activities in patients with chronic proximal patellar tendinopathies.**

**Twenty subjects with chronic proximal patellar tendinopathy benefited from 1 infiltration of PRP coupled with a standardized eccentric rehabilitation. The follow-up (up to 1 year) was assessed by means of a Visual Analogue Scale (VAS), the International Knee Documentation Committee (IKDC) form and the Victorian Institute of Sport Assessment (VISA-P) score. Moreover, subjects had to answer an information questionnaire concerning their life and sports activities.**

**Seventy percents of the patients reported a favourable evolution with decrease of pain, and returned to sports activities. With time, VAS dropped significantly and both IKDC and VISA-P scores improved also significantly.**

**This study confirms that a local injection of PRP coupled with a program of eccentric rehabilitation for treating a chronic jumper's knee, improves pain symptoms and the functionalities of the subjects' knee up to 1 year after injection.**

**Keywords :** platelet-rich plasma ; PRP ; jumper's knee ; patellar tendinopathy ; sport ; apheresis.

## INTRODUCTION

Tendinopathy is highly prevalent and is one of the most frequently self-reported musculoskeletal issues in sportsmen and physical workers (13). Jumper's knee is a frequent chronic overuse syndrome of the proximal part of the patellar tendon (13). Conservative treatments are not completely satisfactory and the recurrence of symptoms is

- 
- Jean-François Kaux.
  - Jean-Michel Crielaard.  
*Physical Medicine and Sports Traumatology Department, University and University Hospital of Liège, Liège, Belgium.*
  - Olivier Bruyère.  
*Department of Public Health, Epidemiology and Health Economics, University of Liège, Liège, Belgium.*
  - Jean-Louis Croisier.
  - Bénédicte Forthomme.  
*Physiotherapy Service, Department of Motility Sciences, University of Liège, Liège, Belgium.*
  - Caroline Le Goff.  
*Department of Clinical Biology, University Hospital of Liège, University of Liège, Liège, Belgium.*
- Correspondence : Jean-François Kaux, Physical Medicine and Sport Traumatology, University Hospital of Liège, Avenue de l'Hôpital, B35, 4000 Liège, Belgium.  
E-mail : jfkaux@chu.ulg.ac.be  
© 2015, Acta Orthopædica Belgica.
- 

*This study was supported by the Lejeune-Lechien Foundation and the ADEPS grants of the Léon Frédéricq Funds.*

*Conflict of interest : Fresenius-Kabi lent us the apheresis machine COM.TEC for the study, but the CS5L kits were bought.*

common. This is why different experimental treatments are now being developed including Platelet-Rich Plasma (PRP) infiltration (9). By releasing different platelet growth factors, PRP may be a new therapeutic option for chronic tendinopathies (21). Its ease of preparation, relatively low cost, and minimal invasiveness are arguments in its favour (21). Moreover, PRP has been removed from the doping drugs list of the World Anti-Doping Agency since 2011. Despite the proven efficacy of PRP in tissue regeneration *in vitro* (11), there is currently little tangible clinical evidence for its effectiveness in chronic tendon disorders (9,21). The few studies that have been performed appear difficult to compare; they use different PRP preparations with varying qualities (15), various injection methods, and different post-infiltration protocols (9,21). Moreover, data on long-term results are lacking (9,21).

The objective of this study is to evaluate the clinical status and return to sporting activities in patients with chronic superior patellar tendinopathies 1 year after 1 infiltration of PRP and to assess how this date evolved since the 3-month follow-up evaluation (10).

## MATERIALS AND METHODS

This is a 1-year follow-up of our previous published prospective case series (10), which was accepted by the Ethic Committee of our institution. We used an experimental protocol according to our first study (10).

Twenty patients (17 men and 3 women, mean age  $28.8 \pm 8.2$  y.o.) with a chronic proximal patellar tendinopathy (diagnosed clinically and confirmed by ultrasounds and/or magnetic resonance imaging) for more than 3 months (mean 17.6 months; from 4 to 62 months) were recruited in our Physical Medicine and Sports Traumatology Department (after having signed an informed consent form), and met the following inclusion criteria: proximal patellar tendinopathy for longer than 3 months, and no satisfactory improvement after 3 months of conservative management (including eccentric intervention and shock wave therapy). No treatment could be applied during the last month before infiltration of PRP. The sports they practiced were (some subjects practiced more than 1 sport): soccer (n = 8), jogging (n = 4), basketball (n = 3), karate (n = 3), volleyball (n = 2), tennis (n = 2), judo (n = 2), mountain biking (n = 2) and boxing (n = 1).

Due to pain, their sports capacities were decreased or impossible.

Platelets were collected using an apheresis machine (COM.TEC and kit CS5L, Fresenius-Kabi, Bad-Homburg, Germany) (18). This machine offered a reproducible PRP from the autologous blood of each patient, with only very limited concentration of white and red blood cells (18). We decided to collect platelets with a concentration of around  $8-9 \cdot 10^9$  platelets/ $\mu$ L (18). Just before infiltration, 300  $\mu$ L of CaCl<sub>2</sub> were added to the PRP to activate the platelets. Six millilitres of PRP were injected in the patellar tendon after disinfection without local anaesthetic (7). In case of pain, they could not take any anti-inflammatory drugs, but only classical painkillers, up to 3 months after the infiltration. After one week of relative rest, they started a standardised progressive sub-maximal eccentric program supervised by a physical therapist, 3 times a week, 5 sessions of 15 repetitions, for 6 weeks (14). This eccentric exercise was done using the weight of the patient's body, with the back against the wall. The patient would slide slowly his back down the wall until his pathologic leg would be bent at 60° before pushing on both legs to return to the starting position. The angulation and the number of sessions were progressively increased during the reeducation, respectively from 60° to 90° and from 5 to 7 sessions of 15 to 20 repetitions. Thirty seconds of rest were allowed between the sessions. The patient benefited also from electro-stimulation, stretching of the quadriceps, and cryotherapy. Ten minutes of cycloergometer with low resistance were also added to the program after 2 post-infiltrative weeks, and proprioception exercises were introduced after 1 month.

After six weeks they were authorised to start progressively their sports activities. However, they were encouraged to apply ice locally after efforts and to continue their eccentric exercises individually following the same eccentric and stretching modalities. The mean score of compliance with the auto-reeducation was calculated using a scale from 0 (no compliance) to 10 (maximum compliance).

One year after infiltration, patients were contacted by phone by the same examiner who reproduced, as much as possible, the same evaluation condition as for the 3-month follow-up. Estimate of pain intensity quantified on a VAS was compared to date before infiltration and 3 months after infiltration. Similarly, the VISA-P and IKDC scores were compared at these 3-time points. Patients were also asked to fill out a standardised questionnaire on the pain severity and the return to sports activities:

- pain during daily, professional and sports activities ;
- the sport they practiced (the same or not as before tendinopathy) ;
- the level of sport they practiced (the same or not as before tendinopathy).

Results were expressed as the mean  $\pm$  standard deviation of the mean (SD) or as percentages. The comparisons before infiltration and after 3 months and 1 year were made using an ANOVA. Pearson correlation coefficients were used to assess the relationship between changes in various outcomes. Changes in the various outcomes observed after 12 months of follow-up were also compared between patients with a 3-month change in symptoms below or over the median. The results were regarded as significant at the level of 5% ( $p < 0.05$ ). Statistical analyses were done with the software Statistical Analysis System, version 9.1 (SAS Institute, Caro, NC).

## RESULTS

The concentration of the PRP used for the infiltration was  $884.88 \pm 70.82 \times 10^3/\mu\text{L}$ , with nearly no red ( $< 0.001 \times 10^6/\mu\text{L}$ ) or white cells ( $< 0.001 \times 10^3/\mu\text{L}$ ). No significant difference was observed between platelet concentrations of the PRP injected in the whole group of patients.

After 3 months, from the 20 patients, 15 were able to return to sport (75%) : 10 to the same sport as before infiltration (50%) and 7 to the same level of practice (35%) ; 5 (25%) had still a disabling pain which prevent them to return to sport. After 1 year, 14 (70%) reported a favourable evolution with a significant decrease or disappearance of pain, 3 (15%) reported no improvement and 3 (15%) were treated surgically. From these 3 patients who benefited from surgery, 1 had still significant pain during physical activities and 1 during daily activities.

At one year of follow-up, 12 subjects (60%) reported no pain during daily activities and 11 (55%) reported no pain during their job (especially 6 subjects who were physical workers). Fourteen (70%) returned to sports activities (soccer ( $n = 6$ ), jogging ( $n = 4$ ), basketball ( $n = 2$ ), karate ( $n = 1$ ), volleyball ( $n = 2$ ), tennis ( $n = 1$ ), judo ( $n = 2$ ) and mountain biking ( $n = 1$ )). From these subjects who returned to sport, 64.3% did not feel any pain, and 50% of them recovered the same sport level. We have also ob-

served that patients who were younger (less than 26.5 y.o.) had been more able to return to sport and to practice it more often each week ( $p = 0.003$ ).

VAS scores dropped significantly with time ( $p < 0.0001$ ) : from  $6.3 \pm 1.9 /10$  before infiltration to  $2.6 \pm 2.3 /10$  at 3 months and to  $1.4 \pm 2.1 /10$  at 1 year (Fig. 1a). Moreover, patients who had a shorter history of pain (less than 10.5 months) seemed to have a better improvement of VAS after 1 year ( $p = 0.06$ ).

IKDC scores significantly increased with time ( $p = 0.0007$ ) from  $52.7 \pm 16.0$  before infiltration, to  $61.8 \pm 23.3$  after 3 months and to  $77.0 \pm 26.5$  after 1 year (Fig. 1b). VISA-P scores also significantly increased with time ( $p = 0.0087$ ) from  $47.9 \pm 20.1$  before infiltration, to  $65.6 \pm 26.4$  after 3 months and  $74.2 \pm 26.6$  after 1 year (Fig. 1c). This corresponds to a mean improvement of 74.2% over a year.

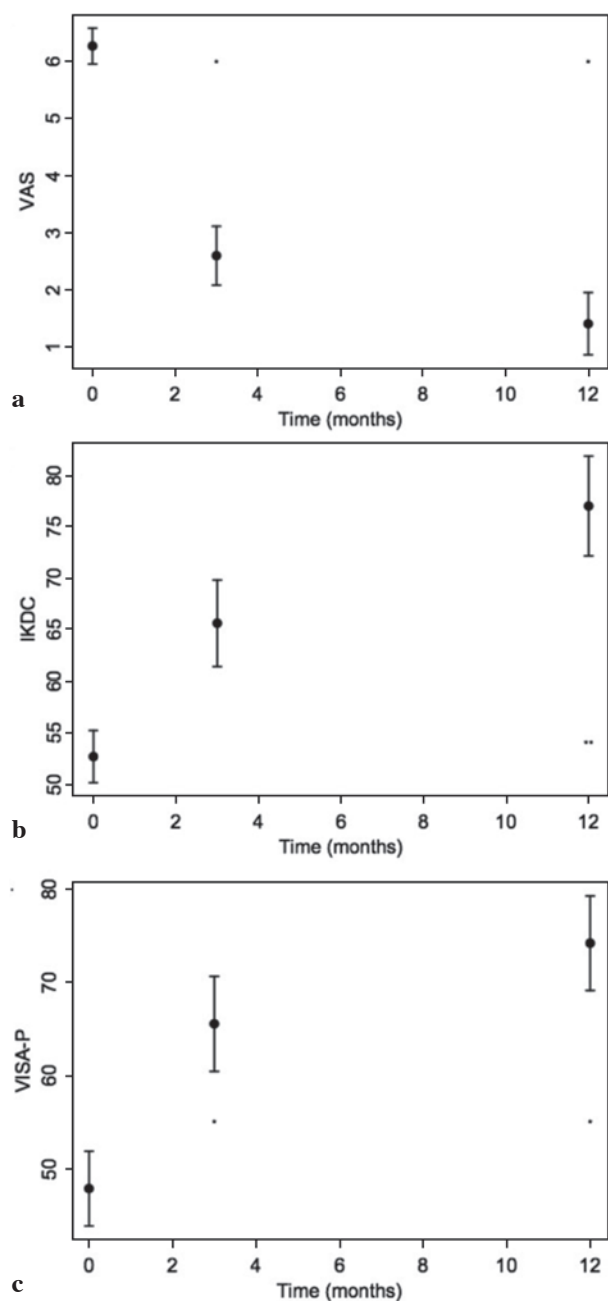
Finally, patients who had the greatest reduction of pain after 3 months of follow-up also had a better improvement after 1 year ( $p = 0.0004$ ) and they had been able to practice sport activities more often ( $p = 0.007$ ).

The compliance to auto-reeducation was  $79.2 \pm 12.8 \%$  ( $7.92 \pm 1.28/10$ ).

## DISCUSSION

Platelet-rich plasma is a relatively innovative treatment for chronic tendinopathies (13). During degranulation, platelets release various cytokines and growth factors which promote angiogenesis, tissue remodelling, and tendon healing (21). Even if, in vitro and animal experiments have demonstrated this stimulation of tendon healing process (11), clinical series are subject to controversy (9). Indeed, various papers seem to show a benefit to use PRP in case of tendinopathy, but one randomized controlled trial on Achilles tendinopathies did not show any improvement linked to PRP infiltrations (3). Moreover, most of the studies evaluated the PRP effects only at short to medium-term (9). Our study followed infiltrated patients up to 1 year, evaluating a longer term evolution of the clinical healing process of proximal patellar tendinopathy.

The following considerations were not the aim of this study but it is essential to remember that these



**Fig. 1.** — Results for the VAS, IKDC and VISA-P scores before infiltration, after 3 months and 1 year. \*  $p < 0.05$  with time pre-injection ; \*\*  $p < 0.05$  with 6 weeks.

elements could condition the efficacy of PRP treatment. Up to now, there is no general agreement on the method to prepare PRP and each technique provides a very different PRP (15), with variations in

the platelet concentrations and in the amount (if any) of red and white blood cells. Leukocytes could adversely affect wound healing through the release of pro-inflammatory factors responsible for extracellular matrix degradation (3) and lead to a bigger early local inflammation (20). In addition, erythrocyte lysis releases free radicals that harm tissue structures (5). Therefore, a strength of our study is that we used an apheresis machine that provided a reproducible PRP from one patient to another. The platelet concentration was always around  $8.5-9 \times 10^5/\mu\text{L}$ , and it contained nearly no red or white blood cells, corresponding to P3-x-A $\alpha$  of the PRP «PAW» classification system (8).

Three months after the infiltration of PRP, 75% of the patients were able to return to sport. From these subjects, 67% were able to practice the same sport as before infiltration and 47% to the same level of practice. Twenty-five percent of patients still experienced pain during physical activities and few patients stopped practicing sports (10%) (10). Among the subjects followed over one year, 15% of them underwent surgery after the 3-month follow-up. Out of these 3 patients, only 1 reported a complete relief of pain ; 1 still felt pain during physical activities and 1 during daily living activities.

Until now, eccentric training has appeared to be the treatment of choice for patients suffering from patellar tendinopathy (2). It has been demonstrated on rat tendons that a mechanical stimulation optimises the healing process of a tendon after PRP use (17), and that eccentric training is more efficient than concentric training to improve tendon biomechanical properties (22). Moreover, this mechanical stimulation would have to be initiated as soon as possible after PRP infiltration because platelets stimulate especially the early phases of tendon healing process (11). Short after the infiltration of PRP, it is thus necessary to apply sub maximal eccentric loads, without causing pain, to guide the tendon cicatrisation process and to improve its healing (17).

To observe the effect of PRP associated with an eccentric program on chronic superior patellar tendinopathies and rebel to conservative treatments, at 12 months, the clinical evolution of patients (without surgery) was evaluated using an EVA, as well as the IKDC and VISA-P scores. These results were

compared to the data established pre-injection and 3 months post-injection (10).

Pain intensity has decreased very significantly, as evidenced in the evolution of the EVA, the IKDC and VISA-P to 1 year. Moreover, we observed that 70% of the patients were able to resume sports activity, including half to an identical level as previously, and almost  $\frac{2}{3}$  did not feel any pain even during their sport activities. These results therefore show a decrease of the level of sporting activity that would not be related to pain nor function as observed by algo-functional scores, but rather to an apprehension. Our results are similar to those presented in the literature (12,16), although in these studies, 3 infiltrations were conducted, and no assessment had been done after the first single infiltration. Interestingly, our results at 1 year could be compared to those obtained with eccentric reeducation or shockwave therapy in case of less rebel patellar tendinopathy, since included patients were rebels to this treatment. However, our 1-year results are better than those obtained with corticoid infiltration even if early results could be better with this latter (6). Finally, return to sport could perhaps be improved if it could be initiated with a taping or bracing device to protect the tendon (4).

From this study, we can retain the following clinical implications. Patient who had the best improvement 1 year after the infiltration of PRP were younger (< 26.5 y.o.), with a shorter history of pain (< 10.5 months), and had also shown also a better improvement after 3 months of follow-up. It is well-known that tendon healing process may take up to 6 months to 1 year. The third month after infiltration could thus be considered as the cut-off time to evaluate the potential efficacy of a second PRP infiltration (1) or to guide patients towards alternative treatments (i.e. surgery) in case of failure of this conservative treatment.

However, our study had some limitations. First, due to the absence of a favourable evolution with a non-invasive therapeutic, it was not ethical, as in our previous study (10), to propose this type of treatment as placebo. This study was thus prospective with a follow-up of 1 year. Second, the progressive sub-maximal eccentric program would be more standardized and controlled if the exercises were

performed on an isokinetic dynamometer, but this device is not available at each physiotherapist's practice. Third, our 1-year follow-up could have been made in the same way than the 3-months follow-up (10), using functional tests and imagery. However, we would have had a lot of drop-out patients. Indeed, some subjects were abroad and some returned to work and had less availability for our study. Contacting them by phone, allowed us to collect data for all the 20 subjects.

## CONCLUSIONS

This study confirms that a local injection of PRP coupled with a program of eccentric rehabilitation to treat a jumper's knee, improves significantly pain symptoms and functionalities of the subjects' knee up to 1 year. Most of the subjects (70%) were able to return to sport and half of them recovered the same level of sport activities.

## REFERENCES

1. **Dallaudiere B, Meyer P, Hummel V et al.** Efficacy of second intra-tendinous platelet-rich-plasma injection in case of incomplete response of the first injection : three-year follow up experience. *Diagn Interv Imaging* 2013 ; 94 : 871-877.
2. **DeLong JM, Russell RP, Mazzocca AD.** Platelet-rich plasma : the PAW classification system. *Arthroscopy* 2012 ; 28 : 998-1009.
3. **de Vos RJ, Weir A, van Schie HT et al.** Platelet-rich Plasma injection for chronic Achilles tendinopathy : a randomized controlled trial. *JAMA* 2010 ; 303 : 144-149.
4. **de Vries AJ, van den Akker-Scheek I, Diercks RL, Zwerver J, van der Worp H.** Effect of patellar strap and sports tape on jumper's knee symptoms : protocol of a randomised controlled trial. *J Physiother* 2013 ; 59 : 270.
5. **Dragoo JL, Braun HJ, Durham JL et al.** Comparison of the acute inflammatory response of two commercial platelet-rich plasma systems in healthy rabbit tendons. *Am J Sports Med* 2012 ; 40 : 1274-1281.
6. **Filardo G, Kon E, Di Matteo B, Pelotti P, Di Martino A, Marcacci M.** Platelet-rich plasma for the treatment of patellar tendinopathy : clinical and imaging findings at medium-term follow-up. *Int Orthop* 2013 ; 37 : 1583-9.
7. **Foster TE, Puskas BL, Mandelbaum BR, Gerhardt MB, Rodeo SA.** Platelet rich plasma : from basic science to clinical applications. *Am J Sports Med* 2009 ; 37 : 2259-2272.

8. **Jiang N, Tan NS, Ho B, Ding JL.** Respiratory protein-generated reactive oxygen species as an antimicrobial strategy. *Nat Immunol* 2007 ; 8 : 1114-1122.
9. **Kaux JF, Crielaard JM.** Platelet-rich plasma application to treat chronic tendinopathies : a review. *Acta Orthop Belg* 2013 ; 79 : 10-15.
10. **Kaux JF, Crosier JL, Bruyère O et al.** One injection of platelet-rich plasma associated to a submaximal eccentric protocol to treat chronic jumper's knee. *J Sports Med Phys Fit*, in press.
11. **Kaux JF, Drion PV, Colige A et al.** Effects of platelet-rich plasma (PRP) on the healing of Achilles tendons of rats. *Wound Repair Regen* 2012 ; 20 : 748-756.
12. **Kaux JF, Drion P, Libertiaux V et al.** Eccentric training improves tendon biomechanical properties : A rat model. *J Orthop Res* 2013 ; 31 : 119-124.
13. **Kaux JF, Forthomme B, Le Goff C, Crielaard JM, Croisier JL.** Current opinion on tendinopathy. *J Sports Sci Med* 2011 ; 10 : 238-253.
14. **Kaux JF, Forthomme B, Namurois MH et al.** Description of a standardized rehabilitation program based on submaximal eccentric following a platelet-rich plasma infiltration for jumper's knee. *Muscles Ligaments Tendons J* 2014 ; 4 : 85-89.
15. **Kaux JF, Le Goff C, Seidel L et al.** [Comparative study of five techniques of preparation of platelet-rich plasma]. *Pathol Biol (Paris)* 2011 ; 59 : 157-160.
16. **Kon E, Filardo G, Delcogliano M et al.** Platelet-rich plasma : new clinical application : a pilot study for treatment of jumper's knee. *Injury* 2009 ; 40 : 598-603.
17. **Larsson ME, Käll I, Nilsson-Helander K.** Treatment of patellar tendinopathy – a systematic review of randomized controlled trials. *Knee Surg Sports Traumatol Arthrosc* 2012 ; 20 : 1632-46.
18. **Lopez-Vidriero E, Goulding KA, Simon DA, Sanchez M, Johnson DH.** The use of platelet-rich plasma in arthroscopy and sports medicine : optimizing the healing environment. *Arthroscopy* 2010 ; 26 : 269-78.
19. **Moog R, Zeiler T, Heuft HG et al.** Collection of WBC-reduced single-donor PLT concentrates with a new blood cell separator : results of a multicenter study. *Transfusion* 2003 ; 43 : 1107-1114.
20. **Pizza FX, McLoughlin TJ, McGregor SJ, Calomeni EP, Gunning WT.** Neutrophils injure cultured skeletal myotubes. *Am J Physiol Cell Physiol* 2001 ; 281 : C335-C341.
21. **Smets F, Croisier JL, Forthomme B, Crielaard JM, Kaux JF.** Applications cliniques du Plasma riche en plaquettes (PRP) dans les lésions tendineuses : revue de la littérature. *Science & Sport* 2012 ; 27 : 141-153.
22. **Virchenko O, Aspenberg P.** How can one platelet injection after tendon injury lead to a stronger tendon after 4 weeks ? Interplay between early regeneration and mechanical stimulation. *Acta Orthop* 2006 ; 77 : 806-12.