



## Unusual localizations of unicameral bone cysts and aneurysmal bone cysts : A retrospective review of 451 cases

Osman Emre AYCAN, İsmet Yalkın ÇAMURCU, Devrim ÖZER, Yavuz ARIKAN, Yavuz Selim KABUKÇUOĞLU

*From Baltalimanı Bone Diseases Training and Research Hospital, Orthopaedic Oncology Clinic, Istanbul, Turkey*

Unicameral bone cysts (UBC) and aneurysmal bone cysts (ABC) are benign cystic lesions of bone which are easily diagnosed. However, unusual locations may lead to a false diagnosis. Therefore the aim of this retrospective study was to determine the frequency of unusual localizations. The authors studied 451 cases with histopathologically confirmed diagnosis of UBC or ABC, seen between 1981 and 2012. In the UBC group (352 cases) humerus, femur and calcaneus were found to be the most common sites, while acetabulum, scapula, scaphoid, lunatum, metacarpals, metatarsals, toe phalanges and ulna each accounted for less than 1%. In the ABC group (99 cases) the most common sites of involvement were femur, humerus and tibia, while finger phalanges, ilium, acetabulum, pubis, calcaneus, cuboid, and toe phalanges each accounted for only 1%. The differential diagnosis of cystic bone lesions should include both UBC and ABC. Pain complaints plead for the latter, except in case of fracture.

**Keywords:** unicameral bone cyst; aneurysmal bone cyst; unusual localizations.

### INTRODUCTION

Unicameral bone cyst (UBC) has a predilection for the metaphyseal region of the major long bones, particularly the proximal humerus and the femoral neck, but has been described in almost all sites, including the flat bones and the spine (7). In aneurysmal bone cyst (ABC) primary sites of involvement

include long bones of lower extremity, vertebrae, long bones of upper extremity and flat bones (18). The aim of this retrospective study on 451 cases was to determine the frequency of unusual localizations.

### MATERIALS AND METHODS

Between 1981 and 2012, 451 patients were seen with histopathologically confirmed diagnosis of unicameral bone cyst (352 cases, 64.4% males/35.6% females; mean age 21.3 years, range 2-83) or aneurysmal bone cyst (99 cases, 45.4% males/54.6% females; mean age 17.3, range 2-57). Their case records were retrospectively studied.

### RESULTS

A unicameral bone cyst (UBC) was seen in 352 out of 451 patients (78%) (Table I) (Fig. 1). The

- 
- Osman Emre Aycan, MD.
  - İsmet Yalkın Çamurcu, MD.
  - Devrim Özer, MD.
  - Yavuz Arıkan, MD.
  - Yavuz Selim Kabukçuoğlu, MD, Associate Professor.  
*Baltalimanı Bone Diseases Training and Research Hospital, Orthopaedic Oncology Clinic, Istanbul, Turkey.*
- Correspondence : Osman Emre Aycan, Baltalimanı Bone Diseases Training and Research Hospital, Orthopaedic Oncology Clinic, Rumelihisarı Caddesi 62, 34470 Istanbul, Turkey.  
E-mail : emre\_md@yahoo.com

© 2015, Acta Orthopædica Belgica.

---

Table I. — Unicameral bone cysts (n = 352)

Localizations	
Humerus	36.5%
femur	28.6%
calcaneus	13.8%
tibia	7.9%
fibula	3.9%
radius	1.6%
talus	1.4%
finger phalanges	1.4%
ilium	1.1%
acetabulum	0.8%
scapula, scaphoid, lunatum, metacarpals, metatarsals, toe phalanges each :	0.77%
ulna	0.5%

Table II. — Aneurysmal bone cysts (n = 99)

Localizations	
femur	20.2%
humerus	15.1%
tibia	13.1%
fibula	11.1%
metacarpals	6.1%
talus	6.1%
clavicle	5.1%
ulna	5.1%
metatarsals	4.04%
radius	3.03%
vertebrae	2.02%
finger phalanges, ilium, acetabulum, pubis, calcaneus, cuboid, toe phalanges each	1%

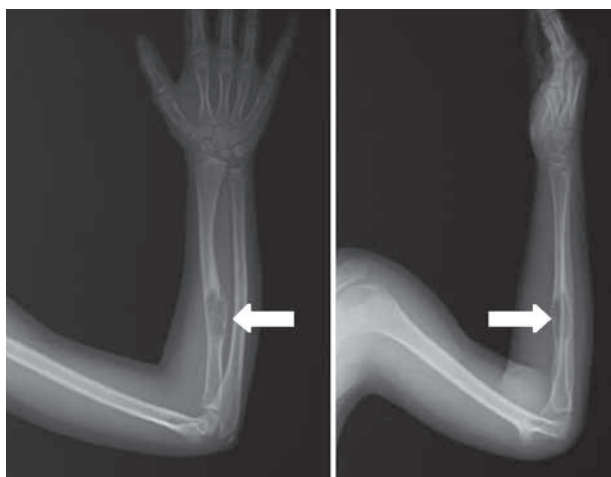

Fig. 1. — AP and lateral view of the right forearm in an 11-year-old boy : unicameral bone cyst. Localization rather unusual.

distribution of the cysts was as follows : humerus 36.5%, femur 28.6%, calcaneus 13.8%, tibia 7.9%, fibula 3.9%, radius 1.6%, talus 1.4%, finger phalanges 1.4%, ilium 1.1%, acetabulum 0.8%, scapula, scaphoid, lunatum, metacarpals, metatarsals, toe phalanges each 0.77%, ulna 0.5%.

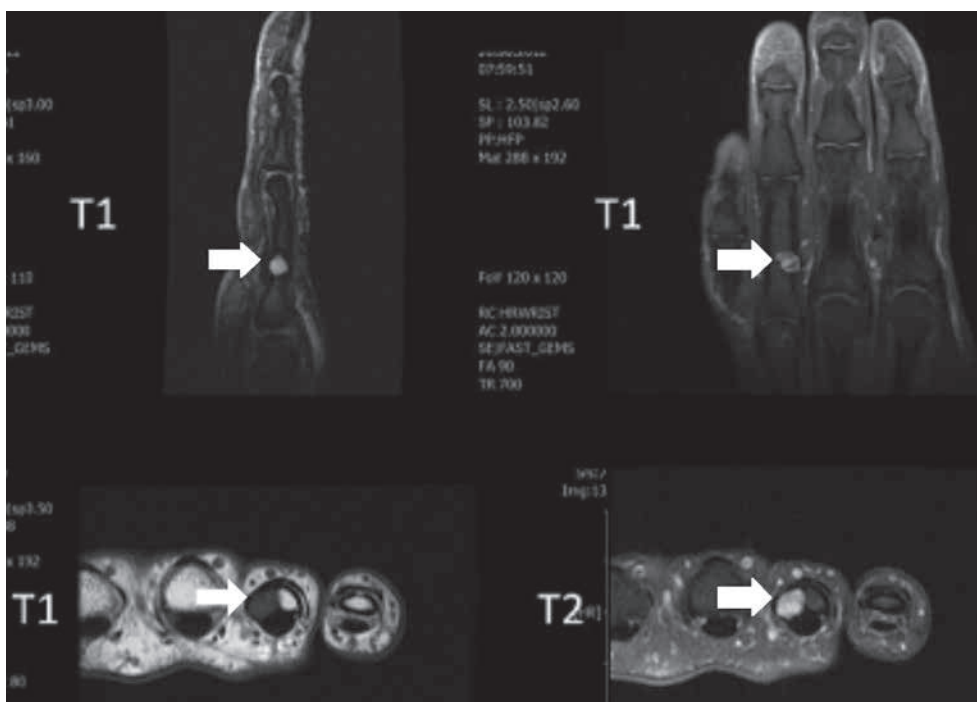
An aneurysmal bone cyst (ABC) was noted in 99 out of 451 patients (22%) (Table II) (Fig. 2, 3). The distribution was as follows : femur (20.2%), humerus 15.1%, tibia 13.1%, fibula 11.1%, metacarpals 6.1%, talus 6.1%, clavicle 5.1%, ulna 5.1%, meta-

tarsals 4.04%, radius 3.03%, vertebrae 2.02%, finger phalanges, ilium, acetabulum, pubis, calcaneus, cuboid, toe phalanges each 1%.

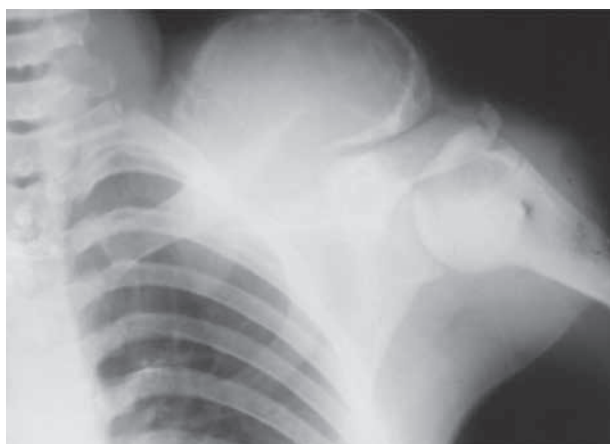Interestingly, metacarpal and metatarsal lesions were predominantly aneurysmal bone cysts (10 of 12 cases, or 83.3%).

## DISCUSSION

The entity *unicameral bone cyst* was first recognized by Virchow in 1876. The etiology is still unknown. UBC constitutes 3% of all bone tumors. It usually involves the metaphysis of a long bone, especially the proximal humerus and the proximal femur (9). Tumors and tumor-like lesions of the calcaneus are rare, but unicameral bone cyst is the most common benign tumor of the calcaneus (2,13). UBC is more common in males (3:1, but 2:1 in the current series) and is usually detected during the first two decades of life (12). The authors found that humerus, femur and calcaneus were the most frequent localizations (together 78.9%), which confirms the data from the literature. As to carpal bone involvement, only scaphoid, lunatum and capitatum have been reported (16). Only 4 cases of unicameral bone cyst have been reported in the hand (6) ; the differential diagnosis with enchondroma, aneurysmal bone cyst and intraosseous ganglion cyst is mandatory. Most UBCs are asymptomatic and



**Fig. 2.** — MRI images of the right fourth proximal phalanx in a 54-year-old woman : aneurysmal bone cyst with a fluid level. A relatively rare localization.



**Fig. 3.** — AP view of the left shoulder in a 19-year-old woman : aneurysmal bone cyst in the lateral part of the clavicle.

constitute incidental radiographical findings. They can also be brought to light by a pathologic fracture. UBCs seldom persist beyond early adult life (7), but can occasionally be seen in elderly persons, up to 83 years in the current series.

*Primary aneurysmal bone cyst* (ABC) is a rare expansile osteolytic tumor, representing 1.4% of the primary bone tumors ; it is usually diagnosed at adolescence, and has no predilection for males or females (7,10,14,22). This lesion may be encountered in any bone, however most commonly in the long bones and in the spine (3). The metaphyseal regions of the knee are the most common sites of involvement (5,7,19). Up to 1975 the literature mentioned only 25 aneurysmal bone cysts of the clavicle (4) (Fig. 3). Until 2012 only 20 ABCs of the talus have been reported (20) ; the authors treated 6 primary ABCs of the talus since 1981.

The differential diagnosis between UBC and ABC is important, as both tumors are most frequently seen in the first two decades. It may be helpful that aneurysmal bone cyst patients generally present with pain and swelling, unlike UBC patients, except in case of fracture through the cyst. Moreover, in the current series ABCs were more frequently situated in unusual locations (frequency less than 10%) than UCBs : about 38% versus 23%.

## REFERENCES

1. **Barbary S, Métais P, Dautel G.** Reconstruction of the trapeziometacarpal joint and the first metacarpal bone by reversed free osteocutaneous dorsalis pedis flap. *Chir Main* 2007 ; 26 : 232-234.
2. **Bullough PG.** In : *Bullough and Vigorita's Orthopedic Pathology*. 3rd ed, Mosby-Wolfe, Baltimore, 1997, pp 402-405.
3. **Campanacci M.** Aneurysmal bone cyst. In : *Bone and Soft Tissue Tumors*. Springer-Verlag, Wien, 1986, pp 725-751.
4. **Chadha M, Singh AP.** Aneurysmal bone cyst of the clavicle. *Can J Surg* 2008 ; 51 : E32-33.
5. **Dabezies EJ, D'Ambrosia RD, Chuinard RG, Ferguson AB Jr.** Aneurysmal bone cyst after fracture. A report of three cases. *J Bone Joint Surg* 1982 ; 64-A : 617-621.
6. **Diaz VA, Vernon SE, Ouellette EA.** Pain and deformity of the index finger in a 41-year-old woman. *Clin Orthop Relat Res* 2009 ; 467 : 1387-1391.
7. **Enneking WF.** Tumor-like lesions. In : *Musculoskeletal Tumor Surgery*. 1<sup>st</sup> edition, vol. 2. Churchill Livingstone, New York, 1983, pp 1492-1513.
8. **Fillingham YA, Lenart BA, Gitelis S.** Function after injection of benign bone lesions with a bioceramic. *Clin Orthop Relat Res* 2012 ; 470 : 2014-2020.
9. **Günder H, Sahin M, Alici T.** Unicameral bone cyst of the lunate in an adult : case report. *J Orthop Surg Res* 2010 ; 5 : 79.
10. **Jaffe HL, Lichtenstein L.** Solitary unicameral bone cyst with emphasis on the roentgen picture, the pathologic appearance and the pathogenesis. *Arch Surg* 1942 ; 44 : 1004-1025.
11. **Jain SK, Nathan SS.** An unusual presentation of a simple bone cyst in the scapula. *Musculoskelet Surg* 2012 ; 96 : 227-231.
12. **Javdan M, Zarezadeh A, Gaulke R, Eshaghi MA, Shemshaki H.** Unicameral bone cyst of the scaphoid : a report of two cases. *J Orthop Surg (Hong Kong)* 2012 ; 20 : 239-242.
13. **Ly JQ, LaGatta LM, Beall DP.** Calcaneal chondroblastoma with secondary aneurysmal bone cyst. *AJR Am J Roentgenol* 2004 ; 182 : 130.
14. **Nayak A, Kulkarni S, Kulkarni A, Natesh K, Bami M.** Aneurysmal bone cyst of the pubis : a case report. *J Clin Diagn Res* 2013 ; 7 : 1740-1742.
15. **Nonnenmacher J, Bahm J, Laforest P, Kempf I.** Aneurysmal cyst of the proximal radius : resection and free vascularized fibular bone graft. *Microsurgery* 1993 ; 14 : 280-284.
16. **Norman A, Schiffman M.** Simple bone cysts : factors of age dependency. *Radiology* 1977 ; 124 : 779-782.
17. **O'Brien MS, Donnell A, Miller J, Iven VG, Pascale M.** An abnormal bone lesion of the scapula in a collegiate basketball player : A Case Report. *J Athl Train* 2013 ; 48 : 859-863.
18. **Papagelopoulos PJ, Choudhury SN, Frassica FJ, Bond JR, Unni KK, Sim FH.** Treatment of aneurysmal bone cysts of the pelvis and sacrum. *J Bone Joint Surg* 2001 ; 83-A : 1674-1681.
19. **Parashari UC, Khanduri S, Upadhyay D, Bhadury S, Singhal S.** Radiologic and pathologic correlation of aneurysmal bone cysts at unusual sites. *J Cancer Res Ther* 2012 ; 8 : 103-105.
20. **Sharma S, Gupta P, Sharma S, Singh M, Singh D.** Primary aneurysmal bone cyst of talus. *J Res Med Sci* 2012 ; 17 : 1192-1194.
21. **Sung AD, Anderson ME, Zurakowski D, Hornicek FJ, Gebhardt MC.** Unicameral bone cyst : a retrospective study of three surgical treatments. *Clin Orthop Relat Res* 2008 ; 466 : 2519-2526.
22. **Tornetta P, Morris CD, Einhorn TA, Damron TA.** Benign tumors of bone. In : *Oncology and Basic Science*. 7th edition . Lippincott, Williams and Wilkins, a Wolters Kluwer business, Philadelphia, 2008, pp 54-79.
23. **Vergel De Dios AM, Bond JR, Shives TC, McLeod RA, Unni KK.** Aneurysmal bone cyst. A clinicopathologic study of 238 cases. *Cancer* 1992 ; 69 : 2921-2931.
24. **von Kieseritzky J, Widenfalk B.** Treatment of a large aneurysmal bone cyst in a 15-year-old boy using a corticospingial bone graft and a 12-year follow-up after operation. *J Plast Surg Hand Surg* 2012 ; 46 : 132-136.