



Acute acromioclavicular dislocation : a cheaper, easier and all-arthroscopic system. Is it effective in nowadays economical crisis ?

Sergi SASTRE, Michelle DADA, Simon SANTOS, Lluís LOZANO, Xavier ALEMANY, Lluís PEIDRO

From Orthopedic Surgery Department, Hospital Clinic, University of Barcelona, Spain

The objective of this manuscript is to show an effective, easier and cheaper way to reduce acute acromioclavicular (AC) dislocation type III and V (Rockwood classification). Numerous procedures have been described for surgical management of acromioclavicular joint disruption. Newest devices involve an arthroscopic technique that allows nonrigid anatomic fixation of the acromioclavicular joint. Arthroscopically assisted treatment of acute AC joint dislocation is advantageous because it provides good clinical results and few complications. It also allows reviewing glenohumeral associated lesions. This surgical technique requires no specific implants to achieve a correct AC reduction. Actually, economical advantages are very important factors to decide the use of determinate surgical techniques.

Keywords : acromioclavicular ; Suture repair ; surgery ; type III acromioclavicular dislocation ; economic cost.

INTRODUCTION

Acromioclavicular (AC) joint dislocation is a common shoulder injury that is often due to direct force from falling on the point of the shoulder with the arm adducted or with an extended and adducted arm. It mostly occurs in young athletes during sports activities. The treatment of these injuries is controversial and depends on the degree of dislocation, the patient's complaints, and the postinjury period.

Most types I and II AC joint separations are treated nonsurgically. Type III injuries are usually evaluated on a case-by-case basis, taking into account hand dominance, occupation, heavy labour, position/sport requirements, scapulothoracic dysfunction, and the risk of reinjury. Most authors agree that type IV, V, and VI injuries should be treated operatively with any one of the many described reconstructions. These injuries involve disruption of the AC and CC ligaments, significant clavicle displacement, and often disruption of the deltotracheal fascia (2). Some literature supports reduction of the clavicle in types IV, V, and VI injuries, to turn them into a type III injury that can be treated conservatively (9).

The arthroscopic procedure can be used to diagnose associated lesions in the glenohumeral joint. In arthroscopy, the AC joint can be accessed through small incisions, without the need to detach any

-
- Sergi Sastre.
 - Michelle Dada.
 - Simon Santos.
 - Lluís Lozano.
 - Xavier Alemany.
 - Lluís Peidro.

Orthopedic Surgery Department, Hospital Clinic, University of Barcelona, Spain.

Correspondence : Dr Sergi Sastre, Hospital Clínic de Barcelona, C/ Villarroel 170, 08036 Barcelona, Spain.

E-mail : ssastre@clinic.ub.es ; sastre@drsergisastre.com

© 2015, Acta Orthopædica Belgica.

tissue. Therefore, the postoperative recovery is faster, less painful, and with fewer complications.

This paper describes a new and modified surgical repair technique for acute complete AC joint separation. The procedure involves the use of 2 loops of nonabsorbable sutures passed under the base of the coracoid with arthroscopic assistance. This maintains the AC joint in the reduced position until the CC ligaments heal. This technique does not involve the use of any additional implants for fixation and the functional results are the same as those obtained in conventional surgery.

SURGICAL TECHNIQUE

The patient is placed in the beach-chair position under general anesthesia, and a pneumatic arm holder is used to position the upper extremity. The arm is prepared and draped in standard fashion, and appropriate antibiotic prophylaxis is administered before incision.

From posterior portal (F) we perform standard intrarticular diagnosis of possible associated lesions. From lateral (A) and anterior (B) portals (Fig. 1), without the use of arthroscopy canullas, we perform a bursectomy and debride the inferior zone of the coracoid using a coblator of radiofrequency. This enables us to visualize the base of the coracoid correctly (Fig. 2). Then, the anterior part of the coracoid body must be debrided, without detaching any of the structures. We only need to debride a zone large enough to view the posterior suture clearly and pass it under the coracoid. Special attention must be taken not to remove the coracoid insertion of the coracoacromial ligament neither the coracoid body insertion of the conjoined tendon.

With the arthroscope in portal B, we use a needle to place a portal anterior to the coracoid (C) (Fig. 1). With the help of a knotpusher, we insert a suture shuttle into this portal and under the inferior part of the body and base of the coracoid until it can be seen in the previously prepared inferior space. We do not use a cannula in this portal.

We insert an arthroscopic suture retriever into a Neviaser portal (D). We pass the retriever across the area of the damaged CC ligaments until it appears in the space inferior to the coracoid. There we retrieve

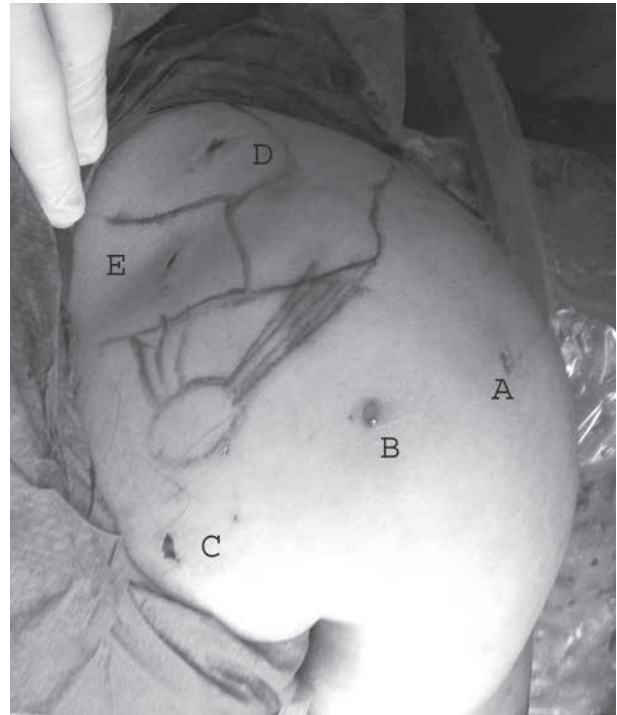


Fig. 1. — Five portals (A-D) used for this technique

the loop of the suture shuttle that was inserted from the anterior portal (C) (Fig. 3). The loop travels laterally to the conjoined tendon fibers and medially to the coracoacromial ligament.

In a portal superior to the clavicle (E) (Fig. 1), we insert an arthroscopic suture retriever. We pass this retriever across the area of the damaged CC ligaments until it appears in the space anterior to the coracoid that we prepared previously. There, we retrieve the other free end of the suture shuttle (Fig. 4).

Then, we retrieve both ends of the suture shuttle from the superior portal and use this same shuttle to pass 2 ultrabright sutures (Smith & Nephew Endoscopy Inc, Andover, Minnesota) that will make a loop from the superior part of the clavicle to the inferior part of the coracoid.

We tie a final, independent knot with the two sutures passed twice, so that four loops have been made to reduce the acromioclavicular joint in its correct position under arthroscopic control. The use of four sutures reduces the friction and the risk of osteolysis that could be caused by a single, high

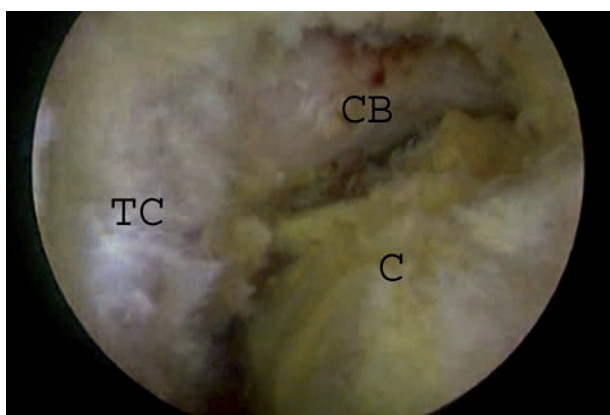


Fig. 2. — Subcoracoid arthroscopic view. Arthroscope in portal B. The inferior part of the base of coracoid (CB), the subscapular (C) and the tip of the coracoid (TC) are shown.

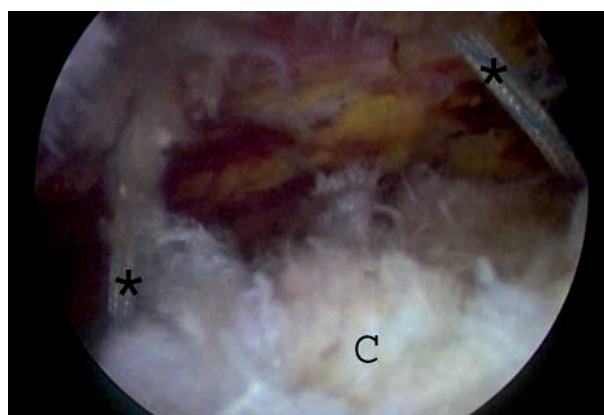


Fig. 4. — Supracoracoid arthroscopic view. Arthroscope in portal A. Both suture shuttle (*) around the base of the coracoid are shown.

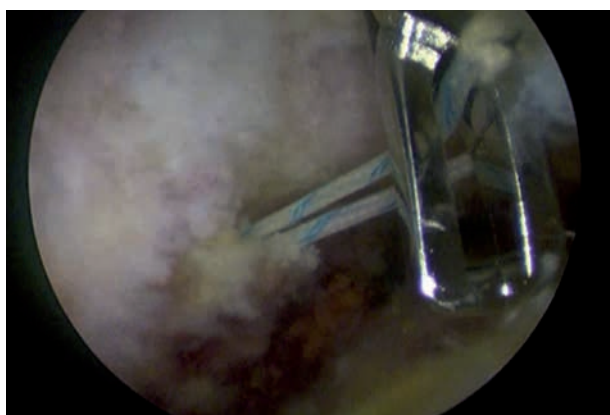


Fig. 3. — The same view of figure 2, with suture retriever into the Neviaser portal (D), we retrieve the loop of the suture shuttle that was inserted from the anterior portal (C).

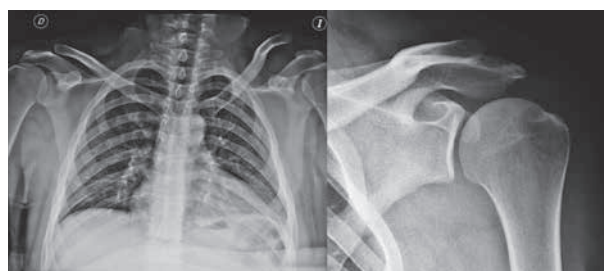

Fig. 5. — Radiographs with the initial lesion and final result 2 years follow-up.

strength suture on the clavicle and/or coracoid (Fig. 5). Plain radiographs allow to overview the correct dislocation reduction and its maintenance through the fixation system used.

DISCUSSION

The literature is replete with surgical techniques used to treat complete AC dislocations, including primary repair of the coracoclavicular ligaments, augmentation with autogenous tissue (coracoacromial ligament), augmentation with absorbable and nonabsorbable sutures as well as prosthetic material, the new techniques of distal clavicular resection

and reduction with osteosynthesis, and coracoclavicular stabilization with metal screws, among others (1-3,8).

In addition to being a minimally invasive system, one of the main advantages of using an arthroscope is that, during the surgical procedure, we can observe and treat concomitant injuries in the glenohumeral joint that may have been overlooked initially. Some case series have been described in which associated lesions were found in 15 to 18% of types III-V AC dislocations (10,12). The main concomitant injuries encountered in association with AC dislocations are SLAP lesions and supraspinatus muscle injuries (PASTA and complete lesions). These can be repaired in the same surgical procedure using the arthroscope.

Satisfactory results can be obtained with common open surgery techniques. However, no technique has emerged as the ideal treatment for these

injuries, as all involve surgery-related complications.

Acromioclavicular cerclage has good clinical and functional results (1,7) in conventional surgery. Many techniques have been described that use clavicular or coracoid tunnelling (4,6,8,11), including new implants that facilitate joint reduction and are positioned using arthroscopy (3,5). The main complications in tunnelling and fixation systems using monofilament sutures are aseptic reaction to the reconstruction, calcifications, erosion through the clavicle caused by the nonabsorbable materials used to augment the repair and reconstruction, fracture of the coracoid and osteolysis (3,5).

The main inconvenience of the CC cerclage is the subtle anteroposterior (horizontal) residual instability comparing to other more rigid systems such as the hook-plate which are capable of providing more stability (antero-posteriorly as well as superior-inferiorly). Nevertheless these systems require a second time surgery to remove the osteosynthesis material.

Our series of 5 patients operated by the arthroscopic technique has a minimum follow-up of 1 year (13-25 months). No complication related to the arthroscopic technique has arisen and all patients are back to previous activity.

A minimum loss of initial reduction was noted in one patient ; however it had no clinical effect. Another patient was diagnosed of Bankart lesion which was confirmed arthroscopically and was treated by the use of 3 impacted suture anchors.

Indications for this technique under our criteria would be acute type III AC dislocations, whereas type IV to VI require an open reduction. The limitations of this study are the number of patients. Further larger, prospective, randomized studies with Langer follow-up may finally clarify the place of this method.

The advantages of the system presented in this paper are as follows : it can be performed using an arthroscopic technique, it has very good clinical results, as demonstrated in open surgery series, and it is much cheaper than the current double flip button systems. As four suture threads are used, there is less pressure on the bone, so osteolysis and erosion are prevented. No further surgery is needed to extract implanted material, as required in other

techniques. The main advantage of the arthroscopic procedure versus the open surgery it is the fact that direct overview of the glenohumeral articulation is possible and therefore associated lesions can be assessed and dealt, as well as minor scars that could occur along the way. The main disadvantage is that anteroposterior stability is not maintained as rigidly as in other fixation systems (8).

REFERENCES

1. **Blatter G, Meier G.** Augmentation of the coraco-clavicular ligament suture. Comparison between wire cerclage, vicryl tape and PDS cord. *Unfallchirurg* 1990 ; 93 : 578-583.
2. **Bradley JP, Elkousy H.** Decision making : operative versus nonoperative treatment of acromioclavicular joint injuries. *Clin.Sports Med* 2003 ; 22 : 277-290.
3. **El Sallakh SA.** Evaluation of Arthroscopic Stabilization of Acute Acromioclavicular Joint Dislocation Using the TightRope System. *Orthopedics* 2012 ; 35 : e18-e22.
4. **El Shewy MT, El Azizi H.** Suture repair using loop technique in cases of acute complete acromioclavicular joint dislocation. *J Orthop Traumatol* 2011 ; 12 : 29-35.
5. **Gerhardt C, Kraus N, Pauly S, Scheibel M.** Arthroscopically assisted stabilization of acute injury to the acromioclavicular joint with the double TightRope technique : One-year results. *Unfallchirurg* 2011.
6. **Jari R, Costic RS, Rodosky MW, Debski RE.** Biomechanical function of surgical procedures for acromioclavicular joint dislocations. *Arthroscopy* 2004 20 : 237-245.
7. **Manak P, Coufal D.** Is treatment of acromioclavicular dislocation with coraco-clavicular cerclage justified ? *Rozhl Chir* 1991 ; 70 : 97-101.
8. **Mazzocca AD, Arciero RA, Bicos J.** Evaluation and treatment of acromioclavicular joint injuries. *Am J Sports Med* 2007 ; 35 : 316-329.
9. **Nuber GW, Bowen MK.** Acromioclavicular Joint Injuries and Distal Clavicle Fractures. *J Am Acad Orthop Surg* 1997 ; 5 : 11-18.
10. **Pauly S, Gerhardt C, Haas NP, Scheibel M.** Prevalence of concomitant intraarticular lesions in patients treated operatively for high-grade acromioclavicular joint separations. *Knee Surg Sports Traumatol Arthrosc* 2009 ; 17 : 513-517.
11. **Salzmann GM, Walz L, Schoettle PB, Imhoff AB.** Arthroscopic anatomical reconstruction of the acromioclavicular joint. *Acta Orthop Belg* 2008 ; 74 : 397-400.
12. **Tischer T, Salzmann GM, El-Azab H, Vogt S, Imhoff AB.** Incidence of associated injuries with acute acromioclavicular joint dislocations types III through V. *Am J Sports Med* 2009 ; 37 : 136-139.