

CASE REPORT

STRESS FRACTURE OF THE FEMORAL NECK IN A CHILD CASE REPORT AND REVIEW OF THE LITERATURE

M. ROMÁN¹, R. RECIO¹, J.C. MORENO¹, S. FUENTES², F. COLLANTES¹

Fatigue fractures generally appear in normal bone following increased repetitive activity or strenuous exercise, when imbalance occurs between applied force and elastic resistance. Femoral neck fatigue fractures are most common in athletes and young military recruits ; such fractures in children with open physes are very rare.

This paper reports a fatigue fracture of the femoral neck in an 8-year-old girl presenting with pain in the anterior aspect of the right thigh, of one month duration and without evidence of previous injury.

Bed rest and relief of weight bearing are indicated for nondisplaced compression fractures. Surgical treatment is indicated for tension fractures. In most cases, the outcome is favorable, and complications are rarely reported.

Keywords : stress fracture ; femoral neck ; children.

Mots-clés : fracture de fatigue ; col fémoral ; enfant.

INTRODUCTION

Stress fractures have been defined by Blickenstaff and Morris as those fractures showing no initial evidence of a fracture line, but rather a gradual alteration of the bone due to repeated and unusual demands, which may result in complete fracture (1). Predisposing factors identified include anatomic variations, relative osteopenia, poor physical condition, temporary inactivity or systemic medical conditions that can demineralize bone (4).

Stress fracture of the femoral neck has been considered typical of two age groups : active youths (long-distance runners, ballet dancers, military

recruits) and elderly people affected by osteoporosis. Occurrence in children is extremely rare.

Radiographs are usually normal in the initial phase of the condition, when bone scan (fairly non-specific) and magnetic resonance imaging (more sensitive in the early phases) may be more useful. The majority of cases respond well to conservative treatment and are associated with minimal related disease.

CASE REPORT

An 8-year-old girl was brought to the emergency room by her parents. She complained of pain in the anterior part of the right thigh, of roughly one month duration. The pain subsided at rest and increased with physical activity. There was no clear evidence of previous injury, and other aspects of her clinical history were noncontributory. She had not had fever, morning stiffness or weight loss over the previous months. Pain increased during assessment of range of motion of the hip.

Simple radiography revealed callus formation in the lower part of the right femoral neck, consistent with advanced fatigue fracture (fig. 1). The fracture

¹ Department of Orthopedic Surgery and Traumatology, Infanta Margarita County Hospital, Cabra (Province of Cordoba), Spain.

² Department of Orthopedic Surgery and Traumatology, Reina Sofía Regional University Hospital, Cordoba, Spain.

Correspondence and reprints : Manuel Román Torres, C/ Alcalde Velasco Navarro, n°6, 3° 3, 14004 Córdoba (España).

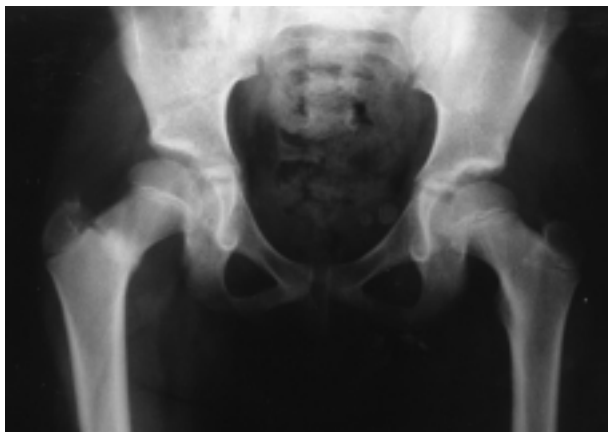

Fig. 1. — Radiograph showing an advanced fatigue fracture of the right femoral neck.

was classified as type III using Delbet's classification, compression fracture according to Devas, type I according to Blickenstaff and Morris and stage 2 according to Fullerton and Snowdy.

Conservative treatment was instituted, based on a reduction of physical activity, the use of crutches and partial support of the lower limb for 3 weeks.

Bone scintigraphy performed at 3 months using MDP-99mTc was normal (fig. 2), and the 5-month radiographic follow-up indicated complete healing of the fracture (fig. 3). Currently, the patient is asymptomatic, and her parents report no lingering alteration in gait or daily physical activity.

DISCUSSION

Two classic types of stress fractures are described: fractures due to fatigue or overloading (bone of normal elasticity submitted to abnormal force), and fractures due to bone insufficiency (diminished elastic resistance and physiological applied force). The case we report is a fatigue fracture.

Maitra and Johnson report that femoral neck fractures comprise 5 to 10% of all stress fractures (4). Stress fractures of the hip are found in long-distance runners, military recruits and elderly osteoporotic patients. Nevertheless, in 1963 Devas

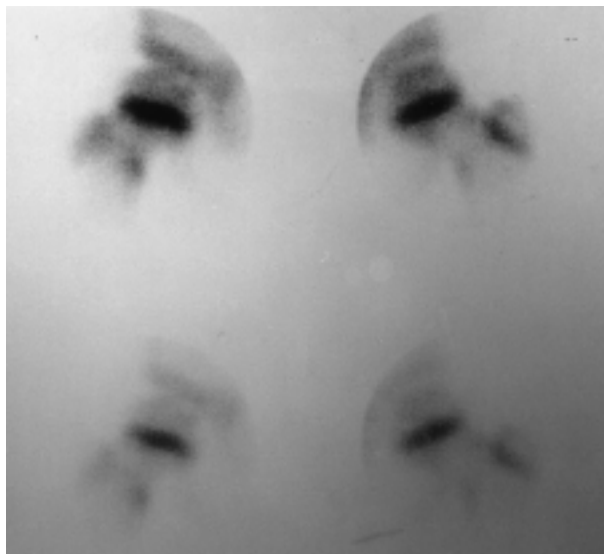


Fig. 2. — Bone scintigraphy performed 3 months after diagnosis.

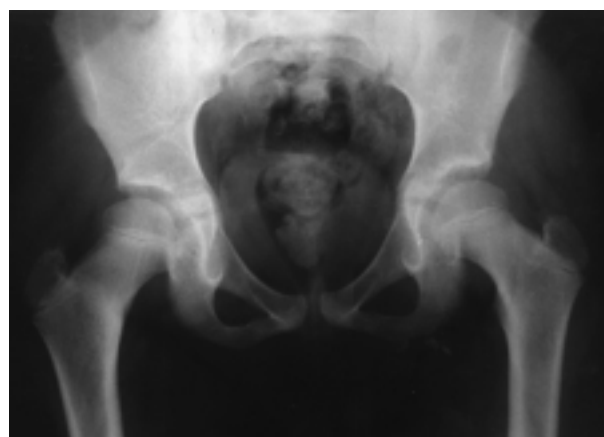

Fig. 3. — 5-month radiographic follow-up showing the healing of the fracture.

described a fracture of this type in a 14-year-old malnourished child (2). To date, 13 cases have been reported in children between 5 and 16 years of age. Only one case of bilateral involvement was found in our review of the literature, in an 8-year-old child (5). In children, osteogenesis imperfecta and myelomeningocele are associated with an increased risk of femoral neck insufficiency fractures.

The pathogenesis of these fatigue fractures remains controversial. Stress fractures occur because the body's normal response is unable to compensate or repair the damage caused by repetitive, cyclic, and physiologically abnormal stresses (4). There is a greater incidence among women, owing to a wider pelvis, genu valgum, lower muscle mass per body weight than men and exercise-induced endocrine anomalies (4).

Stress fractures in the femoral neck often go undetected. This injury should be suspected if there is a history of increased or modified physical activity or an underlying metabolic alteration. The importance of early diagnosis and careful follow-up is stressed by all authors.

Accurate diagnosis of femoral neck stress fractures requires the following : a) gradual onset of inguinal or inguocrural pain which may radiate to the knee after infrequent, repeated physical exercise accompanied by limping and subsiding at rest ; b) pain with range of motion assessment ; c) normal laboratory results ; d) additional tests (radiology, bone scintigraphy, magnetic resonance imaging).

In the first week following the onset of pain, radiographs are usually normal. Xrays may be normal or may show either focal sclerosis (the most frequent finding) or a clear cortical disruption with displacement. Three weeks after the onset of symptoms, radiological signs of bone healing may be apparent (periosteal reaction). Only at 4-6 weeks does callus formation become visible ; this is the stage covered here.

Bone scintigraphy can show findings (increased radioisotope uptake) two or more weeks before xray studies. The MRI shows areas of low signal density on T1-weighted images, and high signal density on T2-weighted sequences. A black line continuous with the cortex may be distinguished in the high signal area.

Several radiology-based classifications have been provided for femoral neck stress fractures, including those of Devas (2), Fullerton and Snowdy (3), and Blickenstaff and Morris (1). According to Devas' 1965 definition (2), stress fractures are located in the superior cortex of the

femoral neck and carry a risk of displacement, leading to severe complications. They are most frequent in older subjects. Compression fractures appear as a fracture line or callus formation in the inferior femoral neck and rarely cause displacement. These are most frequent in young patients.

In children owing to the nonspecific nature of the bone reaction to mechanical overloading, it is especially vital to establish a differential diagnosis with benign tumors such as osteoid osteoma or malignant tumors such as osteosarcoma. The differential diagnosis should also include proximal femoral epiphysiolysis (the most frequent hip problem in adolescents). For the differential diagnosis with hip synovitis, patient history and laboratory results, especially temperature and ESR, are very important.

The majority of patients respond to appropriate treatment, which tends to be conservative. Bed rest and unloaded walking or plaster casts are options to be considered for nondisplaced fractures. Our patient responded well to reduction of load and activity, a treatment widely advocated in the literature.

Surgical treatment is indicated if an opening appears in the fracture, if there is cortical involvement, if bed rest is not possible or if the patient is uncooperative (3).

For tension fractures, which affect the superior cortex of the femoral neck, internal fixation with cannulated screws is recommended before displacement appears. Compression fractures are usually treated by rest and relief of weight bearing.

REFERENCES

1. Blickenstaff M. L., Morris J. M. Fatigue fracture of the femoral neck. *J. Bone Joint Surg.*, 1966, 48-A, 1031-1047.
2. Devas M. B. Stress fracture of the femoral neck. *J. Bone Joint Surg.*, 1965, 47-B, 728-738.
3. Fullerton L. R. Jr. Femoral neck stress fractures. *Sports Med.*, 1990, 9, 192-197.
4. Maitra R. S., Johnson D. L. Stress fractures. Clinical history and physical examination. *Clin. Sports Med.*, 1997, 16, 259-274.
5. Scheerlinck T., De Boeck H. Bilateral stress fractures of the femoral neck complicated by unilateral displacement in a child. *J. Pediatr. Orthop.*, 1998, 7, 246-248.

SAMENVATTING

M. ROMÁN, R. RECIO, J. C. MORENO, S. FUENTES, F. COLLANTES. Vermoeidheidsfractuur van de femurhals bij het kind. Gevalstudie en literatuuroverzicht.

Vermoeidheidsfracturen doen zich meestal voor in normaal bot na herhaalde inspanning of na overbelasting, waarbij er een onevenwicht optreedt tussen inwendige kracht en elastische weerstand. Vermoeidheidsfracturen van de femurhals zijn het meest frequent bij atleten en jonge recruten ; ze zijn echter zeldzaam bij kinderen met open groeischijven.

Dit artikel beschrijft een vermoeidheidsfractuur van de femurhals bij een achtjarig meisje. Ze klaagde van pijn in de rechter dijvoorvlakte sinds één maand, zonder enig voorafgaandelijk trauma. Aangezien dergelijke fracturen zeldzaam zijn op kinderleeftijd oordeelden de auteurs het nuttig dieper in te gaan op diagnosestelling en behandeling. De evolutie is meestal gunstig ; verwikkelingen zijn zeldzaam.

RÉSUMÉ

M. ROMÁN, R. RECIO, J. C. MORENO, S. FUENTES, F. COLLANTES. Fracture de fatigue du col fémoral chez l'enfant. Présentation d'un cas et revue de la littérature.

Les fractures de fatigue se produisent généralement dans un os normal qui a été soumis à des sollicitations mécaniques répétées et accrues ou à un exercice intense, lorsqu'il s'établit un déséquilibre entre les forces auxquelles il est soumis et sa résistance élastique. Les localisations au col fémoral sont fréquentes chez les athlètes et chez les jeunes conscrits ; par contre, elles sont très rares chez l'enfant, dont les cartilages de croissance sont encore actifs.

Cet article décrit une fracture de fatigue du col fémoral chez une enfant de 8 ans qui présentait une douleur localisée à la face antérieure de la cuisse droite depuis un mois, sans antécédent traumatique. Le traitement d'une fracture par compression non déplacée est basé sur la réduction de la charge et de l'activité, qui peut être obtenue, selon les cas, par le repos au lit, par immobilisation plâtrée ou par simple mise en décharge. Le traitement chirurgical est proposé pour les fractures par tension. Dans la plupart des cas, le résultat est satisfaisant et les complications sont rares.