



Review of quality of x-rays for templating for total hip arthroplasty

Faiz KHAN, Tayyab AHMAD, Finbarr CONDON, Brian LENEHAN

From Department of Orthopaedics, University Hospital, Limerick, Republic of Ireland

Digital templating of x-rays for total hip arthroplasty is used routinely for pre-operative planning. This is to assure that appropriately sized implants are selected to replicate patient's hip biomechanics. Multiple studies have shown that templating does not always correspond to the final implants used. The aim of this study was to assess the suitability of the x-rays taken pre-operatively for templating for total hip arthroplasty.

We undertook a review of a series of pre-operative templating pelvis x-rays in 100 consecutive patients undergoing total hip arthroplasty. These x-rays were compared against set criteria to determine their suitability for use for templating.

We determined that six x-rays met the criteria whereas ninety four x-rays did not meet the criteria for suitable x-rays. Twenty patients had repeat x-rays. The reasons for unsuitability were inadequate opposite femur (66%), absence or incomplete template (54%), inadequate femur length (47%), external rotation (39%), absence of opposite hip (4%). The twenty repeated x-rays were also reviewed for the same parameters and two (10%) satisfied the established criteria.

It is imperative that x-rays for templating for total hip arthroplasty are done to a strict standard to obtain an x-ray that is appropriate for templating and there is minimal exposure of the patient to irradiation.

Keywords : Hip templating ; total hip arthroplasty ; pre-operative hip arthroplasty planning.

INTRODUCTION

Total hip arthroplasty is one of the most common orthopaedic procedures being undertaken. In England and Wales, almost half a million total hip arthroplasty procedures were undertaken from April 2003 to December 2011 (9). It is common practice to template the hip x-rays in pre-operative planning. This is to replicate the patients offset, leg length, center of rotation, biomechanics and to provide a stable and well fixed hip. Multiple studies have shown the wide variation in the relationship of template values as compared to the actual implant size. Eggli *et al* (2) stated that 92% femoral and 90% acetabular template values corresponded to the implants used. Levine B *et al* (6) demonstrated that 58.5% values correlated. Neither study details the quality of the x-rays used nor their effect on the lack of correlation between the template values and the actual values. The position of the limb especially

-
- Faiz Khan.
 - Tayyab Ahmad.
 - Finbarr Condon.
 - Brian Lenehan.

Department of Orthopaedics, University Hospital, Limerick, Republic of Ireland.

Correspondence : Faiz Khan, Registrar Orthopaedics, Department of Orthopaedics, University Hospital, Limerick, Republic of Ireland. E-mail : fk166@yahoo.com

© 2015, Acta Orthopædica Belgica.

rotation is important to reduce the effect of anteversion (Hananouci T *et al* (3)). A well centered and adequately exposed x-ray will also help to diagnose and preempt any potential problems that may arise during the course of the surgery. Mueller (8) states that templating of hips for arthroplasty “forces the surgeon to think in three dimensions, greatly improves the precision of surgery, shortens the length of the procedure, and greatly reduces the incidence of complications.”

MATERIALS AND METHODS

X-rays of 100 consecutive patients who underwent total hip replacement in our Regional Orthopaedic Unit were reviewed retrospectively. They were compared to a set standard x-ray of the pelvis (Scheerlinck (10)) and the differences in the x-rays were noted as were the reasons for their unsuitability for use as template x-rays.

The standard x-ray was defined as a weightbearing AP x-ray of the pelvis with the beam centered on the pubis (rather than sacrum), that included both hips, proximal third of both femora with good penetration and exposure. Internal rotation of 15-20 degrees is desirable to correspond to natural femoral neck anteversion. The x-rays ideally should be taken weight bearing though this information was not available for the x-rays evaluated in this study and thus not included. A vertical line over the pubic symphysis should bisect the sacrum to exclude rotation. Pelvic tilt is estimated from the distance between sacrococcygeal joint and the symphysis (Range 8-50 mm in females and 15-72 mm in males).

At our institution, a metal ball of 30 mm diameter is used for calibration of the templating software. The location of the metal ball is lateral at the level of the greater trochanter in all films and this is measured as lateral and superior or inferior to the tip of the greater trochanter.

The x-rays that were deemed unsuitable or unsatisfactory were identified and the reasons for the failure to comply were analysed. The repeat x-rays were identified and these x-rays were also reviewed as to determine whether they complied with the said criteria. The x-rays were viewed on a PACS system by Siemens®. The data was analysed with SPSS 20® statistics analysis computer program.

RESULTS

The study examined 100 consecutive x-rays of patients who presented for total hip arthroplasty at

our Regional Orthopaedic Hospital and the subsequent repeated x-rays of twenty patients. There were 46 (46%) females and 54 (54%) males. There were 45 (45%) left and 55 (55%) right hips. The mean age was 65.2 years with a range of 49 to 86 years. Each x-ray was reviewed and assessed for femoral length, presence of the opposite femur and hip, rotation of the femur, presence and adequacy and location of template.

Of the 100 x-rays reviewed, 6 (6%) x-rays met every aspect of the criteria and were suitable for templating. The remaining 94 (94%) x-rays did not meet the set standard for one or more criteria. Twenty patients (20%) had repeat x-rays and these were also reviewed.

The proximal third of the femur was seen in 53 (53%). In the remaining 47 (47%), the length of the femur was too short and thus unsuitable for accurate templating. It was not possible to accurately determine the proximal third of the femur in the absence of a full length x-ray. The authors considered the visualized length of the proximal femur to be appropriate if it corresponded to the length of femoral implant proposed for the surgery. The opposite femur was visualized adequately in 34 (34%) and was partially seen in 35 (35%) and absent in 31 (31%). The opposite hip was visualized in 94 (94%) and was absent in the remaining 4 (4%). The hip was internally rotated in 59 (59%) and externally rotated in 41 (41%). This was determined by the size of the lesser trochanter. The metal ball for templating was present and seen adequately in 46 (46%) and was present but incomplete in 24 (24%). It was absent in 13 (13%) x-ray. It was complete and present in 16 (16%) x-rays but the margins along the edge had a double shadow or was too faint to be measured. The location of the template marker in all the x-rays was lateral. The mean lateral distance was 5.19 cm with a range of 0.50 to 11.80 cm. Of the 84 (84%) x-rays that had a template ball, 23 were superior and 61 were inferior to the greater trochanter. The mean superior distance was 3.01 cm with a range of 0.30 to 10.80 cm. The mean inferior distance was 3.51 cm with a range of 0.20 to 8.60 cm. A wide variation was seen in the placement of the templating marker.

The number of patients who had repeat x-rays was 20 (20%). These repeat x-rays were also

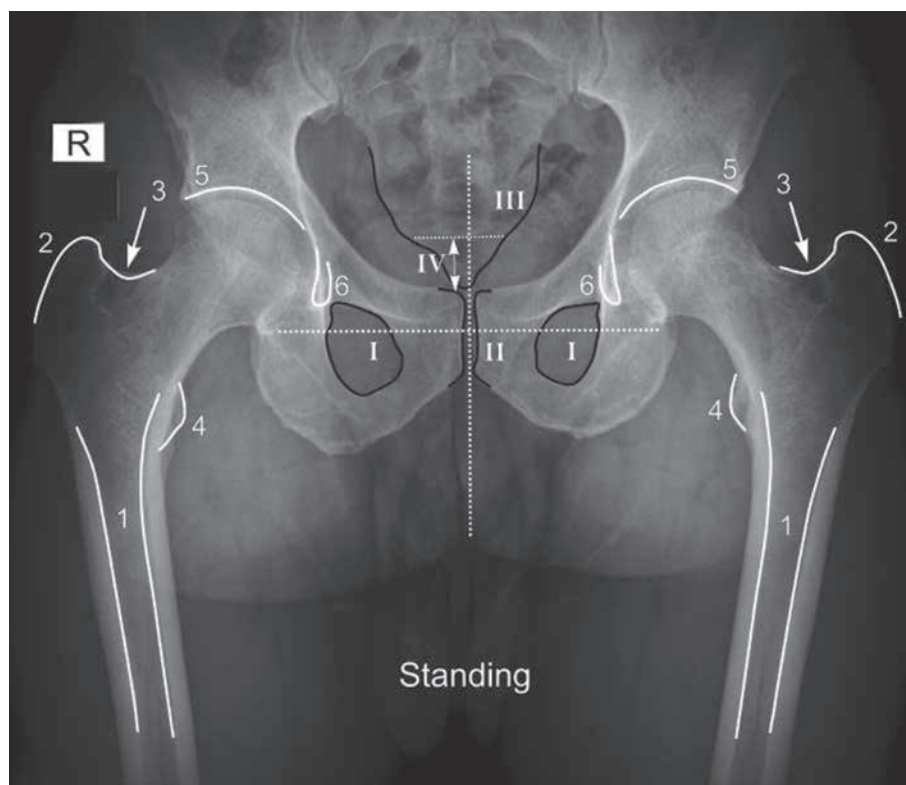


Fig. 1. — Standing anteroposterior pelvic radiograph suitable for hip templating. Anatomical landmarks : 1. Femoral shaft ; 2. Greater trochanter ; 3. “Saddle” ; 4. Lesser trochanter ; 5. Acetabular roof ; 6. Teardrop. Landmarks for radiographic quality assessment : I. Foramen obturatum ; II. Symphysis ; III. Sacrum ; IV. Distance between symphysis and sacro coccygeal joint. (Scheerlinck T. Primary hip arthroplasty templating on standard radiographs. A stepwise approach. *Acta Orthopaedica Belgica*, Vol 76-4-2010).

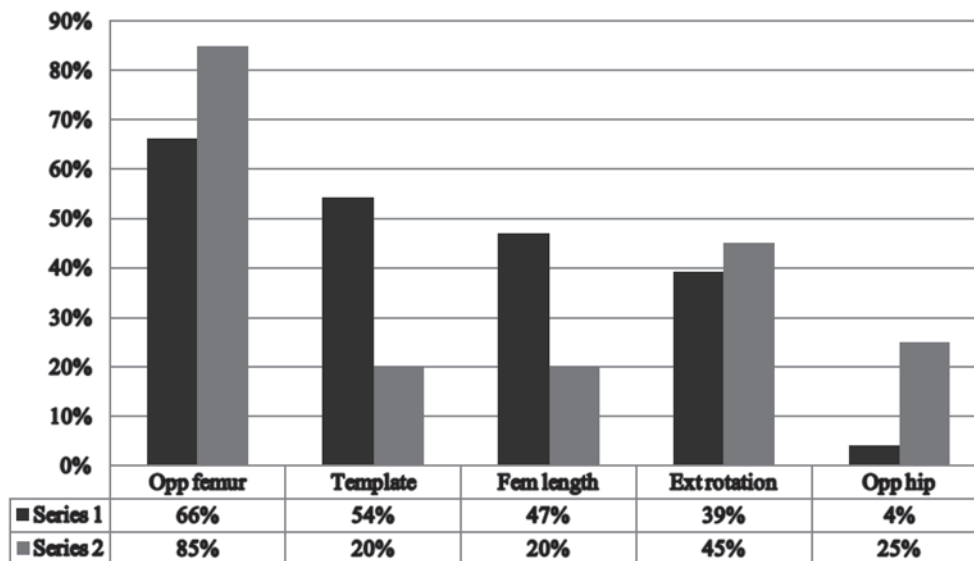
reviewed and 2 (10%) met the stated criteria whereas the remainder 18 (90%) were deficient. The proximal third of the femur was seen in 16 (80%) x-rays. The opposite femur was seen completely in 3 (15%), partially in 3 (15%) and absent in 14 (70%) x-rays. The opposite hip was visualized adequately in 15 (75%) x-rays. The hip was internally rotated in 11 (55%) x-rays. The metal ball for templating was complete in 16 (80%), absent in 1 (5%) and present but inadequate in 3 (15%) x-rays.

DISCUSSION

A consecutive series of 100 x-rays of patients who underwent total hip arthroplasty at our institution were retrospectively reviewed. The aim of the study was to determine the percentage of x-rays that

were suitable for templating. A set criterion of an AP pelvis x-ray was used as guide for comparison. The parameters specifically seen were adequacy of the film, view of the proximal third of the femur, visualisation of the opposite hip, location of the template ball, complete visualisation and adequacy of the template ball, internal rotation of the femur. Of the 100 x-rays, only 6 (6%) met all the criteria and the remainder 94 (94%) did not meet one or more of the criteria. Repeat x-rays were done for 20 (20%) patients thus subjecting them to extra radiation which was not necessary if the first x-ray had been satisfactory. The inclusion of the opposite hip is very important in a pelvis x-ray for templating. This is especially true if the hip architecture is extensively damaged and not suitable for templating. The opposite hip is thus used to template.

Table I. — Review of individual criteria of unsatisfactory x-rays for their unsuitability for templating



Series 1 : 94 unsatisfactory primary x-rays.

Series 2 : 18 unsatisfactory repeat x-rays.

Templating decreases the incidence of leg length discrepancy. According to Unnanuntana A *et al* (12), the mean leg length discrepancy was with 10 mm in 93.5% in a series of 109 templated total hip replacements. Jassim S *et al* (4) report that leg length correction was accurately performed with the help of digital templating. Maheshwari A *et al* (7) in his paper discusses the common errors of pre-operative templating. He affirms the need for templating not only to achieve a successful surgical outcome in relation to implant position and size but also alludes to achieving a leg length difference of less than 5mm in 89% of cases. An AP pelvis x-ray that includes the opposite femur is thus important to achieve optimum leg length. Digital templating has the potential to reduce errors in total hip arthroplasty. It allows for early recognition of potential issues. According to Shaarani *et al* (11), a large difference between the templated and the intraoperative size will alert the operator to a possible potential problem. Lecerf G *et al* (5) state that pre-operative templating is important to achieve a good offset which in turn is related to good abductor function. The metal marker sphere used provides a reference for the software to calculate the magnification as it

is of a known diameter. Its position in relation to the hip is thus important. Bayne C *et al* (1) assessed the accuracy of templating with the marker in four different positions. The most accurate readings were obtained with the marker at the greater trochanter without any overlap of the skin. It should be completely visualised in the x-ray to allow for circle of the software to be placed on the template ball to accurately obtain the size which is then used to template the hip. The x-ray of the pelvis should be obtained in one attempt. In our study 20% required a second x-ray. The amount of radiation was thus doubled with unnecessary exposure of the patient to radiation. On enquiry from the radiology department, no set protocol was in place in relation to x-rays for templating.

CONCLUSION

We have highlighted the importance of an adequate pelvis x-ray with a template marker in the correct position. This is a basic requirement in today's environment of computer based preoperative templating. It is also imperative that one x-ray that would encompass all the criteria of an x-ray suitable

for templating should be done to avoid undue exposure to radiation. It is imperative that a policy exists in the x-ray departments in relation to pre-operative x-rays for hip templating to achieve this aim.

REFERENCES

1. **Bayne CO, Krosin M, Barber TC.** Evaluation of the accuracy and use of x-ray markers in digital templating for total hip arthroplasty. *J Arthroplasty* 2009 ; 24 : 407-13.
2. **Eggl S, Pisan M, Müller ME.** The value of preoperative planning for total hip arthroplasty. *J Bone Joint Surg Br* 1998 ; 80 : 382-390.
3. **Hananouchi T, Sugano N, Nakamura N, Nishii T, Miki H, Yamamura M, Yoshikawa H.** Preoperative templating of femoral components on plain X-rays. Rotational evaluation with synthetic X-rays on ORTHODOC. *Arch Orthop Trauma Surg* 2007 ; 127 : 381-385.
4. **Jassim SS, Ingham C, Keeling M, Wimhurst JA.** Digital templating facilitates accurate leg length correction in total hip arthroplasty. *Acta Orthop Belg* 2012 ; 78 : 344-349.
5. **Lecerf G, Fessy MH, Philippot R, Massin P, Giraud F, Flecher X, Girard J, Mertl P, Marchetti E, Stindel E.** Femoral offset : anatomical concept, definition, assessment, implications for preoperative templating and hip arthroplasty. *Orthop Traumatol Surg Res* 2009 ; 95 : 210-219.
6. **Levine B, Fabi D, Deirmengian C.** Digital templating in primary total hip and knee arthroplasty. *Orthopedics* 2010 ; 33 : 797.
7. **Maheshwari AV, Rasquinha VJ.** Re : common errors in the execution of preoperative templating for primary total hip arthroplasty. *J Arthroplasty* 2011 ; 26 : 980-981 ; author reply 981.
8. **Mueller ME.** Lessons of 30 years of total hip arthroplasty. *Clin Orthop Relat Res* 1992 ; 274 : 12-21
9. **National Joint Registry for England and Wales,** 9th Annual Report, 2012.
10. **Scheerlinck T.** Primary hip arthroplasty templating on standard radiographs. A stepwise approach. *Acta Orthopaedica Belgica* 2010 ; 76 : 432-442.
11. **Shaarani SR, McHugh G, Collins DA.** Accuracy of Digital Preoperative Templating in 100 Consecutive Uncemented Total Hip Arthroplasties : A Single Surgeon Series. *J Arthroplasty* 2013 ; 28 : 331-337.
12. **Unnanuntana A, Wagner D, Goodman SB.** The accuracy of preoperative templating in cementless total hip arthroplasty. *J Arthroplasty* 2009 ; 24 : 180-186.