



Dorsal nail plate versus percutaneous k-wire fixation in the treatment of displaced distal radius fractures

Omer KARATOPRAK, Sinan KARACA, Mehmet Nuri ERDEM, Ferit KIRAC, MERIC ENERCAN, Serdar TUNCER

From Department of Orthopaedic Surgery, Istanbul Florence Nightingale Hospital, Sisli, Istanbul, Turkey

Distal radius fractures are the most common fractures in the elderly, yet the treatment is controversial and still debated in the literature. Twenty four patients aged older than sixty with distal radial fractures were treated by dorsal nail plate. We compared them with twenty four similar matched patients treated by percutaneous Kirschner wiring surgical method. The patients were operated on by a surgeon experienced in carrying out hand surgery. The purpose of this retrospective review was to compare the clinical and radiological outcomes in elderly patients with displaced distal radial fractures who were treated with either the dorsal nail plate or percutaneous Kirschner wiring surgical procedures. Both groups had high union rates and low complication rates for the treatment of displaced distal radius fractures in elderly patients. However, better functional results can be expected in dorsal nail plate.

Keywords : Distal radius ; fracture ; osteoporosis ; colles.

INTRODUCTION

Distal radius fractures (DRF) are extremely common. They occur more frequently in women, being the most common fractures in women in the United States and Northern Europe up to the age of 75 years, with a lifetime risk of ~15% (5). Improper treatment results in chronic wrist pain and stiffness, seriously affecting hand function. The main factors that deter-

mine functional recovery are restoration of normal anatomy and early mobilisation without joint stiffness (9,17). These aims can be difficult to achieve using nonoperative treatments in elderly patients with poor bone qualities (17).

In the last decade, the popularity of internal fixation increased among orthopedic surgeons. New plate designs were shown to be effective in stabilising unstable fractures and restoring functional

■ Omer Karatoprak.

■ Meric Enercan.

Department of Orthopaedic Surgery, Istanbul Florence Nightingale Hospital, Sisli, Istanbul, Turkey.

■ Sinan Karaca.

Department of Orthopaedic Surgery, Fatih Sultan Mehmet Training and Research Hospital Atasehir, Istanbul, Turkey.

■ Mehmet Nuri Erdem.

Department of Orthopaedic Surgery, International Kolan Hospital, Sisli, Istanbul Turkey.

■ Ferit Kirac.

Department of Orthopaedic Surgery, Diyarbakır, Training and Research Hospital, Ückuyular Mevki TOKİ karşısı Diyarbakır, Turkey.

■ Serdar Tuncer.

Department of Hand Surgery, Istanbul Bilim University, Sisli, Istanbul, Turkey.

Correspondence : Omer Karatoprak, Department of Orthopaedic Surgery, Istanbul Florence Nightingale Hospital, Abide-I Hurriyet cd. No : 290 Sisli, Istanbul 34360, Turkey.

E-mail : karatoprako@yahoo.com

© 2015, Acta Orthopædica Belgica.

There is no competing interest.

No benefits or funds were received in support of this study.

The authors report no conflict of interests.

anatomy, allowing early functional use of the hand. Clinical studies also reported good or excellent functional results in most patients (11,14). Volar plate fixation was shown to give better clinical results with lower rates of complications compared to dorsal fixation (7,15). However fixed angle volar plate fixation requires extensive surgical dissection and complications of this technique, although few, are noted in all series (11,8). Methods combining stable fixation with minimal invasive surgery were developed (4,12). These implants like Dorsal Nail Plate (DNP) link a specifically designed stem inserted into the radial diaphyseal canal, to a distal part where divergent fixed angle screws support the subchondral bone of the distal epiphysis.

Despite the development of new surgical treatments in the management of DRF, closed reduction and Percutaneous Kirschner Wiring (PKW) remains a popular method for maintaining fracture reduction. PKW is a relatively simple, quick, and minimally invasive technique, which is cheap and requires limited operative hardware. Disadvantages of Kirschner Wires (KW) include possible failure of the wires in maintaining fracture reduction in elderly patients because the wires are inherently flexible, and risk of infection through pin tracks on the skin (16). There are no previous studies comparing PKW and DNP for DRF treatment. The aim of this retrospective study is to compare the clinical and radiological outcomes of PKW and DNP for the management of DRF in patients aged older than 60.

PATIENTS AND METHODS

A retrospective analysis of 48 patients surgically treated in a single orthopaedic department by a single orthopaedic trauma surgeon for DRF between February 2010 and November 2011 was carried out. The patients were separated into two groups, 24 patients treated by DNP were included in Group 1, and a similar group of patients treated by closed reduction and PKW were included in Group 2. There were 17 female and 7 male patients in DNP, and 19 female 5 male patients in PKW group. Mean ages were 68.1 ± 3.7 and 69.3 ± 4.2 in DNP and PKW groups, respectively.

Patients with acute and unstable fractures and with no or with minimal articular involvement (fractures A2, A3, or C1 according to the Arbeitsgemeinschaft für Osteosynthesefragen (AO) classification) aged older than 60 years were included into the study. The fractures were classified according to the preoperative anteroposterior and lateral roentgenograms. All cases were evaluated by one senior physician. In the DRF group 11 patients were A2, 7 patients were A3, and 6 patients were C1. In the PKW group 14 patients were A2, 5 patients were A3, and 5 patients were C1 (Table I). Medical conditions were also analyzed retrospectively (Table II).

Radial length, palmar tilt, and radial angulation were measured. Exclusion criteria for the study were (a) open fractures (including also Gustilo Anderson type 1) (b) previous fractures or nonunions of the wrist, (c) bilateral fractures, d) delayed treatment (> 10 days from the trauma) e) dementia or psychiatric illness f) polytrauma. The patients were similarly matched according to age (within six years) and sex between the groups. All

Table I. — Fracture classification in both groups

AO fracture classification	DNP group	PKW group	P value
A2	11 (45,8%)	14 (58,3%)	0,27
A3	7 (29,1%)	5 (20,8%)	0,23
C1	6 (25,0%)	5 (20,8%)	0,32

Table II. — Medical conditions in both groups

Medical Conditions	DNP group	PKW group	P values
Diabetes	1	2	0,5
Heavy smokers	1	0	0,5
Renal disease	0	1	0,5
Average follow up	20,3 ± 6,1	22,8 ± 9,8	0,26

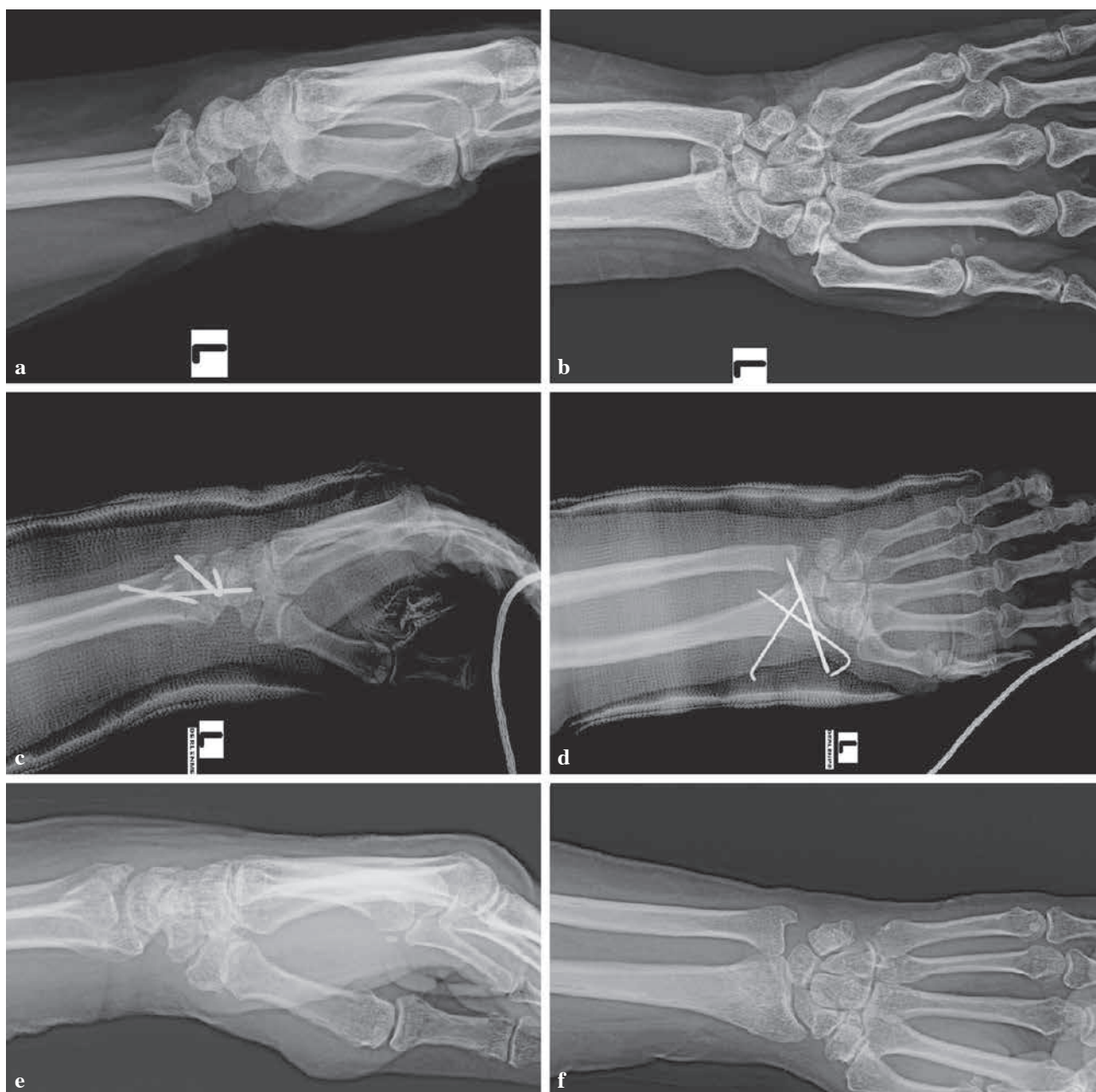


Fig. 1. — PKW surgical method a) preoperative lateral x-ray, b) preoperative anterior-posterior x-ray, c) early postoperative lateral x-ray, d) early postoperative anterior-posterior x-ray, e) 12 week follow up postoperative lateral x-ray, f) 12 week follow up postoperative anterior-posterior x-ray.

patients were followed-up for a minimum period of 18 months after the surgical procedure.

All procedures were carried out under full sterile preparation and draping. In the PKW group closed reduction of all fractures were performed under general anesthesia and with fluoroscopy guidance. After acceptable reduc-

tion (> 15 radial inclination, < 5 mm radial shortening, < 15 dorsal and < 20 palmar tilt, ulnar variance negative or neutral, articular gap should be less than 2mm and the articular step < 1 mm.) of the fracture was achieved, 3 percutaneous KW were inserted in traction (Fig. 1). A below elbow cast with the wrist in the ulnar deviation

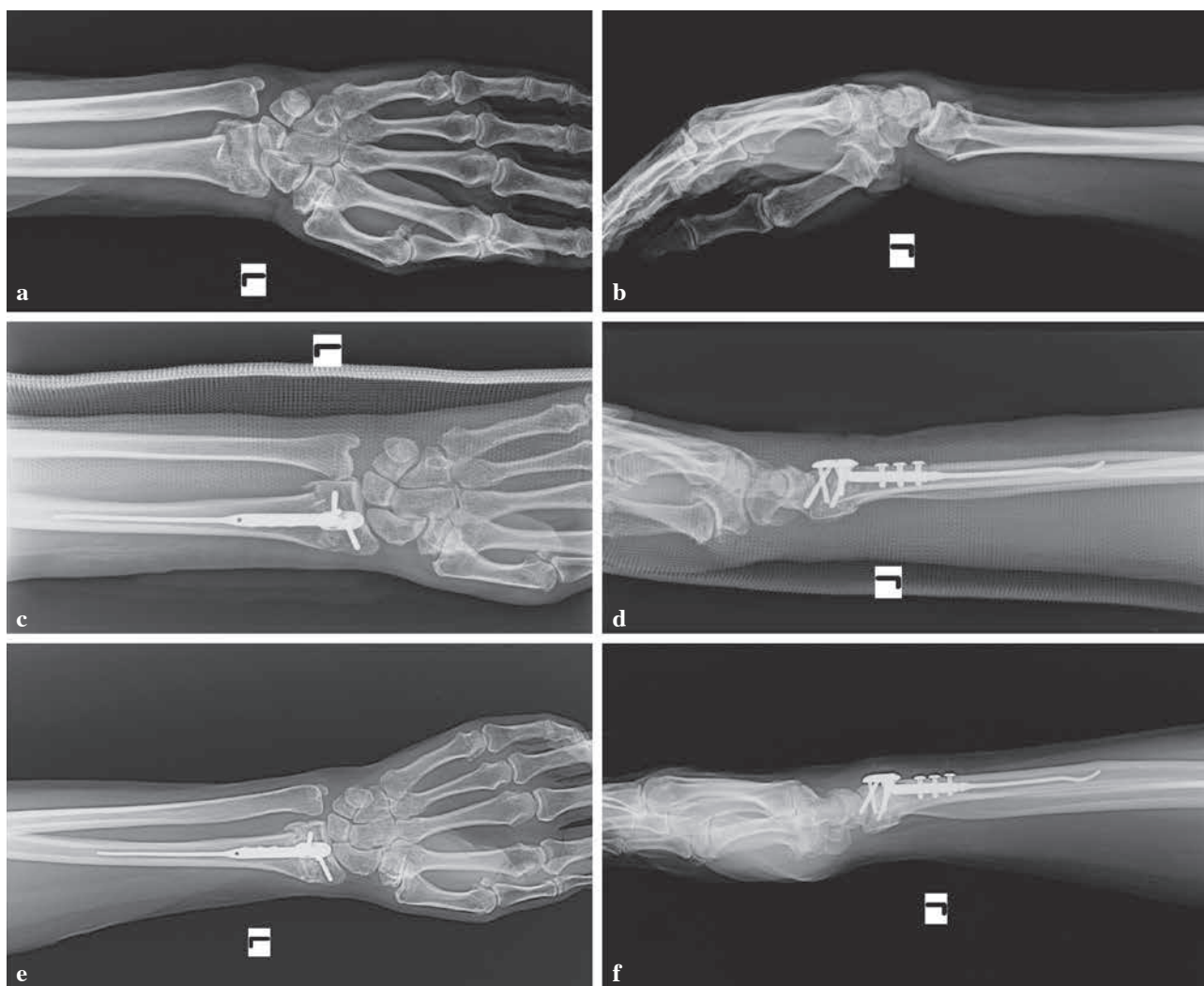

Fig. 2. — DNP surgical method a) preoperative anterior-posterior x-ray b) preoperative lateral x-ray, c) early postoperative anterior-posterior x-ray, d) early postoperative lateral x-ray, e) 12 week follow up postoperative anterior-posterior x-ray, f) 12 week follow up postoperative lateral x-ray.

position was used for 3 weeks in all cases. The percutaneous wires were usually removed after 3 weeks of immobilization with sedation in the operation room. A protective splint was applied after the removal of the cast. The splint could be removed for bathing and exercise, and was discontinued after 4 to 6 weeks once solid union was obtained.

The surgical procedure for DNP was performed as described by Orbay *et al* (10). Postoperatively, the injured wrist was immobilised in a below-elbow cast for three weeks (Fig. 2).

In both groups, the operated hand was kept elevated postoperatively during hospital stay. Active finger,

shoulder and elbow mobilization was started as early as the patient could perform. The patients were discharged 24 hours later after ensuring good distal circulation of fingers. Hand physiotherapy after cast removal was carried out routinely.

The two groups were compared for pain, range-of-motion (ROM), grip strength, and functional outcome measured by the disabilities of the arm, shoulder, and hand questionnaire (DASH). Standard anteroposterior and lateral radiographs were taken for radiological evaluation and the radiographic data were measured with a goniometer and included evaluation of radial length, inclination, and tilt at 3, 6, 9, 12 weeks and at 18 week

Table III. — Clinical outcome results of two groups

Clinical outcome	DNP	PKW	P values
Pain (0-10)	1,54 ± 1.3	1,79 ± 1.1	0.23
Flexion	68,1 ± 8.1	58,9 ± 10.2	0.018
Extension	67,8 ± 3,2	63,9 ± 4.7	0.29
Radial deviation	24,2 ± 3.9	22 ± 5.0	0.41
Ulnar deviation	36,1 ± 4,1	24 ± 3.7	0.032
Pronation	73,5 ± 10,2	69 ± 8.9	0.19
Supination	72,9 ± 9.3	70 ± 9.2	0.27
Dash score	5,9 ± 2.9	7,1 ± 2.4	0.11
Mean duration of rehabilitation	2,8 ± 1,4 week	3,2 ± 1,2 week	0.25
Time to return daily activities	6-12 week	6-12 week	NS

final follow-up. Healing was defined both clinically (no pain at the fracture site) and radiographically (consolidation of the fracture). Grip power was measured with a dynamometer. The time that the patients were able start performing activities of daily living was questioned and recorded.

Statistics

Statistical analysis was performed using chi-square test with Yates' correction. Comparison of the two treatment groups was performed by analysing the mean values using a paired test for match-paired analysis. SPSS 10.0 statistical software package was used to analyse the data ; p values below 0.05 were considered to be significant.

RESULTS

There were statistically no significant differences between the two groups with respect to fracture type and medical conditions (p values > 0.05) (Table I and II). The operative time was significantly less in the PKW group when compared to the DNP group (mean 22,6 ± 6,1 versus 61,3 ± 9,4 p < 0.001). There was no difference (p = 0,33) in hospital stay between the PKW group (mean 2.2 ± 1.0 day) and DNP group (mean 2.3 ± 1.1 day).

In the DNP group, all fractures healed in 12 weeks. The mean healing time was 8.4 ± 2.2 weeks. Also in the PKW group, all fractures were healed by the 12th week, with a mean of

9.1 ± 2.7 weeks. Healing time were not significantly different between the two groups (p = 0.95).

There were 3 complications in total. One patient in the DNP group had tenosynovitis of the EPL tendon that resolved with corticosteroid injection and another one had iatrogenic partial rupture of EPL that was repaired primarily and kept immobilized for 3 weeks. In the PKW group one patient had a pin site infection that healed with oral antibiotics for seven days.

Mean range of motion including extension, radial deviation, pronation, and supination were better in the DNP group when compared with the PKW group at the final follow up, but the difference was not significant (p values > 0.05) (Table III). Ulnar deviation and flexion were significantly better in the DNP group compared with the PKW group (all p values < 0.05). In addition, DASH scores and also pain were not significantly different between the treatment groups throughout the 18 week period (Table III).

Mean duration of postoperative rehabilitation was shorter in the DNP group but the difference was not significant. There was no difference between two groups in the time to return to daily activities.

Final radiologic evaluation in the DNP group revealed a mean radial inclination of 21.0° ± 3.7, volar tilt of 9.7° ± 3.3, radial height of 12.4 ± 5.4 mm, ulnar variance of 0 ± 1.1 mm, and 1 mm articular stepoff in 1 patient. In the PKW group there was a mean radial inclination of 24° ± 4.2, volar tilt of

Table IV. — Radiographic results at final follow-up

Radiographic results	DNP group (N:24)	PKW group (N:24)	P values
Ulnar variance (mm)	0 ± 1.1 mm	+0,4 ± 1.3 mm	0.041
Volar tilt (°)	9.7° ± 3.3	2.6 ± 6.1	0.012
Radial height (mm)	12.4 ± 5.4mm	10 ± 4.9 mm	0.24
Radial inclination (°)	21.0° ± 3.7	24° ± 4.2	0.38
1 mm articular stepoff	1 case	2 case	

2.6 ± 6.1, radial height of 10 ± 4.9 mm, ulnar variance of +0,4 ± 1.3 mm, and 1 mm stepoff in 2 cases. No patients from either treatment groups had a stepoff > 2 mm. Only the ulnar variance (radial length) and volar tilt showed statistically significant outcomes in favor of the DNP group (Table IV).

DISCUSSION

Fractures of the distal radius are one of the most common skeletal injuries treated by orthopaedic surgeons and account for approximately one sixth of all fractures seen and treated in emergency rooms (1). In various studies there is still no absolute consensus regarding the management and assessment of the outcomes of distal radius fracture (2,3).

Fixation may be achieved in several surgical ways ranging from minimal invasive closed techniques to open reduction and internal fixation (13). Closed reduction and PKW can be solutions for elderly patients, who may develop loss of reduction and radial shortening due to the poor bone quality when a nonsurgical treatment is performed (6). Also a new implant ; DNP which is aiming a stable, anatomic fixation of the DRF could be an option for the treatment of DRF. To our knowledge, this is the first study comparing DNP and PKW for displaced DRF.

We found improved ROM and superior radiographic results with DNP in the treatment of DRF compared with PKW in patients greater than sixty years of age. On the other hand DASH scores that measure functional status and pain were not significantly different between the treatment groups throughout the 18 week period.

Screw penetration into the distal radio-ulnar joint is reported as one of the major complications of sur-

gical plating procedures in the treatment of DRF (18). There were no cases of screw penetration in the distal radio-ulnar joint, which could cause symptomatic arthritis. This could be related with careful use of fluoroscopy during the surgical procedure.

Rampoldi *et al* (12) reported two EPL partial lacerations in 48 patients. In our study we had one EPL laceration in 24 patients. EPL complication rates were similar in both studies, we did not see any screw loosening as reported in previous series.

In the PKW group, we did not encounter common pin site problems (4.1%). This may be due to sponge padding the part of KW remaining out of the skin with an occlusive dressing and iodine solution. Postoperatively appropriate pin care was maintained for all patients. These methods help to prevent skin irritation and pin site infection.

A negative aspect of the DNP procedure is the cost. PKW is a less expensive surgery procedure due to the implant costs.

Our study had limitations. First, it was a retrospective study and the patients were not matched according to the AO fracture type due to our small database. Secondly the study group size was small. Also, the research assistants involved in the data collection of this study were not blinded to treatment type and which may have introduced a bias. Finally, the length of follow-up in this study was another limitation. It is possible that with longer-term follow up, the posttraumatic arthritis noted at one year could begin to impact function.

In conclusion, treatment of displaced, extra-articular or simple intra-articular fractures of the distal part of the radius in patients between 50 and 70 years old is a challenging issue for the orthopaedic surgeons. Newer devices continue to improve

the results. In our study both PKW and DNP groups had high union and low complication rates. Prospective, controlled, high-powered, and randomized studies comparing these two treatments need to be performed to determine the differences in patient outcomes and to further elucidate optimal treatment strategies for distal radius fractures.

REFERENCES

1. **Ark J, Jupiter JB.** The rationale for precise management of distal radius fractures. *Orthop Clin North Am* 1993 ; 242 : 205-210.
2. **Azzopardi T, Ehrendorfer S, Coulton T, Abela M.** Unstable extra-articular fractures of the distal radius : A prospective, randomized study of immobilization in a cast versus supplementary percutaneous pinning. *J Bone Joint Surg* 2005 ; 87-B : 837-840.
3. **Blakeney WG.** Stabilization and treatment of Colles' fractures in elderly patients. *Clin Interv Aging* 2010 ; 18 : 337-344.
4. **Brooks KR, Capo JT, Warburton M, Tan V.** Internal fixation of distal radius fractures with novel intramedullary implants. *Clinical Orthop Relat Res* 2006 ; 445 : 42-50.
5. **Cummings SR, Kelsey JL, Nevitt MC, O'Dowd KJ.** Epidemiology of osteoporosis and osteoporotic fractures. *Epidemiol Rev* 1985 ; 7 : 178-208.
6. **Das AK, Sundaram N, Prasad TG, Thanhavelu SK.** Percutaneous pinning for non-comminuted extra-articular fractures of distal radius. *Indian J Orthop* 2011 ; 45 : 422-426.
7. **Jakubietz RG, Gruenert JG, Kloss DF, Schindele S, Jakubietz MG.** A randomised clinical study comparing palmar and dorsal fixed-angle plates for the internal fixation of AO C-type fractures of the distal radius in the elderly. *J Hand Surg* 2008 ; 33E : 600-604.
8. **Jupiter JB, Marent-Huber M.** LCP Study Group : Operative management of distal radius fractures with 2.4 mm locking plates. A multicenter prospective case series. *J Bone Joint Surg* 2009 ; 91-A : 55-65.
9. **Nana AD, Joshi A, Lichtman DM.** Plating of the distal radius. *J Am Acad Orthop Surg* 2005 ; 13 : 159-171.
10. **Orbay JL, Touhami A, Orbay C.** Fixed angle fixation of distal radius fractures through a minimally invasive approach. *Tech Hand Up Extrem Surg* 2005 ; 9 : 142-148.
11. **Osada D, Kamei S, Masuzaki K et al.** Prospective study of distal radius fractures treated with a volar locking plate system. *J Hand Surg* 2008 ; 33-A : 691-700.
12. **Rampoldi M, Marsico A.** Dorsal nail plate fixation of distal radius fractures. *Acta Orthop Belg* 2010 ; 76 : 472-478.
13. **Ring D, Jupiter JB.** Treatment of osteoporotic distal radius fractures. *Osteoporos Int* 2005 ; 16 : Suppl 2 : S80-S84.
14. **Rozental TD, Blazar PE, Franko OI et al.** Functional outcomes for unstable distal radius fractures treated with open reduction and internal fixation or reduction and percutaneous fixation. A prospective randomized trial. *J Bone Joint Surg* 2009 ; 91-A : 1837-1846.
15. **Ruch DS, Papadonikolakis A.** Volar versus dorsal plating in the management of intra-articular distal radius fractures. *J Hand Surg* 2006 ; 31-A : 9-16.
16. **Sommer C, Brendebach L, Meier R, Leutenegger A.** Distal radius fractures – retrospective quality control after conservative and operative therapy. *Swiss Surg* 2001 ; 7 : 68-75.
17. **Stevenson I, Carnegie CA, Christie EM, Kumar K, Johnstone AJ.** Displaced distal radial fractures treated using volar locking plates : maintenance of normal anatomy. *J Trauma* 2009 ; 67 : 612-616.
18. **Toros T, Sügün TS, Ozaksar K.** Complications of distal radius locking plates. *Injury* 2013 ; 44 : 336-339.