



Clinical results of cementless total hip arthroplasty with shortening osteotomy for high dislocation with developmental dysplasia

Engin Eren DESTELI, Yunus İMREN, Erkan TAN, Murat ERDOĞAN, Hüseyin ÖZCAN

From Department of Orthopaedics and Traumatology, Üsküdar State Hospital, Istanbul, Turkey

Total hip arthroplasty for severe developmental dysplasia of the hip is a technically challenging procedure. Subtrochanteric femoral osteotomy enables reducing the femoral head and restoring abductor muscle strength without compromising proximal femoral bone stock in advanced dysplasia. We aimed to retrospectively evaluate Crowe type III or IV developmental dysplasia of the hip who underwent reconstruction with cementless total hip arthroplasty combined with a transverse subtrochanteric femoral osteotomy. Sixty hips of 52 patients (11 male, 49 female) with Crowe type III (n : 37) or IV (n : 23) developmental dysplasia of the hip were included. The average age was 51.4 years. Surgery was performed in lateral decubitus position with posterolateral approach. Subtrochanteric transverse femoral osteotomy were used with cementless components. 40 of the femoral components were Secur-Fit type, and 20 of them were secur-fit plus max type. Ceramic-ceramic coupling was used in 24 cases and metal-polyethylene coupling was used in 36 cases. Merle D'Aubigne and Harris Hip score were used to rate the clinical outcome at the final follow up. All femoral shortening osteotomies were united at a mean of 5.7 months. Mean Merle D'Aubigne pain score was increased from 3.1 to 5.4, and mean Harris Hip score improved from 39 to 92.8, postoperatively ($p < 0.01$). There was no significant difference in time to union between different types of stems. 4 femoral stems had asymptomatic radiolucent lines. There was no significant difference in time to union between different types of stems.

Keywords : Total hip replacement ; developmental dysplasia ; shortening osteotomy ; hip.

INTRODUCTION

Total hip arthroplasty for severe developmental dysplasia of the hip is a technically challenging procedure. Anatomical abnormalities of the hip typically presented in high hip dislocation are deformed femoral head, short femoral neck with excessive anteversion, small and narrow femoral medullary canal, hypoplastic acetabulum with reduced depth ; muscular contractures, deficient superior bone stock and a more posteriorly located greater trochanter (2,8,25,33) (Fig. 1). Due to developed pathologies, total hip arthroplasty for dysplastic hips has more complication rates than primary total hip arthroplasty for patients without dysplasia (5,7,27). Due to high

■ Engin Eren Desteli.

■ Yunus İmren, M.D.

■ Erkan Tan.

■ Hüseyin Özcan.

Department of Orthopaedics and Traumatology, Üsküdar State Hospital, Istanbul, Turkey.

■ Murat Erdoğan.

Department of Orthopaedics and Traumatology, Ondokuzmayıs University, Samsun, Turkey.

Correspondence : Yunus İmren, Üsküdar State Hospital, Istanbul, Turkey. E-mail : yunusimren@yahoo.com

© 2015, Acta Orthopædica Belgica.

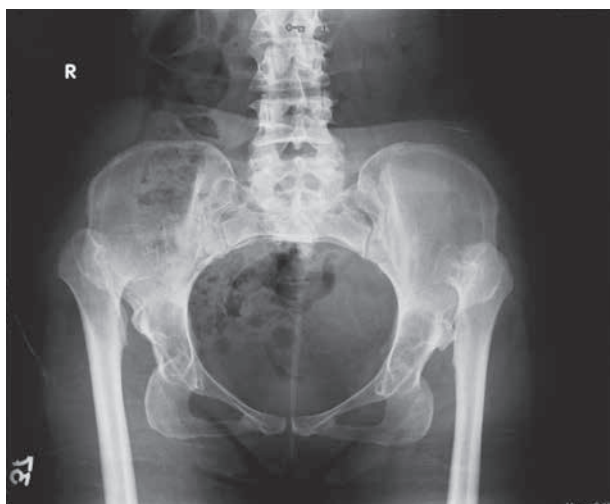


Fig. 1. — Preoperative AP view of bilateral dysplastic hips with high dislocation.

complication rates it has been discussed whether to operate the irreducible high hip dislocations or not (1,6). However, proper placement of the acetabular cup in the true acetabulum and decreasing possible nerve injury by subtrochanteric femoral shortening osteotomy has satisfactory clinical results (14, 22,23,28,30,34). Subtrochanteric femoral osteotomy enables reducing the femoral head and restoring abductor muscle strength without compromising proximal femoral bone stock. Subtrochanteric femoral osteotomy can be performed via different techniques ; step- cut, oblique-cut, double-chevron or V-shaped osteotomy (3,19,20,26). Cementless stems are suggested in many papers for longer prosthetic survival and simpler revision surgery than cemented stems. Placement of the acetabular cup in the true acetabulum is suggested to equalize lower limb length and to obtain sufficient abductor muscle power (12,18,21,29). In this study, we retrospectively evaluated 60 hips of 52 patients with Crowe type III or IV developmental dysplasia of the hip who underwent reconstruction with cementless total hip arthroplasty combined with a transverse subtrochanteric femoral osteotomy.

MATERIALS AND METHODS

From 2004 to 2008, 60 hips of 52 patients with Crowe type III or IV developmental dysplasia of the hip who

underwent reconstruction with cementless total hip arthroplasty combined with a transverse subtrochanteric femoral osteotomy were evaluated for prospectively followed patients. All patients gave the informed consent to this study. This study conforms to the declaration of Helsinki and was authorized by the ethical committee of the authors' institution. Eight of the patients underwent bilateral sequential total hip arthroplasty surgery. Pre-operative clinical and radiographic evaluation was made for all of the patients. On preoperative radiographs the degree of dysplasia was determined by using the system of Crowe (8). According to this system 37 of the dysplastic hips were type III and 23 of them were type IV. Pre-operative templating was made to determine the appropriate implant.

The average age was 51.4 years (range 31-69 years). 11 of the patients were male and 49 of the patients were female. Severe pain and functional impairment while performing daily activities were indications for arthroplasty.

Surgery was performed under general or spinal anesthesia with the patients placed in lateral decubitus position. Posterolateral approach was used for surgery. Surgeries were carried out by a single surgeon. Cementless femoral and acetabular components were used in all of the operations. The acetabular component was placed at the level of true acetabulum in all cases. In 7 out of the 60 hips morcellized autograft bone from the femoral head was applied behind the acetabular component. Subtrochanteric femoral osteotomy was performed in all cases in accordance to the preoperative planning, by resection of femur below lesser trochanter, derotation of the proximal part was performed if needed. The resected bone segment was divided along the axis into two pieces and secured at the osteotomy site with two or three titanium bands. Ceramic-ceramic coupling was used in 24 cases and metal-polyethylene coupling was used in 36 cases. 40 of the proximally hydroxyapatite (HA) porous-coated femoral components were Secur-Fit type (Osteonics, Allendale, NJ), and 20 of the femoral stems were secur-fit plus max type (Osteonics, Allendale, NJ) (Table I). This secur-fit plus max type femoral stem has the ability to fit different canal geometries with two distal diameters for each proximal size. (HA) porous-coated acetabular components with 2 or 3 dome screws were used in all hips, ranging from 40 to 48 mm in diameter (Fig. 2-3).

Drainage was removed and passive and active movements of the operated limb were started first day post-operatively. Partial weight bearing with two crutches was allowed before discharge from hospital. Patients were

Table I. — Patient demographics and implants

Variable	N
Patients	52
Hips	60
Mean age at time of surgery	51.4 ± 13.4
Mean follow-up time (year)	6.5 ± 1.7
Femoral stems	
* Secur-fit type	40
* Secur-fit plus max type	20
Acetabular component	
* ceramic-ceramic coupling	24
* metal-polyethylene coupling	36

discharged from 5 to 10 days (mean 8 days) postoperatively. Patients were examined at the third and sixth month postoperatively and once yearly after second examination until an average follow-up of 6.5 years (range 5-8 years). Patients were evaluated using the Merle D'Aubigne (10) and the Harris Hip score (17). Preoperative and postoperative leg length measurement was performed at clinical examination. Anteroposterior and lateral hip radiographs were obtained for radiographic examination. Radiographic analysis was performed using the system of DeLee and Charnley (11) and Gruen (16) for the acetabulum and femur respectively. Trendelenburg test was used to assess abductor strength. Both clinical and radiological evaluations were conducted by two independent observers (EZ and IEK).

RESULTS

Proximal femur fracture occurred in three cases and they were treated with titanium band cerclage. Superficial wound infection was observed in two cases and was treated by antibiotic regimen.

Merle D'Aubigne and Harris Hip score were used to rate the clinical outcome at the final follow up at a mean of 6.5 years (range 5-8 years). For Merle D'Aubigne ; preoperative mean pain score was 3.1 points (range 1-5 points) postoperatively it was found to be 5.4 points (range, 3-6 points). Mean preoperative score for function was 3.0 points (range 1-5 points), postoperative function score was 4.5 (range, 3-5) and preoperative mean range of motion score was 2.8 points (range 1-4 points). Postoperatively this score was improved to 5 points

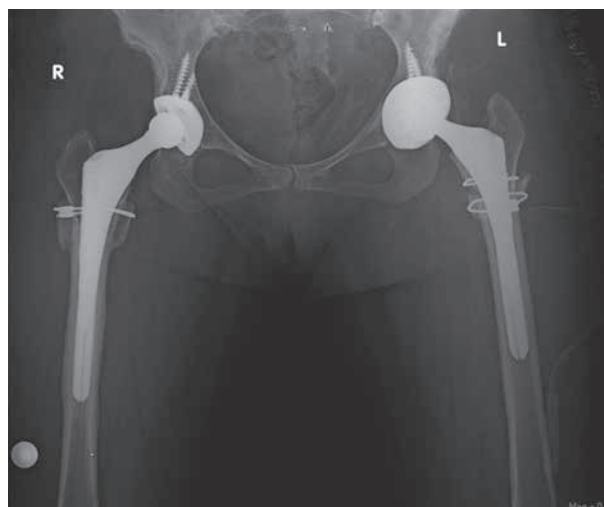


Fig. 2. — Secur-Fit plus max type femoral stem.

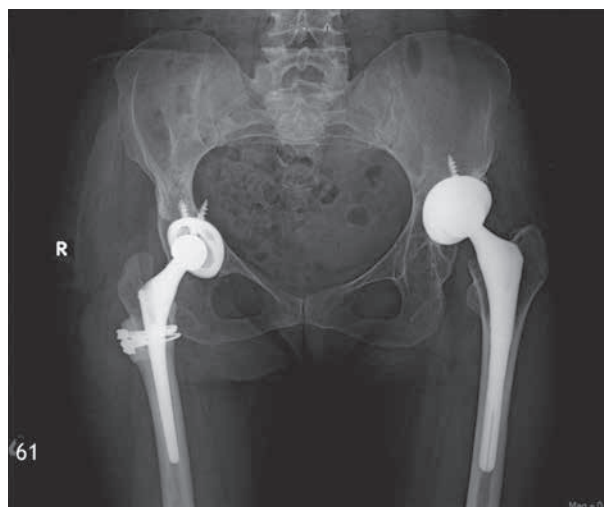


Fig. 3. — Secur-Fit type femoral stem

(range 4-6 points). Mean preoperative Harris Hip score was 39.0 (range 25-60), postoperatively Harris Hip Score improved to 92.8 (range 80-100) ($p < 0.001$). Trendelenburg sign was positive in all patients preoperatively, at final follow up it was present in 11 patients. 18 patients had a leg length discrepancy less than 1 cm and 7 patients more than 1 cm (up to 1.4 cm) at final follow up.

Radiographic analysis showed that 4 femoral stems had radiolucent lines less than 2 mm in zones 2-3, 6, 2 and 3-4 respectively however in these

Table II. — Hips with osteolysis

Gruen	Time since surgery
Zone 2-3	85 months
Zone 6	94 months
Zone 2	81 months
Zone 3-4	76 months

4 cases no definite radiographic or clinical indication of implant loosening was observed (Table II). All of the stems with radiolucent lines were secur-fit type stems ; we did not observe any radiolucent lines in secur-fit plus max type which had the ability to fit different sizes of canal geometries. We did not observe any radiolucent lines or expansile osteolytic lesions suggestive of loosening (35) in any of the acetabular components. There was no migration of any implant and none of the implants has been revised. All femoral shortening osteotomies were united at a mean of 5.7 months. There was no significant difference in time to union between different types of stems.

DISCUSSION

Due to the pathological anatomy of the hip in developmental hip dysplasia, total hip replacement is a technically demanding procedure. In the absence of pain, dislocation is not an indication for arthroplasty. Survival of the implants depends both on the implants chosen and the surgical technique. Initial rigid fixation of the femoral component is essential to avoid both prosthetic micromotion and fibrous tissue around the stem in cementless implants. Although cancellous bone provides some mechanical strength in the acetabulum, a good cortical rim fit of the component should be achieved. Secure fixation of the cup requires additional fixation with screws. In the current study, 4 of these cases had some amount of radiolucency around the stem ; radiolucent lines observed were below the level of the subtrochanteric osteotomy site. None of these femoral stems were of secur-fit plus max type, which had the ability to fit larger canals. In proximally HA coated stems, porous surface is kept in the metaphyseal and upper metaphyseal regions of the femur, this me-

chanical design allows proximal loading and more load on the osteotomy site, in 20 of the cases we used secur-fit plus max type femoral stems providing more cortical contact at the distal femoral stem-cortical bone interface. This type of stem design allows distal loading without bypassing proximal metaphysis, due to its proximally HA porous coating design. We did not observe any significant delay of union at the osteotomy site in any of the cases. 8 of the 52 patients had bilateral high dislocations. Lengthening of one extremity in such situations will lead considerable discrepancy and abnormal stresses on the total hip arthroplasty so we applied the same procedure later on the opposite side. Radiolucent lines were noted in 4 hips (7%), they were observed in Gruen zones 2-3, 5-6, 2 and 3-4 respectively. Osteolysis tended to be distal to osteotomy site, there was no osteolysis at proximal regions of any stems. None of the hips have undergone acetabular or femoral revision. Osteolysis rates were reported to be higher in some prior studies of longer follow-up periods with extensively porous-coated and proximally HA-coated femoral stems (9,13) however osteolysis rates are higher in cemented implants. Some authors reported high aseptic loosening rates with cemented prosthesis. Stans *et al* (32) reported 40% aseptic loosening for femoral stems at an average of 16 years follow-up. There are some reports regarding the increase in stress shielding with increased stem diameters (15) which may lead to stem loosening however in our series we did not observe severe stress shielding with larger distal stem sizes, longer-term follow-up periods may be needed in this group of patients with poorer bone quality. In some prior studies, delayed union of the osteotomy site has been reported (24,31) however union of the osteotomy site is generally less than six months (23). Union of the osteotomy site takes longer time with cemented stems due to the presence of the cement in the medullary cavity which degenerates endosteum and decreases number of bone marrow cells. In the current study, cementless hip arthroplasty components showed adequate performance and patients had satisfactory clinical and radiographic results. Biant *et el* reported similar follow-up results for cementless hip implants in ten years of mean follow-up time (4). A limitation to

this study was the relatively short follow-up time for evaluation of the outcome of a hip prosthesis. Femoral stem structure with the ability to fit larger canals will provide more cortical contact at the distal femoral stem-cortical bone interface and may lead less osteolysis distally without causing significant delay of union at the osteotomy site.

REFERENCES

- Anwar MM, Sugano N, Masuhara K et al.** Total hip arthroplasty in the neglected congenital dislocation of the hip : a five to 14-year follow-up study. *Clin Orthop Relat Res* 1993 ; 127-34.
- Argenson JN, Flecher X, Parratte S, Aubaniac JM.** Anatomy of the dysplastic hip and consequences for total hip arthroplasty. *Clin Orthop Relat Res* 2007 ; 465 : 40-5.
- Becker DA, Gustilo RB.** Double-chevron subtrochanteric shortening derotational femoral osteotomy combined with total hip arthroplasty for the treatment of complete congenital dislocation of the hip in the adult. Preliminary report and description of a new surgical technique. *J Arthroplasty* 1995 ; 10 : 313-18.
- Biant LC, Bruce WJ, Assini JB, Walker PM, Walsh WR.** Primary total hip arthroplasty in severe developmental dysplasia of the hip. Ten-year results using a cementless modular stem. *J Arthroplasty* 2009 ; 24 : 27-32
- Cameron HU, Botsford DJ, Park YS.** Influence of the Crowe rating on the outcome of total hip arthroplasty in congenital hip dysplasia. *J Arthroplasty* 1996 ; 11 : 582-7.
- Charnley J, Feagin JA.** Low-friction arthroplasty in congenital subluxation of the hip. *Clin Orthop Relat Res* 1973 ; 98-113.
- Chougle A, Hemmady MV, Hodgkinson JP.** Severity of hip dysplasia and loosening of the socket in cemented total hip replacement. A long term follow-up. *J Bone Joint Surg Br* 2005 ; 87 : 16.
- Crowe JF, Mani VJ, Ranawat CS.** Total hip replacement in congenital dislocation and dysplasia of the hip. *J Bone Joint Surg Am* 1979 ; 61 : 15-23.
- D'Antonio JA, Capello WN, Manley MT.** Remodelling of bone around hydroxyapatite-coated femoral stems. *J Bone Joint Surg* 1996 ; 78A : 1226.
- D'Aubigne RM, Postel M.** Functional results of hip arthroplasty with acrylic prosthesis. *J Bone Joint Surg Am* 1954 ; 36 : 451-475.
- DeLee JG, Charnley J.** Radiological demarcation of cemented sockets in total hip replacement. *Clin Orthop Relat Res* 1976 ; 121 : 20-31.
- Dunn HK, Hess WE.** Total hip reconstruction in chronically dislocated hips. *J Bone Joint Surg Am* 1976 ; 58 : 838-845.
- Engh CA, Bobyn JD, Glassman AH.** Porous-coated hip replacement. The factors governing bone ingrowth, stress shielding and clinical results. *J Bone Joint Surg Am* 1987 ; 69B : 45.
- Eskelinen A, Helenius I, Remes V et al.** Cementless total hip arthroplasty in patients with high congenital hip dislocation. *J Bone Joint Surg Am* 2006 ; 88 : 80-91.
- Glassman AH, Bobyn JD, Tanzer M.** New femoral designs : do they influence stress shielding ? *Clin Orthop Relat Res* 2006 ; 453 : 64.
- Gruen TA, McNeice GM, Amstutz HC.** Modes of failure of cemented stem-type femoral components : a radiographic analysis of loosening. *Clin Orthop Relat Res* 1979 ; 141 : 17-27.
- Harris WH.** Traumatic arthritis of the hip after dislocation and acetabular fractures : treatment by mold arthroplasty. An end-result study using a new method of result evaluation. *J Bone Joint Surg Am* 1969 ; 51 : 737-755.
- Hartofilakidis G, Karachalios T.** Total hip arthroplasty for congenital hip disease. *J Bone Joint Surg Am* 2004 ; 86 : 242-50.
- Hotokebuchi T, Sonohata M, Shigematsu M, Mawatari M.** A new device for a V-shaped subtrochanteric osteotomy combined with total hip arthroplasty. *J Arthroplasty* 2006 ; 21 : 135-7.
- Huo MH, Zatorski LE, Keggi KJ.** Oblique femoral osteotomy in cementless total hip arthroplasty. Prospective consecutive series with a 3-year minimum follow-up period. *J Arthroplasty* 1995 ; 10 : 319-27.
- Karachalios T, Hartofilakidis G.** Congenital hip disease in adults : terminology, classification, pre-operative planning and management. *J Bone Joint Surg Br* 2010 ; 92 : 914-921.
- Krych AJ, Howard JL, Trousdale RT, Cabanela ME, Berry DJ.** Total hip arthroplasty with shortening subtrochanteric osteotomy in Crowe type-IV developmental dysplasia. *J Bone Joint Surg Am* 2009 ; 91 : 2213-21.
- Makita H, Inaba Y, Hirakawa K, Saito T.** Results on total hip arthroplasties with femoral shortening for Crowe's group IV dislocated hips. *J Arthroplasty* 2007 ; 22 : 32-8.
- Masonis JL, Patel JV, Miu A et al.** Subtrochanteric shortening and derotational osteotomy in primary total hip arthroplasty for patients with severe hip dysplasia : 5-year follow-up. *J Arthroplasty* 2003 ; 18 : 68-73.
- Noble PC, Kamaric E, Sugano N et al.** Three-dimensional shape of the dysplastic femur : implications for THR. *Clin Orthop Relat Res* 2003 ; 417 : 27-40.
- Paavilainen T, Hoikka V, Solonen KA.** Cementless total replacement for severely dysplastic or dislocated hips. *J Bone Joint Surg Br* 1990 ; 72 : 205-11.
- Pagnano W, Hanssen AD, Lewallen DG, Shaughnessy WJ.** The effect of superior placement of the acetabular component on the rate of loosening after total hip arthroplasty. *J Bone Joint Surg Am* 1996 ; 78 : 1004.
- Park MS, Kim KH, Jeong WC.** Transverse subtrochanteric shortening osteotomy in primary total hip arthroplasty for patients with severe hip developmental dysplasia. *J Arthroplasty* 2007 ; 22 : 1031-6.

29. **Perka C, Fischer U, Taylor WR, Matziolis G.** Developmental hip dysplasia treated with total hip arthroplasty with a straight stem and a threaded cup. *J Bone Joint Surg Am* 2004 ; 86 : 312-19.
30. **Reikeras O, Haaland JE, Lereim P.** Femoral shortening in total hip arthroplasty for high developmental dysplasia of the hip. *Clin Orthop Relat Res* 2010 ; 468 : 1949-55.
31. **Sener N, Tozun IR, Asik M.** Femoral shortening and cementless arthroplasty in high congenital dislocation of the hip. *J Arthroplasty* 2002 ; 17 : 41-8.
32. **Stans AA, Pagnano MW, Shaughnessy WJ, Hanssen AD.** Results of total hip arthroplasty for Crowe type III developmental hip dysplasia. *Clin Orthop* 1998 ; 348 : 149.
33. **Sugano N, Noble PC, Kamaric E et al.** The morphology of the femur in developmental dysplasia of the hip. *J Bone Joint Surg Br* 1998 ; 80 : 711-719.
34. **Togrul E, Ozkan C, Kalaci A, Gulsen M.** A new technique of subtrochanteric shortening in total hip replacement for Crowe type 3 to 4 dysplasia of the hip. *J Arthroplasty* 2010 ; 25 : 465-70.
35. **Zicat B, Engh CA, Gokeen E.** Patterns of osteolysis around total hip components inserted with and without cement. *J Bone Joint Surg Am* 1995 ; 77 : 432.