



## Computed tomography-guided percutaneous focal catheter infusion in the treatment of spinal tuberculosis

Xiaohua HOU, Xiaowei SUN, Zhiyong ZHANG, Guangyue XIE, Xifeng ZHANG

From Department of Orthopaedics, Tangshan Workers' Hospital of Hebei Medical University, Tangshan, China

The study aimed to investigate the efficacy of computed tomography (CT)-guided percutaneous focal catheter infusion for the treatment of spinal tuberculosis. Clinical and follow-up data from 27 spinal tuberculosis patients who underwent CT-guided intervertebral catheterized infusion chemotherapy from May 2008 to October 2011 were retrospectively analyzed; treatment included pure intervertebral infusion chemotherapy and catheter drainage for continuous abscess washing during infusion chemotherapy. All surgeries were successfully completed under CT guidance without complications. The C-reactive protein levels of most patients rebounded within the first postoperative week but significantly decreased after the second and fourth postoperative weeks. CT-guided percutaneous focal catheter infusion was effective for the treatment of spinal tuberculosis and induced little trauma; this treatment could also relieve the symptoms and improve the quality of life of elderly patients with poor general conditions.

**Keywords:** spinal tuberculosis; CT-guided; spinal minimal invasive surgery.

### INTRODUCTION

Spinal tuberculosis (ST) is among the most common spinal infectious diseases. Vertebral or ST accounts for approximately 50% to 75% of all osteoarticular tuberculosis cases, and the affected patients are mostly young and middle-aged adults,

with females slightly outnumbering males. As this disease involves the spine, it often causes spinal deformity and compression of the spinal cord or nerve root, leading to serious adverse consequences. In China, young and middle-aged adults often comprise a family's main source of income and labor; once these individuals are infected with ST and consequently become paralyzed and lose their valuable working abilities, a heavy burden is placed on the families and society (1,2,5-9,11-15,17-20). Currently, simple systemic anti-tuberculosis drug treatment is often administered to most ST patients with milder nerve compression symptoms (below Frankel grade C) (4). As it is difficult to instill drugs into the core of the liquefaction necrosis lesion, the cure rate of this method is low and the recurrence rate is high. However, the spinal deformity is often milder in

- Xiaohua Hou<sup>1</sup>.
- Xiaowei Sun<sup>1</sup>.
- Zhiyong Zhang<sup>1</sup>.
- Guangyue Xie<sup>1</sup>.
- Xifeng Zhang<sup>2</sup>.

<sup>1</sup>Department of Orthopaedics, Tangshan Workers' Hospital of Hebei Medical University, Tangshan, 063000, China.

<sup>2</sup>Special Hospital of Orthopaedics, the General Hospital of the People's Liberation Army (PLA), Beijing, 100039, China.

Correspondence: Xifeng Zhang, Special Hospital of Orthopaedics, the General Hospital of the People's Liberation Army (PLA), Beijing, 100039, China.

E-mail: xiaoweisuncn@163.com

© 2014, Acta Orthopædica Belgica.

such cases, and therefore debridement with internal spinal fixation might lead to excessive treatment and aggravate the economic burden on the patient.

In order to improve the ST treatment efficacy and reduce the treatment costs, the minimally invasive treatment computed tomography (CT)-guided percutaneous focal catheter infusion was applied for ST treatment in an attempt to maximally eliminate the tuberculosis lesions through catheter infusion and drainage. This also represented a minimally invasive technological extension of the ST radical correction concept, which was advocated by Professor Xianzhi Fang in the 1950s and 1960s (4). Based on systemic chemotherapy, the focal concentrations of anti-tuberculosis drugs were substantially increased and adequately drained for the purpose of curing local lesions and relieving systemic tubercular symptoms. From May 2008 to October 2011, 27 ST patients were subjected to this treatment method and achieved good results.

## MATERIALS AND METHODS

### Clinical data

Twenty-seven ST patients who underwent CT-guided intervertebral catheterized infusion chemotherapy from May 2008 to October 2011 at our department were selected for this study ; these included 19 cases of pure intervertebral chemotherapy and 8 cases involving catheter drainage for continuous abscess washing during infusion chemotherapy. The patients were 15 men and 12 women aged 34-88 years, with a mean age of  $56 \pm 14$  years. This study was conducted in accordance with the declaration of Helsinki. This study was conducted with approval from the Ethics Committee of Tangshan Workers' Hospital of Hebei Medical University. Written informed consent was obtained from all participants.

In the patients, the main manifestation was low back pain associated with an activity disorder. Physical examination revealed that the patients had lumbar spinous percussion pain, whereas some patients also had paraspinous percussion pain and positive straight-leg raising test results. Additionally, 11 patients had fever. 5 cases were accompanied by low limb radiating pain ; Frankel grading revealed that all these patients had grade D disease. And 2 cases were accompanied by lung and pleural tuberculosis. The lesion locations were as follows : 1 case in a thoracic vertebra, 7 in the thoracic waist, and 19 in

the lumbar vertebrae ; 15 cases were accompanied by paravertebral or psoas abscess, 6 had bilateral abscesses, and 9 had unilateral abscesses. All patients had the following indications of treatment eligibility : 1. formation of spinal tubercular abscesses, sequestrae, and cavity without obvious nerve compression symptoms ; 2. severe bone destruction, obvious kyphosis, or significant dead bone with accompanying nerve compression symptoms and neurological Frankel grading below and including grade C ; 3. recurrent disease after open surgery or development of sinus tract ST ; and 4. poor general condition and inability to tolerate surgery.

Patients in whom lesions skipped segments were then classified according to the severely infected vertebral body positions. All infected intervertebral spaces were subjected to catheter chemotherapy. Regarding the paraspinal abscess size, 12 cases with pure disc space infection or only single or few abscesses at the paraspine and psoas major muscle (abscess diameter < 2 cm) underwent simple intervertebral catheter-chemotherapy ; 8 cases with large abscesses at the paraspine or psoas major muscle (diameter > 5 cm) underwent catheter implantation for continuous irrigation and drainage ; and 7 cases with multiple small paraspinal abscesses or a large abscess at the psoas major muscle (diameter of 2-5 cm) underwent pus drainage during puncture to the extent possible but did not undergo catheter drainage. Therefore, among the total 27 patients, 19 underwent simple intervertebral infusion chemotherapy and 8 underwent fusion chemotherapy accompanied with continuous catheter drainage and flushing towards the abscess (Table I).

### Treatment

The SOMATOM.PLUS-4A Spiral CT Scanner (SIEMENS AG, Munich, Germany) was used for scanning and positioning with a slice thickness of 3-5 mm ; puncture catheterization was performed towards the intervertebral lesions and psoas abscesses according to the preoperative CT scanning and intraoperative CT guidance, respectively. The operations were performed under local anesthesia ; for thoracic vertebrae, punctures were performed above the transverse process and into the intervertebral space and paraspinal abscess, whereas for lumbar vertebrae, puncture was performed from the Kambin triangle into the intervertebral space. For psoas abscesses, puncture was performed vertically from the dorsal side, and for iliac fossa abscesses, puncture was performed from the anterior superior iliac spine. In cases of single or double vertebral infection in which the infection foci were limited and paraspinal abscess formation

Table I. — Details of abscess locations and sizes

	Small abscess (< 2 cm)	Middle abscess (2-5 cm)	Big abscess (> 5 cm)	summary
thoracic vertebrae (T1-T10)	1	0	0	1
thoracic waist (T11-L2)	4	2	1	7
lumbar vertebrae (L3-S1)	7	5	6	19
summary	12	7	8	27

was absent, 1-2 epidural tubes were retained for the drug-injection tubes. Patients with more extensive paraspinous or psoas abscesses underwent the placement of double-lumen silicone drainage tubes for continuous infusion according to the specific circumstances. Disposable AS-E/S II anesthesia puncture kits were provided by Shandong Weigao Group Medical Polymer Co., Ltd. (Weihai, P. R. China). The surgical procedures were as follows. (1) For epidural catheter placement, an epidural needle was used to puncture the lesions or abscesses; once CT scanning confirmed placement of the needle in the lesion center, the inner core was removed and the epidural tube placed, after which CT was performed again to confirm the end position, the epidural needle was removed, and the epidural tube was attached to the vicinal skin with medical paste. (2) For placement of a double-lumen tube, following successful puncture according to the above method, the inner core was pulled out and replaced with a guide wire. Using the guide wire, a 5-mm-OD expansion pipe with a tapered front was placed inside. After CT confirmation, the 5-mm-ID working casing was placed using the guide wire; after CT reconfirmation, the guide wire and expansion tube were taken out and the double-lumen tube was placed inside, followed by removal of the working casing. The drug-injection tube was sealed with heparin saline, and the drainage tube was connected to the sterile drainage bag, at which point the entire catheterization process was complete. Pus obtained via pretreatment puncture was subjected to tuberculosis culture along with drug susceptibility testing, as well as to ordinary bacterial culture and drug susceptibility testing.

During the treatment period, the patients were strictly kept in the supine position; after chemotherapy and catheter removal, the bed continuation time was determined according to the imaging of vertebral body damage and personal judgment. Patients who developed extensive vertebral destruction associated with multiple psoas abscesses would retain their double-lumen washing tubes; the infusion fluid was 1000-1500 ml of saline + 1 g of isoniazid (Tianjin Jinyao Amino Acid Co., Ltd., Tianjin,

P. R. China) for continuous infusion and drainage over a period of 2-4 weeks. Extubation was not performed until the drainage fluid was clear and without obvious floccular necrosis. The focal chemotherapy drug was 0.1 g of isoniazid given once or twice daily via the tube, and 80,000 units of gentamicin sulfate (CSPC Ouyi Pharmaceutical Co., Ltd., Shijiazhuang, P. R. China) could also be injected to prevent cross-infection. Local chemotherapy treatment lasted for 4-6 weeks and, if necessary, could be extended to 3 months. After discharge, oral antitubercular drug administration continued for 1 year, while functional rehabilitation and lumbar back muscle exercises were simultaneously performed under the protection of a thoracolumbar brace.

### Efficacy evaluation

Visual analog scale (VAS) was used to evaluate symptom relief. The erythrocyte sedimentation rate (ESR) and C-reactive protein (CRP) level were dynamically monitored preoperatively and each week postoperatively until the fourth week to evaluate the infection status.

### Statistical analysis

SPSS11.0 statistical software (SPSS, Inc., Chicago, IL, USA) was used for the statistical analysis. The data were expressed as means  $\pm$  standard deviations, and differences with a *P*-value < 0.05 were considered significant.

## RESULTS

### Follow-up

All surgeries were successfully completed under CT guidance without complications. During the infusion rinsing and local chemotherapy, 1 patient accidentally pulled out their injection tube because

of movement in bed and was subsequently re-catheterized under CT guidance and able to complete the therapy; the remaining patients all successfully completed the therapy while hospitalized. The abscess washing duration ranged 14-52 days with an average duration of  $29 \pm 11$  days, and the local chemotherapy duration ranged 28-75 days with an average duration of  $44 \pm 12$  days. Among the 27 patients, 1 female patient died within 2 months after therapy because of an association with level 3 silicosis and pulmonary tuberculosis, and therefore follow-up could not be performed. The remaining 26 patients were followed-up for 12-30 months, with a mean period of  $19 \pm 4$  months. During follow-up, no signs and symptoms recurred and the abscesses disappeared; additionally, the VAS scores decreased from the preoperative average of  $6.5 \pm 0.9$  to the postoperative average of  $2.4 \pm 0.7$  ( $P < 0.05$ ). Among the patients, 1 exhibited no significant improvement in neurological function because of an association with lumbar disc herniation, whereas the remaining 4 neurologic cases were all downgraded from Frankel D level to E level.

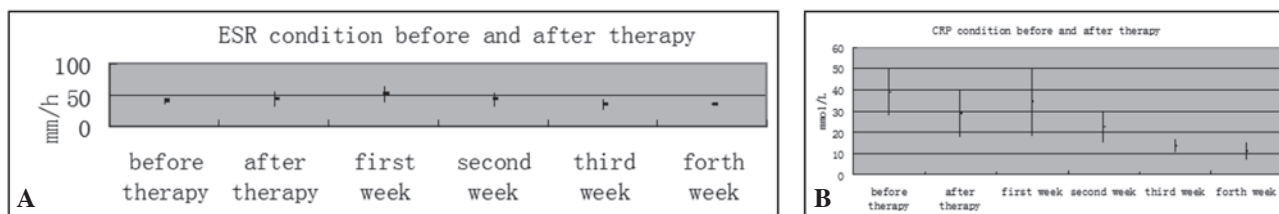
### Changes in the ESR and CRP level

Changes in the ESR from the preoperative to the postoperative levels at 1-4 weeks are shown in Fig. 1A; there were no statistically significant differences. Changes in CRP from the preoperative to the postoperative levels at 1-4 weeks as shown in Fig. 1B; most patients exhibited a rebound during the first postoperative week but exhibited significant decreases during the second postoperative week. The intergroup comparison revealed that there

was no significant difference between the first postoperative week and preoperative data, whereas the CRP values during the preoperative and second to fourth postoperative weeks exhibited statistically significant differences.

### DISCUSSION

Osteoarticular tuberculosis is the most common type of extrapulmonary tuberculosis. ST is the most frequently occurring form of osteoarticular tuberculosis, and its treatment has always plagued clinicians. Conservative treatment, which involves oral or intravenous systemic medication, provides acceptable efficacy against mild ST, although the side effect of bone destruction is also significant; however, it would be difficult to achieve the desired outcome in situations with abscess formation. Open surgical therapy is often difficult to perform in primary hospitals because of the high surgical difficulty, risk, and expense. In recent years, imaging techniques have undergone rapid development, and their irreplaceable advantages in minimally invasive treatment have been demonstrated. Dinc contributed the first international report of 21 patients with 26 iliopsoas tuberculous abscess lesions who were treated at the Farabi Hospital in Turkey from 1992 to 2000; these patients achieved good results following CT-guided percutaneous minimally invasive catheterization for abscess infusion (3). Zhang Xifeng of the Department of Orthopedics at Beijing 301 Hospital began to perform minimally invasive catheterized debridement and drug infusion treatment for ST in 2002 and has since achieved good results (21). He considered the core goal of minimal-



**Fig. 1.** — ESR and CRP changes after treatment

A : ESR changes before and within 4 weeks after the treatment

B : CRP changes before and within 4 weeks after the treatment.

ly invasive surgery for lumbar and lumbosacral tuberculosis to be improvement of the focal drug concentration. Effective improvement of the focal drug concentration was the difficulty associated with systemic medication for ST because of the specificity of local pathological changes and increases in bacterial drug resistance; the methods of long-term, high-dose, and combination therapy, which were supported by tuberculosis chemotherapy, were all directly focused on the above problem. The findings of our study were similar to those of previous studies (3,10). Minimally invasive surgery solved this problem in the most direct way. This type of surgery merely establishes and places tubes that can directly reach primary and secondary lesions under CT guidance but is unable to completely remove lesions, abscesses, voids, and sequestrae and is unable to correct deformities. Instead, the goal of this method was to increase the focal drug concentration, as this is the most powerful weapon with which to kill pathogens (8,9,16,21). Therefore, the following 4 points should be contraindications towards this treatment method: 1. infection at the local puncture site; 2. coagulation disorders; 3. accompanying nerve compression symptoms with a Frankel classification level above grade C (not including C); and 4. severely damaged vertebrae with obvious kyphosis, and vertebral body instability. For the patients who exhibited nerve compression symptoms because of obvious kyphosis or a huge sequestrum as well as those who required metal implantation because of poor spinal stability, open surgery was still recommended to clean the lesions, followed by intrafixation as the first choice.

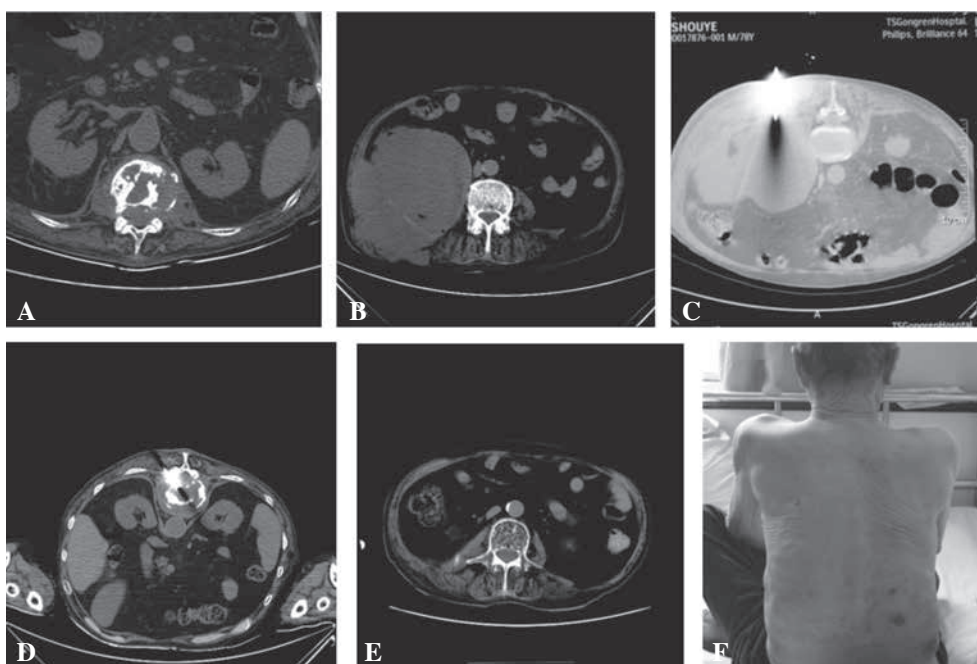
During the experiment, we observed that some patients developed fever, night sweats, and other symptoms 2-7 days after surgery and that during this period, the CRP levels were elevated over the preoperative levels; a possibility is that the puncture might have destroyed the lesion or abscess peps, resulting in the leakage of a small amount of pus into the circulatory system and inducing the degrees of systemic symptoms.

In previous clinical treatments, ST patients would normally undergo debridement and internal fixation, which would often result in changing the patients' spinal cord force lines, thereby reducing the

patients' activities and increasing the expenses associated with internal fixation materials and surgery (e.g., hospitalization would cost at least ¥100,000), all of which would place a serious burden on the patients and their families. Meanwhile, many ST patients did not have obvious spinal stability damage even if stability had been affected, and a short period of bed rest could completely restore stability. The suggestion to remove the sclerotic diseased vertebra faced the obvious suspicion of surgical exaggeration. Exaggerated lesion debridement and internal fixation might have serious negative effects on the patients whereas CT-guided percutaneous focal catheter infusion therapy demonstrated clear efficacy in these patients without further affecting the spinal morphology and mechanical properties. CT-guided minimally invasive surgery would leave no blind-point catheter positions and could achieve the aim of adequate drainage. At the same time, this method would not damage spinal posterior column structures such as the soft tissue, spinous process, and lamina, thus exerting no iatrogenic effects on the patients' spinal stability and an even smaller impact on the patients' internal environments. From an economic perspective, many ST patients have restricted economic conditions with low incomes, whereas spinal fixation materials are expensive; although the hospitalization time was long, the cost of minimally invasive local chemotherapy was still less than 30% of the cost of debridement and internal fixation.

Regarding old end-stage patients, open-lesion debridement and internal fixation surgeries are often difficult to tolerate and the surgical risks and cardiovascular complication rates were extremely high. In contrast, the duration of minimally invasive catheter insertion under local anesthesia would usually range 30-45 min, the resulting stress response in the body would be low, and the risk of complications would be significantly reduced. In this study, there were 3 patients older than 85 years, of whom one 87-year-old man experienced severe back pain and was unable to sit up by himself and was also affected by a huge retroperitoneal abscess; 3 weeks after infusion-rinsing, the abscess was significantly reduced and continued local chemotherapy yielded obvious improvements in back pain. Once the treatment was





**Fig. 2.** — Imaging and clinical manifestations before and after treatment

A : Preoperative vertebral destruction situation

B : Retroperitoneal abscess situation before the treatment

C : CT-guided abscess-puncturing catheterization

D : CT-guided intervertebral puncturing catheterization

E : Recheck 2 months after the treatment revealed that the abscesses significantly reduced

F : The patient could sit up all by himself after the treatment.

completed, the patient could stand and act on his own and could address the majority of his own life and care activities (Fig. 2). Meanwhile, one 88-year-old woman with associated level III silicosis and pulmonary tuberculosis died 2 months after treatment from internal lung disease ; however, at treatment completion, this patient still experienced significant pain relief and an improved end-stage quality of life.

In our clinical work, we found that the most common problem that appeared during catheter infusion therapy was oozing or leakage of the infusion fluid or medication from the wound. This was largely caused by poor drainage and excessive fluid pressure within the wound, and an epidural tube and body sinus tract contained the leakage. The prevention measure was intended to maintain an unobstructed drainage tube while, at the same time, the skin-exit of the drug injection tube could also be compressed when injecting the drug to reduce the

distance traveled by the drug to reach the lesion and reduce the space between the drug injection tube and the body's sinus tract. If necessary, the injection amount and infusion volume could be reduced or the drainage tube could be removed.

## CONCLUSION

CT-guided percutaneous focal catheter infusion could be used as a third option for the treatment of ST in addition to conservative treatment and the open surgery. This third option provides irreplaceable advantages for the treatment of the patients with vertebral destruction, abscesses, sequestrae, cavity formation and a lack of nerve compression, or mild symptoms. In elderly ST patients with poor general conditions and an inability to tolerate surgery, this technique could also relieve symptoms and improve the quality of life and therefore has good prospects for clinical application and

promotion. Currently, no multi-center large-sample prospective studies have been conducted to support the use of this treatment, and therefore additional work is needed in the future to improve the medical theory and practice.

## REFERENCES

1. **Benli IT, Acaroğlu E, Akalin S, Kiş M, Duman E, Un A.** Anterior radical debridement and anterior instrumentation in tuberculosis spondylitis. *Eur Spine J* 2003 ; 12 : 224-234
2. **China Tuberculosis Control Collaboration.** The effect of tuberculosis control in China. *Lancet* 2004 ; 364 : 417-422.
3. **Dinç H, Ahmetoğlu A, Baykal S, Sari A, Sayıl O, Gümele HR.** Image-guided percutaneous drainage of tuberculous iliopsoas and spondylodiskitite abscesses : midterm results. *Radiology* 2002 ; 225 : 353-358.
4. **Fang XZ, Tao P, Shang TY.** Clearance therapy of osteo-articular tubercular lesions : clinical report of 941 cases. *Chinese J Surgery* 1957 ; 1 : 31-71.
5. **Godlwana L, Gounden P, Ngubo P, Nsibande T, Nyawo K, Puckree T.** Incidence and profile of spinal tuberculosis in patients at the only public hospital admitting such patients in KwaZulu-Natal. *Spinal Cord* 2008 ; 46 : 372-374.
6. **Hakin FT, Flomerfelt FA, Boyiadzis M, Gress RE.** Aging, immunity, and cancer. *Curr Opin Immunol* 2004 ; 16 : 151-156.
7. **Jain AK, Aggarwal PK, Arora A, Singh S.** Behaviors of the kyphotic angle in spinal tuberculosis. *Int Orthop* 2004 ; 28 : 110-114.
8. **Jain AK.** Tuberculosis of the spine : A fresh look at an old disease. *J Bone Joint Surg* 2010 ; 92 : 905-913.
9. **Jutte PC, Van Altena R, Pras E, Thijn CJ.** Cause of misdiagnosis and mistreatment of spinal tuberculosis with radiotherapy in non-endemic area. A pitfall in diagnosis and treatment ; hazards of radiotherapy on the tuberculous lesion. *Spine* 2005 ; 20 : E300-304.
10. **Kotil K, Alan MS, Bilge T.** Medical management of Pott disease in the thoracic and lumbar spine : a prospective clinical study. *J Neurosurgery Spine* 2007 ; 6 : 222-228.
11. **Maeda Y, Izawa K, Nabeshima T, Yonenobu K.** Tuberculous spondylitis in elderly Japanese patients. *J Orthop Sci* 2008 ; 13 : 16-20.
12. **McLain RF, Isada C.** Spinal tuberculosis deserves a place on the radar screen. *Cleve Clin J Med* 2004 ; 71 : 534-549.
13. **Metha JS, Bhojraj SY.** Tuberculosis of the thoracic spine. A classification based on the selection of surgical strategies. *J Bone Joint Surg (Br)* 2001 ; 83 : 859-863.
14. **Pertuiset E, Beaudreuil J, Lioté F et al.** Spinal tuberculosis in adults. A study of 103 cases in a developed country, 1980-1994. *Med (Baltimore)* 1999 ; 78 : 309-320.
15. **Peter P, Robert D.** Noncontiguous spinal tuberculosis : incidence and management. *Euro Spine J* 2009 ; 18 : 1096-1101.
16. **Pombo F, Martín-Egaña R, Cela A, Díaz JL, Linares-Mondéjar P, Freire M.** Percutaneous catheter drainage of tuberculous psoas abscesses. *Acta Radiol* 1993 ; 34 : 366-368.
17. **Schlesinger N, Lardizabal A, Rao J.** Tuberculosis of the spine : experience in an inner city hospital. *J Clin Rheumatol* 2005 ; 11 : 17-20.
18. **Turgut M.** Spinal tuberculosis (Pott's disease) : its clinical presentation, surgical management, and outcome. A survey study on 694 patients. *Neurosurg Rev* 2001 ; 24 : 8-13.
19. **Wang H, Li C, Wang J, Zhang Z, Zhou Y.** Characteristics of patients with spinal tuberculosis : seven-year experience of a teaching hospital in Southwest China. *Int Orthop* 2012 ; 36 : 1429-1434.
20. **Weng CY, Chi CY, Shih PJ et al.** Spinal tuberculosis in non-HIV-infected patients : 10 year experience of a medical center in central Taiwan. *J Microbiol Immunol Infect* 2010 ; 43 : 464-469.
21. **Zhang XF, Wang Y, Xiao SH.** Treatment of lumbar and lumbosacral spinal tuberculosis with minimally invasive surgery. *Orthopaedic Surg* 2010 ; 2 : 64-70.