



## Comparison of two treatment strategy for Lenke I adolescent idiopathic scoliosis

Omer ERSEN, Serkan BILGIC, Selahattin OZYUREK, Safak EKINCI, Kenan KOCA, Erbil OGUZ

*From Maresal Cakmak Military Hospital, Department of Orthopaedics, Erzurum, Turkey*

The aim of the study study is to determine whether bilateral pedicle screw placement and posterior only spinal fusion improves sagittal correction parameters compared to alternate posterior segmental fixation in adolescent idiopathic scoliosis. 49 patients with Lenke Type 1 main thoracic curves who underwent single stage posterior only instrumentation and spinal fusion at a single center were retrospectively evaluated according to coronal radiological parameters. Patients divided into two groups of treatment strategy. Bilateral segmental fixation group's results were similar to alternate fixation group. Although quality of life or cosmetic evaluation of patients not involved in this study, alternate fixation provides similar results as bilateral segmental fixation in adolescen idiopathic scoliosis.

**Keywords :** adolescent idiopathic scoliosis ; Lenke type 1 curve ; fusion ; radiographical measurement.

### INTRODUCTION

The use of pedicle screw implants for adolescent idiopathic scoliosis (AIS) take place of hook implants over several years. Pedicle screws have been shown to be safe and effective with their greater correction power in coronal, sagittal and axial plains in the treatment of AIS (2,3,6,8,14,16,23,24). Beside this, pedicle screws were shown to have superior biomechanical properties from other instrumentation techniques (13,15).

Pedicle screw fixation in the toracic spine first used for trauma and tumors (21). In 1995 Suk *et al.* reported thoracic pedicle screw fixation in the treatment of AIS (24). They found better coronal correction with all screw constructs than all hook constructs. Correspondingly Kim *et al.* found 75% major curve correction in all screw group and 49% in all hook group. Lowenstein *et al.* observed better correction of main thoracic curve in the all screw construct group (9,17).

There are limited studies investigating whether bilateral pedicle screw placement improves correction of deformity compared to alternate segmental

- 
- Omer Ersen, MD.  
*Maresal Cakmak Military Hospital, Department of Orthopaedics, Erzurum, Turkey.*
  - Serkan Bilgic, MD.
  - Kenan Koca, MD.
  - Erbil Oguz, MD.  
*Gulhane Military Medical Academy, Department of Orthopaedics, Ankara, Turkey.*
  - Selahattin Ozyurek, MD.  
*Aksaz Military Hospital, Department of Orthopaedics, Mugla, Turkey.*
  - Safak Ekinci, MD.  
*Agri Military Hospital, Department of Orthopaedics, Agri, Turkey.*
- Correspondance : Ömer Ersen, Maresal Cakmak Military Hospital Palandoken, Erzurum, Turkey.  
E-mail : merschenn@yahoo.com  
© 2014, Acta Orthopædica Belgica.
-

fixation in AIS (19,27). Quan retrospectively reviewed Lenke Type 1 AIS who underwent one stage posterior only spinal fusion and found bilateral segmental fixation did not improve curve correction compared to unilateral or alternate segmental fixation (19). Yang *et al.* evaluate the relationship between implant density, Cobb angle correction and cosmesis and found that increasing density did not improve Cobb angle and did not change cosmesis parameters (27).

Radiological evaluation of AIS is not limited only with Cobb angle. T1 tilt angle clavicle angle, apical vertebral translation, trunk shift are parameters evaluating coronal balance in AIS (10,26). This study evaluates sagittal parameters of posterior only instrumented Lenke Type1 AIS patients between bilateral segmental fixation group and alternate segmental fixation groups.

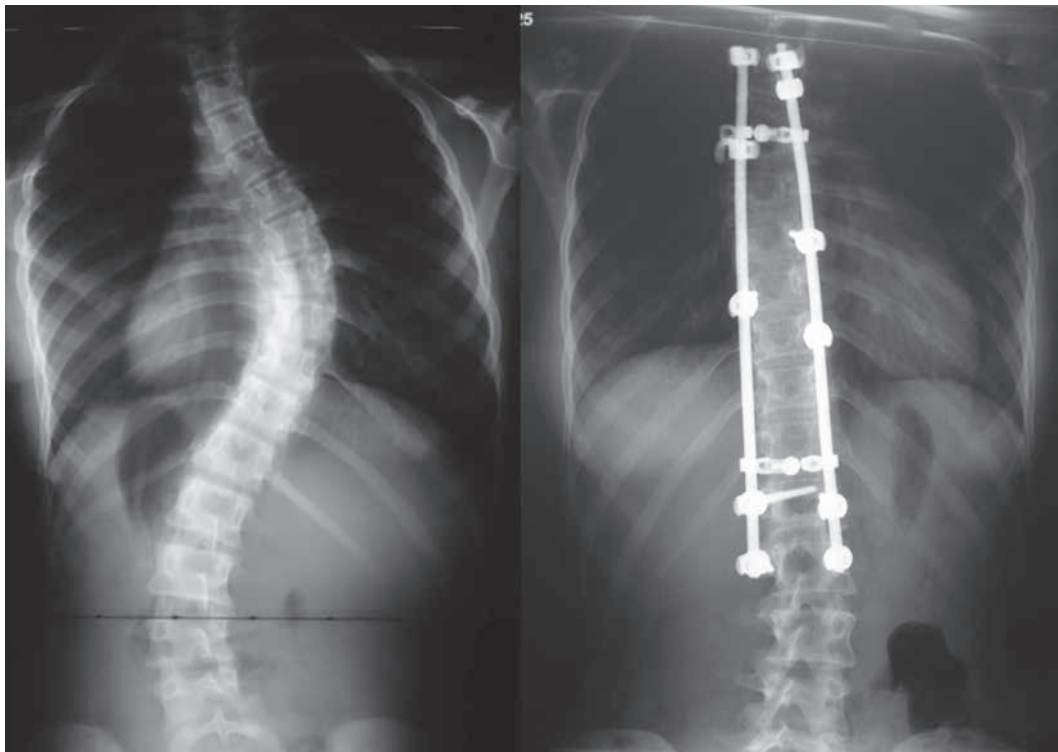
The purpose of this retrospective study is to determine whether bilateral pedicle screw placement and posterior only spinal fusion improves sagittal

correction parameters compared to alternate posterior segmental fixation in AIS.

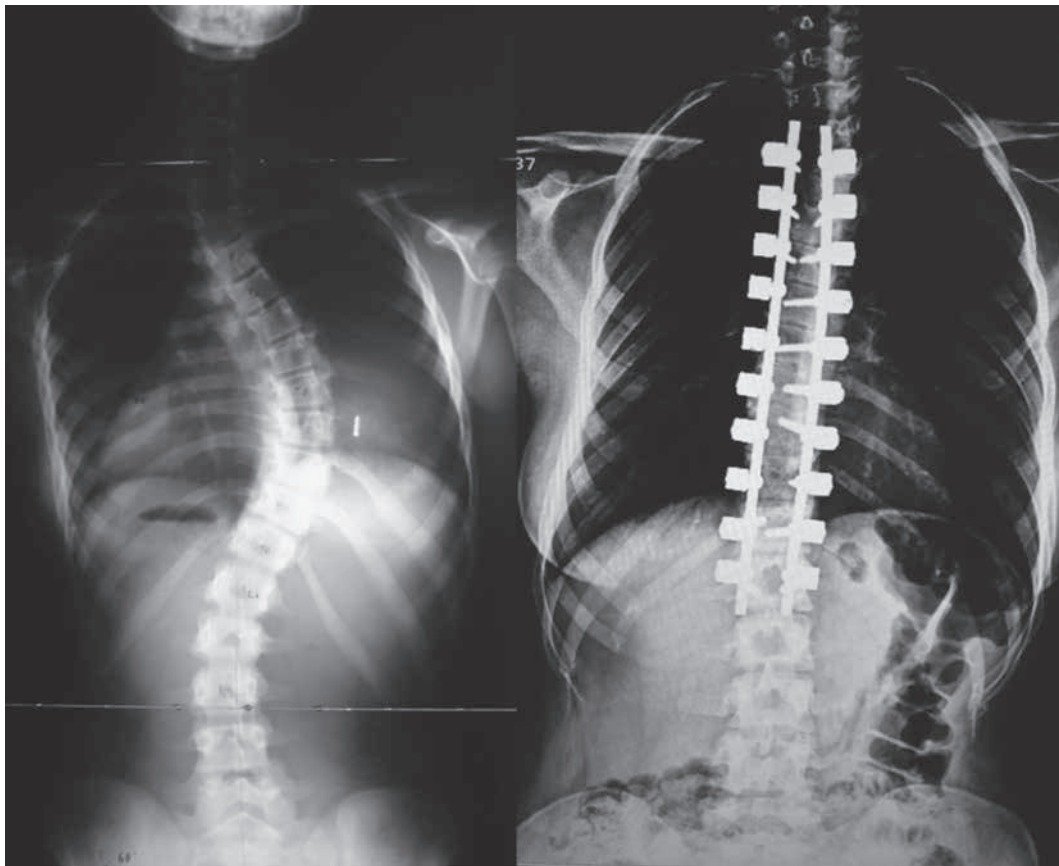
## MATERIALS AND METHODS

49 consecutive (7 males, 42 females) adolescent idiopathic scoliosis patients with Lenke Type 1 main thoracic curves who underwent single stage posterior only instrumentation and spinal fusion at a single center were retrospectively evaluated. Magnetic resonance imaging was routinely performed before the surgery and no neurological abnormality which could affect surgery strategy was detected. Apex of the major thoracic curves was between T6 and T10. The average age at the time of surgery was  $14 \pm 0,9$ . Patients were divided into two groups according to implantation as alternate segmental fixation group and bilateral segmental fixation group (Fig. 1, 2).

Coronal radiographic analyses include Cobb angles, apical vertebral translation (AVT), coronal balance (CB), T1 tilt angles (T1A), clavicle angles (CA), and trunk shift (TS). Standing whole spine anteroposterior radiographs before the surgery and at last follow up were evaluated.



*Fig. 1.* — Preoperative and 4 year postoperative x-ray of a patient in alternate fixation group



*Fig. 2.* — Preoperative and 3 year postoperative x-ray of a patient in bilateral fixation group

Patients without standard X ray were excluded from the study. Average follow up was 48 months.

All surgeries were performed by the same surgery group at a single institution, senior author was the major surgeon of all surgeries. Treatment was selective thoracic fusion usually extended from one level above the proximal end vertebra to one level below the distal end vertebrae. All pedicle screws were inserted using free hand technique under continuous neuromonitorization. Correction was performed by rod derotation, translation, segmental derotation and compression-disraction maneuvers. The posterior elements were decorticated and autologous bone grafts mixed with demineralized bone matrix placed along the decorticated fusion bed.

We used the SPSS software package (version 15.0, SPSS, Chicago, IL) and expressed categorical variables as percentages and continuous variables as mean  $\pm$  standard deviation (SD) or median (quartiles). We used the Kolmogorov-Smirnov test to evaluate whether the distribution of continuous variables was normal. For

parameters that showed normal distribution we used the paired sample t test and for parameters that did not show normal distribution we used the Mann-Whitney U-test. We used the Chi-square test to analyze categorical variables. Statistical significance was set at  $p < 0.05$ .

## RESULTS

Patient age at the the time of surgery was  $14,09 \pm 0,84$  in bilateral segmental fixation group of 23 (20 female, 3 male) patients and  $13,96 \pm 0,99$  in alternate segmental fixation group of 26 (22 female, 4 male) patients ( $p = 0,64$ ). Average follow up period of the groups was  $4,00 \pm 0,85$  and  $3,69 \pm 1,08$  years respectively ( $p = 0,28$ ).

In preoperative radiologic evaluation no significant difference found between the groups in Cobb angles of proximal thoracic, main thoracic and lumbar curves. Also the other coronal plane angles ;

Table I. — Preoperative coronal parameters

	Bilateral Fixation	Alternate Fixation	p
Proximal thoracic (°)	0,43 ± 0,89	0,54 ± 0,85	0,68*
Main thoracic (°)	3,61 ± 3,04	4,46 ± 2,84	0,31*
Lumbar (°)	1,91 ± 2,62	1,54 ± 1,52	0,54*
Apical vertebral translation (mm)	5,65 ± 6,23	7,73 ± 4,09	0,17*
Coronal balance (mm)	5,09 ± 3,99	4,54 ± 3,30	0,60*
Trunk shift (mm)	4,65 ± 4,141	3,92 ± 4,07	0,53*
T1 tilt angle (°)	0 (0-4)	0 (0-3)	0,53 <sup>†</sup>
Clavicle angle (°)	1 (0-5)	0 (0-4)	0,57 <sup>†</sup>

\* unpaired sample t test, <sup>†</sup> Mann Whitney U test.

apical vertebral translation, coronal balance, trunk shift, T1 tilt angles and clavicle angles found similar between groups (Table I). In postoperative radiologic evaluation correction of deformities did not differ and in last follow-up no significant difference was found according to mentioned parameters (Table II).

## DISCUSSION

Pedicle screw fixation for deformity surgery in thoracic spine became popular. It has been shown to be safe and accurate method and even in large curves can be used without pedicle screw related visceral or neurologic complications in experienced hands (8,12,19). The aim of our study was to compare two different treatment strategies for Lenke 1 adolescent idiopathic scoliosis retrospectively. There was no significant difference between the groups. Bilateral segmental pedicle screw fixation did not improve curve correction compared with unilateral or alternate segmental fixation.

In this study T1 tilt angle and clavicle angle were used to evaluate shoulder balance. Although these parameters found only partially correlated or non correlated with cosmetic appearance of shoulder in AIS patients (7,20), they frequently used in the literature (11,18,22). The current study demonstrate no difference in T1 tilt angle, clavicle angle and shoulder balance according to treatment strategy. Trunk shift, apical vertebral translation and coronal balance were parameters used to assess the global balance of the body pre and postoperatively in AIS (25,26). In

this study we measured these parameters and found no significant difference in global balance between bilateral segmental fixation and alternate fixation groups in Lenke 1 AIS patients.

Pedicle screws provides longer moment arm and better 3 column control compared with laminar hooks and for this reason segmental systems are currently decided to be the gold standard to correct deformities (5,15). As a result of these more correction of curves can be expected with bilateral segmental fixation. Lowenstein *et al.* compare all screw and hybrid constructs and found no significant difference between groups although better correction trend of main thoracic curves with all screw construct (17). Quan found no correlation between implant density and magnitude of coronal or sagittal correction in his study of 49 Lenke 1 AIS patients. Diametrically Dobbs *et al.* reported significant curve correction with pedicle screws versus hooks in major thoracic compensatory lumbar C modifier curves. They evaluate apical vertebral translation and global balance beside Cobb angles. Additionally they also found more correction in uninstrumented lumbar curve (5). In this study we evaluate Cobb angles, apical vertebral translation, coronal balance, T1 tilt angles, clavicle angles and trunk shift and found no significant difference between bilateral segmental fixation and alternate fixation group in all parameters.

In fact radiographic evaluation is not the only method that determines the coronal balance. Asher *et al.* reported posterior trunk surface topography of 44 idiopathic scoliosis patients treated with primary

Table II. — Postoperative coronal parameters

	Bilateral Fixation	Alternate Fixation	p
Proximal thoracic (°)	20,83 ± 7,86	20,96 ± 8,54	0,95*
Main thoracic (°)	49,09 ± 11,73	52,54 ± 11,79	0,31*
Lumbar (°)	27,91 ± 11,56	29,31 ± 8,49	0,63*
Apical vertebral translation (mm)	32,39 ± 12,59	32,88 ± 13,82	0,89*
Coronal balance (mm)	12,57 ± 10,25	15,42 ± 8,29	0,28*
Trunk shift (mm)	11,57 ± 6,28	14,00 ± 10,04	0,32*
T1 tilt angle (°)	0 (0-3)	0 (0-4)	0,23 <sup>†</sup>
Clavicle angle (°)	1 (0-5)	0 (0-4)	0,13 <sup>†</sup>

\* unpaired sample t test, <sup>†</sup> Mann Whitney U test.

posterior instrumentation and arthrodesis to assess trunk deformity (1). Unfortunately we did not have a device or program measuring topography and clinical trunk deformity was not evaluated.

One of the most popular argument on bilateral segmental fixation is loss of thoracic kyphosis. Lowenstein *et al.* demonstrated significant decrease of kyphosis with all screw construct versus hybrid constructs (17). In their recent meta-analysis Cao *et al.* found hybrid constructs more powerful in restoring kyphosis than pedicle screw (4). In this study we could not assess the sagittal plane alterations pre or postoperatively due to non-standard lateral x rays of the patients.

There were some other limitations of the current study. Because of the retrospective design, clinical evaluation or quality of life of patients before and after the surgery could not be compared. Although groups were similar before surgery, implants were not all from the same manufacturer, so implant problems were disregarded.

In conclusion, in this study bilateral segmental fixation and alternate fixation treatment strategies produced similar corrections in AIS patients. This study showed that for a similar group of patients with Lenke 1 curves bilateral segmental fixation does not equal to more coronal correction compared to alternate fixation in AIS. Further investigations including quality of life and cosmetic evaluations needed to compare these strategies completely.

## REFERENCES

1. Asher M, Lai SM, Burton D, Manna B. Maintenance of trunk correction following posterior instrumentation and arthrodesis for idiopathic scoliosis. *Spine (Phila Pa 1976)* 2004 ; 29 (16) : 1782-1788.
2. Belmont PJ Jr, Klemme WR, Dhawan A, Polly DW Jr. In vivo accuracy of thoracic pedicle screws. *Spine* 2001 ; 26 : 2340-6.
3. Belmont PJ Jr, Klemme WR, Robinson M, Polly DW Jr. Accuracy of thoracic pedicle screws in patients with and without coronal plane spinal deformities. *Spine* 2002 ; 27 : 1558-1566.
4. Cao Y, Xiong W, Li F. Pedicle Screw Versus Hybrid Construct Instrumentation in Adolescent Idiopathic Scoliosis : Meta-Analysis of Thoracic Kyphosis. *Spine (Phila Pa 1976)* 2014 ; 39 (13).
5. Dobbs MB, Lenke LG, Kim YJ, Kamath G *et al.* Selective posterior thoracic fusions for adolescent idiopathic scoliosis : comparison of hooks versus pedicle screws. *Spine (Phila Pa 1976)* 2006 ; 31 (20) : 2400-2404.
6. Gaines RW Jr. The use of pedicle-screw internal fixation for the operative treatment of spinal disorders. *J Bone Joint Surg Am* 2000 ; 82 : 1458-1476
7. Ilharreborde B, Even J, Lefevre Y, Fitoussi F *et al.* How to determine the upper level of instrumentation in Lenke types 1 and 2 adolescent idiopathic scoliosis : a prospective study of 132 patients. *J Pediatr Orthop* 2008 Oct-Nov ; 28 (7) : 733-739.
8. Kim YJ, Lenke LG, Bridwell KH, Cho YS *et al.* Free hand pedicle screw placement in the thoracic spine : is it safe ? *Spine* 2004 ; 29 : 333-342.
9. Kim YJ, Lenke LG, Cho SK, Bridwell KH *et al.* Comparative analysis of pedicle screw versus hook



- instrumentation in posterior spinal fusion of adolescent idiopathic scoliosis. *Spine* 2004 ; 29 : 2040-2048.
10. **Knott PT, Mardjetko SM, Techy F.** The use of T1 sagittal angle predicting overall sagittal balance in spine. *Spine J* 2010 ; 10 (11) : 994-998.
  11. **Kuklo TR, Lenke LG, Graham EJ, Won DS et al.** Correlation of radiographic, clinical and patient assessment of shoulder balance following fusion versus nonfusion of the proximal thoracic curve in adolescent idiopathic scoliosis. *Spine* 2002 ; 27 : 2013-2020.
  12. **Kuklo TR, Lenke LG, O'Brien MF, Lehmann RA Jr. et al.** Accuracy and efficacy of thoracic pedicle screws in curves more than 90 degrees. *Spine* 2005 ; 30 : 222-226.
  13. **Lehman RA Jr, Polly DW Jr, Kuklo TR, Cunningham B et al.** Straight-forward versus anatomic trajectory technique of thoracic pedicle screw fixation: a biomechanical analysis. *Spine* 2003 ; 28 : 2058-2065.
  14. **Lehmann RA, Lenke LG, Keeler KA, Kim YJ et al.** Operative treatment of adolescent idiopathic scoliosis with posterior pedicle screw-only constructs: minimum three-year follow-up of one hundred fourteen cases. *Spine* 2008 ; 33 : 1598-1604
  15. **Liljenqvist U, Hackenberg L, Link T, Halm H.** Pullout strength of pedicle screws versus pedicle and laminar hooks in the thoracic spine. *Acta Orthop Belg* 2001 ; 67 : 157-163.
  16. **Liljenqvist UR, Halm HFH, Link TM.** Pedicle screw instrumentation of the thoracic spine in idiopathic scoliosis. *Spine* 1997 ; 22 : 2239-2245.
  17. **Lowenstein JE, Matsumoto H, Vitale MG, Weidenbaum M et al.** Coronal and Sagittal Plane Correction in Adolescent Idiopathic Scoliosis A Comparison Between All Pedicle Screw Versus Hybrid Thoracic Hook Lumbar Screw Constructs. *Spine* 2007 ; 32 : 448-452
  18. **Matsumoto M, Watanabe K, Ogura Y, Okada E et al.** Short fusion strategy for Lenke type 1 thoracic curve using pedicle screw fixation. *J Spinal Disord Tech* 2013 ; 26 (2) : 93-97.
  19. **Quan GMY, Gibson MJ.** Correction of main thoracic adolescent idiopathic scoliosis using pedicle screw instrumentation. Does higher implant density improve correction ? *Spine* 2010 ; 35 : 562-567.
  20. **Qui XS, Ma WW, Li WG, Yu Y et al.** Discrepancy between radiographic shoulder balance and cosmetic shoulder balance in adolescent idiopathic scoliosis patients with double thoracic curves. *Eur Spine J* 2009 ; 18 (1) : 45-51.
  21. **Roy-Camille R, Saillant G, Berteaux D, Salgado V.** Osteosynthesis of thoracolumbar spine fractures with metal plates screwed through the vertebral pedicles. *Reconstr Surg Traumatol* 1976 ; 15 : 2-16.
  22. **Suk SI, Kim WJ, Kim JH, Lee SM, Lee JH.** Indications of proximal thoracic curve fusion in thoracic adolescent idiopathic scoliosis. *Spine* 2000 ; 25 : 2342-2349.
  23. **Suk SI, Kim WJ, Lee SM, Kim JH et al.** Thoracic pedicle screw fixation in spinal deformities: are they really safe ? *Spine* 2001 ; 26 : 2049-2057.
  24. **Suk SI, Lee CK, Kim WJ, Chung YJ et al.** Segmental pedicle screw fixation in the treatment of thoracic idiopathic scoliosis. *Spine* 1995 ; 20 : 1399-1405.
  25. **Trobisch PD, Samdani AF, Pahys JM, Cahill PJ.** Postoperative trunk shift in Lenke 1 and 2 curves: how common is it? and analysis of risk factors. *Eur Spine J* 2011 ; 20 (7) : 1137-1140.
  26. **Wang Y, Bünger CE, Wu C, Zhang Y et al.** Postoperative Trunk Shift in Lenke 1C Scoliosis What Causes It? How Can It Be Prevented? *Spine (Phila Pa 1976)* 2012 ; 37 (19) : 1676-1682.
  27. **Yang S, Jones-Quaidoo SM, Eager M, Griffin JW et al.** Right adolescent idiopathic curve (Lenke 1 A and B) does cost of instrumentation and implant density improve radiographic and cosmetic parameters ? *Eur Spine* 2011 ; 20 : 1039-1047.