



## Kyphoplasty versus vertebroplasty in the treatment of painful osteoporotic vertebral compression fractures : two-year follow-up in a prospective controlled study

Junhua DU, Xigong LI, Xiangjin LIN

*From Department of Orthopaedic Surgery, First Affiliated Hospital of Zhejiang University, Hangzhou, China*

A total of 112 patients with a single-level osteoporotic vertebral compression fracture who did not respond to conservative therapy were included and allocated to either kyphoplasty or vertebroplasty treatment. The Visual Analogue Scale (VAS) and Oswestry Disability Index (ODI) were used to assess back pain and disability. Anterior, midline, posterior vertebral body heights, and kyphotic angle at the fractured vertebra were measured for radiographic evaluation. Clinical and radiographic follow-up examinations were performed postoperatively at 3, 6, 12 and 24 months. Complications and patient satisfaction with the surgical procedure were also recorded.

The follow-up rate was 73.3% in the kyphoplasty group and 80.8% in the vertebroplasty group ( $P = 0.737$ ). There were no significant differences between the 2 groups with regard to improvement in VAS and ODI scores ( $P > 0.05$ ) at all postoperative intervals. Both treatment groups achieved marked vertebral height restoration and kyphotic angle reduction, but the radiographic parameters were significantly better in the kyphoplasty group ( $P < 0.05$ ). The incidence of asymptomatic cement leakage per treated vertebrae in the kyphoplasty group was 11.4% versus 31% in the vertebroplasty group ( $P < 0.001$ ). Three adjacent level fractures in the kyphoplasty group and 2 in the vertebroplasty group occurred during 2-year follow-up, and no

difference in patient satisfaction was detected between the 2 groups. Kyphoplasty and vertebroplasty achieved similar improvement of clinical outcomes and patient satisfaction at 2 years after surgery, albeit kyphoplasty had more ability to markedly reduce vertebral deformity and resulted in less cement leaks compared with vertebroplasty.

**Keywords :** osteoporotic ; vertebral fracture ; kyphoplasty ; vertebroplasty.

### INTRODUCTION

Vertebral compression fractures (VCFs) are the most common fractures among the elderly with osteoporosis (7). The consequences of osteoporotic VCFs include pain over that fracture region, and in many cases, progressive vertebral collapse with resultant spinal deformity. Despite appropriate

■ Junhua Du, PhD, MD.

■ Xigong Li, PhD, MD.

■ Xiangjin Lin, MD.

*Department of Orthopaedic Surgery, First Affiliated Hospital of Zhejiang University, Hangzhou, China*

Correspondence : Xiangjin Lin, Department of Orthopaedic Surgery, First Affiliated Hospital of Zhejiang University, Qingchun 79, Hangzhou, Zhejiang Province, China, 31002.

E-mail : zyorthopaedic@aliyun.com

© 2014, Acta Orthopædica Belgica.

*The first two authors contributed equally to this study and share first authorship.*

*No funds were received in support of this work, and no benefits in any form have been or will be received from a commercial party related directly or indirectly to the subject of this manuscript.*

conservative treatment involving analgesics, bed rest, and external bracing, as many as one third of patients fail to obtain any symptomatic relief (34). Chronic pain and kyphotic deformity may lead to impaired physical function, decreased quality of life and increased mortality in this cohort (6,19,31,32).

Kyphoplasty and vertebroplasty are two minimally invasive procedures that have been consistently shown to be safe and effective in the treatment of symptomatic osteoporotic VCFs (1,3,4,11,13,18,20,22,24,33,44). While the benefits of both procedures compared to conservative therapy are already documented in recent randomized controlled trials (38,39,47), it remains uncertain whether one provides better treatment outcomes than the other. To date, there have been some clinical studies that directly compare kyphoplasty and vertebroplasty in the treatment of osteoporotic VCFs (8,9,12,14,27,28,37,40). Most of them, including one prospective randomized trial, have found kyphoplasty and vertebroplasty are equally effective in the short-term clinical improvement of pain and function (8,27,28,37,40).

However, despite the similarly early clinical efficacy, radiographic findings in previous reports demonstrate that kyphoplasty can offer a substantially higher degree of improvement in vertebral height or kyphotic angle than vertebroplasty (27,28,37,40). The obvious advantage in this regard can be ascribed to the kyphoplasty procedure per se, in which a percutaneous inflatable balloon tamp (IBT) is used to elevate the end-plates of the collapsed vertebral body, thereby allowing for superior vertebral deformity correction (11,24,33,41,44,46). Although it appears that the magnitude of deformity correction does not significantly correlate with early symptomatic alleviation, many clinicians remain concerned about this difference in radiographic outcomes between the 2 procedures and the potential resultant clinical impact in the long-term (27,37,40). It has been suggested that correction of existing kyphotic deformity in the elderly patients with osteoporotic VCFs may have overwhelmingly theoretical benefits of decreasing disability, morbidity, or risk of subsequent VCFs (16,17,29). Logically, kyphoplasty therefore may result in more advantageous long-term clinical outcomes than vertebroplasty, as

favorable deformity reduction following this procedure will contribute to further decrease the incidence of adverse events associated with spinal kyphosis. However, currently, there are few reports prospectively comparing the 2-year follow-up outcomes of the two procedures. Therefore, we designed a prospective study to compare the 2-year clinical and radiographic outcomes of kyphoplasty and vertebroplasty in the treatment of painful osteoporotic VCFs, and to investigate if either of kyphoplasty or vertebroplasty provides a better treatment outcome than the other procedure.

## MATERIALS AND METHODS

From February 2009 and April 2011, a total of 112 patients with a single-level osteoporotic VCF who did not respond to conservative therapy were included in the study. The criterion for inclusion was a poor response to conservative treatment over at least 4-week period. The fracture was mainly confirmed by correlating the physical findings with marrow signal changes on Magnetic Resonance Imaging (MRI), such as hypointense signal on T1-weighted images, hyperintense signal on T2-weighted images, and short tau inversion recovery sequence. Bone scan and computerized tomography (CT) were used in patients medically unable to undergo MRI. Increased vertebral-body uptake on bone scan indicated high bone turnover. CT was used to help distinguish fracture from tumors or infection. Exclusion criteria included a pathologic fracture due to metastasis or myeloma, active infection, uncorrected therapeutic anticoagulation, neurological complications, osteoporotic vertebral collapse of greater than 90%, destruction of posterior wall or major retropulsion of bony fragments into the spinal canal. We decided to exclude from this study the data from patients whose fractured vertebrae had a fracture age dated more than 3 months because previous studies have noted a potential influence of fracture age on vertebral fracture reduction (11,24). Patients were divided according to the surgeon who they had been referred to. Each senior spine surgeon exclusively performed one type of procedure at our institution. Consequently, initially, the study population consisted of 60 patients in the kyphoplasty group and 52 patients in the vertebroplasty group. Our institutional review board approved the present study, and all patients provided informed consent.

All vertebroplasty and kyphoplasty procedures were performed under general anesthesia in the operating theater, and patients were positioned prone on the radiolu-

cent table with the spine extended by chest and pelvic bolsters. Simultaneous biplane fluoroscopy was used throughout the procedure. The surgical techniques for vertebroplasty and kyphoplasty were carried out as previously described (11,18). Briefly, vertebroplasty was accomplished through a transpedicular or extrapedicular approach to the vertebral body using an 11- to 13-gauge needle. Bone cement was injected under continuous fluoroscopy. Kyphoplasty involved inserting Inflatable Bone Tamps bilaterally into the fractured vertebral body. The IBTs were inflated until vertebral body height was restored, the IBT contacted a vertebral body cortical wall, the IBT reached 300 psi, or the maximal balloon volume was reached. Then, the balloons were deflated and withdrawn, and the resulting intravertebral cavity was filled with BMMA bone cement. After surgery, all patients were evaluated by a medical osteoporosis specialist who monitored their pharmacologic anti-osteoporosis treatment.

Clinical evaluation was made on the improvement of back pain and disability. The intensity of back pain was measured with a 10-point visual analog scale (VAS) commencing preoperatively, and continuing postoperatively on the first day, at 3, 6, 12 and 24 months. The disability was assessed by means of the Oswestry Disability Index (ODI) before surgery and at 3, 6, 12 and 24 months after surgery. Additionally, intraoperative and postoperative complications were recorded. At latest follow-up, patients independently completed a questionnaire to determine how satisfied they were with the procedure. Each patient was asked to rate this outcome as: very satisfaction, satisfaction, fair, or dissatisfaction.

Radiographic evaluation included change of vertebral body height and kyphotic angle of the spine lateral view taken before surgery, at the time of discharge and postoperatively at 3, 6, 12 and 24 months. The method of height measurement recommended by McKiernan was chosen (30). Briefly, standard 6-point, semi-quantitative vertebral body height measurements (anterior, Ha; midline, Hm; and posterior, Hp) were obtained from lateral radiographs before and after surgery for fractured and the nearest nonfractured vertebra. The normal height of the fractured vertebra was estimated from the measurements of the adjacent nonfractured referent vertebra. Thus, fractured heights were expressed as fractions of the adjacent normal referent vertebral height: (fractured vertebral height/ adjacent normal referent vertebral height)  $\times$  100. The vertebral kyphotic angle measurement was taken from the superior and inferior endplates of the fractured vertebra, and the correlation between change of kyphotic angle and clinical result was analyzed. Intraoperative

fluoroscopic and postoperative radiographic images were used to monitor cement leakage from all treated vertebral levels. New VCFs occurring after initial intervention were identified based on changes from baseline imaging data. A vertebral height reduction of 10% or more compared with the initial vertebral height of the next adjacent normal vertebrae was defined as a new vertebral fracture.

All of radiographic analyses were performed using the measurement software. The digitization precision error was calculated for each dimension kypotic angle, Ha, Hm, and Hp by measurement of 15 randomly selected fractured and nonfractured osteoporotic vertebrae and expressed as percent coefficient of variation (CV) and standard deviation (SD).

Continuous data were expressed as means  $\pm$  standard deviation. Analyses of continuous variables were performed with the independent Student t test, the paired Student's t test, Mann-Whitney U test, and Spearman rank correlation. Categorical data are presented as percentages and were analyzed with the  $\chi^2$  test or the Fisher exact tests. SPSS version 13.0 software was used for the statistical analysis. A P value of less than 0.05 was considered significant.

## RESULTS

Of the 112 patients, 26 (23.2%) were lost before completing 2-year follow-up and were excluded from this study. This involved 18 cases (16.1%) died of causes unrelated to the procedure; 8 (7.1%) could not be contacted for additional evaluation because of changes in address or telephone number. The remaining 86 patients (76.8%) who could be followed up regularly comprised the patient cohort in this study. They consisted of 44 patients (73.3%) in the kyphoplasty group and 42 (80.8%) in the vertebroplasty group ( $P = 0.737$ ). Baseline characteristics were presented in Table I. Patients age ( $P = 0.042$ ) and fracture age ( $P = 0.016$ ) were over-represented in the kyphoplasty group, but no significant difference was observed between the 2 groups with respect to gender, location of the fractured vertebrae, height loss, VAS and ODI scores.

The graph of VAS pain score was shown in Figure 1A. All patients in both groups had significantly less pain after surgery compared with their preoperative scores, and the pain relief was better maintained for 2 years. The preoperative average VAS score was  $7.6 \pm 1.2$  (range, 5-10) in the kyphoplasty

Table I. — The baseline characteristics of the study population

	Kyphoplasty	Vertebroplasty	P ( <i>t</i> test)
No. patients	44	42	
Patient age (yr) [mean $\pm$ SD (range)]	75.6 $\pm$ 8.2 (65-89)	72.1 $\pm$ 7.9 (60-88)	0.042
Gender [No. (%)]			
Male	8 (18.2)	9 (21.4)	
Female	36 (81.8)	33 (78.6)	
Age of fracture* (day) [mean $\pm$ SD (range)]	45.2 $\pm$ 17.6 (5-81)	32.5 $\pm$ 12.3 (7-74)	0.016
Location of the fractured vertebrae [No. (%)]			
Thoracic (T6 to T9)	7 (15.9)	6 (14.3)	
Thoracolumbar (T10 to L2)	26 (59.1)	23 (54.7)	
Lumber (L3 to L5)	11 (25.0)	13 (31.0)	
Height loss [No. (%)]			
$\geq$ 30%	13 (29.5)	14 (33.3)	
$\geq$ 50%	22 (50.0)	20 (47.6)	
70% to 90%	9 (20.5)	8 (19.1)	
Pain VAS [mean $\pm$ SD (range)]	7.6 $\pm$ 1.2 (5-10)	8.1 $\pm$ 1.3 (6-10)	0.33
Oswestry disability index [mean $\pm$ SD (range)]	66.2 $\pm$ 12.9 (50-82)	68.5 $\pm$ 13.2 (52-88)	0.28

\* Age of fracture was the time between the onset of pain and surgery.

group and  $8.1 \pm 1.3$  (range, 6-10) in the vertebroplasty group. At final follow-up, the average VAS score decreased to  $2.8 \pm 0.8$  (range, 1-4) in the kyphoplasty group and  $2.7 \pm 1.0$  (range, 1-4) in the vertebroplasty group. There were no statistically significant differences ( $P < 0.05$ ) when comparing the VAS scores between the 2 groups at all follow-up time intervals. No patients had increased pain unless additional, symptomatic VCFs occurred.

Results of analysis for function showed an improvement of ODI score in the postoperative periods. The average preoperative ODI score was  $66.2 \pm 12.9$  (range, 50-82) in the kyphoplasty group and  $68.5 \pm 13.2$  (range, 52-88) in the vertebroplasty group. At final follow-up, the average ODI score was  $32.2 \pm 11.6$  (range, 14-46) in the kyphoplasty group compared with  $32.9 \pm 12.1$  (range, 16-48) in the vertebroplasty group. We found no difference in ODI score between the 2 groups at any time intervals (Fig. 1B).

Digitization precision errors expressed as %CV were 6.2%, 3.6%, 3.8% and 2.3% for kyphotic angle, Ha, Hm and Hp, respectively. These correspond to SD of 0.7°, 1.5%, 1.6% and 1.2% for kyphotic

angle, Ha, Hm and Hp, respectively. All these parameters compared favorably with previously published measurement errors (41,46).

Height correction of the fractured vertebra was summarized in Table II. Compared to the preoperative vertebral heights, mean Ha, Hm, and Hp showed statistically significant increases in both groups. The height correction was preserved after surgery: there was no significant difference ( $P > 0.05$ ) between the immediately postoperative and final height measurement in both groups. However, the postoperative increase of vertebral body height in each dimension was higher in the kyphoplasty group than in the vertebroplasty group ( $P < 0.05$ ). These differences between the groups were more remarkable in measurement of Ha and Hm ( $P < 0.01$ ). At final follow-up, 36 of 44 fractured vertebrae (81.8%) in the kyphoplasty group and 20 of 42 (47.6%) in the vertebroplasty group had more than 10% restoration of height in at least one dimension measure, which was statistically significant ( $P = 0.004$ ).

Likewise, both groups showed some degrees of decrease in kyphotic angle in all postoperative

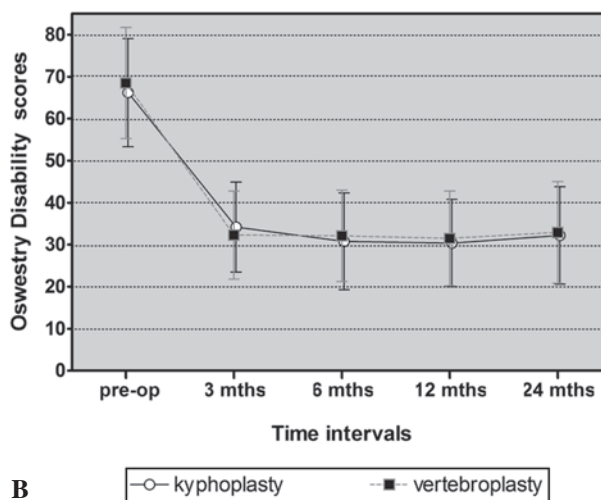
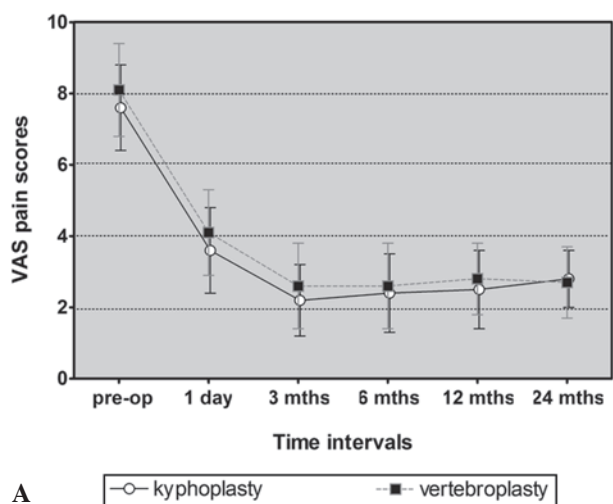


Fig. 1A, B

periods (Table III). There was a greater reduction in postoperative kyphotic angle in the kyphoplasty group than in the vertebroplasty group at every follow-up time point. At final follow-up, 34 of 44 fractured vertebrae (77.3%) in the kyphoplasty group and 22 of 42 (52.4%) in the vertebroplasty group had more than 5° reduction of kyphotic angle ( $P = 0.001$ ). However, there was no substantial correlation between change of kyphotic angle and clinical outcomes ( $P > 0.05$ ,  $P > 0.05$ ).

There were no procedure related adverse events observed in this study. Evaluation of intraoperative and postoperative radiographs revealed extravertebral cement leaks in 5 of 44 treated fractures (11.4%) in the kyphoplasty group and in 13 of 42 treated fractures (31.0%) in the vertebroplasty group ( $P = 0.011$ ). Of these 18 levels, 3 from the vertebroplasty group had cement leaks into both the adjacent vertebral disc and paravertebral tissues (Fig. 2). However, none of the cement leaks had any apparent clinical consequence.

During the 2-year follow-up, 14 patients (16.3%) suffered a new symptomatic fracture in 16 levels. This was comprised of 8 patients (18.2%), 9 levels in the kyphoplasty group and 6 patients (14.3%), 7 levels in the vertebroplasty group. Of these new fractured vertebrae, 3 levels (33.3%) in the kypo-

plasty group and 2 levels (28.6%) in the vertebroplasty group were adjacent to the vertebrae previously treated ( $P = 0.677$ ). And 2 adjacent level fractures (40%) occurred within 3 months of the initial fracture treatment. Finally, six of these 14 patients required a second operation (2 were treated by kyphoplasty and 4 by vertebroplasty), and the remaining 8 patients underwent conservative treatment.

The graph of patient satisfaction is shown in Figure 3. The majority of patients in both groups were very satisfied or satisfied with the surgery overall. At final follow-up, the satisfaction rate was 81.8% in the kyphoplasty group and 78.6% in the vertebroplasty group, respectively. Differences between the groups in terms of patient satisfaction were not statistically significant ( $P = 0.571$ ). However, it is noteworthy that two patients in each group were dissatisfied with the procedure, although the clinical results improved during the follow-up but still fall short of these patients' expectations for returning to their prefracture function.

### DISCUSSION

Kyphoplasty and vertebroplasty are elective alternatives for the treatment of painful osteoporotic



Table II. — Vertebral body Height in the Kyphoplasty and Vertebroplasty Groups (%)

	Group	Time intervals					
		preoperative	postoperative	3 months	6 months	12 months	24 months
Ha	Kyphoplasty	58.7 ± 21.2	82.3 ± 14.3*	82.7 ± 13.4*	81.9 ± 13.2*	82.6 ± 12.8*	80.7 ± 12.2*
	Vertebroplasty	56.4 ± 18.5	71.2 ± 12.5	70.6 ± 11.6	70.8 ± 13.8	70.2 ± 12.5	69.8 ± 11.2
Hm	Kyphoplasty	57.2 ± 20.5	79.1 ± 14.4\$	79.2 ± 13.2\$	78.6 ± 14.5\$	78.3 ± 13.2\$	77.5 ± 11.2\$
	Vertebroplasty	56.8 ± 17.6	68.5 ± 13.8	68.2 ± 12.1	67.1 ± 12.5	66.9 ± 13.1	66.1 ± 11.4
Hp	Kyphoplasty	78.5 ± 12.7	85.3 ± 6.5#	85.6 ± 4.5#	85.1 ± 6.2#	86.1 ± 5.1#	85.3 ± 5.7#
	Vertebroplasty	79.3 ± 11.6	82.7 ± 5.4	82.9 ± 6.2	82.4 ± 5.6	82.1 ± 4.2	81.9 ± 5.5

Values are given as mean ± SD; comparisons by means of paired t test or independent t test; Ha = anterior vertebral body height; Hm = middle vertebral body height; Hp = posterior vertebral body height; mean postoperative vertebral body height in each dimension at all time intervals increased significantly compared to the corresponding preoperative value ( $P < 0.05$ ).

\*  $P < 0.01$  for kyphoplasty vs. vertebroplasty in the measurement of anterior body height.

\$  $P < 0.01$  for kyphoplasty vs. vertebroplasty in the measurement of middle body height.

#  $P < 0.05$  for kyphoplasty vs. vertebroplasty in the measurement of posterior body height.

Table III. — Kyphotic Angle in the Kyphoplasty and Vertebroplasty Groups (°)

Group	Time intervals					
	preoperative	postoperative	3 months	6 months	12 months	24 months
Kyphoplasty	12.2 ± 6.3	6.5 ± 4.2*	6.4 ± 4.8*	6.2 ± 4.2*	6.7 ± 4.1*	6.9 ± 4.5*
Vertebroplasty	12.7 ± 7.2	8.4 ± 4.6	8.8 ± 5.2	8.7 ± 4.6	8.9 ± 3.2	9.1 ± 5.6

Values are given as mean ± SD; comparisons by means of paired t test or independent t test; mean postoperative kyphotic angle at each time interval decreased significantly compared to the corresponding preoperative value ( $P < 0.01$ ).

\*  $P < 0.05$  for kyphoplasty vs. vertebroplasty.

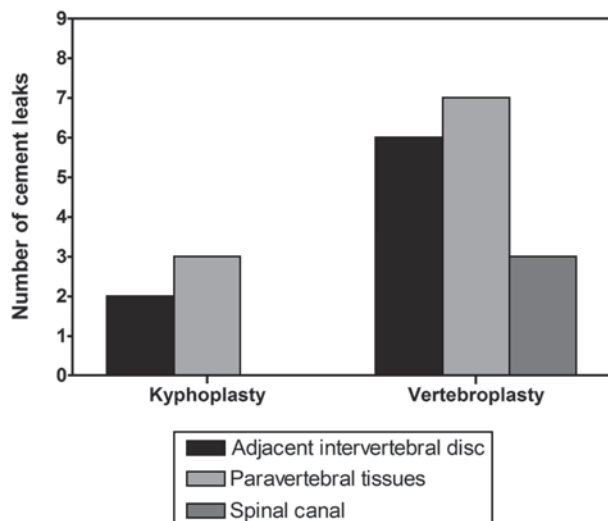


Fig. 2

VCFs. Several studies have demonstrated the benefits of these 2 procedures using validated outcome measures (1,3,4,11,13,18,20,22,24,33,44). Vertebroplasty entails the image-guided percutaneous injection of cement into a fractured vertebra to alleviate pain and stabilize the fracture. Kyphoplasty is introduced to address some disadvantages of vertebroplasty by percutaneous expansion of an IBT to effect fracture reduction before cement deposition in a fractured vertebra. Height restoration with resultant kyphosis correction is touted as the most important point that differentiates this technique from vertebroplasty. Therefore, kyphoplasty has been considered more advantageous in the management of osteoporotic VCFs than vertebroplasty (11,33,44).

However, despite higher degree of height restoration or kyphotic angle reduction, many investigators have described that early clinical results of kyphoplasty were not superior to those of vertebroplasty (8,27,28,37,40), and that vertebroplasty is a more

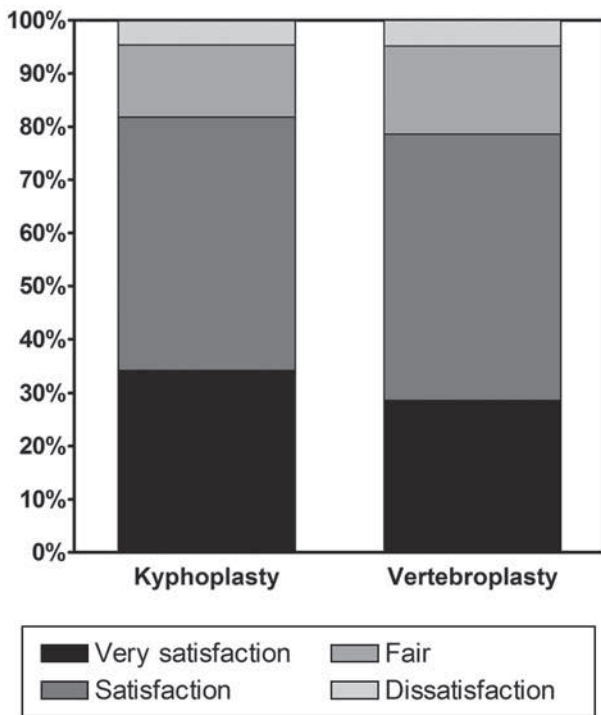


Fig. 3

rapid procedure with a lower cost. In one recent clinical randomized study of 100 patients undergoing kyphoplasty or vertebroplasty treatment, Liu et al confirmed that similar improvement of clinical results were obtained for both groups during the 6-month follow-up, and therefore recommended vertebroplasty over kyphoplasty for the treatment of osteoporotic VCFs considering higher cost of the balloon tamp (27). But few studies prospectively compare the long-term outcomes of the 2 procedures, in order to clarify the potential influence of deformity correction on outcome of the cement augmentation procedure.

Grohs et al compared kyphoplasty and vertebroplasty in the treatment of 51 patients with osteoporotic VCFs at regular intervals for 2 years, looking specifically into relevant differences between the 2 procedures during the long-term follow-up (12). They found both kyphoplasty and vertebroplasty provided pain relief, but it was more pronounced for kyphoplasty at 2-year follow-up. This result was

considered attributable to marked kyphosis reduction following the kyphoplasty procedure, which led to less compensating activity of the paraspinal muscle. These findings had not been confirmed by one subsequent nonrandomized study undertaken to assess the long-lasting effects of kyphoplasty and vertebroplasty. It demonstrated no difference in back pain alleviation and functional recovery between the 2 treatment groups at a minimum of 2 year's follow-up, although favorable correction of vertebral deformity was achieved with kyphoplasty throughout the follow-up (28). However, a specific treatment algorithm in this study introduces a noticeable selection bias toward a greater number of patients who have pain for longer than 3 months in the vertebroplasty group, on the contrary, a larger number of cases with severe vertebral height loss in the kyphoplasty group, which adversely affects the statistical power.

In the present study, we describe the clinical outcomes in 2 patient cohorts with intractable back pain from one single-level osteoporotic VCF who had a less-than-satisfactory response to conservative therapy for at least 4 weeks but not more than 3 months. And patient selection criteria for each surgical treatment are identical to ensure the comparability of the 2 groups. Our results show a comparable 2-year clinical outcomes and patient satisfaction of both groups, thus suggesting that long-lasting clinical improvement are not affected by technical differences between the 2 procedures. These findings support data from previous nonrandomized studies with short-term follow-up (8,27,28,37,40).

As expected, this study proves the advantage of kyphoplasty in the correction of vertebral deformity associated with VCFs. However, it is worth noting that some patients in the vertebroplasty group can achieve considerable height restoration and kyphotic angle reduction, which is also found by other authors (5,27,28,37,40,43). The improvement observed in this group may be due to the reduction effect resulting from patient positioning or the insertion of bolsters to induce lordosis, while deformity correction following the kyphoplasty procedure is attributed to this mechanism of spontaneous reduction as well as expansion of the inserted balloon tamp. That may account for a difference in radiographic outcomes

between the groups. However, significantly different measures of kyphotic angle reduction as well as vertebral height restoration in the vertebroplasty group did not affect the overall clinical outcome and patient satisfaction in this cohort. Furthermore, the present study fails to provide evidence of an association between the correction of kyphotic angle and the clinical improvement at 2-year follow-up overall. These findings seem to contradict the previous conclusion that a consistent and significant association of vertebral deformities with adverse health outcomes (29). The possible explanation may be that such changes of local kyphotic angle following either kyphoplasty or vertebroplasty, especially for a single level procedure like our series, are poorly predictive of improvement in overall spinal alignment, which may have more important physiological effects on the consequence of patients with osteoporotic VCFs (36,43). However, a longer investigation with more participants is needed to further evaluate the clinical relevance of vertebral deformity correction during the course of kyphoplasty and vertebroplasty.

Based on indirect comparison of kyphoplasty and vertebroplasty case series, previous systematic reviews or meta-analyses showed that kyphoplasty appears to have a substantially lower incidence of cement leakage than vertebroplasty (15,23,42). The presumed differences in leakage rate were confirmed in current study, in which cement leakage occurred in 11.4% and 31% of treated levels after kyphoplasty and vertebroplasty, as seen on plain radiographs. The less frequent cement leakage with kyphoplasty is probably because this technique created a cavity which allowed for a more viscous cement to be injected under the lower pressure (48). Additionally, the expansion of the balloon tamp by compacting cancellous bone in the intravertebral cavity might also reduce the rate of cement leakage. None of the cement leaks in current study caused clinical consequences, but the significance of an asymptomatic leak remained unclear. It had been suggested that cement leaks into the adjacent intervertebral disc space affect the mechanical loading of either the disc or adjacent vertebrae, which might predispose the patient to an adjacent-level fracture (21,43). Hence, the long-term impacts of these

asymptomatic cement leaks need further research.

Several studies have reported an increased risk of adjacent level fracture after an index fracture has been augmented by either kyphoplasty or vertebroplasty (10,45), and suggest the biomechanical effect of injected PMMA cement has been postulated as one important cause of new fracture in adjacent vertebrae (2,35). However, adjacent level fracture can also reflect systematic weakening of bone in osteoporotic spine. Lindsay et al reported around 19.2% of patients with one initial VCF on baseline imaging will experience a new fracture within a year, this incidence increased to 24% if there were two or more VCFs present on the initial radiograph (25). Compared with this natural history of untreated primary osteoporotic VCFs, we did not observe an increased risk of subsequent fractures in the 2 patient cohorts during the follow-up. Moreover, only a minority of these new fractures occurred in an adjacent level (33.3% vs. 25%). These data appeared to differ from that reported by others, who found that most of the observed new fractures in patients undergoing the cement augmentation procedure occurred in vertebrae adjacent to those previously treated (10,45). We therefore believe this phenomenon may represent the natural progression of osteoporosis in this series.

There are some limitations in this study. Firstly, it is not a prospectively randomized study. Non-randomized design may not discount the selection bias and confounding in the study. However, small differences in the baseline characteristics seem to favor the vertebroplasty group, which would not explain our results. Secondly, relatively low follow-up rate affects the sample size for patients included in this study. Higher comorbidities and mortalities among this elder population limit the number of cases who can be followed for at least 2 years. That means a 10 to 15 years study period may be even more impractical. Therefore, a study with a follow-up of 2 to 5 years has been recommended for evaluating the long-lasting effects of the 2 techniques (27). Additionally, spinal kyphosis as measured by Cobb angle is not analyzed in this study, because we note the measurement of Cobb angle may have been significantly affected by a slight change in the patient's body position at the time of the lateral radiographs



taken. Others have reported similar problems when attempting to evaluate this parameter (36,43). Given similarly clinical efficacy, relative cost may be an important indicator of the more appropriate procedure. Therefore, the cost-effectiveness of kyphoplasty versus vertebroplasty needs to be investigated in future study.

## REFERENCES

1. **Álvarez L, Alcaraz M, Pérez-Higueras A et al.** Percutaneous Vertebroplasty : functional improvement in patients with osteoporotic compression fractures. *Spine* 2006 ; 31 : 1113-8.
2. **Baroud G, Nemes J, Heini P et al.** Load shift of the intervertebral disc after a vertebroplasty : a finite-element study. *Eur Spine J* 2003 ; 12 : 421-6.
3. **Barr JD, Barr MS, Lemley TJ et al.** Percutaneous vertebroplasty for pain relief and spinal stabilization. *Spine* 2000 ; 25 : 923-8.
4. **Berlemann U, Franz T, Orlor R et al.** Kyphoplasty for treatment of osteoporotic vertebral fractures : a prospective non-randomized study. *Eur Spine J* 2004 ; 13 : 496-501.
5. **Carlier RY, Gordji H, Mompoin DM et al.** Osteoporotic vertebral collapse : percutaneous vertebroplasty and local kyphosis correction. *Radiology* 2004 ; 233 : 891-8.
6. **Cockerill W, Lunt M, Silman AJ et al.** Health-related quality of life and radiographic vertebral fracture. *Osteoporos Int* 2004 ; 15 : 113-9.
7. **Cooper C, Atkinson EJ, O'Fallon WM et al.** Incidence of clinically diagnosed vertebral fractures : a population-based study in Rochester, Minnesota, 1985-1989. *J Bone Miner Res* 1992 ; 7 : 221-7.
8. **De Negri P, Tirri T, Paternoster G et al.** Treatment of painful osteoporotic or traumatic vertebral compression fractures by percutaneous vertebral augmentation procedures : a nonrandomized comparison between vertebroplasty and kyphoplasty. *Clin J Pain* 2007 ; 23 : 425-30.
9. **Frankel BM, Monroe T, Wang C et al.** Percutaneous vertebral augmentation : an elevation in adjacent-level fracture risk in kyphoplasty as compared with vertebroplasty. *Spine J* 2007 ; 7 : 575-82.
10. **Fribourg D, Tang C, Sra P et al.** Incidence of subsequent vertebral fracture after kyphoplasty. *Spine* 2004 ; 29 : 2270-6.
11. **Garfin SR, Yuan HA, Reiley MA.** New technologies in spine : Kyphoplasty and vertebroplasty for the treatment of painful osteoporotic compression fractures. *Spine* 2001 ; 26 : 1511-5.
12. **Grohs JG, Matzner M, Trieb K et al.** Minimal invasive stabilization of osteoporotic vertebral fractures : a prospective nonrandomized comparison of vertebroplasty and balloon kyphoplasty. *J Spinal Disord Tech* 2005 ; 18 : 238-42.
13. **Heini PF, Wälchli B, Berlemann U.** Percutaneous transpedicular vertebroplasty with PMMA : operative technique and early results. A prospective study for the treatment of osteoporotic compression fractures. *Eur Spine J* 2000 ; 9 : 445-50.
14. **Hiwatashi A, Westesson PL, Yoshiura T et al.** Kyphoplasty and vertebroplasty produce the same degree of height restoration. *AJNR Am J Neuroradiol* 2009 ; 30 : 669-73.
15. **Hulme PA, Krebs J, Ferguson SJ et al.** Vertebroplasty and kyphoplasty : a systematic review of 69 clinical studies. *Spine* 2006 ; 31 : 1983-2001.
16. **Ismail AA, Cooper C, Felsenberg D et al.** Number and type of vertebral deformities : Epidemiological characteristics and relation to back pain and height loss. European Vertebral Osteoporosis Study Group. *Osteoporos Int* 1999 ; 9 : 206-13.
17. **Ismail AA, O'Neill TW, Cooper C et al.** Mortality associated with vertebral deformity in men and women : Results from the European Prospective Osteoporosis Study (EPOS). *Osteoporos Int* 1998 ; 8 : 291-7.
18. **Jensen ME, Evans AJ, Mathis JM et al.** Percutaneous polymethylmethacrylate vertebroplasty in the treatment of osteoporotic vertebral body compression fractures : technical aspects. *Am J Neuroradiol* 1997 ; 18 : 1897-904.
19. **Kado DM, Browner WS, Palermo L et al.** Vertebral fractures and mortality in older women : a prospective study. *Arch Intern Med* 1999 ; 159 : 1215-20.
20. **Kasperk C, Hillmeier J, Nöldge G et al.** Treatment of painful vertebral fractures by kyphoplasty in patients with primary osteoporosis : a prospective nonrandomized controlled study. *J Bone Miner Res* 2005 ; 20 : 604-12.
21. **Komemushi A, Tanigawa N, Kariya S et al.** Percutaneous vertebroplasty for osteoporotic compression fracture : multivariate study of predictors of new vertebral body fracture. *Cardiovasc Intervent Radiol* 2006 ; 29 : 580-5.
22. **Ledlie JT, Renfro MB.** Kyphoplasty treatment of vertebral fractures : 2-year outcomes show sustained benefits. *Spine* 2006 ; 31 : 57-64.
23. **Lee MJ, Dumonski M, Cahill P et al.** Percutaneous treatment of vertebral compression fractures : a meta-analysis of complications. *Spine* 2009 ; 34 : 1228-32.
24. **Lieberman IH, Dudeney S, Reinhardt MK et al.** Initial outcome and efficacy of "kyphoplasty" in the treatment of painful osteoporotic vertebral compression fractures. *Spine* 2001 ; 26 : 1631-8.
25. **Lindsay R, Silverman SL, Cooper C et al.** Risk of new vertebral fracture in the year following a fracture. *JAMA* 2001 ; 285 : 319-23.
26. **Lin EP, Ekholm S, Hiwatashi A et al.** Vertebroplasty : cement leakage into the disc increases the risk of new fracture of adjacent vertebral body. *AJNR Am J Neuroradiol* 2004 ; 25 : 175-80.
27. **Liu JT, Liao WJ, Tan WC et al.** Balloon kyphoplasty versus vertebroplasty for treatment of osteoporotic vertebral compression fracture : a prospective, comparative, and

- randomized clinical study. *Osteoporos Int* 2010 ; 21 : 359-64.
28. **Lovi A, Teli M, Ortolina A et al.** Vertebroplasty and kyphoplasty : complementary techniques for the treatment of painful osteoporotic vertebral compression fractures. A prospective non-randomised study on 154 patients. *Eur Spine J* 2009 ; 18 (Suppl 1) : 95-101.
  29. **Matthis C, Weber U, O'Neill TW et al.** Health impact associated with vertebral deformities : Results from the European Vertebral Osteoporosis Study (EVOS). *Osteoporos Int* 1998 ; 8 : 364-72.
  30. **McKiernan F, Jensen R, Faciszewski T et al.** The dynamic mobility of vertebral compression fractures. *J Bone Miner Res* 2003 ; 18 : 24-9.
  31. **Nevitt MC, Ettinger B, Black DM et al.** The association of radiographically detected vertebral fractures with back pain and function : a prospective study. *Ann Intern Med* 1998 ; 128 : 793-800.
  32. **Oleksik A, Lips P, Dawson A et al.** Health-related quality of life in postmenopausal women with low BMD with or without prevalent vertebral fractures. *J Bone Miner Res* 2000 ; 15 : 1384-92.
  33. **Phillips FM, Ho E, Campbell-Hupp M et al.** Early radiographic and clinical results of balloon kyphoplasty for the treatment of osteoporotic vertebral compression fractures. *Spine* 2003 ; 28 : 2260-5.
  34. **Phillips FM.** Minimally invasive treatments of osteoporotic vertebral compression fractures. *Spine* 2003 ; 28 (15 Suppl) : S45-S53.
  35. **Polikeit A, Nolte LP, Ferguson SJ.** The effect of cement augmentation on the load transfer in an osteoporotic functional spinal unit : finite-element analysis. *Spine* 2003 ; 28 : 991-6.
  36. **Pradhan BB, Bae HW, Kropf MA et al.** Kyphoplasty reduction of osteoporotic vertebral compression fractures : correction of local kyphosis versus overall sagittal alignment. *Spine*, 2006 ; 31 : 435-41.
  37. **Rölinghoff M, Siewe J, Zarghooni K et al.** Effectiveness, security and height restoration on fresh compression fractures : a comparative prospective study of vertebroplasty and kyphoplasty. *Minim Invas Neurosurg* 2009 ; 52 : 233-7.
  38. **Rousing R, Andersen MO, Jespersen, SM et al.** Percutaneous vertebroplasty compared to conservative treatment in patients with painful acute or subacute osteoporotic vertebral fractures : three-months follow-up in a clinical randomized study. *Spine* 2009 ; 34 : 1349-54.
  39. **Rousing R, Hansen KL, Andersen MO et al.** Twelve-months follow-up in forty-nine patients with acute/semi-acute osteoporotic vertebral fractures treated conservatively or with percutaneous vertebroplasty : a clinical randomized study. *Spine* 2010 ; 35 : 478-82.
  40. **Schofer MD, Efe T, Timmesfeld N et al.** Comparison of kyphoplasty and vertebroplasty in the treatment of fresh vertebral compression fractures. *Arch Orthop Trauma Surg* 2009 ; 129 : 1391-9.
  41. **Shindle MK, Gardner MJ, Koob J et al.** Vertebral height restoration in osteoporotic compression fractures : kyphoplasty balloon tamp is superior to postural correction alone. *Osteoporos Int* 2006 ; 17 : 1815-9.
  42. **Taylor RS, Taylor RJ, Fritzell P.** Balloon kyphoplasty and vertebroplasty for vertebral compression fractures : a comparative systematic review of efficacy and safety. *Spine* 2006 ; 31 : 2747-55.
  43. **Teng MM, Wei CJ, Wei LC et al.** Kyphosis correction and height restoration effects of percutaneous vertebroplasty. *AJNR Am J Neuroradiol* 2003 ; 24 : 1893-900.
  44. **Theodorou DJ, Theodorou SJ, Duncan TD et al.** Percutaneous balloon kyphoplasty for the correction of spinal deformity in painful vertebral body compression fractures. *Clin Imaging* 2002 ; 26 : 1-5.
  45. **Uppin AA, Hirsch JA, Centenera LV et al.** Occurrence of new vertebral body fracture alter percutaneous vertebroplasty in patients with osteoporosis. *Radiology* 2003 ; 226 : 119-24.
  46. **Voggenreiter G.** Balloon kyphoplasty is effective in deformity correction of osteoporotic vertebral compression fractures. *Spine* 2005 ; 30 : 2806-12.
  47. **Wardlaw D, Cummings SR, Meirhaeghe JV et al.** Efficacy and safety of balloon kyphoplasty compared with non-surgical care for vertebral compression fracture (FREE) : a randomized controlled trial. *Lancet* 2009 ; 373 : 1016-24.
  48. **Weißkopf M, Ohnsorge JAK, Niethard FU.** Intravertebral pressure during vertebroplasty and balloon kyphoplasty : an in vitro study. *Spine* 2008 ; 33 : 178-82.