



Addition-subtraction osteotomy without ligamentoplasty for symptomatic trapezial dysplasia with metacarpal instability

Chul Ki GOORENS, Jean GOUBAU, Petrus VAN HOONACKER, Diederik KERCKHOVE, Bart BERGHS, Thierry SCHEERLINCK

From the Department of Orthopaedics and Traumatology, Upper Limb Unit, AZ Sint-Jan AV Brugge-Oostende, Campus Brugge and the Department of Orthopaedics and Traumatology, Universitair Ziekenhuis Brussel, Vrije Universiteit Brussel (VUB), Brussels, Belgium

Trapeziometacarpal joint pain is often associated with a dynamic adduction deformity of the thumb metacarpal, combined with radial subluxation at the base of the thumb metacarpal, due to trapeziometacarpal dysplasia.

Addition-subtraction osteotomy is a surgical option to correct the bony deformity when conservative treatment fails. Eight patients who underwent surgery with this technique were prospectively evaluated. All patients were female and mean age was 42 (range 27-59) years. Mean follow-up period was 23 (range 10-42) months postoperatively.

Seven patients (87.5%) were very satisfied. Joint mobility and strength of the operated thumb was restored to a degree comparable to the contralateral thumb. Overall function according to the Quick-DASH score improved by 75.5% and pain according to the Visual Analogue Scale decreased by 65%. Radiological evaluation showed a decrease of the trapezial slope. Mean angle between the articular surface of the trapezium and the long axis of the second metacarpal measured 142° preoperatively 129° and postoperatively.

In the present study results of addition-subtraction osteotomy without ligamentoplasty were promising, especially for function and pain. The technique may be a valuable treatment option for trapeziometacarpal dysplasia with metacarpal instability.

Keywords: trapeziometacarpal dysplasia ; metacarpal instability ; addition-subtraction osteotomy.

INTRODUCTION

Trapeziometacarpal (TM) dysplasia with metacarpal instability can evolve to a disabling condition, long before the radiological changes of osteoarthritis appear. This is characterized by pain, loss of motion and strength, and even may lead to joint deformity in the long-term. The patients are mostly young female individuals with high demands. Pain is induced by thumb to index finger pinch. When conservative treatment fails, surgery can be considered. Several techniques have been described, such

-
- Chul Ki Goorens, MD, Orthopaedic Surgeon, Fellow Hand Surgeon.
 - Jean Goubau, MD, PhD, Consultant Orthopaedic and Hand Surgeon.
 - Petrus Van Hoonacker, MD, Consultant Orthopaedic and Hand Surgeon.
 - Diederik Kerckhove, MD, Consultant Plastic and Hand Surgeon.
 - Bart Berghs, MD, Consultant Orthopaedic and Hand Surgeon.
 - Thierry Scheerlinck, MD, PhD, Consultant Orthopaedic Surgeon.

Department of Orthopaedic Surgery, AZ Sint-Jan, Brugge, Belgium and Department of Orthopaedic Surgery, University Hospital Brussels, Belgium.

Correspondence : Jean Goubau, AZ Sint Jan AV Brugge-Oostende, Campus Brugge, Ruddershove 10, 8000 Brugge.

E-mail : jean.goubau@azsintjan.be ; jean@goubau.eu

© 2013, Acta Orthopædica Belgica.

as osteotomies, ligamentoplasties, combined procedures of osteotomies and ligamentoplasties, joint replacements and arthrodesis (5,7). We believe it is necessary to correct the bony anatomy, since the fundamental problem has a bony origin.

Adduction deformity of the thumb and trapezial dysplasia are characterized by an increased articular slope of the trapezium and narrowing of the first intermetacarpal space (3). This can be demonstrated by the “dévers” angle or trapezial tilt angle described by Kapandji. This angle is measured between the axis of the second metacarpal and the slope of the trapezium (normal : 129° , range : 6°) (11). The addition-subtraction osteotomy, first presented by Goubau *et al* in 2007 (7), combines two techniques : an abduction osteotomy of the first metacarpal to correct the axis of the first metacarpal and an opening wedge osteotomy of the trapezium to reorientate the trapezial saddle with a more normal slope (Fig. 1). The combination of both techniques restores the anatomy and centres the forces acting across the joint, which results in restoration of an acceptable level of mobility, force, and stability of the thumb column (5,7). The limit of the angular correction is the size of the short side of the wedge taken from the base of the thumb metacarpal, usually between 3 and 4 mm. The wedge should not exceed 5 mm to avoid an overcorrection deformity of the axis of the first metacarpal. A 5 mm wedge corresponds with a metacarpal correction of 20 to 30 degrees (23,24). By combining both osteotomies, donor site morbidity after harvesting a bone graft is avoided as the removed bone wedge of the first metacarpal is placed into the osteotomy of the trapezium. Finally, this technique preserves the TM joint, allowing other techniques to be used if painful arthritis should develop in the middle or long-term (5,7). A stabilizing ligamentoplasty with a flexor carpi radialis (FCR) tendon slip was initially added to the procedure as a secondary stabilizer (5,7).

We hypothesize that in cases with an increased trapezial slope and moderate dynamic instability of the base of the thumb metacarpal at Eaton stress testing (12), the combined osteotomy in the first metacarpal and trapezium provides enough stability, making the ligamentoplasty superfluous. We report the results of a prospective single-center study

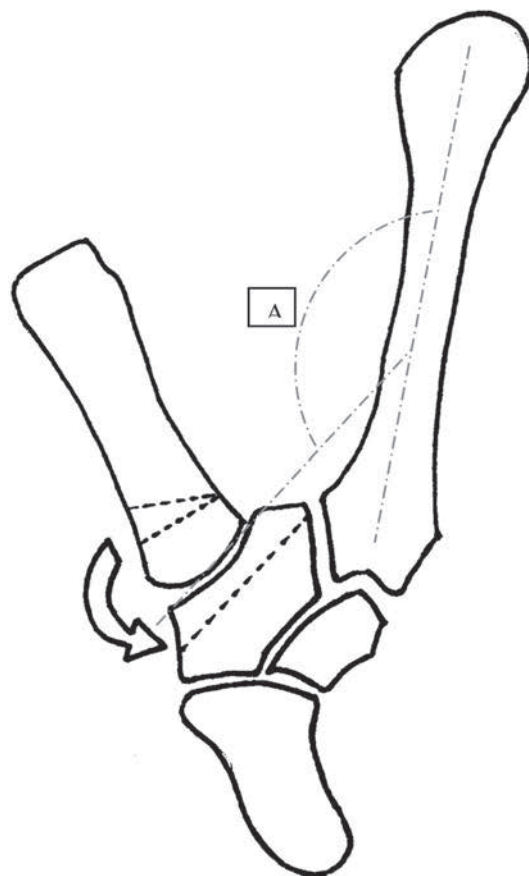


Fig. 1. — Overview of the addition-subtraction osteotomy technique : closing wedge extension osteotomy of the first metacarpal (subtraction) and opening wedge osteotomy of the trapezium (addition). The “dévers” (A) angle is measured between the axis of the second metacarpal and the slope of the trapezium. (Reproduced with permission from : Goubau JF, Ackerman P, Kerckhove D, Van Hoonacker P, Berghs B. Addition-subtraction osteotomy with ligamentoplasty for symptomatic trapezial dysplasia with metacarpal instability. *J Hand Surg* 2012 ; 37-E :138-144).

of 8 consecutive cases of addition-subtraction osteotomy without ligamentoplasty.

MATERIALS AND METHODS

Eight patients were treated for an isolated TM dysplasia with metacarpal instability between 2008 and 2011. They were all operated on by the same experienced hand surgeons (JFG, PVH). Preoperatively, all patients complained of pain at rest and during activities, despite conservative treatment which consisted of night splinting,

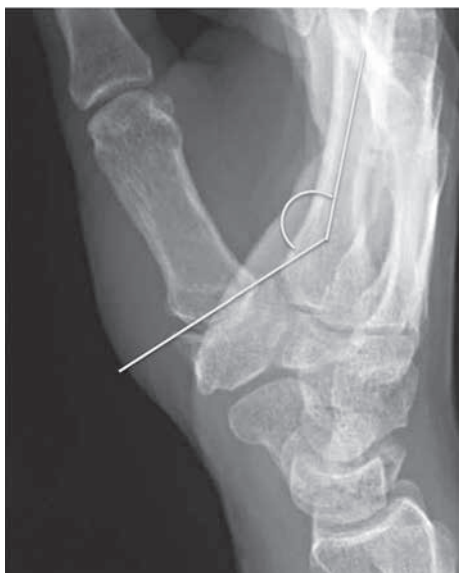

Fig. 2. — Preoperative frontal view of the TM joint with an increased “dévers” angle.

nonsteroidal anti-inflammatory medication and paracetamol.

The radiographic evaluation included frontal and lateral views of the TM joint as described by Kapandji, a straight view of the scaphotrapezoid joint and Eaton views without and with stressing (2,11,24). The indications for surgery were symptomatic instability of the TM joint due to dysplasia of the trapezium with an increased trapezoid slope and secondary instability of the base of the thumb metacarpal and a well preserved joint space on the radiographs (Fig. 2) (11). Instability was described as a non-centered metacarpal base in the trapezoid saddle during radial stressing on the Eaton views. No concomitant scaphotrapezoid arthropathy was noted.

One month prior to the osteotomy, a TM joint arthroscopy was performed for diagnostic purposes in all patients. Signs of synovitis were present and a well-defined deep cartilage lesion in the anteroradial part of the articular surface of the trapezium was in contact with a posteroulnar cartilage lesion on the articular surface of the base of the first metacarpal.

Surgical technique

Patients were hospitalized and the procedure was performed under locoregional anaesthesia with plexus block. The TM joint was exposed by a proximally extended anterolateral Gedda and Moberg incision. This incision provides excellent visualisation of the TM joint and pre-

serves the dorsal vascularisation and ligamentous stability of the saddle joint (4,6,10). The tendon slip of the abductor pollicis longus (APL) to the opponens was disinserted. The opponens and APL origin were dissected from the anterior side of the TM joint and the FCR tendon was localized on the ulnar side of the trapezium. The periosteum of the proximal third of the thumb metacarpal was removed. Attention was paid to preserve the integrity of the articular capsule of the TM joint. The osteotomy level was determined with guidance of the image intensifier. Care was taken to perform this osteotomy in the metaphyseal region to enhance rapid consolidation. An osteotomy parallel to the articular surface was made approximately 8 mm distally of the TM joint with a small oscillating saw. To facilitate this, a needle was inserted into the joint parallel to the base of the thumb metacarpal. Care was taken not to cut the whole diameter of the metaphysis. The distal level of the osteotomy was determined by making an inclined cut producing a wedge with its base on the radial/dorsal border of the thumb metacarpal, which is slightly larger dorsally and radially to create an antepulsion effect. The size of the base of the wedge was calculated by measuring the amount of slope of the trapezium that had to be corrected. The size of the wedge should not exceed 4 to 5 mm at its base, and should have an apical angle between 15° and 25°. Ideally, an ulnar hinge is preserved to create a stable closure of the osteotomy after removal of the wedge. Both surfaces were firmly pressed against each other and maintained with a memory staple (Easyclip®, Memometal - Stryker, Kalamazoo, Minnesota, USA). When the hinge could not be preserved, an additional 1.2 mm K-wire was added across the osteotomy to avoid anterior translation of the distal fragment. The position was verified under image intensifier.

The middle of the waist of the body of the trapezium in a frontal view was located with the use of an image intensifier. A needle can be inserted into the scaphotrapezoid-trapezium space and TM joint to allow better localization of the level of the osteotomy. Under image intensifier guidance, the osteotomy was made with an oscillating saw parallel to the articular surface of the trapezium, using the intra-articular needle as a guide. When 70% of the width of the trapezium had been cut, a thin chisel of 1 cm width was inserted to finish the osteotomy, which allowed preservation of an ulnar hinge. Attention should be paid not to lacerate the FCR tendon. The osteotomy through the trapezium was opened by hinging the almost completely inserted chisel on the ulnar fulcrum. The resected metacarpal wedge was inserted along this chisel into the gap and held in place in press-fit

after removal of the chisel. Care was taken to position the base of the wedge flush with the radial border of the trapezium. No osteosynthesis was necessary at the level of the trapezium, since the compression is done naturally by the hinge in a press-fit fashion. The capsule was closed with Vicryl® 1 sutures and the APL slip was reattached at its original location with Vicryl® 1 sutures. The incised skin was closed with Ethylon® 5.0 sutures over a suction drain. The hand was embedded in a fluffy bandage and a forearm plaster cast, including the thumb.

Postoperative Care

The suction drain was removed 24 hours after surgery. A forearm plaster cast, including the thumb, was applied for six weeks. A thumb splint was kept for another three weeks at night. Automobilisation was possible after six weeks, interdiction of forceful gripping had to be respected for three months. Patients were seen consecutively the day after the operation, two weeks, four weeks, six weeks, three months and yearly after the operation, with regular radiological exams. Postoperative radiographs were frontal and profile views as described by Kapandji and Eaton with and without stressing in radial deviation, permitting a dynamic evaluation of instability (2,12).

Assessment

Patients were assessed preoperatively and with a minimum follow-up of 10 months postoperatively for mobility, strength, function and pain. Satisfaction, external appearance and radiographical evaluation were determined only postoperatively. All results were collected by the first author (CKG).

The mobility of the thumb in opposition (0-10) and retropulsion (0-3) was graded as described by Kapandji (10). The opening of the first web space and the metacarpophalangeal (MP) mobility in flexion and extension were also graded. Strength was measured using a calibrated hydraulic pinch gauge and a calibrated hydraulic hand dynamometer (Baseline Fabrication Enterprises Inc., New York, USA). Function was assessed by the QuickDASH score (8). Pain was scored with the 0-10 visual analogue scale (VAS) (0 = no pain, 10 = severe pain). Radiographical outcome was determined on the frontal view described by Kapandji where the two sesamoids are projected next to each other behind the first metacarpal. This incidence was chosen to compare the preoperative and postoperative angle between the trapezial articular surface and the long axis of the second metacarpal (12,13).

Results of the osteotomy were compared with the preoperative status and with the contralateral non-operated thumb. The Wilcoxon signed-rank test was used to determine statistical differences ($p < 0.05$).

RESULTS

Eleven patients were treated with the addition-subtraction osteotomy without ligamentoplasty.

Three patients were lost to follow-up. Eight patients were available for evaluation: all were female, with a mean age of 42 (range: 27-59) years. Surgery was done in seven dominant hands and in one non-dominant hand. The mean follow-up period was 23 (range 10-42) months postoperatively.

The results are shown in Table I. Several measured parameters revealed significant improvements postoperatively compared to the preoperative situation. The QuickDASH score improved by 75.5%. Pain according to the VAS score decreased by 65%. The radiological evaluation showed a decrease of the trapezial slope. The mean angle between the articular surface of the trapezium and the second metacarpal measured 142° preoperatively and 129° postoperatively (Fig. 3 & 4). These differences were statistically significant ($p < 0.05$). Joint mobility and strength of the operated thumb were restored to a degree comparable to the contralateral non-operated thumb.

Restoration of strength and mobility to a useful functional level occurred generally after a period of three months. All patients were satisfied with the appearance of the scar. Seven patients (87.5%) were subjectively satisfied or highly satisfied and reported no spontaneous complaints at the moment of questioning. They all would have the operation again. Only one patient hesitated, due to an increased postoperative stiffness which might be partially caused by progression of osteoarthritis. This had a repercussion on daily activities, although she experienced a decrease of pain after the operation. Another patient suffered from impingement symptoms due to osteophyte formation. After arthroscopic osteophyte resection and debridement of synovitis, complaints disappeared. No complex regional pain syndrome, dysaesthesia or apprehension for forceful gripping were noted in our series.

Table I. — Results

	Mean				Range		
	Preop (SD)	Postop (SD)	Improvement Post- vs preop	Postop vs contralateral (SD)	Preop	Postop	Postop contralateral
Opening 1st web (°)	–	68 (21)	–	66 (29)	–	40-90	32-90
Opposition	9 (1)	9 (1)	0%	9 (3)	9-10	9-10	9-10
Retropulsion	2 (1)	2 (1)	0%	2 (1)	1-3	1-2	1-3
MP flexion (°)	–	53 (12)	–	53 (21)	–	35-70	40-68
MP extension (°)	–	-3 (5)	–	-4 (5)	–	-20-0	-10-0
Key pinch (kg)	4.4 (2.1)	5.2 (1.7)	18.1%	6 (2.8)	2.5-8	4-8	3-10
Precision pinch (kg)	3.4 (1.6)	3.4 (1.5)	0%	3.9 (2.3)	2.5-6	1-6	1-7
Grip strength (kg)	24.4 (6.5)	26.9 (8.7)	10.2%	26.5 (11.9)	14-36	12-46	20-50
QuickDASH	53 (19)	13 (SD 19)	75.5%	–	21-82	0-52	–
VAS	7 (3)	2 (2)	65%	–	7-9	0-5	–
Dévers angle (°)	142 (50)	129 (43)	9.2%	–	135-153	124-135	–

$p < 0.05$.

DISCUSSION

The period of time between the onset of symptoms of TM instability and eventual irreversible degenerative changes can last for many years. Particularly useful for diagnostic purpose, is the TM joint arthroscopy which can allow detection of any articular changes long before they would be noted with routine radiographs (1).

Since the conservative treatment is usually sufficient, it is particularly difficult to collect large patient series, reporting on a particular type of osteotomy, which was also the case in the present study.

Techniques that are applicable for arthritic TM joints such as fusion or prosthetic replacement may not be indicated in painful unstable dysplastic joints with preserved cartilage in young patients. These joints have a significant dysplasia of the trapezium with a hypoplastic lateral rim, causing instability and subluxation at the base of the thumb metacarpal. This laxity is due to the elongation of the anterior oblique superficial and deep ligaments, which causes progressive pain with repetitive mechanical load. This mechanism progressively damages parts of the articular surface of the joint (1,18,22,23).

Metacarpal osteotomies have been reported as a treatment for early stage TM joint arthritis. Extension osteotomy of the thumb compensates for the

incompetence of the anterior oblique ligament and reduces the laxity in the dorsal-palmar direction. Extension osteotomy of 30° gave good results in terms of pain relief and improved grip and pinch strength (1,16,20,22). However, extension osteotomy alone does not address the increased trapezial slope (5). Combined osteotomies of trapezium and thumb metacarpal have been proposed together with a ligamentoplasty (5,7).

In our results, the addition-subtraction osteotomy provided a high patient satisfaction rate. Range of motion, key pinch and grip strength of the operated thumb were similar to the preoperative situation and the contralateral asymptomatic thumb. This technique seems to be especially effective for reduction of pain caused by joint instability and for restoration of daily functioning. Literature confirms this clinical experience. During lateral pinch grip, the centre of force is primarily located in the dorsal region of the trapezium in the normal joint (17). A recent experimental study in cadavers revealed that a 15° opening wedge osteotomy of the trapezium reduces radial subluxation of the metacarpal on the trapezium by 64% and increases contact pressure and contact area in the ulnar-dorsal region by 76%, away from the diseased compartments of the trapezial surface (2).

There are other surgical techniques that preserve

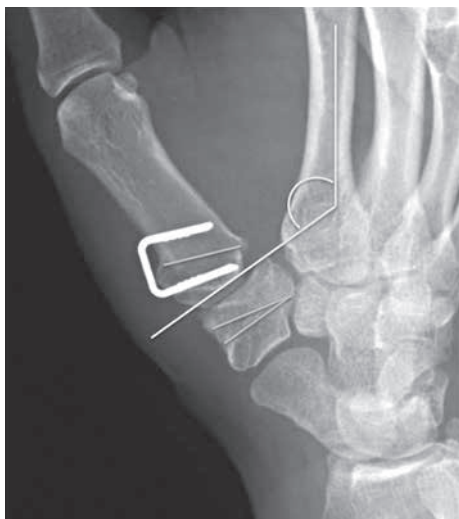

Fig. 3. — Postoperative frontal view of the TM joint with a reduced “dévers” angle.

the TM joint surfaces as the addition-subtraction osteotomy. We believe that the addition-subtraction osteotomy has less morbidity than the more complex vascularized articular osteotomies which have similar biomechanical outcomes or the trapezium opening wedge procedure, which tends to close the first web (15,17,19,21).

In this series, we have not performed the ligamentoplasty additionally to the double osteotomy, as was described in the original article (7). Our results seem to be similar to those obtained with an additional ligamentoplasty, suggesting that the ligamentoplasty is unnecessary in case of good quality of the joint. Stability is obtained, if the deformity is sufficiently corrected (5,7). This was also confirmed earlier experimentally (14). Moreover, the ligamentoplasty tends to favour stiffening of the joint, which in our opinion could be useful in case of suboptimal quality of the cartilage of the TM joint.

Possible complications of metacarpal osteotomies for TM osteoarthritis are peroperative trapezium and metacarpal fractures, dysaesthesia, de Quervain's tendinopathy and complex regional pain syndrome (8). In our series we did not have any complications. In the long term we have to be attentive for progression of arthritis and persistent instability (2,22). In our series, no episodes of remaining instability were noticed. To minimize risk of instability, special

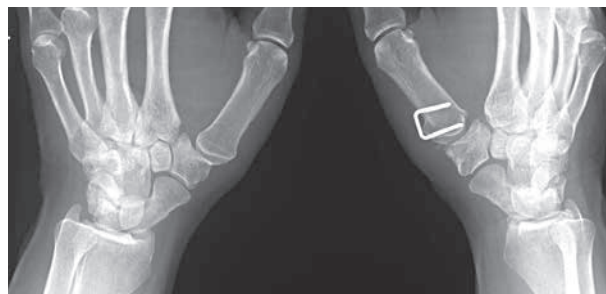

Fig. 4. — Postoperative frontal view of the TM joint of both hands.

attention should be paid on peroperative testing of primary stability and tension and meticulous preservation of the capsule. Postoperatively, careful changing of wound dressing and casting without axial traction of the thumb and prohibition of forceful gripping within a period of three months are mandatory.

We believe that our results indicate that the addition-subtraction osteotomy without ligamentoplasty can be a procedure with a high success rate to treat TM dysplasia with metacarpal instability. However, it is mandatory to be strict regarding the indication for this type of operation. Long-term prospective studies are required for further evaluation.

REFERENCES

1. **Badia A.** Trapeziometacarpal arthroscopy. A classification and treatment algorithm. *Hand Clin* 2006 ; 22 : 153-163.
2. **Cheema T, Salas C, Morrell N et al.** Opening wedge trapezium osteotomy as possible treatment for early trapeziometacarpal osteoarthritis : a biomechanical investigation of radial subluxation, contact area, and contact pressure. *J Hand Surg* 2012 ; 37-A : 699-705.
3. **Eaton RG, Littler JW.** Ligament reconstruction for the painful thumb carpometacarpal joint. *J Bone Joint Surg* 1973 ; 55-A : 1655-1666.
4. **Gedda KO, Moberg E.** Open reduction and osteosynthesis of the so-called Bennett's fracture in the carpo-metacarpal joint of the thumb. *Acta Orthop Scand* 1953 ; 22 : 249-257.
5. **Goubau JF, Ackerman P, Kerckhove D, Van Hoonacker P, Bergs B.** Addition-subtraction osteotomy with ligamentoplasty for symptomatic trapezium dysplasia with metacarpal instability. *J Hand Surg* 2012 ; 37-E : 138-144.
6. **Goubau JF, Benis S, Van Hoonacker P et al.** Vascularization of the trapeziometacarpal joint and its clinical importance : anatomical study. *Chir Main* 2012 ; 31 : 57-61.

7. **Goubau JF, Kerckhove D, Berghs B.** [Addition-subtraction osteotomy with ligamentoplasty for symptomatic trapezial dysplasia with metacarpal instability.] (in French). *Ann Chir Main* 2007 ; 26 : 26-30.
8. **Gummeson C, Ward MM, Atroshi I.** The shortened disabilities of the arm, shoulder and hand questionnaire (QuickDASH) : validity and reliability based on responses within the full-length DASH. *BMC Musculoskelet Disord* 2006 ; 7 : 44.
9. **Gwynne-Jones DP, Penny ID, Sewell SA, Hughes TH.** Basal thumb metacarpal osteotomy for trapeziometacarpal osteoarthritis. *J Orthop Surg (Hong Kong)* 2006 ; 14 : 58-63.
10. **Hagert E, Lee J, Ladd AL.** Innervation pattern of thumb trapeziometacarpal joint ligaments. *J Hand Surg* 2012 ; 37-A : 706-714.
11. **Kapandji A, Heim UFA.** [Reorientation osteotomy of the trapezial saddle.] (in French). *Ann Chir Main* 2002 ; 21 : 124-133.
12. **Kapandji TG, Kapandji AI.** [New radiologic data on the trapeziometacarpal joint. The results of 330 cases.] (in French). *Ann Chir Main* 1993 ; 4 : 263-274.
13. **Kapandji AI, Moatti E, Raab C.** [Specific radiography of the trapeziometacarpal joint and its technique.] (in French). *Ann Chir Main* 1980 ; 34 : 719-726.
14. **Koff MF, Shrivastava N, Gardner TR et al.** An in vitro analysis of ligament reconstruction or extension osteotomy on trapeziometacarpal joint stability and contact area. *J Hand Surg* 2006 ; 31-A : 429-439.
15. **Messina A.** [Vascularized surgical rotation of a bi-articular trapezoid-trapeziometacarpal complex for the treatment of severe rhizarthrosis of the thumb.] (in French). *Chir Main* 2000 ; 19 : 134-140.
16. **Parker WL, Linscheid RL, Amadio PC.** Long-term outcomes of first metacarpal extension osteotomy in the treatment of carpal-metacarpal osteoarthritis. *J Hand Surg* 2008 ; 33-A : 1737-1743.
17. **Rongièrès M.** [Anatomy and physiology of the human trapeziometacarpal joint.] (in French). *Chir Main* 2004 ; 23 : 263-269.
18. **Ropars M, Siret P, Kaila R et al.** Anatomical and radiological assessment of trapezial osteotomy for trapezial dysplasia in early trapeziometacarpal joint arthritis. *J Hand Surg* 2009 ; 34-E : 264-267.
19. **Roux JL.** [Vascularized bone transfers in the wrist and hand.] (in French). *Chir Main* 2003 ; 22 : 173-185.
20. **Roux JL.** [Trapeziometacarpal arthroplasty by rotation transfer of the trapeziometacarpal joint. Anatomical study and operative technique.] (in French). *Chir Main* 2004 ; 23 : 72-78.
21. **Shrivastava N, Koff MF, Abbot AE et al.** Simulated extension osteotomy of the thumb metacarpal reduces joint laxity in lateral pinch. *J Hand Surg* 2003 ; 28-A : 733-738.
22. **Tomaino MM.** Treatment of Eaton stage I trapeziometacarpal disease with thumb metacarpal extension osteotomy. *J Hand Surg* 2000 ; 25 : 1100-1106.
23. **Wilson JN.** Basal osteotomy of the first metacarpal in the treatment of arthritis of the carpometacarpal of the thumb. *Br J Surg* 1973 ; 60 : 854-858.
24. **Wilson JN, Bossley CJ.** Osteotomy in the treatment of osteoarthritis of the first metacarpal joint. *J Bone Joint Surg* 1983 ; 65-B : 179-181.