



Complications following kyphoplasty in unstable osteoporotic vertebral body fractures

A guide to correct fracture analysis

Hans-Heinrich TROUILLIER, Christof BIRKENMAIER, Tamara SEIDL, Volkmar JANSSON

From the Franziskus Hospital, Bielefeld, Germany

The possibilities offered by kyphoplasty in the treatment of osteoporotic vertebral fractures have been widely described. Kyphoplasty is technically not very demanding, it can be easily learned and it is minimally invasive when compared to open surgical fracture treatment. Like many other simple surgical methods, it has spread rapidly and as a consequence of the above factors combined with its good reimbursement in many countries, it has experienced a widening in the indications for which it is being employed.

The initial purpose of kyphoplasty was pain relief based on vertebral body stabilisation combined with restoration of vertebral body height. An increasingly uncritical use of the method can be observed and as a consequence, an increase in serious complications. During recent years, spinal surgery departments have received an increasing number of patients with serious complications following kyphoplasty, requiring major reconstructive spinal surgery. On the basis of 12 cases treated over the past 36 months, we aim to provide guidelines for the indications of the kyphoplasty procedure.

Keywords : vertebral body fracture ; osteoporosis ; kyphoplasty.

INTRODUCTION

In the treatment of osteoporotic vertebral body fractures, kyphoplasty represents an additional

invasive treatment option. Although it originally aimed at pain relief, its undisputed bone-stabilising effect has now become the top priority among the indications. The technique is easy to learn and as a result, the method has become rapidly accepted both in the traumatological field and beyond the confines of orthopaedic and accident surgery specialists (6,16,18). The polymethylmethacrylate (PMMA) bone cement used for the procedure is bioinert : the fractured bone will not heal directly onto the PMMA, it can only heal around it, provided that there is a sufficient volume of bone fragments around the PMMA tamp. In many cases bone healing cannot occur in the fracture region after the

■ Hans-Heinrich Trouillier, MD, Associate Professor, Chief Consultant.

■ Tamara Seidl, MD, Consultant.
Franziskus Hospital, Bielefeld, Germany.

■ Christof Birkenmaier, MD, Consultant.

■ Volkmar Jansson, MD, Professor, Director & Chairman.
Department of Orthopaedics, University of Munich, Grosshadern Campus, Germany.

Correspondence : PDDr Hans-Heinrich Trouillier, Franziskus Hospital Bielefeld, Teaching Hospital of the University of Hannover, Kiskerstrasse 26, 33615 Bielefeld, Germany.

E-mail : dr.trouillier@ws-chirurgie.com

© 2013, Acta Orthopædica Belgica.

cement has been inserted, and a biomechanically stable incorporation of the cement at the interface with bone cannot be expected either (1). If one only considers the chances for fracture healing, the stability which can be achieved in the medium term is uncertain. Consequently, only primarily stable fractures should be treated by kyphoplasty. Preoperative fracture analysis and recognition of unstable or potentially unstable vertebral body fractures is of critical importance. A particular difficulty of this fracture analysis can be seen in the A-fractures of our group of patients. B- and C-fractures are understandably easier to identify as unstable and are not primarily selected for cement augmentation.

Guidelines for the indication of a kyphoplasty procedure

Complications after kyphoplasty have now been described by many authors. What is lacking is an analysis of possible fracture types that are unsuitable for cement augmentation without an additional primary stabilization.

Re-fractures of the vertebral body originally affected

Complications are observed in the form of re-fractures of the affected vertebral bodies already treated with kyphoplasty (1,3). In the process, the base and upper plates collapse above the cement formation (Fig. 1). In many cases, the associated loss of height induces an additional fracture of the posterior cortex of the vertebral body. This can result in a displacement of bone and / or PMMA into the spinal canal. The re-fracture may occur after an adequate trauma, but in many cases also without any apparent reason. In such cases, it must be assumed that either a true vertebral body stabilization did not occur after cement application and / or that the remaining bone surrounding the PMMA tamp was progressively resorbed. Either osseous consolidation simply did not occur, or the fracture could already have been assessed to be unstable before the primary intervention. This type of unstable osteoporotic vertebral body fracture is present whenever

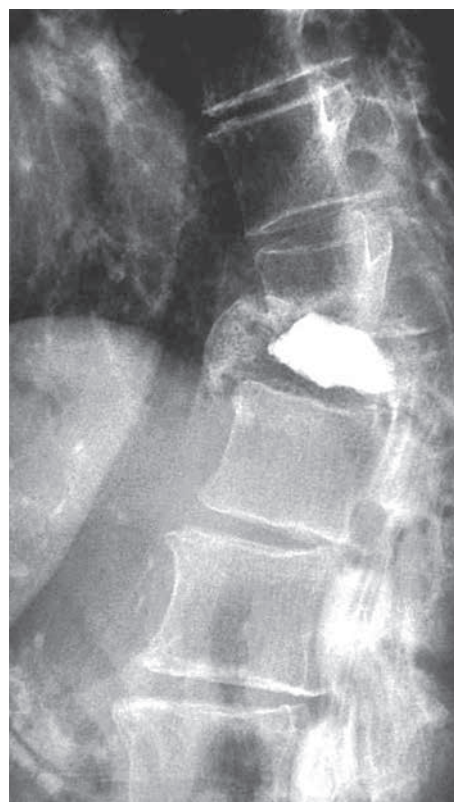

Fig. 1. — Collapse above the cement with spinal canal stenosis and neurological disorder.

- a detachment in the sense of a dissociation of an inferior and/or superior endplate from the rest of the vertebral body is present (Fig. 2) ;
- there is evidence of a pincer fracture, corresponding to an A2.3 fracture, in the posterior third of the vertebral body in the vicinity of the pedicle root (Fig. 3) ;
- the posterior vertebral cortex is involved (Fig. 4).

Osteoporotic fractures that appear to be stable primarily but can turn into unstable fractures must also be taken into account if the fracture extends close to the pedicle region. In such cases, kyphoplasty provokes a dissociation of the vertebral body from the pedicle as a result of the method. These fractures should be considered as potentially unstable (Fig. 5). When assessing an osteoporotic fracture, one must also take into account that the transition between an A1.3 fracture, so-called vertebral

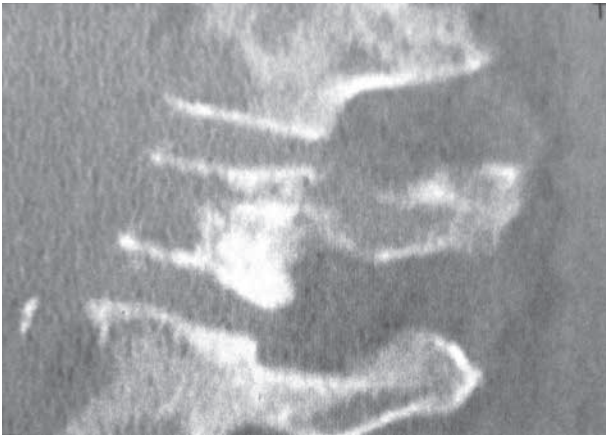


Fig. 2. — Detachment of inferior and superior endplate from the rest of vertebral body, which means, that cement application will not increase stability. Bone and cement will not be inter-locked.

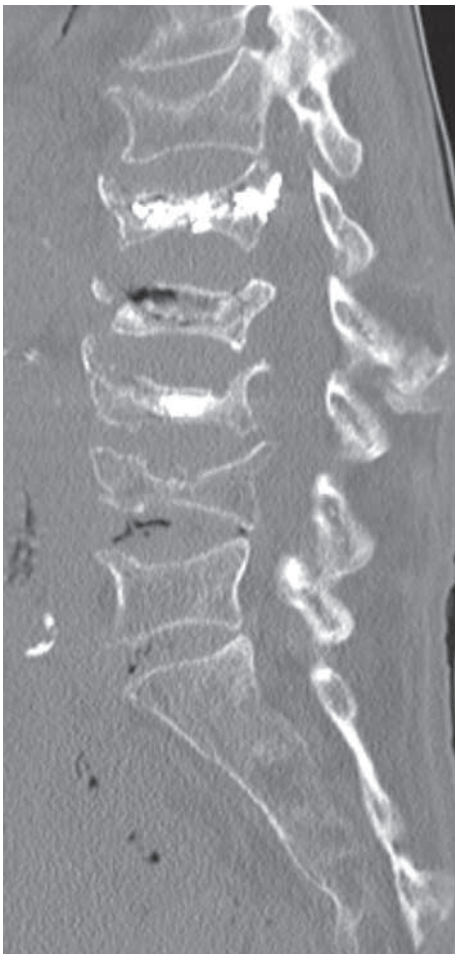

Fig. 3. — Fracture in the posterior third of the vertebral body

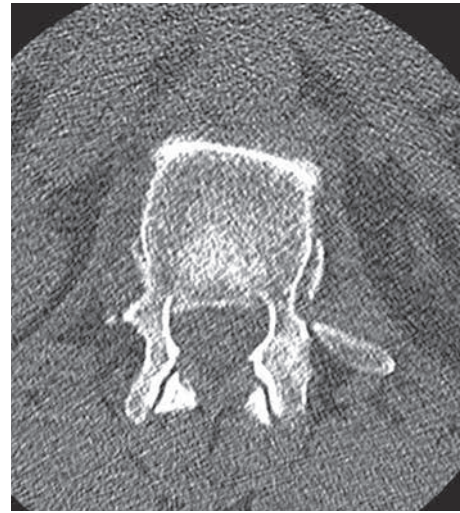

Fig. 4. — Fracture of the posterior edge of the vertebral body in the axial plane with an unstable and displaced posterior wall fragment. An obviously unstable situation.

body collapse, and the A2.2 and A2.3 fractures, i.e. coronal split fracture and pincer fracture, can be fluid.

Fractures of adjacent vertebral bodies

Fractures of the adjacent vertebral bodies (3,6,7,9) are caused by the difference in stiffness between the cement-augmented vertebral body and the untreated adjacent vertebrae. Such fractures are increasingly seen to occur at the biomechanically unfavourable thoracolumbar junction.

Patient data

Over a period of 36 months, between 2005 and 2008, 12 patients were admitted in our institutions due to staggering pain, following a kyphoplasty performed in other institutions, which had provided initial clinical improvement. The time interval between kyphoplasty and admission for disabling pain was on average 17.2 months. In addition to clinical surgical assessment, all patients were seen and examined by a specialist neurologist. The diagnostic work-up consisted of plain radiographs of the spinal segment in two planes and a CT examination of the

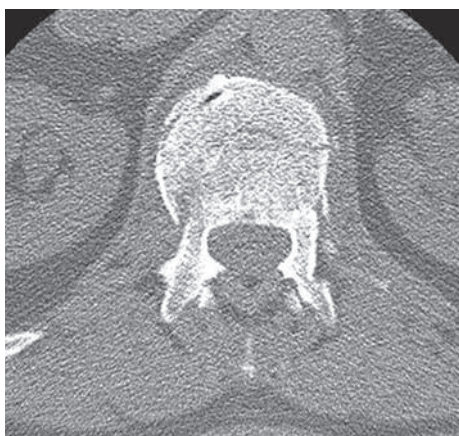

Fig. 5. — Fracture line close to the pedicle region with a stable posterior wall, also to be considered as an unstable situation if a kyphoplasty is planned.

spinal segment affected, including the adjacent segments, as these were to be included in the possible planning of instrumentation, generally 2 segments above and below the vertebral body fracture.

When the diagnostic work-up showed an unstable re-fracture in a vertebral body already treated with kyphoplasty and/or in an adjacent vertebral body, with or without spinal canal compromise, this was considered an indication for surgery.

Surgical treatment was performed on average 37 hours after admission.

In our hands the surgical treatment of the 12 patients was done in 6 cases with cement augmented fusions, in 4 cases non cemented fusions and in two corset managements.

The deterioration of the fracture type within the context of the second event regularly meant an increase in instability and in the degree of fracture quality by several levels according to the AO fracture classification. In the first incident most of the patients had A 1.2 to A 2.2 fractures, after the second incident we found 4 B – fractures (AO classification) and 5 A 3 fractures. In 8 cases multilevel fractures occurred after the second trauma incident.

After adequate bisegmental pedicular instrumentation above and below the fracture in each case, the spinal canal was decompressed. This involved the classical laminectomy and foraminotomy as well as, if necessary, repositioning of the displaced posterior

wall fragment of the vertebral body affected, using bone tampers.

In cases with severe instability and insufficient pedicular screw purchase in severely osteoporotic bone, cement augmentation of the instrumentation was performed.

Patient follow-up

Ten of the 12 patients were treated surgically ; conservative treatment was used in two others owing to their poor general condition. Both patients were mobilized after a 10-day phase of bed rest, and had respiratory exercises in bed and physiotherapy after being fitted with a corset.

Six patients additionally displayed neurological deficits. In all 10 patients treated surgically, marked instability as reflected by the occurrence of re-fractures was present in the area treated. Additional vertebral body fractures occurred indeed in the region of the cement tamps, in part also in the adjacent mobile segment. Retrospective fracture analysis of the preoperative CT scans revealed unstable or potentially unstable vertebral body fractures, e.g. AO type A1.3 fractures, in each case. Key criteria for identifying an unstable or potentially unstable osteoporotic vertebral body fracture are the fracture type on the one hand, and specific features, such as a functional pedicle dissociation, the proximity of a pedicle to the fracture line and the detachment (avulsion) of a disc together with the endplates from the adjacent vertebra, on the other hand. These patients were treated by complex long-segment decompressions, corrections and instrumented fusions.

There appears to be a frequent problem with fracture analysis (2). We therefore suggest the following structured procedure in the problem analysis of stable versus unstable osteoporotic vertebral body fractures.

Problem analysis

Thoracolumbar transition – special features related with fracture level

Attention should be paid to the specifically challenging biomechanics of the thoracolumbar

transition in elderly persons. Thoracic kyphosis with a relatively rigid chest generates powerful alternating compression and distraction forces at the thoracolumbar junction when changing from the supine to the standing position and back. The strong compression forces are caused by the forward shift of the plumbline as a result of sagittal imbalance. The distraction forces are generated by the head/shoulders sinking onto a pillow or other support when lying down with the comparatively rigid thoracic spine pivoting over the fulcrum of its kyphosis, hence exerting a distractive force at the thoracolumbar junction. These two phenomena combined with osteoporotic bone lead to a specific fracture type with a detachment of the intervertebral disc together with the superior or inferior endplate from the remaining vertebral body. In a prospective analysis of 100 patients with osteoporotic fractures, we found 64% of the fractures at the thoracolumbar junction.

Problem analysis

Nature of the fracture

In order to establish the typical fracture features in a patient population that is representative of the complication cases which this manuscript focuses upon, we prospectively analyzed these 100 osteoporotic vertebral fractures primarily seen at our institution. All patients underwent a CT scan.

Independently of the cases with complications presented here, these 100 osteoporotic A-fractures were chronologically recorded with their level and fracture type (AO classification) over 24 consecutive months (2009 to 2011) (14). They were mostly compression (body collapse) or burst fractures (incomplete burst fracture). Among these 100 fresh osteoporotic vertebral body fractures in 82 patients, 18 patients displayed two fractures and A1.1, A1.2 and A1.3 fractures were predominantly observed.

Among other points, these fractures displayed the following instability criteria, as already described :

- detachment of the intervertebral disc with the upper plate
- “functional” dissociation of the pedicle from the remaining vertebral body, meaning that the frac-

ture line runs so close to the pedicle root as to destabilize the mechanical connection between the anterior and the posterior elements.

In many cases, this means that there is too little residual bone to take up the cement and an unfavourable ratio exists between the amount of cement and of potentially healing bone. This must clearly be rated as an unstable situation.

Problem analysis

The technique of kyphoplasty

By means of first creating a void inside the fractured vertebra and then filling this void with low-pressure injection of PMMA, kyphoplasty allows for only very limited interlinking of the bone cement with the remaining cancellous bone. Only minimal stability is achieved in the extension and flexion movement. The same applies to loading in trunk rotation (shearing stability). The PMMA cement is bioinert, which means that fracture healing cannot occur in the area of the cement filling, and the latter is 100 times stiffer than the osteoporotic cancellous bone when comparing the respective moduli of elasticity (Young’s modulus).

DISCUSSION

Serious complications may occur after kyphoplasty, not attributable to the treatment method, but as a result of preoperative misjudgement. In our experience, and also based on current literature (7,16,19), most of the fractured vertebral bodies for kyphoplasty are A-fractures and the follow-up shows us after an second incident an increase in fracture frequency and severity. We are aware of comparable problems with vertebroplasty (3,7,8,9,11,13,14,18,19). Correct fracture analysis is decisive for the successful treatment of osteoporotic vertebral fractures (15, 17). Prerequisites for a correct fracture analysis are adequate imaging, understanding of special biomechanical features as found at the thoracolumbar junction, and training in spinal surgery. The experience gained over the past years has taught us that it is possible “to achieve more by doing less”. All treatment methods should be measured against the

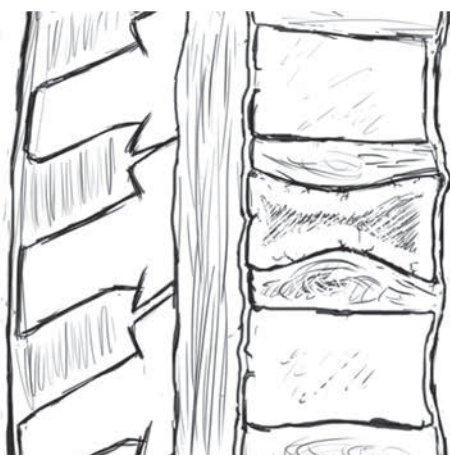


Fig. 6a. — Drawing of an A1.3 fracture. Fracture localization in the posterior third of the vertebral body in AO type A1.3 is rated as potentially unstable.

established conservative fracture treatment as “state of the art”. In our experience, particularly critical attention must be paid to the use of kyphoplasty in A1.3. fractures, if they are located in the dorsal third of the vertebral body in the vicinity of the pedicle, as can be seen in Fig. 6a. Figure 6b also shows an A fracture but the collapse of the superior endplate is close to the pedicle. This fracture is unstable and this entails a high risk for complications after kyphoplasty. Usually, the so-called W-shaped fractures (10) count as a reliable indication. These fractures are often encountered and have been considered to be unobjectionable indications up to now.

It is vitally important to avoid the complications reported and the associated sequelae in elderly individuals (12), since the risk of mortality is increased 7- to 9-fold in such patients, even in the case of an uncomplicated course (4).

REFERENCES

1. Birkenmaier C, Seidl T, Wegener B *et al.* [When is kyphoplasty useful ?] (in German). *Z Orthop Unfall* 2008 ; 146 : 421-424.
2. Blauth M, Bastian L, Knop C, Lange U, Tusch G. [Interobserver reliability in the classification of thoracolumbar trauma.] (in German). *Orthopäde* 1999 ; 28 : 662-681.
3. Boger A, Heini P, Windolf M, Schneider E. Adjacent vertebral failure after vertebroplasty : a biomechanical study of low-modulus PMMA cement. *Eur Spine J* 2007 ; 16 : 2118-2125.

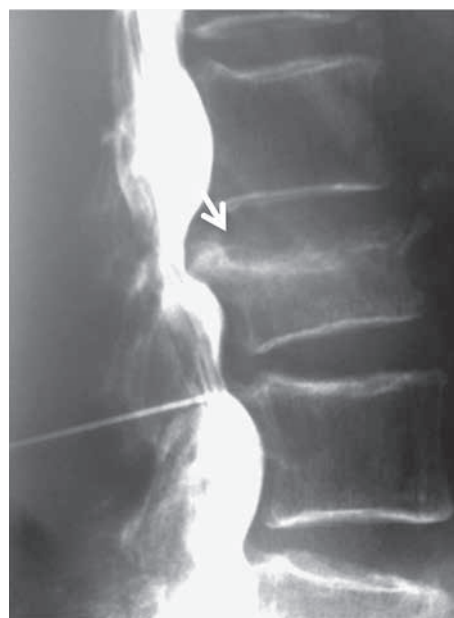

Fig. 6b. — Example of an endplate collapse, comparable to an A 1.3 fracture, but unstable in the analysis if a kyphoplasty is planned.

4. Cauley JA, Thompson DE, Ensrud KC, Scott JC, Black D. Risk of mortality following clinical fractures. *Osteoporos Int* 2000 ; 11 : 556-561.
5. De Negri P, Tirri T, Paternoster G. Treatment of painful osteoporotic or traumatic vertebral compression fractures by percutaneous vertebral augmentation procedures : A nonrandomized comparison between vertebroplasty and kyphoplasty. *Clin J Pain* 2007 ; 23 : 425-430.
6. Frankel BM, Monroe T, Wang C. Percutaneous vertebral augmentation : an elevation in adjacent-level fracture risk in kyphoplasty as compared with vertebroplasty. *Spine J* 2007 ; 7 : 575-582.
7. Fribourg D, Tang C, Sra P, Delamarter R, Bae H. Incidence of subsequent vertebral fracture after kyphoplasty. *Spine J* 2004 ; 29 : 2270-2276.
8. Grohs JG, Matzner M, Trieb K. Minimal invasive stabilization of osteoporotic vertebral fractures : A prospective nonrandomized comparison of vertebroplasty and balloon kyphoplasty. *J Spinal Disord Tech* 2005 ; 18 : 238-242.
9. Kim SH, Kang HS, Choi J-A, Ahn JM. Risk factors of new compression fractures in adjacent vertebrae after percutaneous vertebroplasty. *Acta Radiol* 2004 ; 4 : 440-445.
10. Kim KH, Kuh SU, Chin DK *et al.* Kyphoplasty versus vertebroplasty : Restoration of vertebral body height and correction of kyphotic deformity with special attention to the shape of the fractured vertebrae. *J Spinal Disord Tech* 2012 ; 25 : 338-344.

11. **Lau E, Ong K, Kurtz S, Schmier J, Edidin A.** Mortality following the diagnosis of a vertebral compression fracture in the medicare population. *J Bone Joint Surg* 2008 ; 90-A : 1479-1486.
12. **Lee WS, Sung KH, Jeong HT et al.** Risk factors of developing new symptomatic vertebral compression fractures after percutaneous vertebroplasty in osteoporotic patients. *Eur Spine J* 2006 ; 15 : 1777-1783.
13. **Lin W-C, Lee Y-C, Lee C-H et al.** Refractures in cemented vertebrae after percutaneous vertebroplasty : a retrospective analysis. *Eur Spine J* 2008 ; 17 : 592-599.
14. **Magerl F, Aebi M, Gertzbein SD, Harms J, Nazarian S.** A comprehensive classification of thoracic and lumbar injuries. *Eur Spine J* 1994 ; 3 : 184-201.
15. **Mpotsaris A, Abdolvahabi R, Hoffleith B et al.** [Percutaneous vertebroplasty in vertebral compression fractures of benign or malignant origin : a prospective study of 1188 patients with follow up of 12 months.] (in German). *Dtsch Aertzbl Int* 2011 ; 108 : 331-338.
16. **Pflugmacher R, Kandziora F, Schröder R et al.** [Vertebroplasty and kyphoplasty in osteoporotic fractures of vertebral bodies – a prospective 1-year follow-up analysis.] (in German). *Rofo* 2005 ; 177 : 1670-1676.
17. **Pippan MC, Richter M.** Spinal body reconstruction in osteoporosis. *Eur J Trauma* 2006 ; 32 : 238-243.
18. **Tanigawa N, Komemushi A, Kariya S et al.** Relationship between cement distribution pattern and new compression fracture after percutaneous vertebroplasty. *AJR* 2007 ; 189 : W348-352.
19. **Weber CH, Krötz M, Hoffmann RT et al.** [CT-guided vertebroplasty and kyphoplasty : Comparing technical success rate and complications in 101 cases.] (in German). *Rofo* 2006 ; 78 : 610-617.