



Functional reconstruction of the upper extremity in tetraplegia Application of Möberg's and Allieu's procedures

Daniel WELRAEDS, Abdula Amirali ISMAIL, Alain PARENT

The authors conducted a retrospective study to evaluate the benefit of 43 reconstructive procedures and tendon transfers, performed in 37 sessions to restore hand and arm function in 25 tetraplegic patients. These operative procedures were either single or multiple, depending on the patients' needs for restoration.

The initial clinical situation was assessed based on a simplified version of the international classification of Giens, modified in Edinburgh.

The results were evaluated through clinical assessment and simple functional testing. Gestural ability was improved in more than 80% of the patients and functional gain was important in more than half. The authors conclude that selected tetraplegic patients can benefit from these procedures. The diversity of clinical situations and the variety of surgical procedures result into small scattered series unfit for statistical analysis, and there is a need for unequivocal, internationally recognised assessment methods.

INTRODUCTION

Tetraplegia is responsible for many problems in daily living, mostly related to the recovery and/or preservation of independence for the tetraplegic individual.

In 1976 Hanson et Franklin (9) showed that the function the tetraplegics want to regain primarily is the use of arms and hands. From the first attempts by Royle (19) in 1938 to restore the function of paralysed intrinsic muscles to the assessments made on large series such as Freehafer's (7) in 1998, many operators have tried to improve tendon

transfer techniques. The studies by Möberg, Zancolli and Bunnell are outstanding milestones in this field.

With the population of tetraplegics of a spinal unit admitting around 60 new cases yearly, we attempted between 1986 and 2002, to apply a simplified form of Möberg's principles to 25 patients (43 operations).

In short, Möberg stated that high neurological levels call for restoration of simple functions, and also that arthrodesis must be avoided and tenodesis must be privileged. The hand must be kept supple and suitable for contact. He also stated that a tenodesis is often stronger and more useful than a tendon transfer. All procedures used must be reversible and sensitive discrimination (in the fingers) is of great importance for the quality of the result.

The aim of this study was to assess the results and to investigate the limits of this policy and to point out the unreliability of the systems currently available for evaluation of postoperative results.

From the Trauma and Rehabilitation Center (Centre de Traumatologie et de Réadaptation), University Hospital Brugmann, Brussels, Belgium

Daniel Welraeds, MD, Orthopaedic Surgeon, Surgeon-in-Chief.

Abdula A. Ismail, MD, Orthopaedic Surgeon, Honorary Consultant Surgeon.

Alain Parent, MD, Physiotherapist.

Correspondence : Daniel Welraeds, Centre de Traumatologie et de Réadaptation, place Van Gehuchten, 4, 1020 Brussel, Belgium. E-mail : daniel.welraeds@ctrbx1.be

© 2003, Acta Orthopædica Belgica.

PATIENTS AND METHODS

Between 1986 and 2002, we performed 43 operations for restitution of upper arm function in 25 tetraplegics. Eighteen were male and 7 female, a common distribution among patients with a traumatic lesion of the spinal cord. The mean age at the time of injury was 30 years ; it was 37 years at the time of operation (range : 15 to 52 years). The time interval between injury and the final operation was 68 months (range : 7 to 356 months). Some patients had several consecutive operations on the same limb to restore different functions ; others had operations on both upper limbs at different settings, to avoid simultaneous immobilisation of both sides .

Twenty-four patients had sustained their injury in an accident, most often a road traffic accident (19/24) ; the condition was secondary to a neurological pathology (Guillain-Barré) in one patient.

The spinal cord lesion was at the C5 level in four patients, including two with incomplete tetraplegia ; it was at the C6 level in eleven patients, including two with incomplete tetraplegia ; at the C7 level in eight patients including two with incomplete tetraplegia, and at the C8 level in two patients.

Five patients had been treated conservatively, including the patient with tetraplegia secondary to Guillain-Barré. The other 20 had been treated surgically : one had undergone simple laminectomy, and 19 had undergone anterior and/or posterior spine fixation.

Complications occurred after initial admission in 11 out of 25 patients : 9 respiratory, 6 pressure sores, 2 ectopic ossifications, 1 carpal tunnel syndrome, 1 deep vein thrombosis, 1 nervous breakdown.

Two patients died several years after operation : one from an unknown cause, the other following a fall.

METHODS

Patient selection

Owing to the length and complexity of rehabilitation, we preferred young, motivated patients, able to understand and endure the demands and duration of their rehabilitation.

Youth is a major asset for both plasticity of the tissues and mental adjustment requested for tendon transfers modifying muscular functions. Nevertheless, we accepted older patients if motivation appeared adequate.

Moderate spasticity was not a contra-indication ; stiffness not improved by physiotherapy has lead us to refuse the operation : the expected functional gain would be impaired by the limitation in joint mobility.

Pressure sores were always considered a contra-indication.

Pre- and postoperative evaluation

All patients were submitted to a pre- and post-operative evaluation (usually done by the surgeon in charge of the operation) and, if necessary, to a neurological assessment made by a neurologist.

Pre-operative evaluation was done a short time before the operation ; post-operative evaluation was done before discharge, 12 to 16 weeks after the surgery.

Pre-operative evaluation consisted of a record of the patient's functional needs and motivations, a motor and sensitive assessment of the upper limbs and a record of side issues as spasticity, stiffness, fractures, pain, skin condition, psychological status, infectious diseases. Post-operatively complications and patient appreciation were documented and functional gain evaluated.

Although it was not considered mandatory, pre-operative electrophysiological assessment of the involved muscles was done whenever possible, in order to check the integrity of the muscles elected for transfer and confirm the permanent loss of the receiver muscles, in order to appropriately schedule surgery (Bunnell) (3).

Occupational therapists performed functional evaluation of the upper limb using Filippetti's method (5). It consists of Lamb's autonomy assessment and Sollermann's prehension test. Both tests are meant to give a quantitated rating of common gestures and allow, through pre- and postoperative comparison, an objective appraisal of functional gain of the operation. It was noted that their reproducibility among various occupational therapists was poor and although they might serve as a standard method of evaluation in expert hands, such was not the case in our series.

Operations

Upper limb surgery in a proximal level tetraplegic is planned in two stages : restoration of the spatial control of the arm is always the first step when elbow extension is abolished or severely weakened. As a second step hand function is improved when the need is expressed by the patient.

To acquire spatial control of the arm, it is necessary to restore, through transfer of the posterior deltoid to the triceps, a useful elbow extension, which is often abolished or too weak. This transfer was always done using Allieu's technique (1). An artificial ligament made of Dacron is wrapped in a sheath of fascia lata taken from

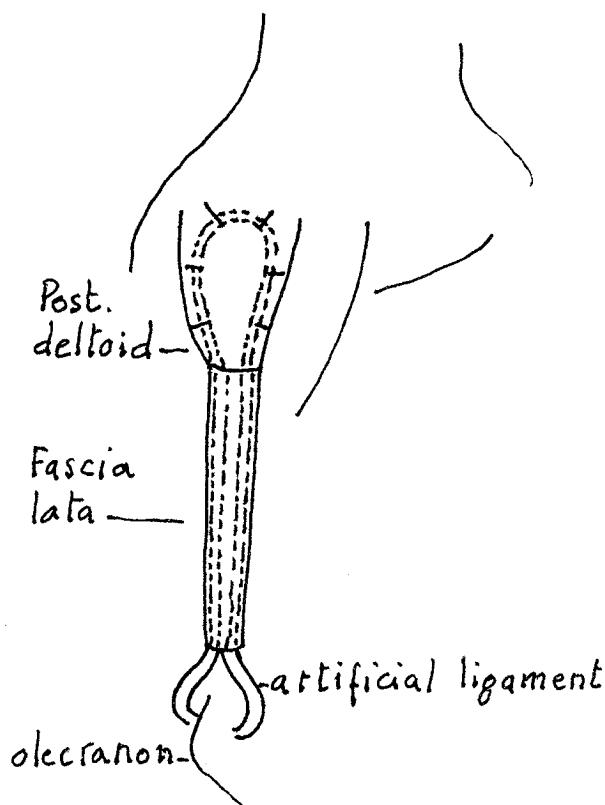


Fig. 1. — Allieu's technique for transfer of the posterior deltoid to the distal triceps tendon and olecranon.

the opposite thigh and made into a tube to cover the distance between the posterior deltoid and the olecranon where it is fixed (fig 1). However, this technique considerably lengthens the course of the posterior deltoid and alters its strength at the insertion. This transfer is functionally poor, sufficiently strong however to control the spatial position of the hand with a strength depending on the pre-tension given to the posterior deltoid. The Dacron ligament was withdrawn from the marketplace in 2000 ; it was substituted by a Mersilen® braid, more difficult to work because the ends tend to unravel.

The second step aimed at improving hand function, by restoring whatever hand gesture could be restored ; this was done as the first step in cases with a functioning triceps.

The following surgical procedures were used for this step :

- Restoration of key grip using the strength of the extensor carpi radialis muscles (ECR) following




Fig. 2. — Möberg procedure : the arrows indicate key grip (thumb to lateral side of index) with wrist extension.

Möberg's technique : The strength of the ECR determines the strength of the key grip, tuning is obtained by varying the tension of a flexor pollicis longus (FPL) tenodesis to the volar side of the distal radius, completed with a tenodesis of the extensor pollicis on the metacarpal and an arthrodesis of the thumb distal joint by mean of a K wire (fig 2). The annular ligament at the metacarpo-phalangeal joint is resected to permit the tendon to bowstring : the gain in strength of the key grip is considerable.

K wires tend to loosen and migrate and must often be removed ; the joint regains some mobility, which does not necessarily compromise the end result, provided the thumb does not slip under the fingers when closing the key grip.

To avoid migration of the wire, we substituted to by a resorbable rod (Biofix®) in 1995. After resorption of the rod, the joint keeps a reasonable stiffness.

- Restoration of grasp : Whenever flexion of the long fingers is impaired, grip may be improved or even re-created by a tendon transfer from an active forearm muscle to the paralysed long flexors. For this purpose, one of the radial muscles is severed from its distal insertion, rerouted to the volar side of the wrist and sutured, using Pulvertaft's method, to the long flexors. The most convenient muscle is the brachioradialis : severed from its distal insertion, it is easily directed and attached to the long flexors at the volar side of the wrist. Because the brachioradialis inserts proximally on the humerus, a brachioradialis transfer has the disadvantage of a course that varies with the position of the forearm.

Another radial muscle would be preferable but is more difficult to redirect. When sacrificing a wrist extensor the weakening effect on an FPL tenodesis must be considered.

- *Restoration of long fingers extension* : When extension to a functional position is impossible and the fingers can be closed (possibly helped by a controlled moderate spasticity), the patient can benefit from an assisted extension. This can be accomplished by a transfer of a radial muscle toward the finger extensors, under the condition that the remaining radial muscles are strong enough to further control wrist extension, automatic closure of the hand, and key grip, if it has been re-created.

Postoperative regime

We applied the classical rule of five weeks on a foam block or adjustable abduction splint following deltoid to triceps transfer and forearm plaster splint, leaving the elbow free, following distal transfers.

Physiotherapists and occupational therapists received all useful information regarding the surgical technique, limitations and potentialities.

Mental corticalisation of the transfer demands adaptability of the patient : in order to speed up the course of rehabilitation, we employed the biofeedback technique which, through visual and audio signals, allows for rapid integration of the transfer at the cortical level.

The analytically obtained movements are next applied in occupational therapy to acquire gestural ability for daily living activities.

Cases distribution

As a **single unilateral** procedure, we performed in 8 cases Möberg's thumb tenodesis (listed as "Möberg") and in 6 cases deltoid to triceps transfer (listed as "deltoid/triceps").

Combined unilateral procedures were done five times : Möberg and deltoid/triceps : one case, Möberg combined with a transfer of brachio-radialis on flexor digitorum profundus : two cases, Möberg combined with transfer of brachio-radialis on extensor digitorum communis : one case, and Möberg combined with a flexor digitorum tenodesis : one case.

Combined bilateral procedures are presented in table I (see "results").

Two cases of paretic hands were managed with atypical procedures : tenotomy of the long flexors for spastic retraction in one case and proximal stabilisation of

the thumb for partial recurrent dislocation in another case.

RESULTS

1. Simple unilateral procedures : 16 procedures in 16 sessions

1.1. Atypical procedures : 2 cases

In one case, which lacked extension of the long fingers owing to spastic flexor digitorum profundus (FDP) retraction, a lengthening tenotomy of the FDL restored the grasp.

In a second case, thumb instability was corrected by a capsulorrhaphy of the metacarpophalangeal joint relieving pain at the cost of moderate loss of joint mobility.

1.2. Thumb tenodesis (Möberg) : 8 cases

- in 6 cases the hand was completely paralysed, and in 2 cases it was partially paralysed with a complete thumb paralysis.
- A useful key grip was restored in 7 patients (one case lost to follow-up due to hospital discharge). Figure 3 demonstrates a typical result.
- Sollerman test : mean 42/80 preoperatively, mean 53/80 postoperatively.

As complications, we noted : 3 Kirschner wire problems (removed), 1 transplant slackening (retightened), 1 loosening of thumb arthrodesis (re-arthrodesis) and one Südeck atrophy.

The various secondary corrective procedures effectively restored the initial quality of function.

1.3. Deltoid/triceps transfer : 6 cases

Elbow extension strength was rated according to the Highet scale (16) ; all cases rated 0 pre-operatively gained from one up to three grades on the scale, giving useful and in some cases powerful active extension (fig 4).

2. Combined unilateral procedures : 10 procedures in 5 sessions

2.1. Deltoid/triceps + Möberg : 1 case

Elbow extension was 0 pre-operatively and 3 postoperatively.

Table I. — Combined bilateral procedures

Patient	Side	Procedure	Function before	Function after	Complications	Treatment	Result
1	right	Möberg	key Grip 0	key Grip +	–	–	good
		ECRL to finger flexors	weak grasp	weak grasp	Tendon course too curved	Straightening	good
	left	ECRL to finger flexors	absent grasp	absent grasp	adhesions	releasing	good
2	right	deltoid to triceps	elbow extension 0	elbow extension 0	sutures slackening	redo	fair
	right	Möberg + brachio-radialis to finger flexors	paralysed hand, functional wrist	Key Grip +	thumb slips under 2 nd and 3 rd fingers	wrist extension orthosis	good
	left	deltoid to triceps	elbow extension 0	elbow extension 1	–	–	poor
3	left	deltoid to triceps	elbow extension 0	elbow extension 4			very good
	right	deltoid to triceps	elbow extension 0	elbow extension 3			good
	right	Möberg + brachio-radialis to finger flexors	paralysed hand, functional wrist	key grip : ok grasp : ok			good
4	left	deltoid to triceps	elbow extension 0	elbow extension 1	slackening of transfer	re-tension	fair
	right	Möberg + brachio-radialis to finger flexors	«automatic» hand	key grip : ok grasp : ok			good
5	right	Möberg	paralysed hand	key grip : ok	wire resorption		good
	right	brachio-radialis to finger flexors	flexion long fingers : 0 extension long fingers : 1	flexion long fingers : ok, but limited amplitude	lack of sensibility of cutaneous branch of radial nerve		good
	left	brachio-radialis to finger flexors	flexion long fingers : 0	flexion long fingers : ok strength : weak			fair

Preoperatively the fingers had no function besides the natural tenodesis effect of wrist extension. Postoperatively a good key grip was regained, and patients were able to hold a sheet of paper (Froment's sign) and to hold a glass.

2.2. Möberg + brachioradialis to FDP : 2 cases

Preoperatively, thumb function was absent, strength of long fingers was rated 0 in one case and rated 1 in the other.

Postoperatively, key grip was good in the 2 cases, long fingers flexion rated 2 in one case, 3 in the other but slackening of the suture on the ring and little finger required revision.

2.3. Möberg + brachioradialis to extensor indicis : 1 case

Preoperatively : paralysed thumb, flexion deformity of long fingers ; postoperatively, good key grip and partial extension of long fingers.

2.4. Möberg + FDP tenodesis : 1 case

Preoperatively : weak thumb, index and major flexion weak, annular and auricular : good flexion. Postoperatively : good key grip, improved flexion of long fingers.

3. Bilateral combined procedures (5 patients, 17 procedures, 16 sessions)

These five cases were submitted to 17 surgical procedures, each directed toward one function. Complications (see tables) occurred in seven cases and had to be corrected surgically in four cases. Möberg's procedure was performed simultaneously with ECRL or brachioradialis transfer on the FDP in 3 cases.

4. Results analysis

These results were recorded after corrective procedures if any and distributed after grouping the procedures in classes.

The result were categorised as good : when a useful function was obtained, fair when function was partially regained and poor with a minimal functional gain.

Atypical procedures (2) good : 2

Möberg procedures (18) good : 17 (fig 3), poor : 1

Deltoid/triceps (12) good : 7 (fig 4), fair 3, poor : 2

Additional procedures (11) good : 7, fair : 3, poor : 1

DISCUSSION

The surgical approach to management of hand paralysis has a long track record : Möberg (10) quotes attempts made in Germany in 1920 by Schmidt and Schrauder.

In 1938, Royle (19) described a technique of restoration of thumb opposition in case of palsy of the intrinsic muscles of the thumb, using tendon "re-routing".

Sterling Bunnell (3) laid out the major principles of tendon transfer : proximal joint stabilisation, release of contractures and fixed deformities,



Fig. 3. — Result of Möberg's procedure

adequate strength and amplitude for the transferred muscle, straightforward tendon pull, respect of muscular function integrity (except for pronator teres and brachioradialis).

In 1974, Zancolli (21) suggested an ingenious technique to correct the claw deformity resulting from the intrinsic paralysis : the lasso operation, using a tenodesis of FDS to suppress the hyperextension of the first phalanx.

Lipscomb (13) pointed out that all spinal cord lesions between the 6th and the 7th cervical vertebrae show complete paralysis of all finger muscles including the intrinsics. Although we had some lesions at this level, we did not encounter clawing.

Evolution in operative techniques

Various surgical techniques were proposed. All rely on three basis surgical principles :

- tenodesis of wrist extensors to restore finger flexion, when active extension is available,
- transfer of functional muscles belonging to a synergistic group to a paralysed muscle,
- arthrodesis or capsulodesis of certain joints (metacarpophalangeal of 1st ray) to obtain stabilisation.

Four major events have influenced reconstruction in tetraplegia :

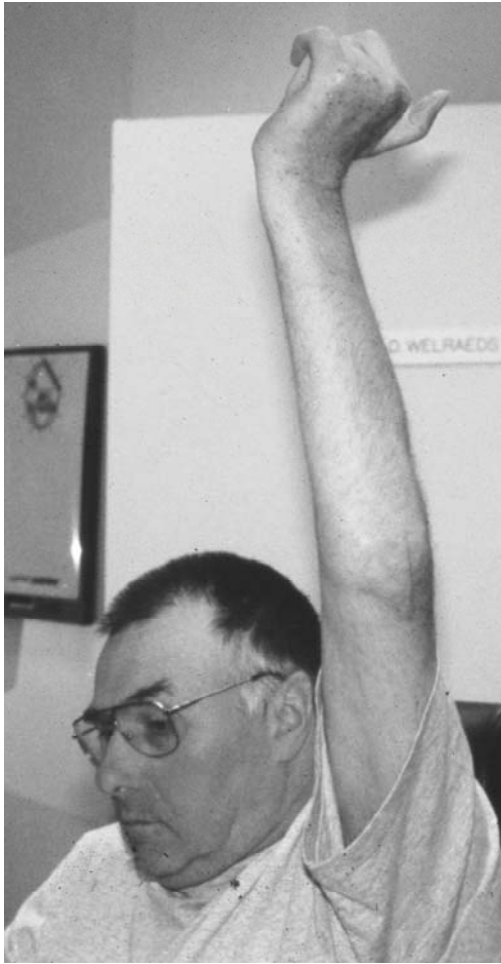


Fig. 4. — Deltoid to triceps transfer : results

- the progressive introduction of the basic reconstruction principles techniques in tetraplegic patients,
- attempts to select the indications following classifications based either on neurological level (13) or residual functionality (8), and finally the general acceptance of the Giens classification (1978) later modified in Edinburgh (1984),
- the emphasis put by Möberg (16) in 1975 on active extension of the elbow to provide adequate positioning of the hand in space, and to oppose passive flexion of the elbow, when the brachioradialis is used as a transfer (Johnstone) (11).
- Lipscomb's publication (13) of treatment algorithms and various surgical steps, based on the

author's chosen classification (22). But in a given situation the choice of the best treatment can be difficult, if one adheres to all different parameters, classifications and algorithms.

Therefore, we have followed Möberg's logical and simple strategy in two steps (17) : the first step is restoration of elbow extension, if absent ; the second step is creation of a key grip. Complementary procedures are considered for flexion or extension of long fingers if advisable.

Although Möberg also mentions restoration of active wrist extension by brachioradialis transfer to the wrist extensors, we limit our operative indications to those cases capable of active wrist extension. It has to be mentioned that the brachioradialis in this transfer becomes a bi-articular muscle, the course of which depends on elbow extension.

Classification and evaluation

The neurological level classification as a guide to restoration of gestuality in a tetraplegic, is not pertinent and reliable. The international classification of Edinburgh (14), modified in Giens in 1984 (15) and based on remaining active muscles is preferred. This classification is favoured to define the algorithms of treatment from an initial situation but it does not allow to quantify the final benefit of surgery.

The selection of a surgical procedure in our hands was based essentially on three criteria :

- the presence of active extension of the elbow, the presence of active wrist extension and the appraisal of the finger function most needed by the patient.

Evaluation of the functional gain is difficult :

- Filipetti *et al* (5) suggested pre- and postoperative evaluation using the autonomy test of Lamb and the prehension test of Sollerman. These tests performed by occupational therapists, are time consuming and their outcome is dubious, seemingly related to the interpretation of the examiner. They were introduced in our department after 1990, but we were unable to apply them with the necessary precision and regularity.

Former-Cordero *et al* in 2003 (6) evaluated 66 operated cases using the questionnaire of Lamb and Chan on daily living activities, modified by Mohamed. This questionnaire is subjective, mixing functional and psychosocial items of unequal importance, rendering its pertinence doubtful. Hentz (10) shares a similar reservation towards functional tests is : he finds functional evaluation useless except for simple measurements of strength and amplitude. Already in 1948, Bunnell (3) stated that, on account of the amount of variables, it is impossible to evaluate statistically the results of tendon reconstruction.

All our patients have at least been submitted to a clinical and functional examination pre- and post-operatively in order to achieve a standard qualitative, if not quantitative assessment of the results. For this purpose we used :

- either the Highet scale for assessing muscular strength, adopted by the Medical Research Council in 1974, advocated by Möberg and applied to muscular groups contributing to one function,
- or a few simple functional tests like taking a pen, a matchbox, a telephone receiver.

Value of electrophysiological assessment.

Electrophysiological testing is usually omitted in pre-operative assessment. However, with medicolegal issues in mind, we found it useful to produce an objective appraisal of the muscular status (rather more qualitative than quantitative). However this method is unable to give any information on muscle strength and Möberg (17) therefore preferred biofeedback for this purpose. We also used biofeedback techniques but solely for rehabilitation purposes : this method provides ocular and auditive signals to the patient and accelerates efficient corticalisation of the transfer.

RESULTS

Results must be objectively assessed in terms of analytical gain (strength, amplitude), functional gain (autonomy), or quality of life.

The diversity of the clinical situations and the corresponding surgical interventions, and the weakness of the evaluation methods do not allow an objective quantitated analysis.

This obstacle in tendon reconstruction surgery was noted by Bunnell (3) in 1948 and later confirmed by Hentz (10) in 1983.

In a study targeted on simple deltoid/triceps transfer, Dunkerly *et al* (4) admitted they were unable to demonstrate any difference between operated tetraplegics and non-operated controls, although the operated cases said they were functionally improved.

Allieu *et al* (1) studied the results of restoration of elbow extension with the posterior deltoid in 11 cases ; they noted that the mean strength of extension amounted to 27 % of that in normal subjects.

We also found these mixed results in our strength ratings ; the deltoid course is too short to give an important extension strength but this gain obtained enlarges prehension space, and provides a functional improvement as described by Allieu *et al* (2).

In hand reconstruction, Vanden Berghe *et al* (20) used Jamar's dynamometer and simple functional tests to quantify their results : they noted some gain in all patients at least in strength (grasp, key grip, wrist extension).

In single procedures as well as in multiple procedures, we rated our results as "good" in 22 cases out of 23 ("good" = an effective function with noticeable gain regarding the function which was absent pre-operatively).

Former-Cordero *et al* (6) analysed their results from a functional standpoint (performance in daily living activities) ; of 20 cases, 3 were rated excellent and 9 medium to good. Likewise, Möberg states that 75 % of quadriplegics can be improved by surgery (16)

This "satisfying" quality of the results is also found to some degree in other studies (5,10,12).

CONCLUSIONS

We conducted a prospective study of 43 operations for restoration of function of the upper limb in

25 tetraplegics, using Bunnell's, Möberg's and Allieu's principles and a simplified protocol bringing into play restoration of elbow extension, key grip and complementary procedures adapted to the patient's needs. We conclude that these operations in selected patients provide a functional gain in more than 80 %, and that the gain is important in more than 50 % of the cases.

The results should be systematically good or very good if the operation is correctly selected and the learning curve has been overcome.

For results evaluation, a major difficulty is encountered: what to measure and how to measure. Besides, the variety of clinical situations together with the numerous surgical techniques result in series too small to be pertinently assessed. These pitfalls are constant in the literature and more consensus conferences should be held to clarify the situation.

Finally, if functional gain is satisfying the impact of this gain on independence is yet to be demonstrated.

REFERENCES

1. Allieu Y, Benichou M, Ohanna E, Rabischong E, Benoit P. Chirurgie fonctionnelle du membre supérieur chez le tétraplégique *Rev Chir Orthop* 1993 ; 79 : 79-88.
2. Allieu Y, Teissier J, Trikki F, Mailhe D, Asencio G, Gomis R, Jacoulet P. Réanimation de l'extension du coude chez le tétraplégique par transplantation du deltoïde postérieur *Rev Chir Orthop* 1985 ; 71 : 195-200.
3. Bunnell S. *Surgery of the Hand*, 2nd ed, Philadelphia : JB Lippincott Company, 1948.
4. Dunkerley AI, Ashburn A, Stack EI. Deltoid triceps transfer and functional independence of people with tetraplegia *Spinal Cord* 2000 ; 38 : 435-441.
5. Filipetti P, Teissier J, Galtiver F *et al.* Chirurgie fonctionnelle du membre supérieur du tétraplégique *Ann Réadaptation Méd Phys* 1990 ; 33 : 121-141.
6. Former-Cordero I *et al.* The role of upper limb in tetraplegia. *Spinal Cord* 2003 ; 41 : 90-96.
7. Freehafer AA. Tendon transfers in tetraplegic patients : the Cleveland experience. *Spinal Cord*, 1998 ; 36 : 315-319.
8. Garrett AL, Perry J, Nickel VL. Traumatic quadriplegia. *JAMA* 1964 ; 187 : 7.
9. Hanson RW, Franklin WR. Sexual loss in relation to other functional losses for spinal cord injured males. *Arch Phys Med Rehabil* 1976 ; 57 : 291-293.
10. Hentz V, Brown M, Keoshian, LA. Upper limb reconstruction in quadriplegia : functional assessment and proposed treatment modifications. *J Hand Surg* 1983 ; 8-A : 129-131.
11. Johnstone BR, Jordan CJ, Buntine JA. A review of surgical rehabilitation of the upper limb in quadriplegia. *Paraplegia* 1988 ; 26 : 317-339.
12. Lamb DW, Chan KM. Surgical reconstruction of the upper limb in traumatic tetraplegia. *J Bone Joint Surg*, 1983 ; 65-B : 291-298.
13. Lipscomb PR, Elkins EC, Henderson ED. Tendon transfers to restore function of hands in tetraplegia, especially after fracture-dislocation of the 6th cervical vertebra. *J Bone Joint Surg* 1958 ; 40-A : 1071-1080.
14. Mc Dowell CL, Möberg EA, Smith AG. International conference on surgical rehabilitation of the upper limb in tetraplegia. *J Hand Surg* 1979 ; 4 : 387-390.
15. Mc Dowell CL, Möberg EA, Houre JH. The second international conference on surgical rehabilitation of the upper limb in tetraplegia. *J Hand Surg* 1986 ; 11-A : 604-608.
16. Möberg E. Surgical treatment for absent single hand grip and elbow extensor in quadriplegia. *J Bone Joint Surg* 1975 ; 57-A : 196-206.
17. Möberg E. *The Upper Limb in Tetraplegia. A New Approach to Surgical Rehabilitation*. Georg Thieme Publishers, Stuttgart, 1978 ; p 25, 51.
18. Riordan DC. Tendon transplantation in median nerve and ulnar nerve paralysis. *J Bone Joint Surg* 1953 ; 35-A : 312-320.
19. Royle ND. An operation for paralysis of the intrinsic muscles of the thumb. *J Am Med Ass* 1938 ; III : 612-613.
20. Vandenberghe A, Van Laere M, Hellings S, Vercauteren M. Reconstruction of the upper extremity in paraplegia : functional assessment, surgical procedures and rehabilitation. *Paraplegia* 1991 ; 29 : 103-112.
21. Zancolli EA. Corrección de la «garra» digital por parálisis intrínseca. La operación del «lazo», *Acta Orthop Latino-Am* 1974 ; 1 : 65.
22. Zancolli EA. Surgery for the quadriplegic hand with active, strong wrist extension preserved. *Clin Orthop* 1975 ; 112 : 111-113.