



Comparison of cervical disc arthroplasty with anterior cervical discectomy and fusion for the treatment of cervical spondylotic myelopathy

Chen DING, Ying HONG, Hao LIU, Rui SHI, Yueming SONG, Tao LI

From West China Hospital, Sichuan University, Chengdu, Sichuan Province, China

The clinical outcome of cervical disc arthroplasty for cervical spondylotic myelopathy (CSM) is still controversial. The authors retrospectively compared the intermediate term clinical outcome of cervical disc arthroplasty and traditional anterior cervical discectomy and fusion (ACDF). Seventy-six cases of single-level CSM with a minimum follow-up of two years were retrospectively analyzed. Thirty-seven patients underwent single-level cervical disc arthroplasty (Bryan disc : 12 cases ; Prestige LP disc : 25 cases), while the other 39 patients underwent single-level ACDF. Significant improvement in SF-36 physical/mental component scores and NDI score was found in both groups ($p < 0.05$); however, the arthroplasty group had significantly greater score improvement at each follow-up time point ($p < 0.05$). The JOA score and Nurick grade improved significantly at each time point in both groups ($p < 0.05$), but there were no significant differences between the groups ($p > 0.05$). The range of motion (surgical level and C2C7) remained unchanged in the arthroplasty group ($p > 0.05$), whereas it decreased significantly in the ACDF group ($p < 0.05$). The arthroplasty group had a lower incidence of complications than the ACDF group. The intermediate outcomes of cervical disc arthroplasty compared favourably to those of ACDF. Arthroplasty avoids complications from spinal fusion by preserving mobility.

Keywords : cervical spondylotic myelopathy ; cervical disc arthroplasty ; anterior cervical discectomy and fusion ; cervical spine.

INTRODUCTION

Cervical spondylotic myelopathy (CSM) is a common and severe kind of degenerative disease. It refers to a chronic compression of the spinal cord by degenerative spinal structures, such as cervical discs, facet joints, posterior osteophytes, an ossified posterior longitudinal ligament, or a hypertrophic yellow ligament, which results in spinal cord dysfunction (4,26,27). Many patients with CSM require surgical treatment. Anterior cervical discectomy and fusion (ACDF) is the classic technique (21), but some studies have shown that interbody fusion leads to increased intradiscal stress and accelerated

-
- Chen Ding, MD, PhD, Orthopaedic Resident.
 - Ying Hong, BS, Operating Room Nurse.
 - Hao Liu, MD, PhD, Professor of Orthopaedic Surgery.
 - Rui Shi, MD, PhD, Orthopaedic Surgeon.
 - Yueming Song, MD, PhD, Professor of Orthopaedic Surgery.
 - Tao Li, MD, PhD, Professor of Orthopaedic Surgery.
Department of Orthopaedic Surgery, West China Hospital, Sichuan University, Chengdu, Sichuan Province, China.
Correspondence : Hao Liu, Dept Orthop. Surgery, West China Hospital, No 37, Wai Nan Guo Xue Xiang, Chengdu, Sichuan Province, China, 610041.
E-mail : liuhao6304@163.com
© 2013, Acta Orthopædica Belgica.
-

degeneration at the adjacent segments. As an alternative to ACDF, cervical disc arthroplasty has been widely applied all over the world in the past 10 years. This technology can maintain the motion, disc height, and normal segmental curvature after thorough anterior decompression, thus theoretically reducing the incidence of adjacent segment degeneration. A number of studies have suggested that the clinical outcomes of cervical disc arthroplasty are equivalent to or better than those of ACDF (12,17, 20,24). Currently, most spine surgeons believe that the indications for cervical disc arthroplasty include radiculopathy and myelopathy due to cervical spondylosis and soft disc herniation, but the efficacy of cervical disc arthroplasty for the treatment of *pure* myelopathy has seldom been reported and is still controversial. The authors performed this retrospective study to evaluate clinical and radiological outcomes of cervical disc arthroplasty compared to ACDF for the treatment of CSM at two years of follow-up.

MATERIALS AND METHODS

Demographics

From November 2005 to August 2009, 83 CSM patients received cervical disc arthroplasty or ACDF at a single level. Seventy-six of them completed at least two years of follow-up and were included in this study. Preoperative imaging included static and dynamic radiographs, CT-scans, and magnetic resonance imaging (MRI). Static lateral radiographs were used to assess the sagittal alignment of the cervical spine. Dynamic radiographs were used to assess the range of motion (operative level and C2C7). CT-scans and MRI were used to evaluate the diameter of the vertebral canal and to determine the level of and reason for spinal cord compression.

The inclusion criteria were 1 : typical symptoms and signs of CSM, such as lower extremity weakness, gait disturbance, muscular hypertonia, hyperreflexia, clonus, Babinski's reflex, and positive Hoffmann's sign, 2 : single level cervical spondylosis or soft disc herniation between C3 and T1, confirmed by CT-scan and MRI, 3 : age between 18 and 65, and 4 : resistance to conservative treatment for at least three months. The exclusion criteria were : cervical radiculopathy, infection, trauma, abnormal alignment or instability, ossification of the posterior longitudinal ligament, severe spondylosis at the

index segment as evidenced by bridging osteophytes, disc height collapse > 50%, reduction of motion, facet arthropathy, osteoporosis, ankylosing spondylitis, rheumatoid arthritis, daily administration of insulin or steroids, pregnancy, and metal allergy.

The arthroplasty group (Table I) consisted of 37 patients : 12 with Bryan discs and 25 with Prestige LP discs (both manufactured by Medtronic Sofamor Danek, Memphis, Tennessee). In this group there were 21 males and 16 females with an average age of 45.4 years (range, 30-62 years). The mean disease history was 17.8 months (range, 6-60 months), and the mean follow-up period was 34 months (range, 24-57 months). The ACDF group consisted of 39 patients, all of whom had Atlantis plates implanted (Medtronic Sofamor Danek, Memphis, Tennessee). In this group there were 23 males and 16 females with an average age of 47.5 years (range, 33-63 years). The mean disease history was 20.5 months (range, 12-72 months), and the mean follow-up period was 30 months (range, 24-48 months). No significant differences were found between the two groups with regard to demographics or baseline characteristics (Table I) : gender, age, disease history, preoperative SF-36, JOA, NDI, and Nurick grade.

Surgical technique and postoperative management

We refer to the literature for the technique. Arthroplasty patients usually started mobilization of the cervical spine four or five days after surgery. A cervical collar was used for the first four weeks during outdoor activities. The arthroplasty patients took celecoxib 200 mg twice a day for two weeks and did strengthening exercises for the muscles of the neck. They were suggested to ambulate the next day. The drainage tube was normally removed one day after surgery. After spinal fusion, the patients were suggested to stay in bed for two to three weeks, and the drainage tube was removed one day after surgery. A cervical collar was used to restrict motion of the cervical spine for four to six weeks.

Data Collection

Patient demographics, surgical data, and outcome data were collected. The clinical and radiographic outcomes were evaluated preoperatively and at 1 week, 3 months, 6 months, 12 months, and 24 months. Clinical evaluation included SF-36 physical component score (PCS) and mental component score (MCS), Japanese Orthopedic Association (JOA) score, neck disability index (NDI)

Table I. — Demographic data and baseline characteristics

Variable	Arthroplasty group n = 37	ACDF group n = 39	p*
Gender	21 m/16 f	23 m/ 16 f	0.845
Age (years)	45.4 ± 6.3	47.5 ± 7.5	0.197
Disease history (months)	17.8 ± 11.3	20.5 ± 10.9	0.293
Preoperative SF-36 (physical)	42.9 ± 16.4	42.6 ± 15.1	0.933
Preoperative SF-36 (mental)	45.1 ± 18.3	47.0 ± 14.2	0.615
Preoperative JOA	10.6 ± 2.5	11.4 ± 2.2	0.174
Preoperative NDI	23.4 ± 10.5	21.5 ± 7.8	0.354
Preoperative Nurick grade	2.9 ± 0.8	2.7 ± 0.8	0.264

* : For continuous variables, p values were based on an independent two-sample t test. For categorical variables, p values were based on Fisher's exact test.

JOA = Japanese Orthopaedic Association ; NDI = neck disability index.

score, and Nurick grade. The SF-36 was used to assess the general outcome, the JOA score to assess the function of spinal cord, the NDI score to assess the status of the cervical spine, and the Nurick grade to assess the severity of the myelopathy (19). Radiographic evaluation included static radiographs and lateral flexion-extension radiographs. Device stability was assessed on neutral and dynamic lateral radiographs. Range of motion (ROM) of the surgical level and the C2C7 segment were also evaluated. The disc space angle was used for the ROM at the surgical level ; the Cobb angle between the inferior margin of the C2 and C7 vertebral bodies for the C2C7 ROM. The radiographic measurements were done by two independent observers with the ACDSee Canvas 11 software (ACD Systems, Seattle, Washington). Each observer measured each parameter twice, and the mean value was used for analysis. In addition, complications and reoperations of both cohorts were recorded.

Statistical Analysis

SPSS version 16.0 software was used for statistical analysis. All continuous data were expressed as mean ± standard deviation. One-way ANOVA was used to analyze the significance of changes between preoperative and postoperative data within each group, while an independent two-sample t test (for continuous variables) or Fisher's exact test (for categorical variables) was used to make statistical comparisons between the two groups. A $p < 0.05$ was defined as statistically significant.

RESULTS

Surgical data

All operations were successfully performed. There was no significant difference between the groups (Table II) as to distribution of levels, operation time and blood loss. Hospital stay and time needed to return to work were significantly longer in the ACDF group (13.5 days and 58.4 days) than in the arthroplasty group (8.4 days and 15.2 days) ($p < 0.01$) (Table II).

Clinical outcomes

The mean SF-36 PCS and SF-36 MCS improved significantly in both groups after surgery, and the effect remained at the 24-month follow-up (Table III). Postoperative SF-36 scores were significantly better in the arthroplasty group at all time points. Similarly, significant improvement in the JOA score, NDI score, and Nurick grade was noted postoperatively in both groups (Table IV). At each postoperative time point, JOA score and Nurick grade showed no statistically significant difference between the two groups ($p > 0.05$), while the NDI score was significantly better ($p < 0.05$) in the arthroplasty group (Table IV).

Table II. — Surgical data

Variable	Arthroplasty group	ACDF group	p*
Operation level	C3C4 (n = 1), C4C5 (n = 8), C5C6 (n = 16), C6C7 (n = 12)	C4C5 (n = 8), C5C6 (n = 20), C6C7 (n = 11)	0.697
Operation time (min.)	114.9 ± 20.2	107.8 ± 13.9	0.079
Blood loss (ml)	89.5 ± 31.4	79.2 ± 35.8	0.190
Hospital stay (days)	8.4 ± 2.7	13.5 ± 3.3	< 0.01
Time needed to return to work (days)	15.2 ± 3.6	58.4 ± 14.1	< 0.01

* : For continuous variables, p values were based on an independent two-sample t test. For categorical variables, p values were based on Fisher's exact test.

Table III. — Pre- and postoperative SF-36 physical and mental component scores

	SF-36 PCS [#]		SF-36 MCS [#]	
	Arthroplasty group	ACDF group	Arthroplasty group	ACDF group
Preoperative	42.9 ± 16.4	42.6 ± 15.1	45.1 ± 18.3	47.0 ± 14.2
1 week	66.5 ± 14.8	51.8 ± 8.3*	69.2 ± 16.6	58.6 ± 8.8*
3 months	70.0 ± 14.9	58.4 ± 6.2*	72.7 ± 17.0	63.9 ± 8.3*
6 months	72.0 ± 13.5	62.6 ± 8.4*	74.1 ± 15.8	66.1 ± 7.5*
12 months	72.8 ± 13.4	60.8 ± 8.1*	73.3 ± 14.8	65.1 ± 8.9*
24 months	71.5 ± 13.2	59.8 ± 8.3*	72.7 ± 15.3	63.6 ± 9.0*

: compared with preoperative : p < 0.05 ; * : compared with arthroplasty group : p < 0.05.

Table IV. — Pre- and postoperative JOA score, NDI score, and Nurick grade

	JOA score [#]		NDI score [#]		Nurick grade [#]	
	Arthroplasty group	ACDF group	Arthroplasty group	ACDF group	Arthroplasty group	ACDF group
Preoperative	10.6 ± 2.5	11.4 ± 2.2	23.4 ± 10.5	21.5 ± 7.8	2.9 ± 0.8	2.7 ± 0.8
1 week	13.4 ± 2.5	13.9 ± 1.4	12.1 ± 6.2	16.1 ± 3.9*	1.6 ± 0.6	1.5 ± 0.6
3 months	14.5 ± 2.1	14.5 ± 1.6	9.0 ± 5.1	13.3 ± 1.9*	1.2 ± 0.7	1.0 ± 0.7
6 months	14.5 ± 2.1	14.9 ± 1.5	7.8 ± 5.3	12.1 ± 2.1*	1.2 ± 0.8	1.3 ± 0.6
12 months	15.3 ± 1.8	15.2 ± 1.1	7.2 ± 4.9	12.2 ± 3.5*	1.1 ± 0.7	1.2 ± 0.8
24 months	14.8 ± 1.8	15.3 ± 1.1	7.1 ± 3.6	13.4 ± 3.9*	1.1 ± 0.7	0.9 ± 0.7

: compared with preoperative : p < 0.05 * : compared with arthroplasty group : p < 0.05.

Radiographic outcome

Based on static and dynamic radiographs, ROM of more than 2° was retained in all patients in the arthroplasty group, and fusion was successful in 94.9% of the patients in the fusion group. In the

arthroplasty group, the surgical level and C2C7 ROM (Table V) significantly decreased at one-week follow-up (p < 0.05), mainly because of wound pain, restriction of the cervical collar, and mental stress, but returned to the preoperative level after three months (p > 0.05) (Fig. 1, 2). In the ACDF

Table V. — Pre- and postoperative surgical level and C2C7 ROM

	Surgical level ROM		C2C7 ROM	
	Arthroplasty group	ACDF group	Arthroplasty group	ACDF group
Preoperative	13.2 ± 2.5	12.8 ± 2.5	58.3 ± 5.8	56.8 ± 5.1
1 week	7.5 ± 1.9 [#]	1.0 ± 0.7 [#]	38.2 ± 6.9 [#]	40.4 ± 6.6 [#]
3 months	12.7 ± 2.2	0.7 ± 0.6 [#]	57.9 ± 4.6	43.0 ± 6.3 [#]
6 months	13.5 ± 1.6	0.5 ± 0.4 [#]	59.9 ± 4.0	42.2 ± 6.6 [#]
12 months	13.9 ± 1.7	0.5 ± 0.3 [#]	60.0 ± 3.9	41.3 ± 6.7 [#]
24 months	13.3 ± 2.0	0.2 ± 0.2 [#]	58.9 ± 4.0	42.8 ± 6.5 [#]

[#]: compared with preoperative : $p < 0.05$.

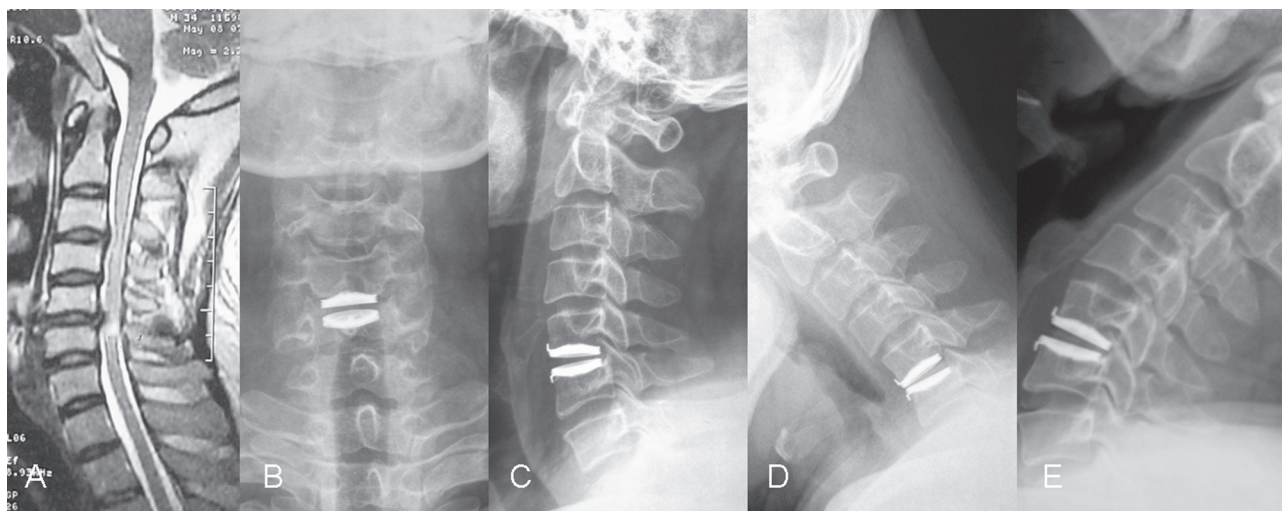


Fig. 1. — This 39-year-old male patient underwent a Bryan cervical disc arthroplasty for myelopathy caused by a C5C6 disc herniation. **A.** MRI showed C5C6 disc herniation and abnormal spinal cord signal before surgery. **B and C.** At one-week follow-up, neutral and lateral radiographs showed a normal prosthesis location. **D and E.** At 36-month follow-up, dynamic cervical radiographs showed that the prosthesis preserved a distinct range of motion.

group, the C2C7 ROM also significantly decreased at one-week follow-up ($p < 0.05$), but there was no obvious change three months later, and none of the differences between any two postoperative time points were significant ($p > 0.05$). The surgical level ROM was always close to 0° after surgery ($p < 0.05$) (Table V).

Complications and reoperations

The arthroplasty group had a lower incidence of complications than did the ACDF group. In the

arthroplasty group, dysphagia was reported in three patients. Mild heterotopic ossification around the prosthesis was found in two patients, but more than 2° of ROM was preserved and there was no spontaneous fusion. Anterior prosthesis migration of less than 4 mm was detected in three patients in the early stages of follow-up, possibly due to inappropriate use of the cervical spine or insufficient milling of the vertebral endplates. The authors asked the patients to use a cervical collar once this phenomenon was noted. These three prostheses regained stabilization after 12 months and were still functional.

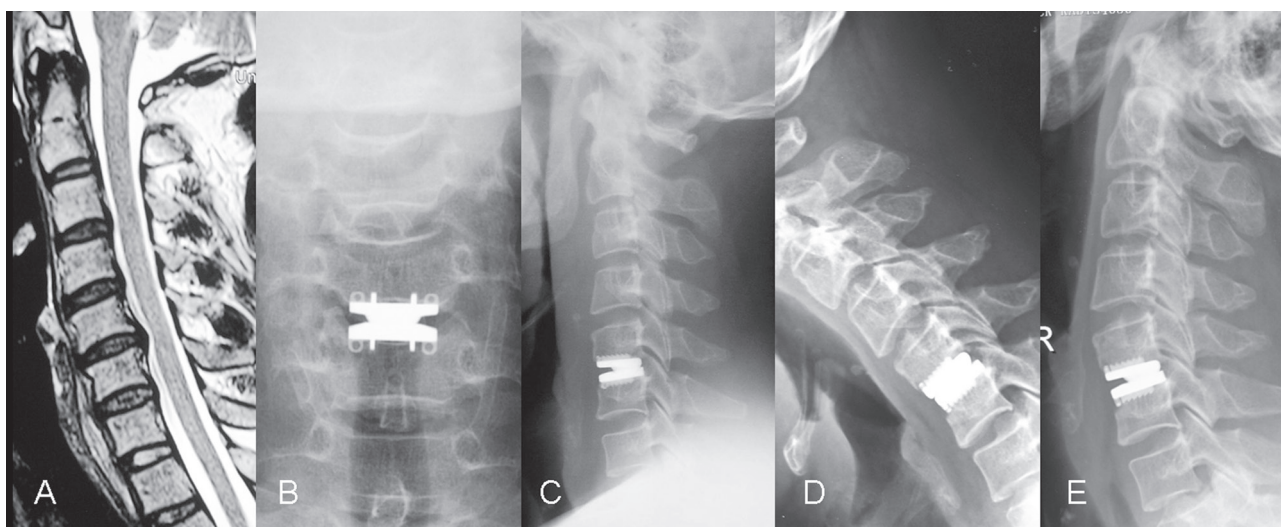


Fig. 2. — This 46-year-old male patient underwent a Prestige LP cervical disc arthroplasty for myelopathy caused by a C5C6 disc herniation. **A.** MRI showed C5C6 disc herniation and compression of spinal cord before surgery. **B and C.** At one-week follow-up, AP and lateral radiographs showed that the location of the prosthesis was normal. **D and E.** At 24-month follow-up, dynamic cervical radiographs showed that the prosthesis preserved a distinct range of motion.

Cerebrospinal fluid leakage occurred in one patient three days after surgery. A reoperation was performed to implant a drainage tube. One week later the tube was removed, and the location and function of the prosthesis were not affected. In the ACDF group, dysphagia was reported in six patients, pseudarthrosis was confirmed in two patients, and seven patients reported pain in the bone-harvesting area. There were three reoperations in the ACDF group, one for pseudarthrosis and the other two for adjacent segment degeneration (Fig. 3). There were no incidents of local haematoma, device subsidence, or vascular or neurological complications in either group.

DISCUSSION

CSM is the most common cause of spinal cord disorder in older persons. It is a condition in which the spinal cord is chronically and progressively compressed by cervical spondylotic changes (4,26,27). The cord damage may be attributed to several important pathophysiologic factors, such as static and dynamic mechanical compression and spinal cord ischaemia (9,16).

Surgery for CSM is necessary in patients with moderate to severe symptoms or progressive neurological deficits, and can be performed using either an anterior (discectomy or corpectomy) or posterior approach (laminectomy or laminoplasty).

For one- to three-level anterior compression, ACDF is the current standard surgical intervention (21). Despite the excellent clinical results of ACDF, spinal fusion sacrifices the ROM of the surgical segment, leading to increased intradiscal stress and accelerated degeneration at the adjacent segments (3,8,14). Goffin *et al* (11) followed 180 patients who received ACDF with a mean follow-up of 100.6 months and detected additional adjacent segment degeneration in 92% of the patients compared with the initial radiographic findings. Hilibrand *et al* (13) found that 2.9% of their patients per year developed symptomatic adjacent segment disease after ACDF, with a predicted incidence of 25.6% within 10 years after surgery.

As an alternative to ACDF, cervical disc arthroplasty is performed in an attempt to preserve motion of the surgical segment and to reduce the incidence of adjacent segment degeneration. So far, the majority of published studies on the technique have

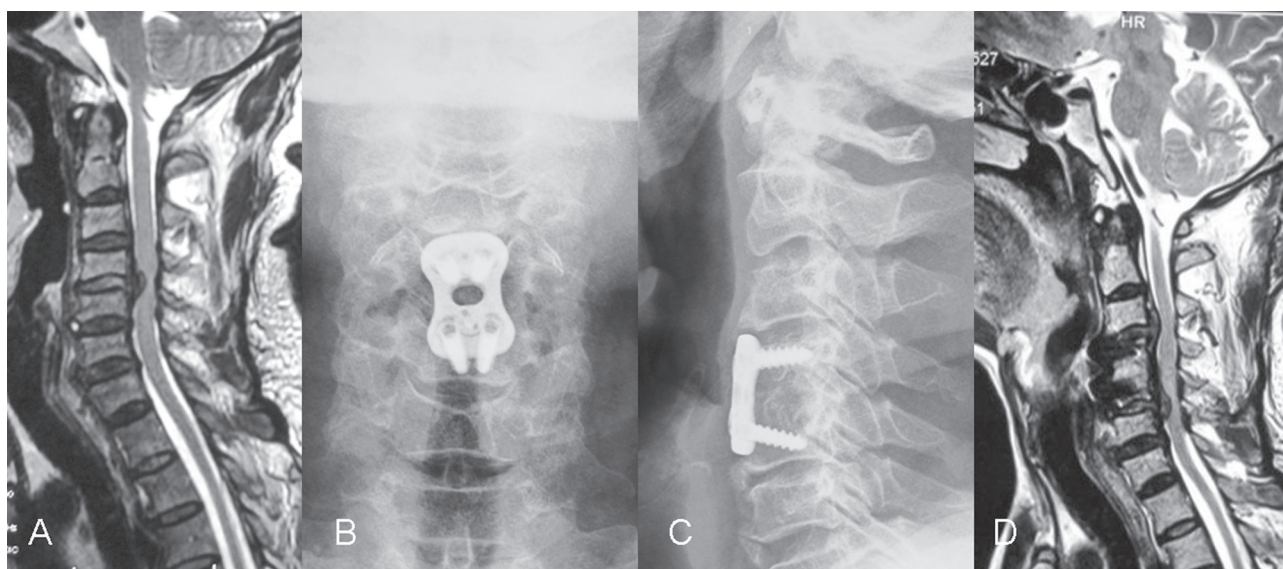


Fig. 3. — This 48-year-old male patient underwent an ACDF for a myelopathy caused by a C4C5 disc herniation. **A.** MRI showed a C4C5 disc herniation and compression of the spinal cord before surgery. **B and C.** At the 12-month follow-up, AP and lateral radiographs showed normal location of anterior plate and fusion of C4-5 segment. **D.** At the 48-month follow-up, MRI showed herniation of upper and lower adjacent discs.

reported that the indications for cervical disc arthroplasty include radiculopathy and myelopathy due to spondylotic changes or disc herniation (6,12,17,18,20, 22,24). However, in light of the pathophysiology of CSM, the preservation of motion may be incompatible with improvement of neurological symptoms and signs. First, with neck flexion and extension, the spinal cord could be compressed against the anterior and posterior structures of the spinal canal, and this condition could theoretically result in sustained microtrauma of the spinal cord (5). Second, the preservation of motion may prevent osteophyte remodeling and even accelerate late osteophyte formation (1,2). There are few studies focusing on the efficacy of cervical disc arthroplasty for a pure cohort (a cohort only including patients with myelopathy, not including patients with radiculopathy or patients with mixed cervical spondylosis) of patients with CSM. Sekhon *et al* (25) performed a study with a mean follow-up of 18.4 months on 11 CSM patients who were treated with cervical disc arthroplasty. They found a 0.91 improvement in the Nurick grade and a 41.5% improvement in NDI,

while spinal cord decompression was confirmed by radiographic examination in all patients. In a post hoc subgroup analysis of two large, prospective, randomized multicenter trials, Riew *et al* (23) reported the two-year outcome of 199 patients who were diagnosed with cervical myelopathy and treated with arthroplasty or ACDF (Prestige ST trial : 59 received arthroplasty, 52 received ACDF ; Bryan trial : 47 received arthroplasty, 41 received ACDF). They found that SF-36, NDI, and VAS scores improved greatly at each time point in all four groups, and that in the Bryan trial the arthroplasty group improved more than the ACDF group. The improvement in neurological status and gait function was similar in the arthroplasty and ACDF groups, and no patient in the arthroplasty group experienced deterioration of neurological function during the study period. In the current study, the JOA score and Nurick grade showed similar improvement in both groups two years after surgery, while the SF-36 and NDI scores improved more in the arthroplasty group than in the ACDF group. Unlike the concerns about arthroplasty, our results suggest that cervical disc

arthroplasty has a better clinical outcome than ACDF for the treatment of CSM caused by spondylotic changes or disc herniation. Moreover, it causes no degradation of neurological function within two years of surgery.

In vivo and *in vitro* studies have suggested that cervical disc arthroplasty can preserve the physiological biomechanics and kinematics of the cervical spine (7,15). Our radiographic results demonstrate that each prosthesis in the arthroplasty group preserved a ROM of more than 2°, while 37 out of 39 patients in the fusion group achieved bony fusion at 24 months. As in previously published studies, the surgical level and C2C7 ROM were well retained in the arthroplasty group but not in the ACDF group. The preservation of motion is theoretically associated with a reduction in the incidence of degeneration at adjacent segments. At 48 months postoperatively, Garrido *et al* (10) reported that only one reoperation due to adjacent segment degeneration occurred in a 21-patient Bryan group, while three reoperations were needed due to adjacent segment degeneration in a 26-patient ACDF group. Kim *et al* (15) found that after a mean follow-up of 19 months, 40.74% (22 patients) of the ACDF group developed radiographic adjacent degenerative changes, while only 17.6% (9 patients) of the disc arthroplasty group displayed degeneration. They also found a 3.5 times greater incidence of radiographic adjacent segment degeneration in the ACDF group than in the arthroplasty group at the last follow-up. In the current study, the sole reoperation in the arthroplasty group was due to cerebrospinal fluid leakage, whereas two of the three reoperations in the ACDF group were due to adjacent segment degeneration at 24 months. Together, these studies suggest that cervical disc arthroplasty reduces the incidence of adjacent segment disease compared with ACDF. However, it should be noted that the sample size was small and that the follow-up period was short : studies with 5 to 10 years follow-up will be necessary to test the long-term merits of cervical disc arthroplasty for the treatment of CSM.

Acknowledgement

Chen Ding and Ying Hong contributed equally to this work.

REFERENCES

1. **Albert TJ, Eichenbaum MD.** Goals of cervical disc replacement. *Spine J* 2004 ; 4(6 Suppl) : 292S-293S.
2. **Anderson PA, Sasso RC, Riew KD.** Update on cervical artificial disk replacement. *Instr Course Lect* 2007 ; 56 : 237-245.
3. **Baba H, Furusawa N, Imura S et al.** Late radiographic findings after anterior cervical fusion for spondylotic myeloradiculopathy. *Spine* 1993 ; 18 : 2167-2173.
4. **Baron EM, Young WF.** Cervical spondylotic myelopathy : a brief review of its pathophysiology, clinical course, and diagnosis. *Neurosurgery* 2007 ; 60 (1 Suppl 1) : S35-S41.
5. **Bohlman HH, Emery SE.** The pathophysiology of cervical spondylosis and myelopathy. *Spine* 1988 ; 13 : 843-846.
6. **Coric D, Finger F, Boltes P.** Prospective randomized controlled study of the Bryan Cervical Disc : early clinical results from a single investigational site. *J Neurosurg Spine* 2006 ; 4 : 31-35.
7. **Dmitriev AE, Cunningham BW, Hu N et al.** Adjacent level intradiscal pressure and segmental kinematics following a cervical total disc arthroplasty : an in vitro human cadaveric model. *Spine* 2005 ; 30 : 1165-1172.
8. **Eck JC, Humphreys SC, Lim TH et al.** Biomechanical study on the effect of cervical spine fusion on adjacent-level intradiscal pressure and segmental motion. *Spine* 2002 ; 27 : 2431-2434.
9. **Fehlings MG, Skaf G.** A review of the pathophysiology of cervical spondylotic myelopathy with insights for potential novel mechanisms drawn from traumatic spinal cord injury. *Spine* 1998 ; 23 : 2730-2737.
10. **Garrido BJ, Taha TA, Sasso RC.** Clinical outcomes of Bryan cervical disc arthroplasty. A prospective, randomized, controlled, single site trial with 48-month follow-up. *J Spinal Disord Tech* 2010 ; 23 : 367-371.
11. **Goffin J, Geusens E, Vantomme N et al.** Long-term follow-up after interbody fusion of the cervical spine. *J Spinal Disord Tech* 2004 ; 17 : 79-85.
12. **Goffin J, van Loon J, Van Calenbergh F et al.** A clinical analysis of 4- and 6-year follow-up results after cervical disc replacement surgery using the Bryan Cervical Disc Prosthesis. *J Neurosurg Spine* 2010 ; 12 : 261-269.
13. **Hilibrand AS, Carlson GD, Palumbo MA et al.** Radiculopathy and myelopathy at segments adjacent to the site of a previous anterior cervical arthrodesis. *J Bone Joint Surg* 1999 ; 81-A : 519-528.
14. **Ishihara H, Kanamori M, Kawaguchi Y et al.** Adjacent segment disease after anterior cervical interbody fusion. *Spine J* 2004 ; 4 : 624-628.
15. **Kim SW, Limson MA, Kim SB et al.** Comparison of radiographic changes after ACDF versus Bryan disc arthroplasty in single and bi-level cases. *Eur Spine J* 2009 ; 18 : 218-231.

16. **Montgomery DM, Brower RS.** Cervical spondylotic myelopathy. Clinical syndrome and natural history. *Orthop Clin North Am* 1992 ; 23 : 487-493.
17. **Mummaneni PV, Burkus JK, Haid RW et al.** Clinical and radiographic analysis of cervical disc arthroplasty compared with allograft fusion : a randomized controlled clinical trial. *J Neurosurg Spine* 2007 ; 6 : 198-209.
18. **Nabhan A, Ahlhelm F, Shariat K et al.** The ProDisc-C prosthesis : clinical and radiological experience 1 year after surgery. *Spine* 2007 ; 32 : 1935-1941.
19. **Nurick S.** The natural history and the results of surgical treatment of the spinal cord disorder associated with cervical spondylosis. *Brain* 1972 ; 95 : 101-108.
20. **Peng CW, Yue WM, Basit A et al.** Intermediate results of the Prestige LP Cervical Disc Replacement : clinical and radiological analysis with minimum two-year follow-up. *Spine* 2011 ; 36 : E105-111.
21. **Rao RD, Gourab K, David KS.** Operative treatment of cervical spondylotic myelopathy. *J Bone Joint Surg* 2006 ; 88-A : 1619-1640.
22. **Ren X, Wang W, Chu T et al.** The intermediate clinical outcome and its limitations of Bryan cervical arthroplasty for treatment of cervical disc herniation. *J Spinal Disord Tech* 2011 ; 24 : 221-229.
23. **Riew KD, Buchowski JM, Sasso R et al.** Cervical disc arthroplasty compared with arthrodesis for the treatment of myelopathy. *J Bone Joint Surg* 2008 ; 90-A : 2354-2364.
24. **Sasso RC, Smucker JD, Hacker RJ et al.** Artificial disc versus fusion : a prospective, randomized study with 2-year follow-up on 99 patients. *Spine* 2007 ; 32 : 2933-2940.
25. **Sekhon LH.** Cervical arthroplasty in the management of spondylotic myelopathy : 18-month results. *Neurosurg Focus* 2004 ; 17 : E8.
26. **Swagerty DL Jr.** Cervical spondylotic myelopathy : a cause of gait disturbance and falls in the elderly. *Kans Med* 1994 ; 95 : 226-227, 229.
27. **Tracy JA, Bartleson JD.** Cervical spondylotic myelopathy. *Neurologist* 2010 ; 16 : 176-187.