



Long-term survival of proximal humerus allografts for reconstruction following resection of malignant bone tumours

Gareth SQUIRE, Tom J. GRUNDY, Nicholas A. FERRAN, William M. HARPER, Robert U. ASHFORD

From the University Hospitals of Leicester NHS Trust, Leicester Royal Infirmary, Leicester, U.K.

We previously reported early favourable results concerning allograft use in proximal humerus reconstruction following malignancy. We now present the long-term follow-up of patients who underwent tumour resection with massive humeral allograft reconstruction.

This is a retrospective review of 8 consecutive patients who underwent massive proximal humeral allograft for primary or secondary bone tumours. The median age at first surgery was 41 years ; the median follow-up is 11.1 years.

The overall revision rate of the allografts was 75%. A total of 10 revision procedures were required in this cohort. Five-year survival for implants was 44% ; at ten years no implants were intact. Five-year survival for patients was 88% ; it was 60% at ten years.

In our experience, proximal humerus allograft reconstruction was associated with a high complication rate and resulted in multiple revision procedures in the long term. We no longer perform or recommend this procedure.

Keywords: malignant tumours ; proximal humerus ; allograft.

INTRODUCTION

The proximal humerus is a frequent site of malignancy, being the 3rd most common site for osteosarcoma, and the 2nd most common site for appendicular bone metastasis (2). Malignant tumours

of the proximal humerus were historically treated with forequarter amputation ; more recent techniques have evolved that allow limb salvage. These methods include proximal humeral allograft (PHA), endoprosthetic replacement (EPR), and allograft-prosthetic composite (APC). Limb salvage provides better functional outcome ; however, patient survival is dependent on adequate tumour clearance.

Risks vary dependent on the choice of reconstruction. Allograft reconstruction can be complicated by fracture, infection, and subchondral collapse, leading to implant revision or removal (8). Difficulties with EPR involve consequences of surgical resection of deltoid and rotator cuff. These include proximal subluxation, instability, and a reduction in functional range of motion (3,4). Methods that spare the deltoid and rotator cuff through intra-articular

-
- Gareth Squire, Medical Student.
 - Tom J. Grundy, Medical Student.
 - Nicholas A. Ferran, MBBS, MRCSEd, MSc (Orth Eng) Registrar.
 - William M. Harper, MD, FRCS (Orth) Professor.
 - Robert U. Ashford, MD, FRCS (Orth), Consultant.
University Hospitals of Leicester NHS Trust, Leicester Royal Infirmary, Leicester, U.K.
- Correspondence : Mr Nicholas A. Ferran, 23 Aber Road, Leicester, UK, LE2 2BA. E-mail : nferran@uku.co.uk
© 2013, Acta Orthopædica Belgica.
-

resection avoid these complications (1) but not all tumours are suitable for intra-articular resection.

The most common procedures described are EPR and PHA implants, the preference between which is dependent on local guidance and surgical preference (3). Our unit published early favourable results concerning allograft use, with all implants intact at median follow-up of 23 months (2). These results supported the use of allograft as an alternative to EPR and APC.

We report the long-term follow-up of patients who underwent proximal humeral tumour resection with massive allograft reconstruction.

PATIENTS AND METHODS

This was a retrospective case review of patients undergoing massive proximal humeral allograft for primary and secondary bone tumours at our institution from 1991 to 2003. Patients were identified from the records of the local bone bank. Case notes, histology records, clinical letters, and radiology were reviewed. No patients were excluded from review. The short-term results for the first 5 patients in this series have been reported previously (2).

Demographic data including gender, histological diagnosis, and age at index surgery were recorded. Date of index procedure, date of revision, date of death, and reasons for revision were recorded in order to calculate patient and implant survival. Time to implant failure was defined as time to the first subsequent operation (excluding bone grafting alone). Survival analysis was performed using STATA 12 (StataCorp, Texas, USA).

Given that this was an observational study of practice, ethics approval was deemed unnecessary.

Surgical technique

Diagnosis was reached in all patients via standard orthopaedic oncological practice with radiological investigations (CT, isotope bone scan and/or MRI) and a biopsy. Induction chemotherapy was given to the osteosarcoma patients for three cycles as per protocols available at the time. The dimensions of allograft required and the humeral transection point were pre-determined from the MRI scans. Allografts were supplied by the local bone bank (Leicester Bone Bank, Glenfield Hospital). Allografts were harvested under sterile conditions from cadaveric donors in the operating theatre and then stored at -80°C. Routine microbiological studies of the explanted allografts were undertaken (2).

Surgical resection

Pre-operative planning was used to determine the level of resection from the available imaging. Patients were positioned in a beach chair position. Antibiotic prophylaxis was given in the form of three doses of intravenous cefuroxime. The humerus was approached by an extended delto-pectoral approach, and the main artery and brachial plexus were preserved. The excision was performed without breaching the tumour, and the resection occurred at a pre-determined level and excising the biopsy tract. Tumour clearance was verified by histopathological analysis of an imprint taken at the diaphyseal resection margin. The allograft was secured using standard osteosynthesis techniques. The wound was closed in layers over a drain. Post-operatively, patients were immobilised in a sling for four weeks and then physiotherapy commenced. The osteosarcoma patients resumed chemotherapy as per their protocol following wound healing and recovery from their surgical procedure (10).

RESULTS

Demographics

From bone bank records eight cases were identified. The median age at resection was 32 years (15-77 years), the male to female ratio was 1:1, and median follow-up was 11 years (2-19 years). There were six primary malignant bone tumours and two metastases (Table I).

Surgical outcome and complications

The two patients with metastatic disease died with their allograft intact, while all implants in patients with primary bone sarcomas were revised. The overall revision rate was 75%, with patients undergoing an average of two revision procedures. Reasons for revision included non-union, fracture, infection, dislocation and local recurrence (Fig. 1, Table II). There were two local recurrences necessitating forequarter amputation. Two patients underwent single stage revision to an EPR. Two patients had first stage revision with a spacer and declined second stage surgery. Of these, one developed lung metastasis and died, and the other was happy with appearance and function and chose not to proceed to second stage. Overall there were 11 complications

Table I. — Demographic data for patients with proximal humerus allografts. (RCC renal cell carcinoma, TC thyroid carcinoma, OS osteosarcoma, CS chondrosarcoma; DOD died of disease, ADF alive and disease free)

Patient	Age (years)	Sex	Diagnosis	Oncological Status	Length of follow-up (years)
1	57	M	RCC	DOD	1.94
2	23	F	OS	ADF	19.6
3	32	F	OS	ADF	14.6
4	15	F	OS	DOD	11.6
5	77	M	CS	DOD	11.2
6	16	F	OS	DOD	8.1
7	45	M	CS	ADF	8.1
8	61	M	TC	DOD	6.6

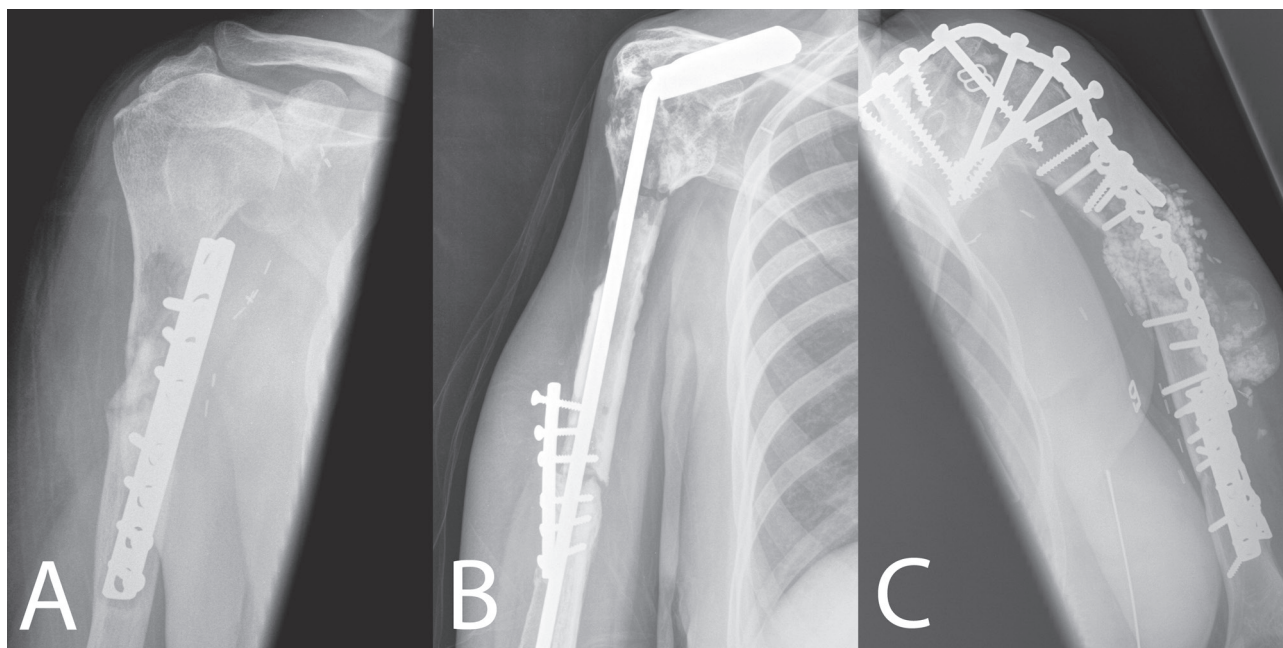


Fig. 1. — Radiographs demonstrating modes of failure ; A : non-union, allograft resorption, and fracture, B : non-union secondary to infection, C : massive infection with metalwork failure.

in eight patients and a total of 10 subsequent procedures to the allograft.

Oncological outcome

In all cases surgical resection margin was wide. At follow-up three patients were alive and disease free (ADF), and five had died of disease (DOD) including both patients in whom the allograft was performed for metastatic disease. Two primary

tumours (1 osteosarcoma, 1 chondrosarcoma) recurred locally and a forequarter amputation was performed in these cases (Table I).

Patient and implant survival

The five-year survival for implant was 44% ; at ten years no implants were intact. The five-year survival for all pathologies was 88% ; at ten years, it was 60% (Fig. 2).

Table II. — Surgical outcome of patients with proximal humerus allografts

Patient	Time to implant failure (years)	Reason for revision	Revised to	Number of revision procedures
1	-----	died with allograft intact	-----	0
2	4.58	Non union, infection	1st stage EPR, (spacer)	4
3	9.86	fracture , degeneration of articular surface	EPR	1
4	3.28	dislocation, fracture, infection	1st stage EPR, (spacer)	2
5	9.11	fracture, recurrence	Forequarter amputation	1
6	0.44	Recurrence	Forequarter amputation	1
7	2.37	Non union	EPR	1
8	-----	died with allograft intact	-----	0

EPR : endoprosthesis replacement.

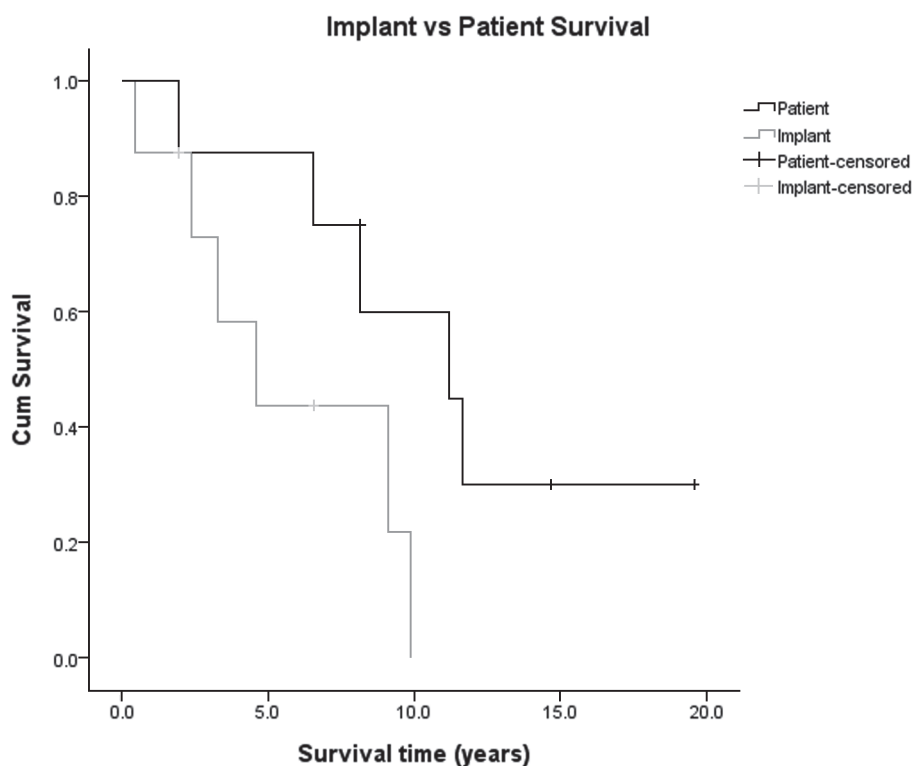


Fig. 2. — Kaplan-Meier survival curves for patients and implants

DISCUSSION

In this series proximal humeral allografts demonstrated poor long-term implant survival with no implants surviving beyond ten years. With the

exception of patients with metastatic disease, all patients outlived their implants.

This was a single surgeon series treated over a twelve-year period, with median follow-up of 11 years. The small sample group is comparable

Table III. — Comparison of PHA, EPR and APC

	Pathology	Mean FU (months)	Reconstruction	Revisions	Complications
Potter (10)	24 Sarcomas 19 Metastases 6 Benign	98	17 PHA	8 (47%)	11 (65%)
			16 EPR	Nil	7 (44%)
			16 APC	1 (6%)	7 (44%)
Van de Sande (11)	24 Sarcomas 4 Metastases 9 Benign	120	13 PHA	8 (61%)	8 (62%)
			14 EPR	3 (30%)	3 (21%)
			10 APC	1 (7%)	4 (40%)

PHA : proximal humeral allograft ; EPR : endoprosthesis replacement ; APC : allograft prosthetic composite.

in size to other reports on this subject. Despite the proximal humerus being a common site for malignant bone tumours, bone tumours in themselves are rare. This study was retrospective, but despite this, all notes were intact and there was no loss to follow-up.

Proponents of allograft implants believed that the procedure provided a cost effective outcome with good pain relief and acceptable function (2,6). We have previously published the short term follow-up of the first five patients in this series who had allograft implants (2). There were no immediate complications post-operatively and at a median of 23 months (14-112 months), there were one infection with associated non-union and two humeral head subluxations. No further surgical procedures had been carried out in order to revise implants, and 80% of patients were alive.

The complication rate for allograft reconstruction of the proximal humerus varies in the literature from 29% to 100% (5,6,9) with higher rates seen in clavicle pro humero.

There are two comparative studies of PHA, APC and EPR (9,10) (Table III). Both demonstrate higher complication and revision rates with PHA than with APC or EPR. In their article Van de Sande *et al* perform an overview of recent literature that demonstrates a complication rate for allograft of 49%, a reoperation rate of 36% and an implant survival rate without revision of 62% (10).

This current study demonstrates that, in contrast to the findings of Mourikis *et al* (6) proximal humeral allografts do not perform well at long-term follow-up, despite good short-term performance (2). In our series all allografts for primary tumours

were revised, with implants remaining intact only in the case of metastasis. Patients with metastasis were significantly older than the rest of the study group. The older age but more likely lower demand of patients with metastasis may explain why their implants did not fail.

The goal of orthopaedic tumour surgery is to restore function whilst achieving adequate resection of malignancy. While proximal humeral allograft provides a cost effective short-term outcome, in the long term, patients with primary bone tumours outlive their allografts and will require revision surgery. We no longer perform or recommend proximal humeral allograft reconstruction. Current evidence would suggest that EPR offers better long-term survival with fewer complications.

REFERENCES

1. **Abdeen A, Hoang BH, Athanasian EA *et al*.** Allograft-prosthesis composite reconstruction of the proximal part of the humerus : functional outcome and survivorship. *J Bone Joint Surg* 2009 ; 91-A : 2406-2415.
2. **Ashford RU, Harper WM.** The versatility of massive allografts in the treatment of bone tumours of the proximal humerus. *Eur J Orthop Surg Traumatol* 2004 ; 14 : 234-238.
3. **Black AW, Szabo RM, Titelman RM.** Treatment of malignant tumors of the proximal humerus with allograft-prosthesis composite reconstruction. *J Shoulder Elbow Surg* 2007 ; 16 : 525-533.
4. **Bos G, Sim F, Pritchard D *et al*.** Prosthetic replacement of the proximal humerus. *Clin Orthop Relat Res* 1987 ; 224 : 178-191.
5. **Getty PJ, Peabody TD.** Complications and functional outcomes of reconstruction with an osteoarticular allograft after *intra-articular* resection of the proximal aspect of the humerus. *J Bone Joint Surg* 1999 ; 81-A : 1138-1146.

6. **Mourikis A, Mankin HJ, Hornicek FJ, Raskin KA.** Treatment of proximal humeral chondrosarcoma with resection and allograft. *J Shoulder Elbow Surg* 2007 ; 16 : 519-524.
7. **Potter BK, Adams SC, Pitcher JD Jr, Malinin TI, Temple HT.** Proximal humerus reconstructions for tumors. *Clin Orthop Relat Res* 2009 ; 467 : 1035-1041.
8. **Probyn LJ, Wunder JS, Bell RS, Griffin AM, Davis AM.** A comparison of outcome of osteoarticular allograft reconstruction and shoulder arthrodesis following resection of primary tumours of the proximal humerus. *Sarcoma* 1998 ; 2 : 163-170.
9. **Rödl RW, Gosheger G, Gebert C et al.** Reconstruction of the proximal humerus after wide resection of tumours. *J Bone Joint Surg* 2002 ; 84-B : 1004-1008.
10. **van de Sande MA, Dijkstra PD, Taminiau AH.** Proximal humerus reconstruction after tumour resection : biological versus endoprosthetic reconstruction. *Int Orthop* 2011 ; 35 : 1375-1380.