



## Solitary haemangioma of the shaft of long bones : resection and reconstruction with autologous bone graft

Zhaoxu LI, Jicun TANG, Zhaoming YE

From Affiliated Hospital of Guilin Medical University, Guilin, China and Second Affiliated Hospital School of Medicine, Zhejiang University, Hangzhou, China

Bone haemangiomas are uncommon lesions, occurring in the skull or spine. A solitary haemangioma in the diaphysis of a long bone is rare. We retrospectively investigated six patients who presented with a solitary haemangioma in a long bone diaphysis. After segmental bone resection, the bone defect was replaced by a bone autograft. Patients were reviewed clinically and with radiographs. The mean follow-up was 6 years (range : 1-20 years). At the time of latest follow-up, no patient had a recurrence. Postoperative complications were one wound necrosis and one superficial wound infection. Union of the gap filling graft with the host bone was achieved in all patients at an average of 4 months (range : 3-8 months). The average Musculoskeletal Tumor Society functional score was 77% (range : 53%-90%) of normal at 6 months postoperatively, and 97% (range : 95%-99%) at the last follow-up evaluation. Segmental resection for solitary haemangioma and reconstruction with autologous bone graft can be considered as a suitable treatment option.

**Keywords :** bone tumour ; haemangioma ; bone grafting ; diaphysis.

### INTRODUCTION

Bone haemangiomas are uncommon lesions, accounting for approximately 0.5-1% of all intraosseous tumours (1) and 1% of all primary bone tumours (2). The most frequent sites of involvement

are vertebrae and calvarium (3). The involvement of long tubular bones is rare, the metadiaphysis being the most commonly affected (4-5). The diaphysis location for a long bone haemangioma is rare, and difficult in radiological and histological differential diagnosis (6). Orthopaedic oncologists consequently have limited experience in the management of a solitary haemangioma in long bone diaphyses. The purpose of the present review is to report on the functional and oncologic results in six patients who underwent segmental resection and reconstruction with autologous bone graft for a solitary haemangioma in long bone diaphyses.

- 
- Zhaoxu Li, MD, Specialist Orthopaedic Registrar.
  - Jicun Tang, MD, Professor of Orthopaedic Surgery.  
*Department of Orthopaedics No. 2, Affiliated Hospital of Guilin Medical University, Guilin Medical University, Guilin, China.*
  - Zhaoming Ye, MD, Professor of Orthopaedic Surgery.  
*Department of Orthopaedics, Second Affiliated Hospital School of Medicine, Zhejiang University, Hangzhou, China.*  
Correspondence : Zhaoxu Li, Specialist Orthopaedic Registrar, Department of Orthopaedics No. 2, Affiliated Hospital of Guilin Medical University, Guilin Medical University, Guilin 541004, China. E-mail : lizhaoxuglm@gmail.com  
© 2013, Acta Orthopædica Belgica.

## PATIENTS AND METHODS

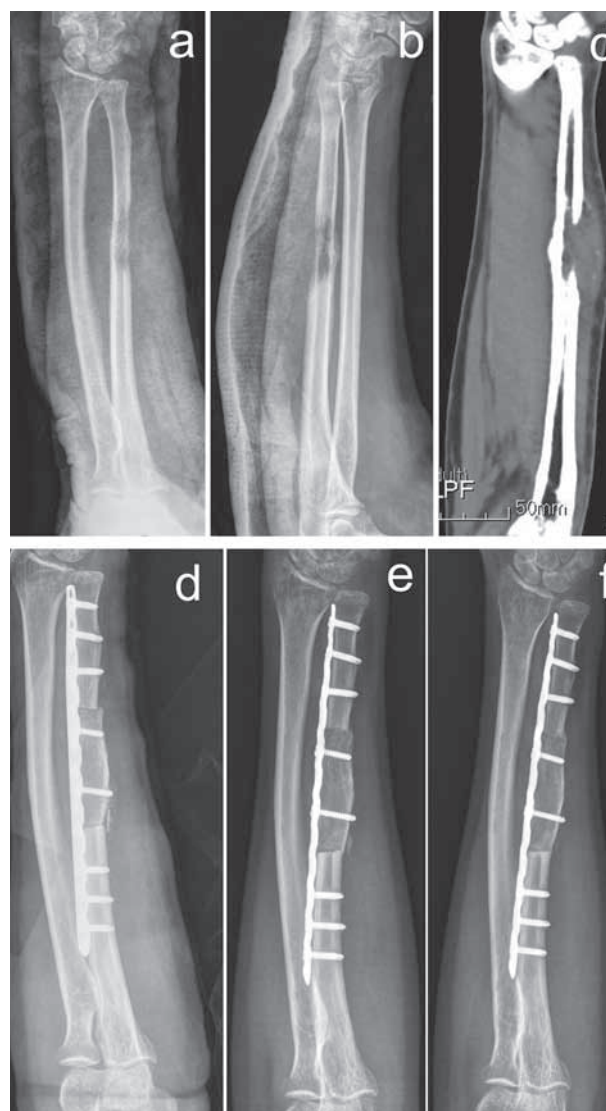
Six patients diagnosed with a solitary haemangioma in a long bone diaphysis during the period 1990-2010 were included in the study. There were four females and two males with an average age of 42 years (range : 27-58). The ulna was affected in two cases, the clavicle in two cases, the radius in one case and the humerus in one case. Two patients had pain and partial restriction of the range of motion of adjacent joints. The other four patients complained only of a painless swelling or soft tissue enlargement at the affected long bone diaphyses. All patients were investigated with X-rays, CT-scan and MRI scan of the involved long bone. Open biopsy was done in one case, while five patients underwent needle biopsy under CT guidance.

The surgical technique varied depending on the anatomical location of the tumour. The extent of resection of the tumour was measured on radiographs. Resection of the periosteum was not attempted. After tumour resection, an autograft was harvested from the iliac bone (if segmental loss < 5 cm) (Fig. 1) or fibula (if segmental loss  $\geq$  5 cm). A locking plate was used for autograft fixation.

Patients were followed with radiographs, and union was assessed postoperatively. The functional outcome was evaluated according to the Musculoskeletal Tumor Society score (MSTS) (7).

## RESULTS

The outcomes are summarized in Tables I and II. At the time of review, all patients were alive with a mean follow-up of 6 years (1-20 years). There was no local recurrence. The mean operating time was 73 minutes (60 min to 85 min), and intraoperative blood loss was 133 ml (100 ml to 200 ml). Two patients had wound problems : one patient with wound necrosis required surgical debridement, and one superficial wound infection was treated conservatively with antibiotics. The mean length of bone resection was  $5 \pm 2$  cm. The mean time to union was 4 months (3 to 8), and delayed union occurred at the distal junction in two of six patients. These delayed unions were not treated surgically and healed with time. The average MSTS functional score was 77% of normal (53%-90%) for all patients at 6 months postoperatively, and 97% (95%-99%) at the last follow-up evaluation.



**Fig. 1.** — Radiograph of a 43-year-old female with a solitary haemangioma of the left ulnar diaphysis. a : Anteroposterior radiograph ; b : Lateral radiograph ; c : Computed tomographic view ; d, e, f : Postoperative radiographs (at 0,1,3 months, respectively).

## DISCUSSION

Intraosseous haemangiomas are rare benign tumours of vascular nature (7). Females, aged 40-50 years, are more frequently affected than males, in the ratio 3:1 (1). Primary skeletal haemangioma of the extremities is uncommon, and occurs predominantly in the lower extremity (73%) usually in the long bones, with the tibia and femur being the

Table I. — Patients' diagnoses and operative data

Number	Age (years)	Gender	Location	Side	Operative Time (min)	Blood Loss (ml)	Length (cm)	Source
1	31	Female	clavicle	Right	75	150	4	iliac bone
2	40	Male	clavicle	Right	65	100	3	iliac bone
3	52	Female	humerus	Left	85	200	7	fibula
4	27	Male	ulna	Right	60	100	6	fibula
5	58	Female	ulna	Left	70	100	4	iliac bone
6	42	Female	radius	Left	85	150	4	iliac bone

Table II. — Functional outcomes and complications at follow-up

Patient Number	Follow-up (ms)	Prox. union (ms)	Distal union (ms)	Functional Outcome				Complications
				6 months follow-up		last follow-up		
				Overall	MSTS Score (%)	Overall	MSTS Score (%)	
1	240	3	4	Excellent	81.0	Excellent	99.0	-
2	24	3	3	Good	76.5	Excellent	98.0	Superficial wound infection
3	108	5	8	Fair	53.0	Excellent	96.0	Wound necrosis
4	30	4	8	Good	73.7	Excellent	95.0	-
5	24	4	3	Excellent	90.0	Excellent	96.0	-
6	12	3	4	Excellent	88.0	Excellent	97.0	-

most common sites (8). In the current study, we present six patients with a solitary haemangioma in the diaphyses of upper limb bones.

Clinical presentation can vary from an incidental finding to local pain, swelling and/ or pathological fracture, according to localization, size and number of lesions (9). Plain radiographs show a classic coarse trabecular bone pattern or soap bubble appearance, and most lesions show cortical destruction (10). CT reveals lytic lesions that exhibit a spiculated pattern known as Irish lace (11). MRI displays hypo- to hyperintense appearance on T1-weighted sequence depending on the amount of adipose tissue, and hyperintense on T2-weighted sequence due to vascularity (12). Biopsy can provide a diagnostic orientation, but is better avoided for large haemangioma, because of the risk of haemorrhage. Differential diagnosis includes fibrous dysplasia, sarcoma, metastatic disease and multiple myeloma.

Management is controversial. Errani *et al* noted no local recurrence in 8 of 11 patients with epitheli-

oid haemangioma (EH) in bone treated with intral-  
esional curettage (13). Therefore, they concluded that EH of bone could be treated with intral-  
esional curettage, whereas EH of soft tissue should be treated with marginal/wide excision. However, Satoh *et al* (14) believed that once bone haemangiomas have been diagnosed, the definitive treatment should be radical en bloc resection including surrounding intact tissue, to guarantee no recurrence and avoid the risk of massive bleeding. In the current study, six patients with a solitary haemangioma in long bone diaphyses underwent segmental resection of their tumours. Despite the fact that our series is relatively small, our findings were similar to those reported by Wu *et al* (15) and Hong *et al* (16). No recurrence was noted in any case with a follow-up period of 1 to 20 years.

After segmental resection for solitary haemangioma in long bone diaphyses, a large defect is a challenge for the restoration of the biomechanics of the adjacent joints. Van Isacker *et al* (17) advocated

the use of a bone allograft, because it allows for immediate restoration of the anatomy without harvesting or weakening another bone. The absence of incorporation in the long term has however limited its use (18). Recently, reconstruction with alloplastic materials, such as methyl-methacrylate cement (1, 16), has been presented as another option. Yu *et al* (19) filled the bone defect with bone cement and K-wires, and after 12-month follow-up, there was no evidence of local recurrence of haemangioma or loosening of bone cement. Stoffelen *et al* (20) reported the reconstruction of a large ulnar defect due to tumour resection, using the Ilizarov technique of segmental transport. However, several drawbacks limit the wide application of this technique (21).

Autografts have been shown to provide better long-term outcomes (22) and are commonly used to bridge large bone defects after resection of a tumour (23-24). In our patients autogenous iliac bone (for segmental defects < 5 cm) or fibula (for segmental defects  $\geq$  5 cm) reconstruction was used and fixed rigidly with locking plates. This procedure is simple and definitive. In our series, all patients achieved union by a mean of about four months. The average MSTS functional score was 77% of a normal function (53%-90%) for all patients at 6 months postoperatively, and 97% (95%-99%) at the last follow-up evaluation.

In conclusion, segmental resection and reconstruction with autologous bone graft is a viable treatment option for solitary haemangioma of long bone diaphyses. Functional results are satisfying, as well as oncological results in terms of local tumour control are excellent.

## REFERENCES

1. Arribas-Garcia I, Alcalá-Galiano A, Fernandez Garcia A, Montalvo JJ. Zygomatic intraosseous haemangioma : reconstruction with an alloplastic prosthesis based on a 3-D model. *J Plast Reconstr Aesthet Surg* 2010 ; 63 : e451-453.
2. Hung CT, Jou IM, Huang MT. Intraosseous capillary haemangioma of a metacarpal bone. *J Hand Surg Eur* 2012 ; 37 : 76-77.
3. Wu JL, Wu CC, Wang SJ *et al*. Imaging strategies in intramuscular haemangiomas : an analysis of 20 cases. *Int Orthop* 2007 ; 31 : 569-575.
4. Maclean FM, Schatz J, McCarthy SW *et al*. Epithelioid and spindle cell haemangioma of bone. *Skeletal Radiol* 2007 ; 36 Suppl 1 : S50-557.
5. Chawla A, Singrakhia M, Maheshwari M, Modi N, Parmar H. Intraosseous haemangioma of the proximal femur : imaging findings. *Br J Radiol* 2006 ; 79 : e64-66.
6. Matsumoto K, Ishizawa M, Okabe H, Taniguchi I. Hemangioma of bone arising in the ulna : imaging findings with emphasis on MR. *Skeletal Radiol* 2000 ; 29 : 231-234.
7. Verbeke SL, Bovee JV. Primary vascular tumors of bone : a spectrum of entities ? *Int J Clin Exp Pathol* 2011 ; 4 : 541-551.
8. Kaleem Z, Kyriakos M, Totty WG. Solitary skeletal hemangioma of the extremities. *Skeletal Radiol* 2000 ; 29 : 502-513.
9. Valentini V, Nicolai G, Lore B, Aboh IV. Intraosseous hemangiomas. *J Craniofac Surg* 2008 ; 19 : 1459-1464.
10. Vermaat M, Vanel D, Kroon HM *et al*. Vascular tumors of bone : imaging findings. *Eur J Radiol* 2011 ; 77 : 13-18.
11. Ching BC, Wong JS, Tan MH, Jara-Lazaro AR. The many faces of intraosseous haemangioma : a diagnostic headache. *Singapore Med J* 2009 ; 50 : e195-198.
12. Wootton-Gorges SL. MR imaging of primary bone tumors and tumor-like conditions in children. *Magn Reson Imaging Clin N Am* 2009 ; 17 : 469-487.
13. Errani C, Zhang L, Panicek DM, Healey JH, Antonescu CR. Epithelioid hemangioma of bone and soft tissue : a reappraisal of a controversial entity. *Clin Orthop Relat Res* 2012 ; 470 : 1498-1506.
14. Satoh K, Ohtsuka T, Abe T, Yokota K, Kunii K. Haemangioma of the forehead : radiographic diagnosis and definitive surgical treatment in a Japanese series. *Scand J Plast Reconstr Surg Hand Surg* 2009 ; 43 : 75-81.
15. Wu JH, Du JK, Lu PC, Chen CM. Interdisciplinary management of mandibular intraosseous haemangioma. *Br J Oral Maxillofac Surg* 2011 ; 49 : e55-57.
16. Hong B, Hermann EJ, Klein R, Krauss JK, Nakamura M. Surgical resection of osteolytic calvarial lesions : clinicopathological features. *Clin Neurol Neurosurg* 2010 ; 112 : 865-869.
17. van Isacker T, Barbier O, Traore A *et al*. Forearm reconstruction with bone allograft following tumor excision : a series of 10 patients with a mean follow-up of 10 years. *Orthop Traumatol Surg Res* 2011 ; 97 : 793-799.
18. Delloye C, Banse X, Brichard B, Docquier PL, Cornu O. Pelvic reconstruction with a structural pelvic allograft after resection of a malignant bone tumor. *J Bone Joint Surg* 2007 ; 89-A : 579-587.
19. Yu L, Cai L, Yu G, Zeng Z, Tao S. Solitary giant hemangioma of the humerus. *Orthopedics* 2009 ; 32 : 925.
20. Stoffelen D, Lammens J, Fabry G. Resection of a periosteal osteosarcoma and reconstruction using the Ilizarov technique of segmental transport. *J Hand Surg Br* 1993 ; 18 : 144-146.
21. Sun XT, Easwar TR, Manesh S *et al*. Complications and outcome of tibial lengthening using the Ilizarov method

with or without a supplementary intramedullary nail : a case-matched comparative study. *J Bone Joint Surg* 2011 ; 93-B : 782-787.

- 22. Langlais F, Lambotte JC, Thomazeau H.** Long-term results of hemipelvis reconstruction with allografts. *Clin Orthop Relat Res* 2001 ; 388 : 178-186.
- 23. Smith WS, Struhl S.** Replantation of an autoclaved autogenous segment of bone for treatment of chondrosarcoma.

Long-term follow up. *J Bone Joint Surg* 1988 ; 70-A : 70-75.

- 24. Jupiter JB, Gerhard HJ, Guerrero J, Nunley JA, Levin LS.** Treatment of segmental defects of the radius with use of the vascularized osteoseptocutaneous fibular autogenous graft. *J Bone Joint Surg* 1997 ; 79-A : 542-550.