



Iliosacral fixation after type-1 hemipelvectomy : a novel technique

Ufuk AYDINLI, Burak AKESEN, Ulviye YALÇINKAYA, Bahattin HAKYEMEZ, Rasim SERİFOĞLU

From the University of Uludag, Bursa, Turkey

Involvement of the iliac bone and a sacroiliac joint with malignant tumours is not uncommon ; treatment is difficult due to the anatomy of the pelvis. Resection of the tumour mass must be extensive in order to achieve safe margins, but this may lead to instability and poor results. We present a new technique for reconstruction after resection of the iliac bone and sacroiliac joint including a sacral ala, and we present two illustrative cases, with 2 years follow-up.

Following en bloc resection of a chondrosarcoma in the iliac bone, two or three polyaxial pedicle screws were placed transversely into the sacrum. Two polyaxial pedicle screws were also inserted into the remaining pubic and ischial bone respectively. After completion of the construct with rods, a cortical strut graft from the ipsilateral fibula was placed between the rods. Next a split mesh was placed around the implants and was filled with 60 cc bone chips allografts.

Both patients were mobilized with crutches and partial weight bearing for 4 weeks and then full-weight bearing. After two years follow-up, they were ambulatory without external support and their radiological results remained satisfactory.

This technique for reconstruction after type I pelvic resection is advantageous in that it saves mobile lumbar segments.

Keywords : iliac bone ; malignant tumour ; hemipelvectomy ; reconstruction.

INTRODUCTION

The iliac bone is the major component of os coxae. As it provides a connection between the

spine and the hip joint it plays an important role in transmitting the vertical and shear forces from the spine to the lower extremities and vice versa through the hip and sacroiliac joints (4). Involvement of iliac bone and sacroiliac joint with malignant tumours is not uncommon ; treatment is difficult due to the anatomy of the pelvis (6,9). It has been believed that stability is not affected significantly if the sacroiliac joint is intact on one side. Also it has been advocated that if 50% or more of the sacroiliac joints can be saved, there is no need for reconstruction and instrumentation (5,14). However in order to achieve safe margins resection of the tumour mass must be extensive (10,16).

-
- Ufuk Aydınli, MD, Orthopaedic Surgeon, Professor.
 - Burak Akesen, MD, Orthopaedic Surgeon.
Department of Orthopaedics and Traumatology, Spine Unit, University of Uludag, Bursa, Turkey.
 - Ulviye Yalçinkaya, MD, Pathologist.
Department of Pathology, University of Uludag, Bursa, Turkey.
 - Bahattin Hakyemez, MD, Radiologist.
University of Uludag, Department of Radiology, Bursa, Turkey.
 - Rasim Serifoğlu, MD, Orthopaedic Surgeon.
Department of Orthopaedics and Traumatology, Medical Park Hospital, Bursa, Turkey.

Correspondence : Burak Akesen, University of Uludag, Department of Orthopaedics, Spine Unit, Görükle, Bursa, Turkey, 16059. E-mail : akesenb@msn.com

© 2012, Acta Orthopædica Belgica.

Massive resections in the ilium and the sacroiliac joint may lead to vertical and rotational instability. Therefore, achieving a stable construct and fusion between ilium and spine (including the sacrum) are important. However, reconstruction and fixation remain major challenges in pelvic tumours because of the remaining bone and disturbed anatomy of the pelvic area after tumour resection (11-13). To date different types of biologic and prosthetic reconstruction techniques have been proposed (2,3,6,9, 11,12).

In this paper, we present a new technique of reconstruction after resection of the iliac bone and sacroiliac joint including the sacral ala, corresponding to type I-S (resection of the ilium and a portion of the sacrum) and type I-A pelvic resections (including only resection of the ilium) respectively (1,15) in two patients with malignant tumours involving the pelvis. This technique provides sufficient stabilization, allows early mobilization with partial weight bearing and also avoids fixation of mobile spine segments.

Case 1

A 39-year-old man presented with severe right hip pain. The pain had begun one year before. Physical examination showed pain over the right sacroiliac joint. Neurologic examination did not suggest any motor or sensory deficit. His bowel and bladder functions were intact. Plain radiographs as well as computerized tomography (CT) scans were obtained. They revealed a mass in the right iliac bone and sacroiliac joint (Fig. 1A & 1B). Tru-cut biopsy of the lesion suggested a diagnosis of chondrosarcoma. *En bloc* resection of the tumour mass with reconstruction of sacroiliac area was performed.

Case 2

A 33-year-old woman with a past medical history of multiple hereditary exostosis presented with severe back pain and disability due to pain. She was ambulatory and her muscle strength in the lower extremities was intact. Her radiologic workup revealed a mass both at T8 - T9 level and in the left

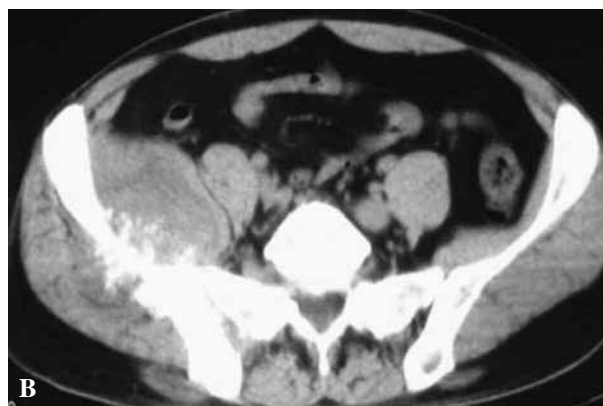
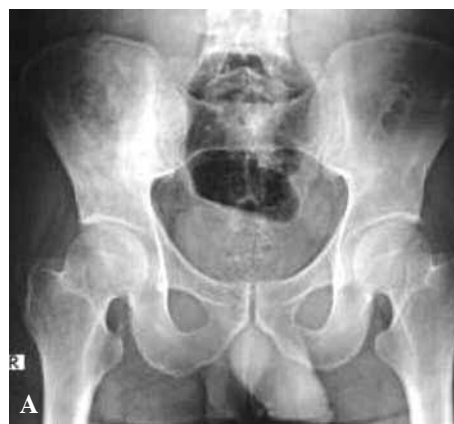
Fig. 1A and 1B. — Preoperative radiologic work-up for case 1. Images suggest a mass involving the right iliac bone and sacroiliac joint.

sacroiliac joint and the left iliac bone (Fig. 2A & 2B). A biopsy was first done at the thoracic spine and resulted in a diagnosis of chondrosarcoma. She underwent *en bloc* resection of the tumour and combined anterior-posterior stabilization. She was neurologically intact and her back pain was relieved when she was discharged. Three months after the index procedure, a second biopsy was done in the left iliac mass and again showed chondrosarcoma. She underwent *en bloc* resection of the tumour mass with reconstruction.

Operative Technique of en bloc Resection and Reconstruction

Before the operation, the patients underwent complete bowel preparation. Preoperative antibiotics were administered. Surgery was performed

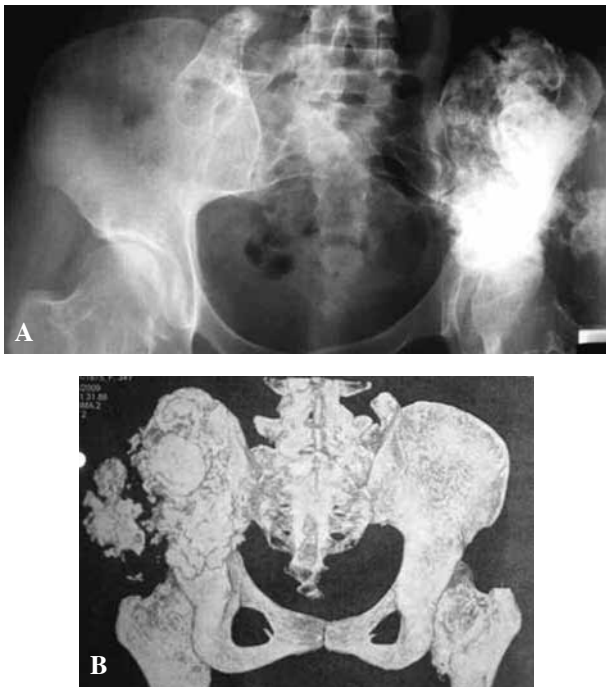


Fig. 2A and 2B. — Preoperative radiographs and CT scans of case 2. Images suggest a mass involving the left iliac bone and sacroiliac joint as well as the gluteal muscles.

under general anaesthesia with endotracheal intubation. Patients were placed in lateral position. Following prepping and draping, two incisions were made. The first incision was made from the SIAS to the sacroiliac joint over the ilium. The second incision was made from the SIAS to the major trochanter. The dissection was carried over the iliac crest subperiostally to the major sciatic notch and to the sacroiliac joint posteriorly. The Iliac wing was exposed medially to the major sciatic notch and the tumour was exposed. The tumour mass was removed *en bloc* including the sacroiliac joint and sacral ala.

The next step of the procedure was fixation. Two or three polyaxial pedicle screws with 8 mm diameter were inserted transversely into the sacrum. Two polyaxial pedicle screws also 8 mm in diameter were inserted into the remaining pubic and ischial bone respectively after making a pathway with a pedicle finder and checking it with a probe to make sure there was no breach or fracture. Sacral and pelvic screws were connected by two rods.

A strut bone graft was harvested from the ipsilateral fibula and was placed between the rods so that it would bridge the shortest distance between sacrum and acetabular dome. In the next step, a split mesh was placed around the implants and was filled with 60 cc bone chips allograft in order to build up an artificial ilium-like bony mass. Two suction drains were placed into the surgical area in both surgeries. Procedures were ended after closing the wound. Patients were transferred to the intensive care unit for postoperative monitoring

Estimated blood loss was 500 cc in both surgeries. Patients were transferred to the ward the next day. Both patients started to mobilize with crutches and partial weight bearing for 4 weeks and then full-weight bearing. They have remained pain free and ambulatory for more than 2 years by now. They are able to walk without any support with some limp due to the loss of gluteal muscles. Radiological results were also satisfactory (Fig. 3 & 4).

DISCUSSION

The iliac bone provides continuity between acetabulum and sacrum as well as an attachment site for a group of muscles including abdominal and gluteal muscles, rectus femoris, sartorius. Type I, I/S, or I/A resections result in defects that may have biomechanical consequences with significant morbidity and functional impairment; this generally necessitates bony reconstruction between the sacrum and acetabulum (6). As the hip joint is not included in these types of resections prosthetic hip reconstructions are not necessary. One should consider reconstruction options before attempting resection.

To date few reconstruction options after type I (including IA and IS) pelvic resection have been described. If the gap between the sacrum and the remaining iliac bone or acetabulum is too large as in our cases, then placement of structural auto / allograft (with or without vascularity) and reconstruction is indicated (2,3,6,9,12). Hugate and Sim (8), reported that either appositional iliosacral arthrodesis or vascularized fibular graft and instrumentation with a few bone screws can achieve solid arthrode-

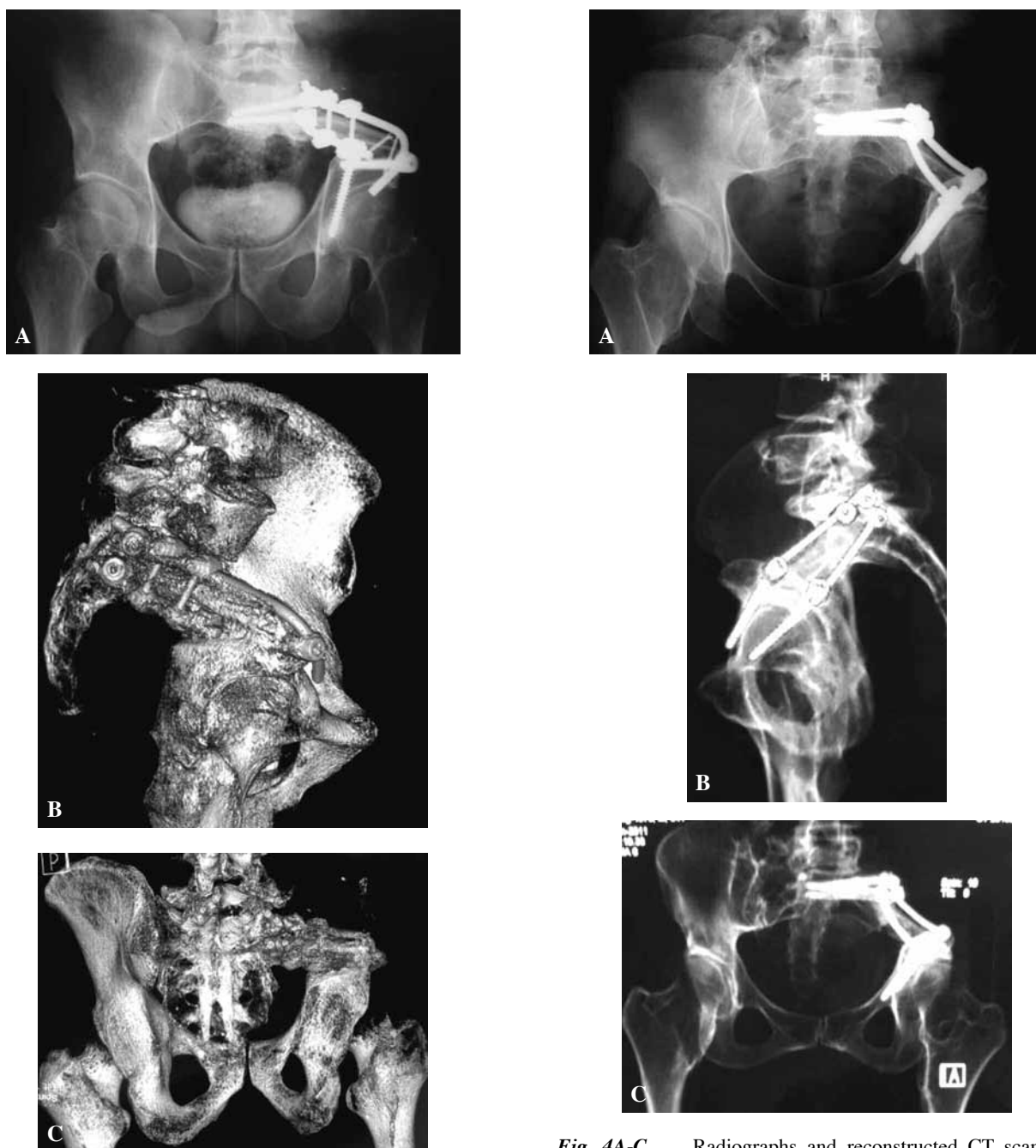


Fig. 3A-C. — Radiographs and 3D CT scans of case 1, 3 years after type-1S pelvic resection.

sis. However, they also mentioned that the involved lower extremity should be placed in a spica cast and immobilized for 2 to 3 months. With the present technique, patients were able to mobilize immediately postoperatively with crutches and partial

Fig. 4A-C. — Radiographs and reconstructed CT scans of case 2, 2 years after operation. This patient underwent type-1S and A pelvic resection.

weight-bearing for 4 weeks and then ambulated full-weight bearing without crutches.

Sakaruba *et al* (12) described the double-barreled vascularized fibular free flap in their study. Type I resection was performed in three of five patients

who were included in the study. Fixation was performed with the Cotrel-Dubousset rod system in two patients and with screws and plate in one patient. The lumbar spine was included in those who were treated with Cotrel-Dubousset systems. These patients started to mobilize after 14 and 25 days respectively without canes. The patient who underwent arthrodesis with screws and plates mobilized with a wheelchair. In our technique we spared the mobile spinal segments and despite this, our patients started to mobilize after they left the intensive care unit.

Guo *et al* (7) reported the results of 61 patients with iliac bone tumours after resection and reconstruction. In their study, resection was performed including region 1, namely the ilium, in 36 patients. They stabilized the remaining periacetabular bone to the spine by inserting pedicle screws into the lumbar spine and sacrum superiorly, into the pubis and ischium inferiorly. Only four patients who were children had additional bone graft or bone cement in order to augment the reconstruction. The technique described by these authors is similar to ours. However they also included the mobile lumbar spine in their reconstruction and bone grafting was not performed routinely in their series.

Necessity of a larger patient population and absence of biomechanical data are the main shortcomings of our study. Nevertheless it suggested both clinically and radiologically sufficient results in two of our patients.

Chondrosarcoma is resistant to both chemotherapy and radiotherapy. Surgical en bloc resection is the choice for curative treatment. This is the reason why our patients underwent surgical treatment.

In the past, plate and screw fixation or instrumentation including the mobile spine have been used in our institution after pelvic tumour resection. However they resulted in high complication and implant failure rates. This prompted us to search for different solutions. In conclusion this is not the first and only but a different type of reconstruction technique for type I pelvic resection with a significant advantage of saving mobile lumbar segments.

REFERENCES

1. **Campanacci M, Capanna R.** Pelvic resections : the Rizzoli Institute experience. *Orthop Clin North Am* 1991 ; 22 : 65-86.
2. **Dai KR, Yan MN, Zhu ZA, Sun YH.** Computer-aided custom-made hemipelvic prosthesis used in extensive pelvic lesions. *J Arthroplasty* 2007 ; 22 : 981-986.
3. **Donati D, El Ghoneimy A, Bertoni F, Di Bella C, Mercuri M.** Surgical treatment and outcome of conventional pelvic chondrosarcoma. *J Bone Joint Surg* 2005 ; 87-B : 1527-1530.
4. **Foley BS, Buschbacher RM.** Sacroiliac joint pain : anatomy, biomechanics, diagnosis, and treatment. *Am J Phys Med Rehabil* 2006 ; 85 : 997-1006.
5. **Gennari I, Azzarelli A, Guagliuolo V.** A posterior approach for the excision of sacral chordoma. *J Bone Joint Surg* 1987 ; 69-B : 565-568.
6. **Gerrand CH, Bell RS, Griffin AM, Wunder JS.** Instability after major tumor resection : prevention and treatment. *Orthop Clin North Am* 2001 ; 32 : 697-710.
7. **Guo W, Tang S, Dong S, Li X.** [Resection and reconstruction for tumors of iliac bone (Abstract).] (in Chinese). *Zonghua Wai Ke Za Zhi* 2006 ; 44 : 813-816.
8. **Hugate Jr R, Sim FH.** Pelvic reconstruction techniques. *Orthop Clin North Am* 2006 ; 37 : 85-97.
9. **Krettek C, Geerling J, Bastian L et al.** Computer aided tumor resection in the pelvis. *Injury* 2004 ; 35 : S-A79-S-A83.
10. **Nolte LP, Zamorano LJ, Jiang Z et al.** Novel approach to computer assisted spine surgery. 1st Int Symp on Medical Robotics and Computer Assisted Surgery (MRCAS) 1994.
11. **Pring ME, Weber KL, Unni KK, Sim FH.** Chondrosarcoma of the pelvis : a review of sixty-four cases. *J Bone Joint Surg* 2001 ; 83-A : 1630-1642.
12. **Sakaruba M, Kimata Y, Iida H et al.** Pelvic ring reconstruction with the double-barreled vascularized fibular free flap. *Plast Reconstr Surg* 2005 ; 116 : 1340-1345.
13. **Shibuya I, Yoshimoto Y, Miki H, Dezawa K.** Brace management for huge bone defect after malignant pelvic bone tumor excision. *J Orthop Sci* 2007 ; 12 : 185-189.
14. **Wanebo JH, Gaker DL, Whitehill R, Morgan RF, Constable WC.** Pelvic recurrence of rectal cancer. Options for curative resection. *Ann Surg* 1987 ; 205 : 482-495.
15. **Wirbel RJ, Schulte M, Mutschler WE.** Surgical treatment of pelvic sarcomas : oncologic and functional outcome. *Clin Orthop Relat Res* 2001 ; 390 : 190-205.
16. **York JE, Kaczaraj A, Abi-Said D et al.** Sacral chordoma : 40-year experience at a major cancer center. *Neurosurgery* 1999 ; 44 : 74-79.