



Metatarsal Giant cell tumour in a 7-year-old child : A case report

Moez DRIDI, Safouane BEN SLAMA, Mondher M'BAREK, Mohsen TRABELSI

From the Traumatology Center, Ben Arous, Tunisia

Giant cell tumours are uncommon benign osseous neoplasias with an obscure origin. They mostly occur in the epiphyses of long bones after skeletal maturity. Occurrence in a metatarsal bone in a child less than 10 years old is quite exceptional.

The authors report a case of a 7-year-old girl with an aggressive giant cell tumour of the first metatarsal bone of her right foot. Intralesional excision by curettage and grafting with morselised iliac cortical and cancellous bone was performed. The girl is now disease free since 7 years.

Giant cell tumours in this location and age group are rare ; they appear to represent a distinct, more aggressive form of tumour. They should be considered in the differential diagnosis of a destructive bony lesion in skeletally immature patients. Curettage and bone grafting with morcelised iliac cortical and cancellous bone remains a treatment option, despite a high potential for recurrence.

Keywords : giant cell tumour ; metatarsal bone ; foot ; intralesional curettage.

population and it appears to display a more aggressive behaviour than in other locations (18).

We present a case of a giant cell tumour of the first metatarsal bone in a 7-year-old girl treated with intralesional excision by curettage and grafting.

CASE REPORT

A 7-year-old girl presented with a twelve month history of a dorsal swelling of the inner edge of the right foot which gradually increased in volume, without pain or fever or any impact on her general health. There was no history of a systemic disorder, trauma, nor presence of a foreign body.

On examination, there was a swelling over the first metatarsal bone with a firm consistency, it was painful on pressure ; the overlying skin was healthy.

A plain radiograph of the right foot showed a destructive lesion involving the entire first metatarsal bone. The cortex was very thin and had

INTRODUCTION

Giant cell tumour (GCT) is an uncommon osseous tumour usually seen at the end of a long bone after skeletal maturity (10). It is defined as a benign but locally aggressive neoplasm with a tendency for local recurrence (6). The location in the foot skeleton represents less than 1.2% of cases (18,21). The tumour is rare in patients less than fifteen years old, with an incidence of 1.7%. In this location, it occurs more often in a younger female

-
- Moez Dridi, MD, Assistant in orthopaedic surgery.
 - Safouane Ben Slama, MD, Assistant in orthopaedic surgery.
 - Mondher M'Barek, MD, Professor in orthopaedic surgery.
 - Mohsen Trabelsi, MD, Professor in orthopaedic surgery.
Department of Orthopaedic surgery and Traumatology, Ben Arous, Tunisia.
- Correspondence : Moez Dridi, 131 avenue Louis Braille, Cité el Khadra, 1003 Tunis Tunisia.
E mail : moez.dridi@voila.fr
© 2011, Acta Orthopædica Belgica.
-

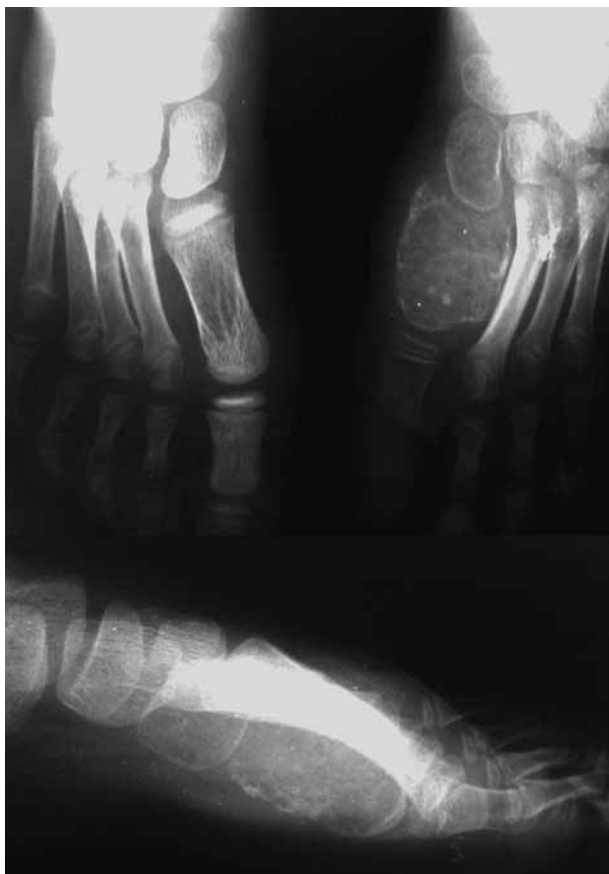

Fig. 1. — A destructive lesion involving the entire right first metatarsal bone with a very thin cortex fractured at places and no periosteal reaction or new bone formation.

a blown-up appearance with several microfractures. Adjacent soft tissue swelling was also noted. There was no periosteal reaction or new bone formation (Fig. 1). Chest radiographs and laboratory tests, including serum calcium and phosphorus levels, were normal.

Given this suspicious aspect, an intralesional curettage of the tumour was performed with packing of the cavity with cortico-cancellous grafts taken from the ipsilateral iliac crest. The pathologic specimen revealed a solid tissue characteristic of giant-cell tumour of bone with typical giant cells and frequent areas of necrosis (Fig. 2).

After 7 years follow-up, the patient was still disease free. A plain radiograph of the right foot showed (Fig. 3) bony filling of the cavity with no evidence of local recurrence but with premature




Fig. 2. — Histology showing typical giant cells and frequent areas of necrosis characteristic of giant-cell tumour of bone.

closure of the growth plate responsible for a shortening of the first metatarsal, however without functional or cosmetic problems.

Gradual lengthening of the first metatarsal bone combined with shortening osteotomies of the other metatarsals can be considered in the future according to the clinical or functional discomfort.

DISCUSSION

The incidence of GCT is highest in the second to fourth decade of life with a peak in the third; only about 1.2% of GCT's occur in the first decade of life (18,21). Picci *et al* (18) reported an incidence of 1.8% of patients under 10 years of age from a series of 326 cases of GCT. Goldenberg *et al* (7) reported one case in a 13-year-old girl in a series of 218 GCT's. However the incidence of skeletally immature patients can be as high as 7.5% (15).

GCT's typically affect the epiphysis and the metaphyseal-epiphyseal region of long bones. Lesions affecting only the metaphysis are rare. More than half of the GCT's occur around the knee joint, most often in the distal femur and proximal tibia, followed by the distal radius and the sacrum (5). GCT's tend, however, to be metaphyseal in skeletally immature patients (11,18). Phalanges, metacarpals, and metatarsals are rarely affected (2,3,12,21). Between 2% and 4% of tumours arise in the small bones of the foot (3,16,17), and approximately 50% of these are seen in the talus (2,9,12,17).

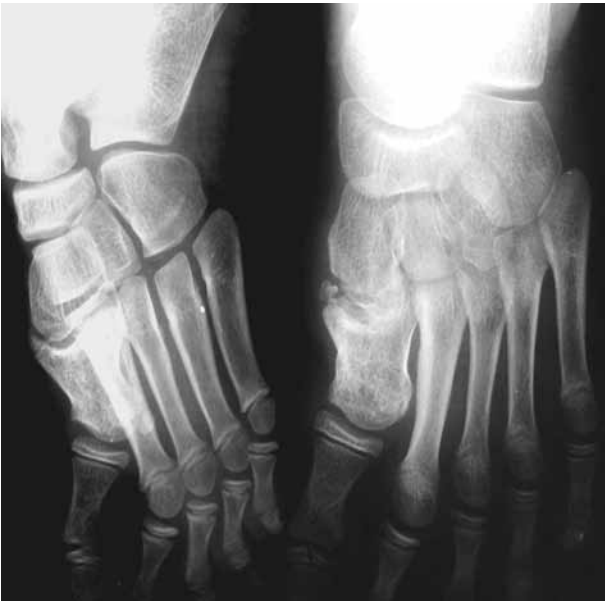

Fig. 3. — Radiograph of the right foot after 7 years follow-up showing filling of the tumour cavity with no evidence of local recurrence but with premature closure of the growth plate responsible for shortening of the first metatarsal.

Giant cell tumours in the foot are known to occur in a younger age group, more often in females and they tend to have a more aggressive behaviour both clinically and radiologically than in other locations (3,9,12,21).

They usually present with pain and swelling of the foot; symptoms are rapidly progressive and the diagnosis is frequently delayed as symptoms may initially be attributed to non-specific foot pathology (6,9,17,20). In tubular bones, the radiological differential diagnosis includes aneurysmal bone cyst, nonossifying fibroma and chondroblastoma (1,6,9,19).

Conventional radiographs of GTC's in long bones show a lytic lesion centred in the epiphysis but involving the metaphysis and extending at least in part to the adjacent articular cortex, no periosteal reaction is seen unless a fracture is present (3,6). However, the radiographic features of giant cell tumours at sites other than long bones are non-specific and are not unlike other osteolytic processes (8,14).

Histologically, it is important to differentiate these tumours from other giant-cell containing lesions of the foot such as giant cell reparative granuloma, aneurysmal bone cyst and chondroblastoma (4,8,9). The histological diagnosis of giant cell tumours relies on the fact that the giant cell component has a uniform distribution in a mononuclear round-oval stromal cell background (13).

The current treatment is curettage and cryotherapy with methacrylate filling, which is associated with a recurrence rate of 2%-25% (12). Radiation therapy can be associated with sarcomatous transformation and is recommended only in inoperable cases. Because of the increased aggressiveness of giant cell tumours in the foot, en bloc resection of the involved bone segment (12,21) or a wide local excision by an extensive curettage is indicated, with or without packing the cavity following tumour excision with morselised iliac cortical and cancellous bone (4), or with acrylic cement. This is considered to be a safe and effective initial treatment, providing immediate stability for early rehabilitation (21). Intralesional excision however, leaves microscopic disease in the bone, which is a major factor for local recurrence; the reported incidence of local recurrence with this technique has been as high as 40-60% (3,8,13,17). A great deal of effort has been done to optimise removal of tumourous tissue following curettage, by chemical (phenol, chlorpactin, ...) or physical means to decrease recurrence rate by inducing necrosis of any remaining neoplastic tissue. If recurrence occurs, this is usually within the first 3 years after initial therapy (2,6,15).

CONCLUSION

Giant-cell tumour of bone mainly occurs in adults and is rarely found in skeletally immature patients. Metatarsal bones of the foot are a very rare location of giant cell tumours. Giant cell tumours in the foot are seen predominantly in females and in younger patients and show a more aggressive behaviour.

The treatment of choice is aggressive curettage or en bloc resection because of the higher rate of local recurrence.

REFERENCES

1. **Bahalaik V, Anand S, Anderton JM.** Giant cell tumour of the cuboid. A case report. *Foot* 2001 ; 11 : 94-96.
2. **Bapat MR, Narlawar RS, Pimple MK, Bhosale PB.** Giant cell tumor of talar body. *J Postgrad Med* 2000 ; 46 : 110-111.
3. **Biscaglia R, Bacchini P, Bertoni F.** Giant cell tumor of the bones of the hand and foot. *Cancer* 2000 ; 88 : 2022-2032.
4. **Burns TP, Weiss M, Snyder M, Hopson CN.** Giant cell tumor of the metatarsal. *Foot And Ankle* 1988 ; 8 : 223-226.
5. **Campanacci M, Balldini N, Boriani S, Sudanese A.** Giant cell tumour of bone. *J Bone Joint Surg* 1987 ; 69-A : 106-114.
6. **Dridi M, Annabi H, Ben Ghazlen R, Abdelkefi M, Trabelsi M.** Giant cell tumour of a phalanx in the foot : A case report. *Acta Orthop Belg* 2008 ; 74 : 273-275.
7. **Goldenberg RR, Campbell CJ, Bonfiglio M.** Giant-Cell Tumor of bone : an analysis of two hundred and eighteen cases. *J Bone Joint Surg* 1970 ; 52-A : 619-664.
8. **Gouin F, Grimaud E, Redini F et al.** Metatarsal giant cell tumors and giant cell reparative granuloma are similar entities. *Clin Orthop Relat Res* 2003 ; 416 : 278-284.
9. **Huda N, Bhardwaj S, Abbas M, Asif N.** Giant cell reaction of a metatarsal bone : a case report. *Acta Orthop Belg* 2007 ; 73 : 279-281.
10. **Baker JF, Perera A, Kiely PD, Lui DF, Stephens MM.** Giant cell tumour in the foot of a skeletally immature girl : a case report. *J Orthop Surg* 2009 ; 17 : 248-250.
11. **Kransdorf MJ, Sweet DE, Buetow PC, Giudici MA, Moser RP.** Giant cell tumor in skeletally immature patients. *Radiology* 1992 ; 184 : 233-237.
12. **Ly JQ, Arnett GW, Beall DP.** Giant cell tumor of the second metatarsal. *Radiology* 2007 ; 245 : 288-291.
13. **Manfrini M, Stagni C, Ceruso M, Mercuri M.** Fibular autograft and silicone implant arthroplasty after resection of giant cell tumor of the metacarpal. A case report with 9 year follow-up. *Acta Orthop Scand* 2004 ; 75 : 779-781.
14. **Mendicino SS.** Giant cell tumor of the first metatarsal bone en bloc resection with autogenous fibular strut graft. *J Foot Ankle Surg* 1993 ; 32 : 405-410.
15. **Morgan JD, Eady JL.** Giant cell tumor and the skeletally immature patient. *J South Orthop Assoc* 1999 ; 8 : 275-284.
16. **Muscolo DL, Ayerza MA, Aponte-Tinao LA.** Giant cell tumours of bone. *Current Orthop* 2001 ; 15 : 41-50.
17. **O'Keefe RJ, O'Donnell RJ, Temple HT et al.** Giant cell tumor of bone in the foot and ankle. *Foot Ankle Int* 1995 ; 16 : 617-623.
18. **Picci P, Manfrini M, Zucchi V et al.** Giant-cell tumor of bone in skeletally immature patients. *J Bone Joint Surg* 1983 ; 65-A : 486-490.
19. **Richard TD, James AP, Lee WM.** Giant-Cell Reaction of Bone : report of two cases. *J Bone Joint Surg* 1972 ; 54-A : 1267-1271.
20. **Scully SP, Mott MP, Temple HT et al.** Late recurrence of giant cell tumor of bone. A report of four cases. *J Bone Joint Surg* 1994 ; 76-A : 1231-1233.
21. **Turcotte RE.** Giant cell tumor of bone. *Orthop Clin North Am* 2006 ; 37 : 35-51.