



Outcome of arthroscopic rotator cuff repair in large tears : The exposed footprint

Eduard BUESS, Bernhard WAIBL, Robert SEIDNER, Stefan WERLEN

From the "Shouldercare Institute", Sonnenhof Hospital, Berne, Switzerland

The purpose of this retrospective study was to evaluate the clinical results of arthroscopic single-row repair in large rotator cuff tears. Selection was based on the extent of the "exposed footprint" (EFP) obtained by adding up the width of the subscapularis tear and the width of the supra/infraspinatus tear. Three groups were studied : Type I had an EFP of less than 5 cm ; Type II had an EFP of 5 cm or more ; tears allowing only partial repair were studied separately. During a period of nearly three years (in 2002-04) 49 shoulders complied with our selection. There were 25 type I and 24 type II tears. Subscapularis tears were found in 32/49 shoulders (65%) ; 10 shoulders (20%) had only partial repair. At an average follow-up of 33 months, all patients were subjected to an outcome assessment using the VAS, the Simple Shoulder Test (SST), Constant score (CS) and strength measurement. A near normal shoulder function (11-12 Yes-answers in the SST) was obtained in 68% of the patients with type I tears, compared to 33% of type II tears ($p = 0.02$). The adjusted CS for patients with a type I tear was 88%, compared to 77% for patients with a type II ($p = 0.01$) ; strength was 69% for type I and 36% for type II shoulders ($p = 0.001$).

After arthroscopic single-row and margin-convergence repair, a near normal shoulder function was obtained in two-thirds of the shoulders with an EFP of up to 5 cm. When the EFP was larger, this outcome was achieved in only one-third of the shoulders.

Keywords : shoulder arthroscopy ; rotator cuff ; massive tear ; footprint.

INTRODUCTION

Controversy persists regarding the most appropriate treatment modality for large and massive rotator cuff tears, ranging from conservative symptomatic treatment to various surgical options like open repair (1), arthroscopic repair (2), partial repair (7), muscle transfers (14) or arthroscopic debridement (19). The "classical" literature regarding open repair (8) showed somewhat discouraging results.

Burkhart (7) proposed a biomechanical concept, to achieve strain reduction at the tear margins. The concept of "margin convergence" was popularized, wherein arthroscopy offered a much better opportunity to visualize the complex patterns of large and massive cuff tears than open surgeons could have dreamed of. Arthroscopy also revealed that subscapularis tears were much more frequent than believed earlier (3). The role of the subscapularis as an anterior counterpart to the posterior cuff found

-
- Eduard Buess, MD, Shoulder Surgeon.
 - Bernhard Waibl, MD, Orthopaedic Surgeon.
Schulthess Clinic, Zurich, Switzerland.
 - Robert Seidner, MD, Orthopaedic Surgeon.
Spital Schwyz, Switzerland.
 - Stefan Werlen MD, Radiologist.
Sonnenhof Clinic, Berne, Switzerland.

Correspondence : Eduard Buess, MD, CH-3012 Berne, Switzerland. E-mail : ebuess@shoulder-care.ch
© 2011, Acta Orthopædica Belgica.

increasing acceptance as a key element in shoulder function (7,14,16). For this reason, we introduced a new measurement of tear extension termed the “exposed footprint” (EFP), which defines the extent of the transverse tear diameter of the combined posterosuperior and anterior cuff.

The purpose of this retrospective study was to evaluate the clinical results of arthroscopic single-row repair in large and massive rotator cuff tears. Our basic repair principles were 3 fold: To use margin convergence whenever possible; to repair all subscapularis tears; and to balance the transverse plane force couple through partial repair, if complete repair was not feasible. We tested the following hypothesis:

- A good outcome with near normal shoulder function can be expected in most cases of tears of less than 5 cm of EFP.
- A moderate outcome with good pain relief but reduced function and strength can be expected in tears of 5 cm or more of EFP and in partial repairs.

MATERIAL AND METHODS

Between March 2002 and November 2004 a total of 240 rotator cuff repairs were performed by the first author. A retrospective consecutive case series study was undertaken of 53 shoulders in 50 patients with a massive tear (i.e. 22% of 240 repairs). Large and massive tears were tears of the supra/infraspinatus tendon unit with a largest diameter according to DeOrio and Cofield (11) of at least 3.5 cm, or 3 cm tears of the supra/infraspinatus complex with additional involvement of the subscapularis tendon. Forty-nine operated shoulders in 46 patients were retained in the study cohort; 4 patients (4 shoulders) were excluded from further evaluation. Three of them had been reoperated since the index surgery (2 reversed prostheses and 1 latissimus dorsi transfer), one patient reruptured her cuff as a consequence of a new trauma.

Mean age of the 20 female and 26 male patients was 61 years (range: 32-79) at operation. The follow-up period ranged from 18 to 56 months, with an average of 33 months. Clinical information was available from the patient's charts, the operating protocol and video prints. All patients except one had a preoperative MRI. All 49 shoulders were examined by an independent examin-

er; there were no drop outs. As an outcome measuring tool we used a Visual Analog Scale (VAS) for pain (0 = no pain, 10 = maximum pain), the Simple Shoulder Test (SST) (17) the Constant score (CS) (9) and an electronic strength measurement with the Isobex device. The SST was collected in the same precisely translated German version, that we have found reliable in previous investigations (3,4).

An independent radiologist, experienced in musculoskeletal MRI and blinded to clinical details, reviewed the 43 available preoperative MRI scans and graded fatty degeneration in the muscle units of the supraspinatus, infraspinatus and subscapularis into one of five stages. He used an MRI adaptation as suggested by Fuchs *et al* (12) of the original CT staging by Goutallier: stage 0 being normal muscle; 1: some fatty streaks; 2: infiltration, but still more muscle than fat; 3: as much fat as muscle; 4: more fat than muscle.

Surgical technique (Fig. 1-3)

All operations were performed in beach-chair position. After debridement, the tears were classified into crescent-, U- or L-shaped (6). The tear size of the supra/infraspinatus tendon unit was determined with a hook probe in steps of 0.5 cm in the anteroposterior and mediolateral direction. Retraction to the glenoid rim was assigned a value of to 3.5 cm of mediolateral extension. After performing the releases and before attaching the tendon to the cancellous bone bed of the greater tuberosity, we applied side-to-side (“margin convergence”) stitches whenever possible (Fig. 1). For cuff attachment to bone we used Mitek Super Anchors and reversed mattress stitches (Fig. 2). As a suture material we used No 3 Ethibond or No 2 Fiberwire. The procedure was concluded with a moderate acromioplasty, except for those tears in which only partial repair was possible. Partial repair included subscapularis repair to the lesser tuberosity, margin convergence stitches as possible without undue tension and refixation of the remaining posterior cuff shifting the tissue anterosuperiorly (Fig. 3). Thirty-two shoulders had relevant subscapularis tears, that were fixed with 1-2 Anchors carefully preserving the comm-sign. Additional procedures included: 18 biceps tenodeses and 7 tenotomies, 5 SLAP repairs and 2 AC resections.

Tear size classification – exposed footprint (Fig. 4)

We estimated the size of the subscapularis tear according to the following intraoperative criteria: 1cm for a small

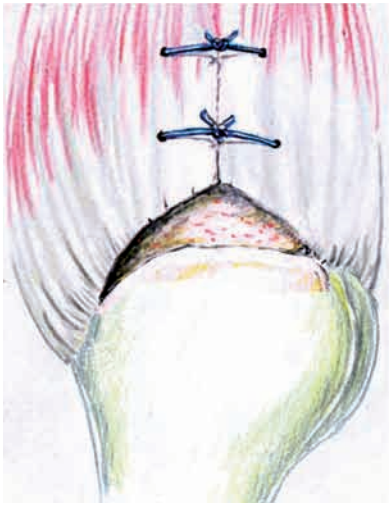

Fig. 1. — Margin convergence repair (U- or L-shape tears) reducing strain on tear margins.

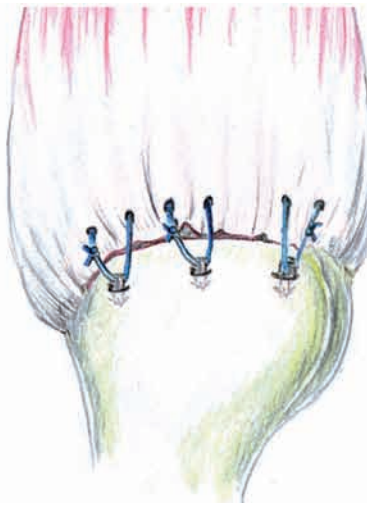


Fig. 2. — Single-row repair to the prepared bone bed (crescent-shape tears).

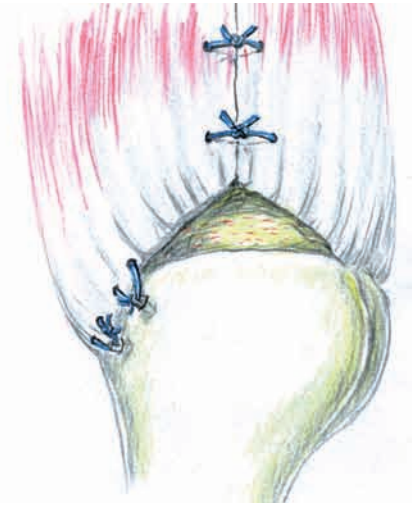

Fig. 3. — Partial repair : margin convergence and posterior leaf reattachment.

partial tear ; 2 cm for an extended partial tear ; 3 cm for a complete tear with a retracted comma sign. This estimation was based on the assumption of a subscapularis footprint measuring 2.6-4 cm in width as supported by the literature (6,10,16). In order to classify the combined antero-postero-superior rotator cuff tears, we applied the term of the “exposed footprint” (EFP) by adding up the width of the subscapularis tear and the transverse diameter of the supra/infraspinatus tear. As an example, a 3 cm wide supra/infraspinatus tear with a 2 cm subscapularis tear would be classified as a tear with an EFP of 5 cm (Fig. 4). For further analysis, the tears were divided into three groups according to size and repairability :

- a) Type I : tears with an EFP of less than 5 cm.
- b) Type II : tear with an EFP equal to or more than 5 cm.
- c) Retracted tears allowing only partial repair. With one exception all these cases were Type II tears.

Statistics

Statistical analyses were performed with the help of the mathematics department of the University of Fribourg. The ANOVA test was done for normally distributed data. The Wilcoxon/Kruskal-Wallis test was used to determine differences between groups in case of a non-parametric distribution of the data. The level of significance was set at $p < 0.05$. All results are expressed as the mean and the standard deviation.

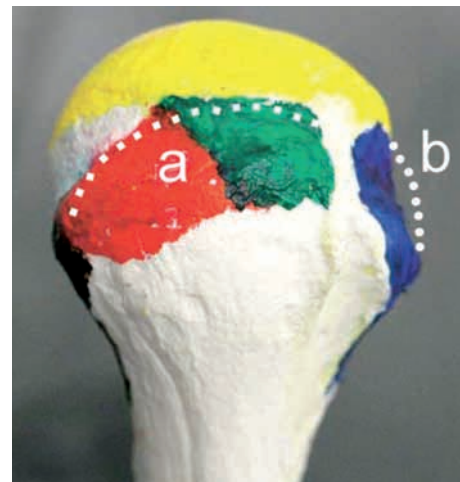


Fig. 4. — Measurement of the “exposed footprint” :
 a) Posterosuperior tear width ;
 b) Subscapularis tear width
 $a + b = \text{EFP}$
 with permission from Curtis, ref. 10 (dotted line added by authors).

RESULTS

Tear size and technique

The mean transverse tear size including the subscapularis (= EFP, Fig. 4) averaged 4.8 cm (range :

Table I. — Age, Sex and Tear Size Distribution

	Type I (EFP < 5 cm)	Type II (EFP > 5 cm)	Partial repair
Number of shoulders	25	24	10
Age (years)	59 (\pm 1.9)	62 (\pm 1.9)	63 (\pm 2.4)
Sex (f/m)	8/17	13/11	6/4
Tear size (EFP in cm)	3.5 (\pm .16)	6.1 (\pm .17)	6.1 (\pm .44)

Values are given as mean \pm SD.

Table II. — Clinical results

	Type I (EFP < 5 cm)	Type II (EFP > 5 cm)	Partial repair
Pain reduction (points on VAS 10)	6.8 (\pm 0.41)	7.5 (\pm 0.42)	7.7 (\pm 0.66)
Yes answers in SST	10.3 (\pm 0.59)*	8.3 (\pm 0.61)*	6.8 (\pm 0.91)*
Adjusted CS (%)	88 (\pm 3.5)*	77 (\pm 3.6)*	71 (\pm 5.5)*
Adjusted strength (%)	69 (\pm 6.1)*	36 (\pm 6.3)*	25 (\pm 10.2)*

Values are given as mean \pm SD.

* $p < 0.05$.

3.0 to 8.0 cm, \pm 1.53). The mean supra/infraspinatus tear size based on the measurement of the greatest diameter (Fig. 5) was 3.8 cm (range : 3.0 to 5.0 cm, \pm .70). There were 25 shoulders with a type I tear of less than 5 cm EFP and 24 shoulders with a type II tear equal to or more than 5 cm (Table I). As for tear configuration, 20 tears were U-shaped, 11 crescent-shaped and 6 L-shaped (6).

The subscapularis was intact in 17 shoulders, while subscapularis tears were found in 32 of the 49 shoulders (i.e. 65%): A small partial tear (= 1 cm) was recorded in 12, an extended partial tear (= 2 cm) in 12 and a complete retracted tear (= 3 cm) in 8 shoulders. Eleven shoulders with tears of 3 cm of largest diameter were included only because of having an additional subscapularis tear. Of the 38 shoulders included because of a tear diameter of 3.5 cm or more, 21 (i.e. 55%) had an additional subscapularis tear. Among the overall number of 240 rotator cuff repairs of all sizes performed over the study period, a total of 85 (i.e. 35%) had a subscapularis tear needing anchor fixation.

On average, 2.8 anchors (range 1 to 6) were used per shoulder for repairing the cuff tendons. Margin convergence was used in 42 of the 49 cases (86%)

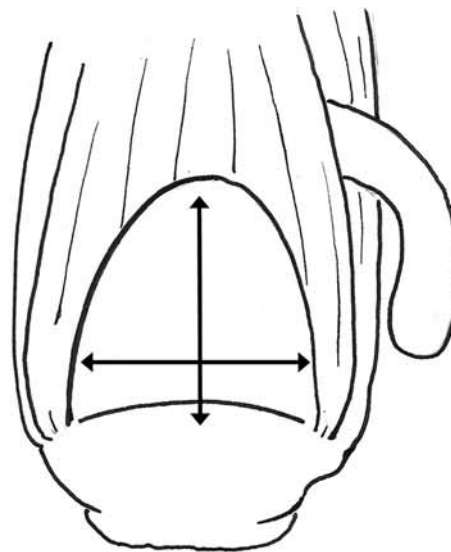


Fig. 5. — Measurement of greatest tear diameter of supra/infraspinatus with probe.

with 1-3 transverse stitches. In 10 of the 49 operated shoulders (20%) only partial repairs were possible. In these retracted tears, after mobilization and repair a residual defect ranging from 0.5 to 4 cm (mean 2.3 cm) was observed.

Outcome scores

Preoperative pain intensity, as expressed on the VAS10, was 8.3 (± 1.9) for all patients. Postoperatively, the pain level had decreased to 1.2 (± 1.51). Pain reduction was highly significant ($p < 0.001$) for both tear types and for partial repairs (Table II). Postoperative pain levels were 1.1 for type I, 1.4 for type II and 1.3 for partial repairs (not significant).

The number of Yes-answers in the Simple Shoulder Test (SST) averaged 9.3 postoperatively (± 3.1) for all patients. Of the patients with a type I tear 68% had a (near) normal shoulder function with 11 or 12 Yes-answers, as compared to 33% in the group with a type II tear ($p = 0.02$). Overall satisfaction rate was 94% (46 of the 49 procedures/3 not satisfied). However, inclusion of the 3 reoperated patients – considering them as failures of the index procedure – would result in a satisfaction rate of 89% (46 of 52).

All Constant score (CS) results reported are age and sex adjusted, according to the normal values given by Yian (20). Numbers are reported as a percentage, the so called “adjusted” Constant score. The mean preoperative CS for all patients was 48% (± 20 , range 4 to 83), compared to 83% (± 18 , range 31 to 105) postoperatively. Looking at the EFP, the postoperative CS for patients with a type I tear was 88% (± 3.5), compared to 77% (± 3.5) for patients with a type II tear ($p = 0.01$). Looking at reparability, postoperative CS values were 85% (± 2.8) for complete repairs, compared to 71% (± 5.5) for partial repairs ($p = 0.03$). A concomitant subscapularis tear regardless of size, did not significantly influence the CS values neither pre- nor postoperatively ($p = 0.21$ and $p = 0.52$, respectively).

Strength

Abduction strength results obtained with the Isobex are also presented age and sex adjusted using the tables given by Yian (20). Preoperative strength of the affected shoulder showed a mean of 28% (± 21) and increased to 53% (± 34.7) postoperatively ($p < 0.01$). Tear size strongly influenced postoperative strength ($p = 0.001$).

MRI

The mean degrees of fatty degeneration on the Goutallier scale of 0-4 as determined on the preoperative MRI scans are shown in table III. In the first column the table gives the average grades for the three muscles of the rotator cuff for the whole study group. Thereafter the Goutallier grades looking at the EFP and then looking at reparability are presented.

DISCUSSION

The natural history (18), patho-anatomy (22), clinical management and repair techniques (3,4,5,15,21) of rotator cuff lesions continue to be the subject of debate. Anatomic studies have shown that the anterior supraspinatus and the free intraarticular edge of the upper subscapularis on either side of the bicipital groove are the mechanically strongest tendinous areas of the rotator cuff (Fig. 6) and therefore likely to contribute most to force transmission (18,22). The infraspinatus is known to be thinner and it tapers away to become muscular inferiorly, which is also true for the inferior subscapularis (10,16). As to biomechanics, Burkhart (7) suggested the “suspension bridge model” with a cable of stronger tissue spanning from the anterior supraspinatus to the infraspinatus. In U- and L-shaped tears he recommended the principle of margin convergence (5), a principle that we have used in 86% of the present case series. For irreparable tears, Burkhart suggested to use a partial repair technique (20% in this series) instead of tendon transfers (7,14).

Looking at the rotator cuff as an anatomical and biomechanical entity, we introduced the term “exposed footprint” to classify our results. This concept is based on the assumption that most tears start in the supraspinatus and grow bigger by propagating posteriorly and anteriorly (7,22). The combined extent of such a tear in the antero-posterior direction was thought to best reflect its severity. The definition of the EFP has helped us to unify the clinical findings of different tear patterns (10,16,21) to a well established biomechanical rationale (7).

Our results show highly significant pain reduction in type I and in type II tears, as well as in partial

Table III. — Fatty degeneration according to Goutallier (preoperatively)

Goutallier grade	All shoulders	Type I	Type II	Complete repair	Partial repair
SSP	1.1	0.9	1.4	0.9	2.1
		p = 0.07		p = 0.0001	
ISP	1.2	0.7	1.8	0.4	1.9
		p = 0.002		p = 0.006	
SSC	0.7	0.3	1.2	0.9	2.6
		p = 0.01		p = 0.005	

SSP : supraspinatus ; ISP : infraspinatus ; SSC : subscapularis.

repairs ; this consistently observed phenomenon accounts for the high patient satisfaction in arthroscopic cuff repairs (21). The Simple Shoulder Test (17), a patient based tool to evaluate shoulder function (2 questions for pain, 4 for mobility, 3 for strength and 3 for function), discriminated between type I tears, type II tears and partial repairs. Assuming that 11 or 12 Yes-answers express a normal or near normal shoulder function, this goal of treatment was achieved in 68% of the patients with type I and in 33% with type II tears, but in only 20% of patients with partial repairs. The Constant score (9) as an objective shoulder evaluation tool, also showed significantly higher values of 88% for type I, than for type II tears with 77%. Post-operative strength differed even more with 69% for type I and 36% for type II tears. Fatty degeneration on MRI of the 3 rotator cuff muscles (12) was rather low in the study population as a whole. Looking at the groups, fatty degeneration of a Goutallier grade less than 1 seems to predict a type I tear and a Goutallier grade of more than 1 a type II tear. Partial repairs should be expected if the Goutallier grade is higher than 2.

When comparing our results with the literature, we realize that, due to different definitions of a massive tear and different outcome measurements, a direct comparison with other published series is difficult. Cofield (8) presented a summary of results of open cuff repairs, where 87% of the patients had pain relief, but only 77% were happy with the outcome. Bigliani *et al* (1) presented their results in a

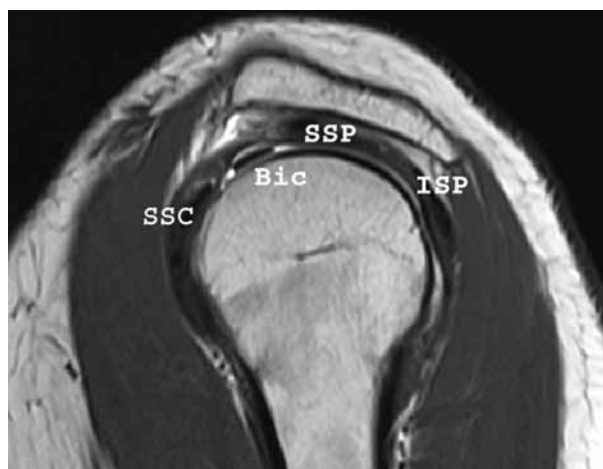

Fig. 6. — Parasagittal MRI slice close to cuff attachment illustrating the strong (black) tendinous portion of superior subscapularis (SSC) and the anterior supraspinatus (SSP) on both sides of the biceps (Bic). Posteriorly the infraspinatus (ISP).

large case series of 61 open repairs of massive tears with 85% of patients having good and excellent results. However, they did not use one of the presently accepted scoring systems. Two early series of arthroscopic repairs published in 2002 showed interesting conclusions : Bittar (2) presented 74 massive retracted tears with 83% good and excellent UCLA results and noted improved visualization and reduced morbidity as compared with open techniques. Burkhart *et al* in a review of 57 shoulders repaired arthroscopically, of which 25 had large and massive tears, reported 95% good and excellent UCLA results independent of tear size. He

considered margin convergence the key element (5). More recently the Constant score has been widely used and imaging techniques such as ultrasound and MRI are being applied more frequently. Hanusch *et al* (15) reviewed 24 patients and found an increase of the adjusted CS from 42 to 78% and a patient satisfaction of 87%. Gerber *et al* in a series of 29 massive tears (defined as a detachment of at least two entire tendons) found an increase in the adjusted CS from 49% to 85% (13).

Our results with an increase of the adjusted CS from 48% preoperatively to 83% postoperatively and an overall patient satisfaction rate of 89% match the results in the literature very well. With a percentage of 65% the subscapularis was very frequently involved in the pattern of cuff pathologies in our series. We are aware of the fact, that our 2 fold inclusion criteria introduced a selection bias in favour of subscapularis tears. But, by eliminating this bias, we still encounter as many as 55% of subscapularis tears. We believe that, in fact, in large and massive rotator cuff tears, subscapularis lesions are very frequent and likely underreported in certain studies.

Our study has the following strengths : First we were able to examine all patients that matched the inclusion criteria, reaching a follow-up rate of 100%. Secondly inclusion of all subscapularis tears and the definition of the “exposed footprint” allowed us to look at the rotator cuff as a functional entity with tears located more anteriorly or posteriorly, instead of a combination of tears of different isolated tendons. The absence of postoperative imaging data is a weakness of our study.

In conclusion, the hypothesis was confirmed that, with arthroscopic single-row and margin-convergence repair, a (near) normal shoulder function can be obtained in two-thirds of the shoulders with an EFP of up to 5 cm. If the EFP is larger, this outcome is achieved in only one-third of the cases. An EFP of 5 cm seems to be the approximate cut-off point in prognosis. For selected cases, partial repair is a valuable option.

Aknowledgement

The authors would like to thank Dr Steve Burkhart, San Antonio TX (USA), for reviewing the manuscript. The main

author is highly grateful for Dr Burkhart's teaching and continuous inspiration since 2000 ; without him this work would not have been possible. The authors also wish to thank Professor Gabriel and coworkers from the University of Fribourg (Switzerland) for their assistance in the statistical analysis of the data and to Miriam Frutiger (Berne) for the artwork.

REFERENCES

1. **Bigliani LU, Cordasco FA, Mc Ilveen SJ, Musso ES.** Operative repairs of massive cuff tears : Long-term results. *J Shoulder Elbow Surg* 1992 ; 1 : 120-130.
2. **Bittar ES.** Arthroscopic management of massive rotator cuff tears. *Arthroscopy* 2002 Suppl. 2 ; 18 :104-106.
3. **Buess E, Steuber KU, Waibl B.** Open versus arthroscopic rotator cuff repair : a comparative view of 96 cases. *Arthroscopy* 2005 ; 21 : 597-604.
4. **Buess E, Waibl B, Vogel R, Seidner R.** A comparative clinical evaluation of arthroscopic single-row versus double-row supraspinatus tendon repair. *Acta Orthop Belg* 2009 ; 75 : 588-594.
5. **Burkhart SS, Danaceau SM, Pearce CE Jr.** Arthroscopic rotator cuff repair : Analysis of results by tear size and by repair technique - margin convergence versus direct tendon-to-bone repair. *Arthroscopy* 2000 ; 17 : 905-912.
6. **Burkhart SS, Lo IK, Brady PC.** *Burkhart's View of the Shoulder : The Cowboy's Guide to advanced Shoulder Arthroscopy.* Lippincott Williams & Williams, Philadelphia, 2006, pp 81-146.
7. **Burkhart SS.** Partial repair of massive rotator cuff tears : The evolution of a concept. *Orthop Clin North Am* 1997 ; 28 : 125-132.
8. **Cofield RH.** Current concepts review : Rotator cuff disease of the shoulder. *J Bone Joint Surg* 1985 ; 67-A : 974-979.
9. **Constant CR, Murley AHG.** A clinical method of functional assessment of the shoulder. *Clin Orthop Relat Res* 1987 ; 214 : 160-164.
10. **Curtis AS, Burbank KM, Tierney JJ et al.** The insertion footprint of the rotator cuff : An anatomic study. *Arthroscopy* 2006 ; 22 : 603-609.
11. **De Orio JK, Cofield RH.** Results of a second attempt at surgical repair of a failed initial rotator-cuff repair. *J Bone Joint Surg* 1984 ; 66-A : 563-567.
12. **Fuchs B, Weishaupt D, Zanetti M et al.** Fatty degeneration of the muscles of the rotator cuff : assessment by computed tomography versus magnetic resonance imaging. *J Shoulder Elbow Surg* 1999 ; 8 : 599-605.
13. **Gerber C, Fuchs B, Hodler J.** The results of repair of massive tears of the rotator cuff. *J Bone Joint Surg* 2000 ; 82-A : 505-515.
14. **Gerber C.** Latissimus dorsi transfer for the treatment of irreparable tears of the rotator cuff. *Clin Orthop Relat Res* 1992 ; 275 : 152-160.
15. **Hanusch BC, Goodchild L, Finn P, Rangan A.** Large and massive tears of the rotator cuff : Functional outcome and

- integrity of the repair after a mini-open procedure. *J Bone Joint Surg* 2009 ; 91-B : 201-205.
16. **Ide J, Tokiyoshi A, Hirose J, Mizuta H.** An anatomic study of the subscapularis insertion to the humerus : The subscapularis footprint. *Arthroscopy* 2008 ; 24 : 749-753.
 17. **Matsen FA, Lippitt SB, Sidles JA, Harryman DTI.** Evaluating the shoulder. In : *Practical Evaluation and Management of the Shoulder*. WB Saunders, Philadelphia, 1994, pp 1-17.
 18. **Matthews TJ, Hand GC, Rees JL et al.** Pathology of the torn rotator cuff tendon. Reduction in potential for repair as tear size increases. *J Bone Joint Surg* 2006 ; 88-B : 489-495.
 19. **Rockwood CA Jr, Williams GR Jr, Burkhead WZ Jr.** Débridement of degenerative, irreparable lesions of the rotator cuff. *J Bone Joint Surg* 1995 ; 77-A : 857-866.
 20. **Yian EH, Ramappa AJ, Arneberg O, Gerber C.** The Constant score in normal shoulders. *J Shoulder Elbow Surg* 2005 ; 14 : 128-133.
 21. **Yoo JC, Ahn JH, Koh KH, Lim KS.** Rotator cuff integrity after arthroscopic repair for large tears with less-than-optimal footprint coverage. *Arthroscopy* 2009 ; 25 : 1093-1100.
 22. **Zgonis MH, Andarawis NA, Soslowsky LJ.** Mechanics and healing of rotator cuff injury. In : Abrams JS, Bell RH, eds. *Arthroscopic Rotator Cuff Surgery*. Springer, New York, 2008, pp 332-347.