



Epicondylar advancement osteotomy for flexion gap asymmetry after total knee replacement

Georg KLAMMER, Daniel A. MÜLLER, Peter P. KOCH, Dominik C. MEYER

From Balgrist Hospital, University of Zurich, Zurich, Switzerland

A possible cause for a painful total knee prosthesis is flexion gap asymmetry with medial or lateral instability despite adequate axial and rotational alignment of both components and adequate extension gap balancing. To avoid component exchange, ligament advancement techniques can be used. Soft tissue procedures carry the risk of insufficiently stable scarring. Epicondylar sliding osteotomies are accepted as a mode of collateral ligament release in severe varus or valgus knee arthroplasties. We describe a technique of anterior epicondylar advancement for the correction of symptomatic flexion gap instability.

Keywords: ligament balancing ; sliding osteotomy ; epicondylar advancement ; total knee arthroplasty ; knee.

INTRODUCTION

Symmetric flexion-extension gap balancing in total knee replacement is usually achieved with sequential lateral soft tissue release for valgus deformity and sequential medial release for varus knees and proper choice of femoral component rotation (3,5). For severe valgus deformities a lateral epicondylar sliding osteotomy has been described : it overcomes the necessity of excessive and poorly controlled release of the lateral collateral ligament and popliteus tendon, possibly leading to mediolateral instability (11). An analogous medial epicondylar osteotomy was described for the correction of varus or fixed-flexion deformities (4).

The problem of stable ligament reinsertion has been adequately solved for fixed varus deformities by means of epicondylar sliding osteotomies (2).

A lateral epicondylar osteotomy was used in the treatment of chronic posterolateral rotatory instability of the knee or as an extensile approach to the posterolateral knee (1,7).

In the evaluation of the painful total knee prosthesis one focus lies on proper gap balancing (12,13). In cases of symptomatic isolated medial or lateral instability primarily in 90° flexion and correct femoral component rotation in CT (12), a firm stop during varus-valgus testing suggests continuity of the collateral ligament. As stability testing in extension is correct, isolated contralateral soft tissue release and elevating the tibial plateau is no option. Changing the rotation of the femoral component can solve the problem, but results in considerable bone loss and a non-anatomical positioning.

-
- Georg Klammer, MD, Registrar.
 - Daniel A. Müller, MD, Resident.
 - Peter P. Koch, MD, Head of Knee Surgery.
 - Dominik C. Meyer, MD, Deputy Head of Knee Surgery.
Department of Orthopaedics, University of Zurich, Balgrist, Zurich, Switzerland.
- Correspondence : Georg Klammer, Department of Orthopaedic Surgery, Uniklinik Balgrist, Forchstrasse 340, 8008 Zürich, Switzerland.
E-mail : georg.klammer@balgrist.ch
© 2011, Acta Orthopædica Belgica.
-

Conversion to a more constrained type of knee prosthesis is a second possibility. However in both options an exchange of a prosthetic component is needed. To avoid component exchange we considered ligament advancement techniques as an alternative, given a sufficient soft tissue competence. To preserve the restored kinematics, stable soft tissue scarring is required with this type of fixation (8,9).

For the lateral side ligament tightening has been proposed by shortening osteotomy of the fibula. However this carries a risk of peroneal nerve injury and a separate skin incision may be needed (9). Krackow *et al* introduced medial or lateral ligament tightening by means of femoral periosteal capsulo-

ligamentous flap advancement or reconstruction tenodesis using semitendinosus or iliotibial band respectively (8,9). Medially Healy *et al* described a technique of femoral bone plug recession with elevation of a square bone plug reinserted in a bed 1 or 2 cm deep prepared on the epicondyle. Their technique of reconstruction led to predictably successful outcomes, but the location of the isometric reinsertion site seems challenging (6). We realised selective ligament tensioning through a sliding epicondylar osteotomy for cases with an asymmetrically loose flexion gap in the presence of a well-rotated total knee prosthesis with stability in extension (10). This technique may be used for medial or lateral laxity.

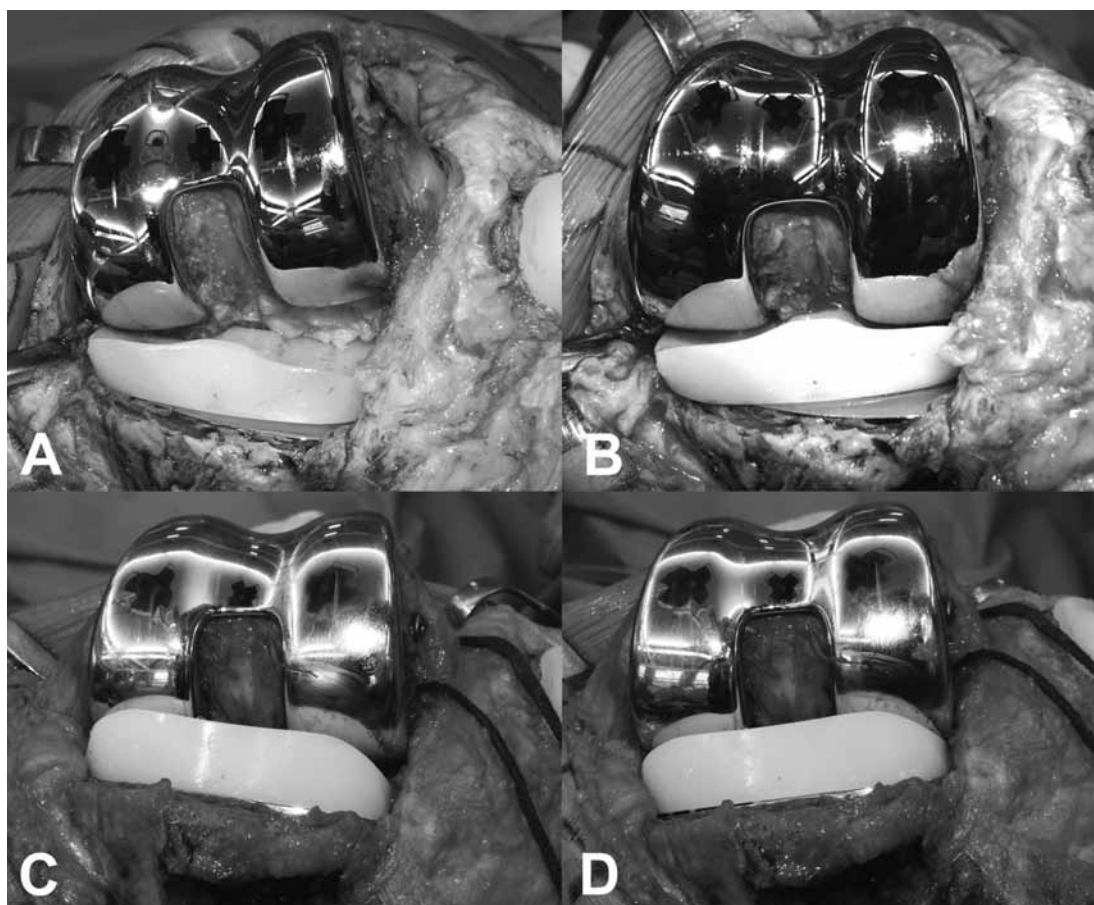


Fig. 1. — Intraoperative varus-valgus testing in 90° flexion in a patient with lateral flexion gap laxity and symmetrically stable extension gap balancing. For exposure an osteotomy of the tibial tuberosity was needed. Significant lateral joint space opening is seen with varus testing (A) while medial stability is confirmed with valgus stress (B). After restoration of the flexion gap balance by epicondylar osteotomy varus (C) and valgus (D) testing depicts symmetrical joint space opening.

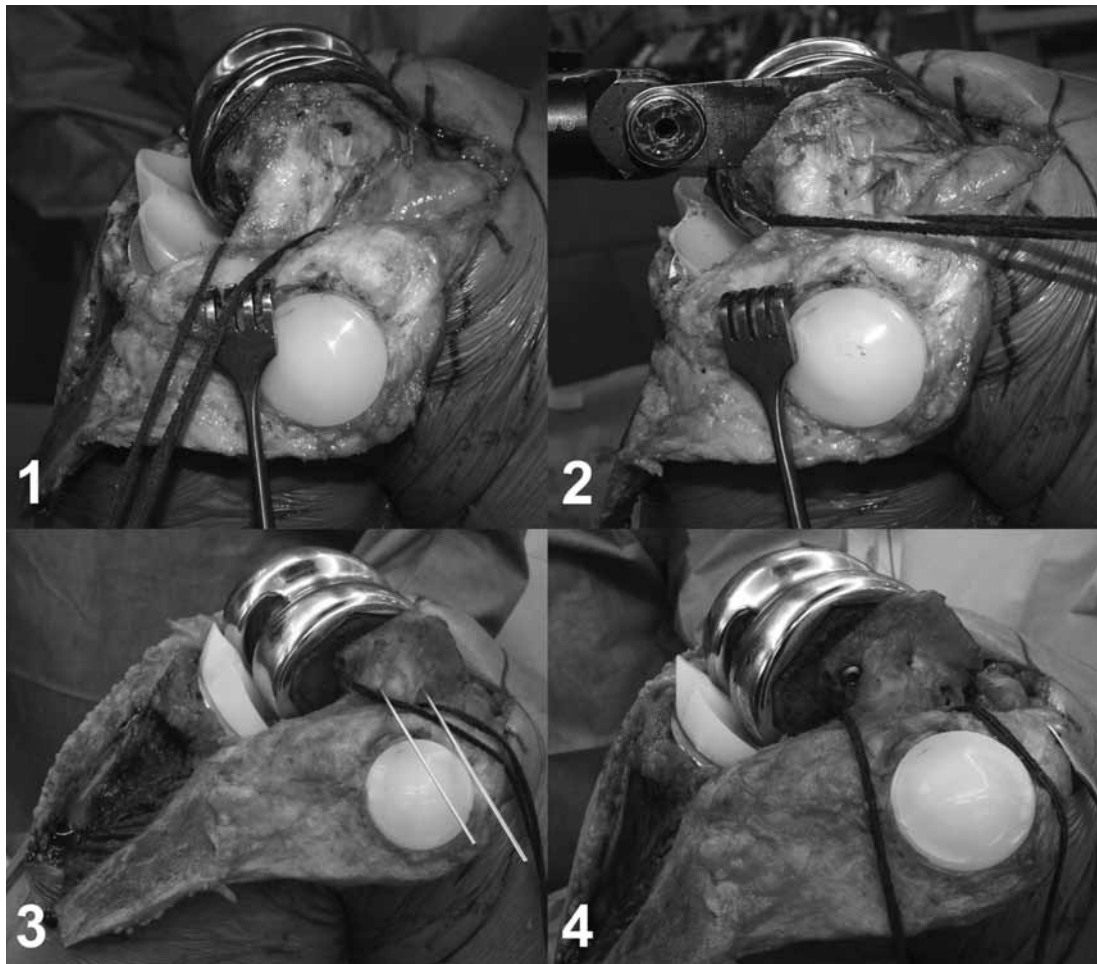


Fig. 2. — Intraoperative views of the same patient as in Figure 1. The lateral ligament complex was isolated and looped with a band. Posterior soft tissue attachments to the epicondyle were preserved (1). Sagittal epicondylar osteotomy with an oscillating saw (2). Temporary fixation with Kirschner wires after proximal advancement of the fragment to verify correct ligament balancing (3). Definitive fixation with compression screws (4). Ventrally overlapping bone is removed with chisel and saw.

Surgical Technique

Indication for a tensioning epicondylar osteotomy is given in the case of an isolated, symptomatic asymmetric flexion gap instability. Diagnosis is confirmed by stress radiologic views in 90° of flexion and full extension (12). Correct, well-aligned and stable implant position is a prerequisite and must be verified by means of CT scan and long standing views (8).

The patient is placed supine. We make use of a dynamic leg holder (Lacroix IFM, Clamart, France) as it facilitates repeated testing of varus and valgus

stability in flexion and extension. The knee is exposed using the approach used for the primary intervention for implantation of the prosthesis. Diagnosis of medial or lateral ligament instability is confirmed with varus-valgus testing in full extension and 90° flexion (Fig. 1A & B). If the continuity of the ligament can be verified the indication for epicondylar advancement is given. For sufficient exposure of the lateral epicondyle, an osteotomy of the tibial tuberosity may be required (14).

The collateral ligament is delineated and the epicondyle relieved of scar tissue. Posterior synovial and capsular attachments to the epicondyle are

preserved to maintain vascularisation (Fig. 2.1). A agittal osteotomy with an oscillating saw is performed next to the femoral implant and the fragment is mobilized (Fig. 2.2). Restoration of stability in flexion is achieved by ventralization of the epicondylar fragment. If additional tensioning in extension is needed additional proximalization may be performed. Once the point of isometry is defined the epicondyle is temporarily fixated with K-wires and correct balancing retested in flexion and extension (Fig. 2.3). For firm definitive re-fixation of the epicondyle three 3.5 mm compression screws are used (Fig. 2.4). Due to the ventral shift, bone will overlap ventrally and is thereafter removed with a chisel and saw. Before wound closure a final balance testing is done with the extensor mechanism restored (Fig. 1C & D). Wound closure is performed in a standard manner.

Early postoperative rehabilitation requires weight bearing restriction and varus-valgus protection in a brace for 6 weeks, until bone-to-bone healing has occurred. Thereafter progressive full weight bearing is allowed.

This technical note presents a surgical technique for collateral ligament advancement by means of epicondylar sliding osteotomy for restoration of ligament balance after total knee arthroplasty. Because the procedure relies on bone healing, secondary graft or scar relaxation problems as seen with soft-tissue techniques are avoided.

REFERENCES

1. **Bowers AL, Huffman GR.** Lateral femoral epicondylar osteotomy : an extensile posterolateral knee approach. *Clin Orthop Relat Res* 2008 ; 466 : 1671-1677.
2. **Brilhault J, Lautman S, Favard L, Burdin P.** Lateral femoral sliding osteotomy lateral release in total knee arthroplasty for a fixed valgus deformity. *J Bone Joint Surg* 2002 ; 84-B : 1131-1137.
3. **Dennis DA, Komistek RD, Kim RH, Sharma A.** Gap balancing versus measured resection technique for total knee arthroplasty. *Clin Orthop Relat Res* 2010 ; 468 : 102-107.
4. **Engh GA.** Medial epicondylar osteotomy : a technique used with primary and revision total knee arthroplasty to improve surgical exposure and correct varus deformity. *Instr Course Lect* 1999 ; 48 : 153-156.
5. **Fehring TK.** Rotational malalignment of the femoral component in total knee arthroplasty. *Clin Orthop Relat Res* 2000 ; 380 : 72-79.
6. **Healy WL, Iorio R, Lemos DW.** Medial reconstruction during total knee arthroplasty for severe valgus deformity. *Clin Orthop Relat Res* 1998 ; 356 : 161-169.
7. **Hughston JC, Jacobson KE.** Chronic posterolateral rotatory instability of the knee. *J Bone Joint Surg* 1985 ; 67-A : 351-359.
8. **Krackow KA.** Instability in total knee arthroplasty : loose as a goose. *J Arthroplasty* 2003 ; 18 : 45-47.
9. **Krackow KA, Phillips MJ, Mihalko WM.** Ligament advancement techniques in primary and revision total knee arthroplasty. *Techniques in Knee Surgery* 2003 ; 2 : 138-143.
10. **Matziolis G, Boenicke H, Pfiel S, Wassilew G, Perka C.** The gap technique does not rotate the femur parallel to the epicondylar axis. *Arch Orthop Trauma Surg* 2011 ; 131 : 163-166.
11. **Mullaji AB, Shetty GM.** Lateral epicondylar osteotomy using computer navigation in total knee arthroplasty for rigid valgus deformities. *J Arthroplasty* 2010 ; 25 : 166-169.
12. **Romero J, Stahelin T, Binkert C et al.** The clinical consequences of flexion gap asymmetry in total knee arthroplasty. *J Arthroplasty* 2007 ; 22 : 235-240.
13. **Sharkey PF, Hozack WJ, Rothman RH, Shastri S, Jacoby SM.** Insall Award paper. Why are total knee arthroplasties failing today ? *Clin Orthop Relat Res* 2002 : 404 : 7-13.
14. **Whiteside LA.** Exposure in difficult total knee arthroplasty using tibial tubercle osteotomy. *Clin Orthop Relat Res* 1995 : 321 : 32-35.