



Arthroscopic rotator cuff repair with platelet-rich plasma (PRP) gel : A technical note

Chris Hyunchul Jo

From SMG-SNU Boramae Medical Center, Seoul National University College of Medicine, Seoul, Korea

Evidence suggesting that platelet-rich plasma (PRP) may have a potential for augmenting tissue healing has been growing recently. However, its local application technique has not been well established. Because of saline irrigation for keeping clear vision during arthroscopic procedures, it appears unreasonable to apply PRP in liquid form. We describe a technique of PRP gel application in arthroscopic rotator cuff repair. It does not require any special instruments nor a long additional time. It can be easily performed with routine arthroscopic instruments such as a regular knot pusher, a 5.5 mm metal cannula, and a regular 8.0mm cannula. With this technique, the PRP gels could be accurately and reproducibly placed in the repair site without concerns of loss or tearing off during delivery under a direct vision without closing the inflow. We suggest that this technique could be useful for arthroscopic application of PRP gels.

Keywords : platelet-rich plasma ; rotator cuff repair ; shoulder ; arthroscopy.

cial and plastic surgery (6), it has now been perceived to enhance and accelerate repair and regeneration of a variety of tissues, including bone, cartilage, tendon, and ligament (1). While a few authors reported promising results of rotator cuff repair with PRP (2,9), description of techniques for surgical application of PRP is still very limited. In addition, as abundant saline is present during and after arthroscopic surgeries which would easily dissipate applied PRP solution, it seems reasonable to apply PRP in gel form. However, considering the cost of PRP preparation and that PRP in gel form would be fragile, an easy, reproducible arthroscopic application technique would be as crucial as preparation methods.

Here, the author describes an easily performed, reproducible arthroscopic technique for application of PRP gel without any special instruments.

INTRODUCTION

Platelet-rich plasma (PRP) is plasma that has higher than physiologic platelet content. As platelets contain various growth factors, such as PDGF, TGF- β , IGF, EGF, VEGF, and FGF, which are released from α -granules on activation, PRP has a potential to release growth factors in a significantly higher concentration than physiologic levels (1). Although PRP was first popularized in maxillofa-

■ Chris Hyunchul Jo, MD, PhD, Orthopaedic Surgeon.
Department of Orthopaedic Surgery, SMG-SNU Boramae Medical Center, Seoul National University College of Medicine, Seoul, Korea.

Correspondence : Chris Hyunchul Jo, Department of Orthopaedic Surgery, SMG-SNU Boramae Medical Center, Seoul National University College of Medicine, 41 Boramae-gil, Dongjak-gu, Seoul 156-707, Korea.

E-mail : chrisjo@snu.ac.kr

© 2011, Acta Orthopædica Belgica.

TECHNIQUE

This study was approved by the institutional review board. All arthroscopic procedures were performed with the patient in the lateral decubitus position under general anaesthesia as previously described (4). A posterior portal was established first, then an anterior portal. A systematic glenohumeral joint exploration was done and management of lesions, if necessary, was performed. The arthroscope was removed and redirected to the subacromial space. A lateral working portal and a posterolateral viewing portal were also established. Debridement of bursal tissue, subacromial and distal clavicle osteophytes was minimally performed. Extensive acromioplasty to convert a hooked or curved acromion to a flat acromion was rarely performed.

After removal of the frayed and atrophied tendon, the rotator cuff tear was carefully evaluated. If the excursion of the torn end was not enough, then tendon mobilization procedures including superior capsulotomy and coracohumeral ligament release were performed. The footprint of the greater tuberosity was debrided and only a minimal layer of cortical bone was removed. Rotator cuff repair was performed with a suture bridge technique (7). Suture anchors were inserted through an accessory portal. The numbers of anchors varied with the size of the tear. Generally, two or three anchors were used for a small and medium size tear and three to five anchors for a large and massive tear. The medial row anchors were inserted first just lateral to the articular surface of the humeral head and sutures were threaded through the rotator cuff. After threading suture of the medial row, PRP gels were applied.

Gelling of PRP was only done within one hour to surgical application with calcium gluconate (or chloride) and bovine thrombin or with calcium gluconate only. Three gels of 3 ml in volume were used for each patient (Fig. 1). First, a No.1 PDS II suture was threaded to the posterior rotator cuff tendon between the medial row and the lateral end using a suture hook near the footprint of the rotator cuff. One end of the suture was retrieved through an 8.0mm cannula in the lateral portal, and then

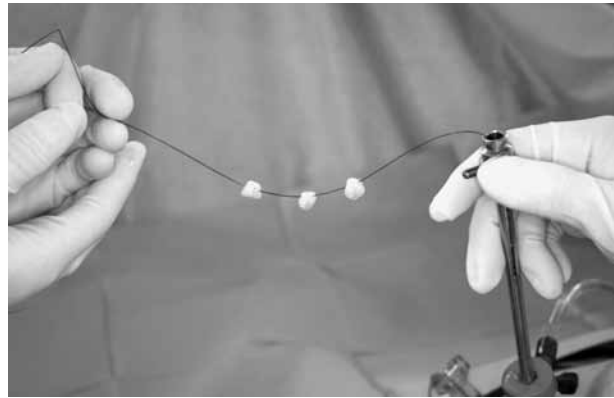


Fig. 1. — Three PRP gels of 3 ml each are threaded to a No. 1 PDS II suture, which was passed through a 5.5 mm cannula without a diaphragm. The 5.5 mm cannula should be out of the 8.0 mm cannula until the PRP gels are completely introduced into it.

through a long 5.5 mm cannula without diaphragm. Three PRP gels were threaded consecutively to the suture and introduced into the long 5.5 mm cannula (Fig. 1). With a knot pusher threaded to the suture for backing up the PRP gels, the 5.5 mm cannula was introduced into the 8.0 mm cannula, which was aimed to the repair site. As the 5.5 mm cannula reached the repair site, the knot pusher pushed the PRP gels into the site. After the PRP gels were out of the 5.5 mm cannula, the posterior suture was pulled so that the PRP gels could be placed at the repair site. Then, the knot pusher was removed quickly. While blocking the outer opening of the 5.5 mm cannula with a finger, a suture retriever was introduced via the anterior portal, passed through the anterior cuff, grabbed the suture and brought it back out of the anterior portal. Now, the 5.5 mm cannula was removed. Once the PRP gels were placed, sutures of the medial row were tied securely using the SP knot (3,5). The lateral row was secured using PushLock (Arthrex, Naples, FL), PopLok (ConMed, Largo, FL) or suture anchors. Then, the PRP gels were interposed in the tendon-bone interface (Fig. 2).

DISCUSSION

In spite of satisfactory clinical results of rotator cuff repair, there are still two major problems to be

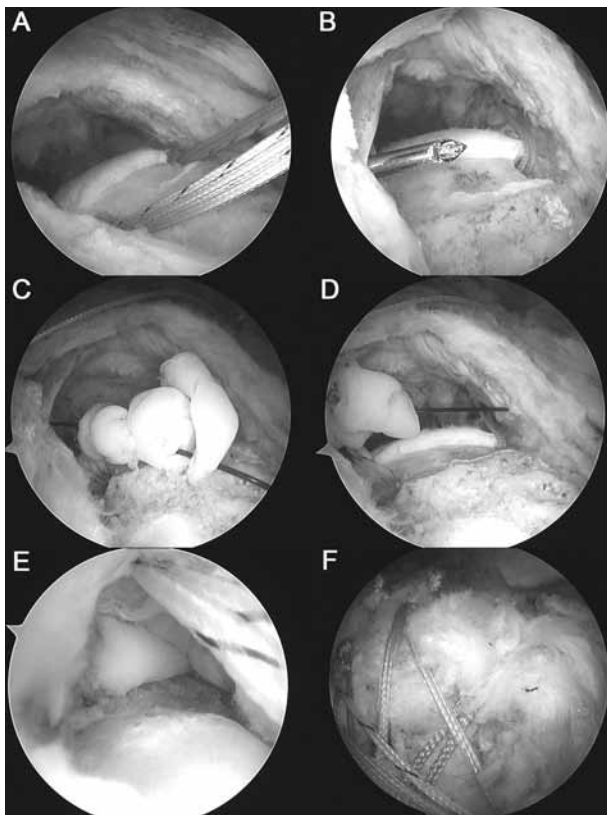


Fig. 2. — Arthroscopic views of PRP gel application ; a right shoulder from the posterolateral viewing portal in lateral decubitus position : (A) After preparation of the greater tuberosity, two suture anchors are inserted in the medial row. (B) A suture hook is introduced through the posterior portal and passed through the posterior rotator cuff tendon. (C) Three PRP gels are introduced through the 5.5 mm cannula without a diaphragm, which, in turn, is introduced into the 8.0 mm cannula. By pushing the PRP gels with a knot pusher and pulling the suture gently, they are safely placed in the repair site. (D) The other end of the suture is passed through the anterior rotator cuff tendon using a penetration instrument. (E) After tying the medial row and bringing sutures through the lateral working portal, the PRP gels are placed between the bone and the repaired tendon. (F) Using the suture bridge technique, the sutures have been secured.

solved : quality and speed of healing. Healing of the repaired tendon occurs through fibrous scar tissue rather than regeneration of a histologically normal insertion ; the scar tissue has inferior mechanical properties more susceptible to structural failure (8). This would be one of the reasons why significant rates of re-tear occurred despite advancement in biomechanical properties of the fixation of the repaired

tendon. In addition, tendon is known to heal slowly (10). Speeding up of healing would be beneficial not only for elite athletes, but also for general populations. PRP containing various kinds of growth factors may have a potential for enhancing the quality and speed of the repaired tissue, and has got a focus recently. However, evidence is scarce, especially for rotator cuff tendon (2,9).

To our knowledge, two groups of authors described techniques of application of PRP to arthroscopic rotator cuff repair. Randelli *et al* used a dedicated spray applicator kit and applied PRP in a fluid status (9). They closed the inflow and aspirated the arthroscopic fluid, and then all but the lateral cannula were removed, producing a dry sub-acromial space. Then PRP was injected while the assistants put their fingers on the portals to reduce outflow of the injected solutions for one minute. A dry arthroscopic check was performed after introducing about 100 ml of air. Meanwhile, Gamradt *et al* applied PRP in a status of gel (2). They threaded PRP gel to a limb of a suture from the anchor, passed and delivered PRP gel to the anchor with a knot pusher so that the PRP gel was trapped in the tendon bone interface. We had thought that there were several limitations for use of either technique. First, as both reports described the application technique very briefly, it seems hard to follow their instructions. Second, we thought that application of PRP in a fluid status might not be reproducible, considering the arthroscopic surgery environment in which a large amount of saline was pumped into the shoulder joint. Closing the inflow would obscure the arthroscopic sight, consequently the injection might actually be done blindly. In addition, closing the inflow does not necessarily mean no flow in the repair site. Rather, bleedings and saline in the swollen tissue would continuously wash away the PRP solution significantly before clotting. Thirdly, as a suture attached to an anchor is usually a braided one with a rough surface, it seems to be difficult to safely deliver the PRP gel from the outside of a cannula to the repair site without tearing off. In addition, as the PRP gel was threaded to a limb of the suture anchor, it was also difficult to be accurately placed in the repair site, e.g. in the middle of the width of the greater tuberosity.

The current technique has been safely and reproducibly performed in our institution for several years for a number of patients. As PRP was used in a status of gel, an exact amount of PRP, that means a desired amount of platelets and growth factors, could be placed in the repair site without any concern of loss during delivery. The current technique could accurately place PRP gels to the repair site without a concern of tearing off during delivery from outside to inside. It is rarely necessary to close the inflow during delivery. Finally, with this technique, no special instrument is necessary.

In conclusion, as evidence has been growing that PRP could possess a potential for augmenting tissue healing, effects of PRP application upon rotator cuff repair should be critically examined for its efficacy and safety. For this purpose, we believe that our technique of PRP gel application would be useful.

Acknowledgement

This study was supported by grant n° 04-2008-0660 from the SNUH Research Fund.

REFERENCES

1. **Everts PA, Knape JT, Weibrich G et al.** Platelet-rich plasma and platelet gel : a review. *J Extra Corpor Technol* 2006 ; 38 : 174-187.
2. **Gamradt SC, Rodeo SA, Warren RF.** Platelet Rich Plasma in rotator cuff repair. *Techniques in Orthopaedics* 2007 ; 22 : 26-33.
3. **Jo CH, Lee JH, Kang SB et al.** Optimal configuration of arthroscopic sliding knots backed up with multiple half-hitches. *Knee Surg Sports Traumatol Arthrosc* 2008 ; 16 : 787-793.
4. **Jo CH, Yoon KS, Lee JH et al.** The effect of multiple channeling on the structural integrity of repaired rotator cuff. *Knee Surg Sports Traumatol Arthrosc* 2011 April 30 (Epub ahead of print).
5. **Jo CH, Yoon KS, Lee JH, Kang SB, Lee MC.** The slippage-proof knot : a new, nonstacking, arthroscopic, sliding locking knot with a lag bight. *Orthopaedics* 2007 ; 30 : 349-350.
6. **Marx RE, Carlson ER, Eichstaedt RM et al.** Platelet-rich plasma : Growth factor enhancement for bone grafts. *Oral Surg Oral Med Oral Pathol Oral Radiol Endod* 1998 ; 85 : 638-646.
7. **Park M, Elattrache N, Ahmad C, Tibone JE.** "Transosseous-Equivalent" rotator cuff repair technique. *Arthroscopy* 2006 ; 22 : 1360.e1361-1360.e1365.
8. **Proctor CS, Jackson DW, Simon TM.** Characterization of the repair tissue after removal of the central one-third of the patellar ligament. An experimental study in a goat model. *J Bone Joint Surg* 1997 ; 79-A : 997-1006.
9. **Randelli PS, Arrigoni P, Cabitza P, Volpi P, Maffulli N.** Autologous platelet rich plasma for arthroscopic rotator cuff repair. A pilot study. *Disability & Rehabilitation* 2008 ; 30 : 1584-1589.
10. **Sampson S, Gerhardt M, Mandelbaum B.** Platelet rich plasma injection grafts for musculoskeletal injuries : a review. *Current Reviews in Musculoskeletal Medicine* 2008 ; 1 : 165-174.