



## Precision of preoperative digital templating in total hip arthroplasty

Turgay EFE, Bilal Farouk EL ZAYAT, Thomas J. HEYSE, Nina TIMMESFELD, Susanne FUCHS-WINKELMANN, Jan SCHMITT

*From the University Hospital Marburg, Germany*

The purpose of the present study was to evaluate the precision of digital templating in total hip arthroplasty (THA) and the influence of the surgeons' level of experience on the accuracy of preoperative planning. A retrospective review of digital computer planned THA's was performed on 169 hips. The preoperatively planned component sizes were compared to the sizes used in the operation. An exact agreement between planned and actually used size was achieved in 33.7% of the hips for the acetabular cups and 36% for the femoral stems. A prediction of +/- 1 size was reached in 77.5% for acetabular components and 82.3% for the femoral stem. On average, the acetabular components were planned approximately 0.9 sizes too large, the femoral stems 0.3 sizes too small. The accuracy of preoperative planning showed no differences according to the level of training of the planning surgeon. We state that the digital templating is useful to predict the implant size. However, 15 of the 169 planned components showed a difference of more than 2 sizes. Therefore, digital templating cannot fully replace intraoperative X-ray use.

**Keywords :** total hip arthroplasty ; accuracy ; preoperative planning.

### INTRODUCTION

Total hip arthroplasty (THA) is a proven and well-established method in the treatment of advanced degenerative joint disease. According to the German Federal Office for Quality Assurance (BQS), in 2008, there were 156,887 primary hip prosthesis implantations performed in Germany.

For the successful use of THA exact placement of the components is necessary. Already Charnley (4) and Müller (15) have supported preoperative templating. The fundamental goal of preoperative planning is to assess the implant size to be used and to anticipate potential intraoperative problems (3,8). Inadequate planning can lead to several complications, including fractures, dislocation, insufficient offset, limb length discrepancy and failure of ingrowth (10,12,26). In former times preoperative planning had been performed with drawings on transparencies of magnified components (13). Currently, picture archiving and communication system (PACS) and digital radiography are replacing conventional X-ray films. As most radiographs

- 
- Turgay Efe, MD, Consultant orthopaedic surgeon.
  - Bilal Farouk El Zayat, MD, Consultant orthopaedic surgeon.
  - Thomas J Heyse, Consultant orthopaedic surgeon.
  - Susanne Fuchs-Winkelmann, MD, Professor for orthopaedic surgery.
  - Jan Schmitt, Consultant orthopaedic surgeon, Assistant Professor for orthopaedic surgery.  
*Department of Orthopaedics and Rheumatology, University Hospital Marburg, Germany.*
  - Nina Timmesfeld, PhD, Epidemiologist.  
*Institute of Medical Biometry and Epidemiology, Philipps-University Marburg, Germany.*
- Correspondence : Turgay Efe, Department of Orthopaedics and Rheumatology, University Hospital Marburg, Baldingerstrasse, D-35043 Marburg, Germany.  
E-mail : efet@med.uni-marburg.de  
© 2011, Acta Orthopædica Belgica.
-

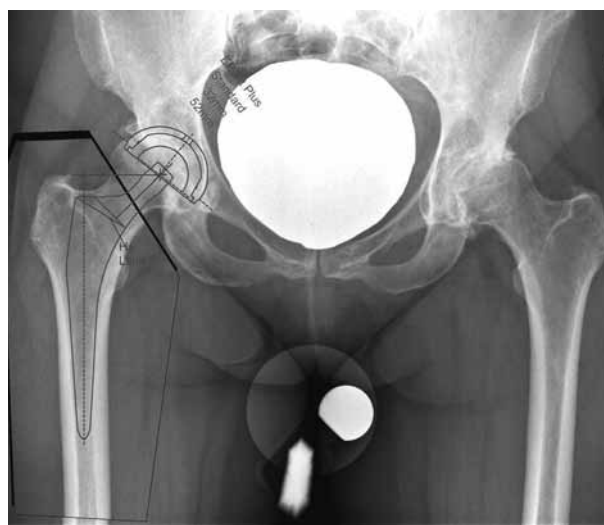
are not available in hardcopy, conventional templating is only possible to a certain extent. Computer templating of digitized radiographs is therefore, used more frequently. However, the accuracy of these tools is not fully evaluated. The aim of the present study was two-fold. First, we assessed the accuracy of computer templating in primary THA by comparing the planned and actually implanted component sizes. Second, we investigated whether surgeon experience had an influence on the preoperative planning accuracy.

### MATERIAL AND METHODS

In a retrospective approach, 169 cases of primary THA performed between 2008 and 2010 at the authors' institution were included in the present study. The indication for THA was primary osteoarthritis in 167 cases, in one case avascular necrosis of the femoral head and in one case revision surgery. There were 75 male and 94 female patients with an average age of  $68.9 \pm 9.7$  years. The left hip was involved in 76 cases and the right in the remaining 93 cases. The operative data and the hospital records were available for all patients.

To assess the accuracy of templating preoperative radiographs, digital planning, operative reports and 3-days postoperative radiographs were used. Preoperative radiographs were taken to the standard protocol including antero-posterior (ap) view of the pelvis and a lateral view of the hip. The ap views of the pelvis were taken with the patient lying flat on the table, the tube beam was placed over the pubic symphysis. The hips were internally rotated  $10^\circ$  to  $15^\circ$  to compensate for the physiologic anteversion. For the planning of THA a calibration object, a 32 mm metallic femoral head, was placed between the legs of the patients (5). Visualisation of the proximal third of the femur was necessary for full femoral stem templating. Lateral projections (Lauenstein method) was performed with the hip in  $45^\circ$  flexion and  $45^\circ$  external rotation, whereas the X-ray beam was placed on the centre of rotation of the hip. Postoperative radiographs included ap view of the hip. In all cases a standardised distance of 110 cm from the X-ray source to the digital film cassette was chosen.

Templating was performed one day before surgery by the residents of our university hospital. To evaluate whether surgeon experience had an influence on the preoperative planning precision the planners were divided into three groups with different levels of experience in hip surgery. Group I included surgeons who had



**Fig. 1.** — Preoperative planning using the mediCAD software. Anteroposterior view of the pelvis with a calibration marker, demonstrating acetabular and femoral component templating.

implanted up to 10 THAs, group II between 10 to 30 THAs and group III  $> 30$  THAs. Digital ap view of the pelvis on a picture archiving and communication system workstation were used. All of the radiographs were processed using the MediCad version 2.06 (Hectec, AltFrauenhofen, Germany). Exact acetabular position was defined as implantation of the component less than 5 mm superior to the inferior tear drop, less than 5 mm lateral to Koehler's line and at an inclination of  $40^\circ$  to  $50^\circ$  (10). The femoral stem position was defined as exact when the stem had full cortical contact in the metaphyseal-diaphyseal junction and the centre of rotation was perpendicular to the tip of the greater trochanter (Fig. 1). On the acetabular side, 162 uncemented EP-FIT-PLUS (Smith&Nephew, Schenefeld, Germany) and 7 cemented Wagner (Smith&Nephew, Schenefeld, Germany) acetabular components were used. The femoral stems included 129 uncemented Polar stems, 33 cemented Polar stems and 7 uncemented Proxy Plus stems (Smith&Nephew, Schenefeld, Germany). For the acetabular cups there was a 2 mm diameter difference between the sizes, for the femoral prosthesis stems the size differences were not uniform.

In 166 cases the transgluteal approach as described by Bauer *et al* (1), in three cases an anterolateral approach as described by Bertin and Röttinger (2) was used. The femoral neck was exposed and the hip dislocated. As planned in the preoperative template, the femoral neck was osteotomised approximately 1.5 cm above the lesser

trochanter. Generally, we used a 28 mm or 32 mm diameter femoral head component depending on the acetabular cup size. According to the manufacturer's guidelines a 28 mm head was used when the acetabular cup was between 44 and 48 mm, whereas a 32 mm femoral head was used in cases in which the acetabular component was 50 mm or greater. The liner was made of cross-linked polyethylene in all cases. The femoral canal was prepared using the rasps of the system until a stable situation was achieved. The cemented devices were implanted using a modern vacuum cementing technique. After implantation of the trial components, intraoperative C-arm radiography was performed. Additionally, secondary measurements (leg-to-leg control, stability tests) were performed to control the tensioning of the surrounding soft tissues. In case of a free range of motion and no dislocation tendency the original components were implanted.

## STATISTICAL ANALYSIS

Descriptive analysis was performed by determination of values, mean and standard deviation. All calculations were performed with the statistical software R, version 2.12.1 (<http://www.r-project.org>).

## RESULTS

There were no intraoperative fractures or postoperative dislocations. The acetabular component was implanted exactly as planned in 33.7% of cases. A difference of +/- 1 size was achieved in 77.5% of the cases. In 10 cases the use of a component with a size difference of more than 2 sizes was recorded. On average acetabular cups were planned 0.9 size too large. The exact femoral stem size was predicted in 36.0%. The femoral stems were within +/-1 size in 82.3%. In 5 cases the use of a femur component with more than  $\pm 2$  sizes difference was recorded. The femoral stems were underestimated

0.3 size on average. Templated versus actually implanted components are shown in Table I.

The study of planning accuracy according to the level of experience showed that group I surgeons predicted exactly acetabular cup size in 34.4%, group II surgeons in 31.8% and group III surgeons in 34.3%. Group I templated acetabular component 1 size too large or too small in 80%, group II in 65.9% and group III in 85.7% respectively. In group I, 5 components with more than  $\pm 2$  sizes difference were implanted, versus 3 in group II and 2 in group III. The acetabular components were overestimated 0.7 size in group I, 1.5 size in group II and 0.9 size in group III. For the femoral stem size, group I matched the templated femoral stem size exactly in 32.2%, group II in 36.4% and group III in 45.5%. Expanding the tolerance to one 1 size difference, the agreement was correct in group I in 87.4%, in group II in 79.5% and in group III in 72.7%. In group I, one component differed from the planning by more than  $\pm 2$  sizes, two in group II and in group III each. The femoral stems were on average underestimated 0.3 size in group I, 0.2 size in group II and 0.6 size in group III. Differences in templating according to the level of experience are shown in Table II.

## DISCUSSION

Preoperative planning in THA is important for correct implantation of the components. The weakness of the conventional planning system lies in magnification mismatches between the radiographs and the templates (12,14). One way to overcome this problem is to use digital planning with adequate calibration of the digitized radiographs (5,6,17). Many hospitals have now adopted PACS for storing and analysing radiographic images (18,19). Using the PACS, templating can be performed digitally

Table I. — Differences between templated and actually implanted components

Components	Same size	1 size different	2 sizes different	3 sizes different	4 sizes different	5 sizes different
Acetabular	57 (33.7%)	74 (43.8%)	28 (16.5%)	8 (4.7%)	2 (1.2%)	0
Stem	59 (36.0%)	76 (46.3%)	24 (14.7%)	4 (2.4%)	0 (0%)	1 (0.6%)

Table II. — Analysis of the level of experience in hip surgery for the acetabular cups and the femoral prosthesis stems templating (0-10 operations = group I, 10-30 operations = group II, > 30 operations = group III). Differences between templated and actually implanted components

Components	Level of experience	Same size	1 size different	2 sizes different	3 sizes different	4 sizes different	5 sizes different
Acetabular	0-10 op.	31 (34.4%)	41 (45.6%)	13 (14.4%)	4 (4.4%)	1 (1.1%)	0
	10-30 op.	14 (31.8%)	15 (34.1%)	12 (8.2%)	3 (6.8%)	0	0
	> 30 op.	12 (34.3%)	18 (51.4%)	3 (8.6%)	1 (2.9%)	1 (2.9%)	0
Stem	0-10 op.	28 (32.2%)	48 (57.2%)	10 (10.5%)	1 (1.1%)	0	0
	10-30 op.	16 (36.4%)	19 (43.1%)	7 (15.9%)	2 (4.5%)	0	0
	> 30 op.	15 (45.5%)	9 (27.2%)	7 (21.2%)	1 (3.0%)	0	1 (3.0%)

using special software packages. Digital templating offers several advantages. First, the necessity of printing large and bulky hardcopy films is eliminated. Second, digital radiographs can be stored more easily with fast access. Finally, the contrast and magnification possibilities of the images are usually excellent.

Although conventional templating was performed for decades, there is still only a limited number of studies available assessing the accuracy of this method. Knight and Atwater (12) reported that accuracy in conventional implant sizing was achieved in 62% for acetabular cups, 78% for cemented femoral stems and 42% for uncemented stems. They noted that the mismatches are related to the magnification of the plain radiographs. Carter *et al* (3) showed that conventional templating of uncemented femoral stem size corresponded exactly to the implanted component in 50% of the cases. The prediction accuracy could be increased to 88%-95% if femoral stems within 1 size were included. Della Valle *et al* (7) reported that digital templating predicted the exact size of uncemented acetabular components in 25% and increased to 81% within 1 size. The cemented femoral stem size was predicted exactly in 58% and increased to 94% within 1 size. In four patients digital templating overestimated the diameter of the acetabular component by more than 1 size. These data on accuracy were echoed by recent studies for both digital (acetabular 60-87%, stem 74%-95%) and conventional (acetabular 67%-99%, stem 77%-99%) templating within 1 size (6, 9,11,13,21,23). Kosashvili *et al* (13) stated

that preoperative digital templating is as reliable as analogue templating.

The results of the present study demonstrated that using the MediCad system, implant sizing within 1 size is in the range of the above mentioned studies. Wedemeyer *et al* (25) who used the MediCad templating system as well assessed the accuracy with the Mayo stem in 40 patients and their findings were in line with ours : 95% accuracy within 1 size for the femoral prosthesis stem and 77.5% accuracy within 1 size for the acetabular cups. However, in the present study 10 acetabular cups and 5 femoral stems were overestimated by more than 2 sizes. We found no clear explanation for these discrepancies. A possible explanation may be not only the anatomy but the bone density. There is a great variability in proximal femoral bone density, leading to different resistance to cementless stems. Therefore in case with lower bone density bigger stems may be used. The templating software does not give information about the bone density. Three-dimensional assessment based on CT scanning with colour mode to visualize the bone density could be helpful (16,20,24). However, these methods expose the patients to high irradiation and it is probably not necessary for a simple hip osteoarthritis. Regardless of the templating technique, surgeons should not rely only on the planning system ; an intraoperative x ray control should be the standard.

Carter *et al* (3) noted that the accuracy of planning increased gradually with the level of experience. The experienced surgeon was able to

predict the component size in 95% of cases, in comparison to 88 and 82% for the less experienced planner. Surprisingly, in the present study the level experience in hip surgery had no influence on the accuracy of the planning. This could be related to the fact that the residents at our university hospital were trained intensively before making use of the templating program. Furthermore, the program used appears to be user-friendly and has a steep learning curve.

The present study has some limitations. First, as there was no control group, results can only be compared to those found in literature. At the authors' institution with the transposition from hardcopy radiographs to digital images no hardcopies are available. Therefore, a direct comparison of digital templating with conventional templating technique is possible only to a certain extent. Secondly, the planning surgeon did not perform the THA in all cases. Usually in the conventional procedure templating is performed by the surgeon who performs the arthroplasty. In case of digital templating the person planning the operation and the person performing the operation are usually not identical (22). Finally, the program used is only two-dimensional. A three-dimensional software package would be more advantageous (20).

## REFERENCES

- Bauer R, Kerschbaumer F, Poisel S, Oberthaler W.** The transgluteal approach to the hip joint. *Arch Orthop Trauma Surg* 1979 ; 95 : 47-49.
- Bertin KC, Röttinger H.** Anterolateral mini-incision hip replacement surgery : a modified Watson-Jones approach. *Clin Orthop Relat Res* 2004 ; 429 : 248-255.
- Carter LW, Stovall DO, Young TR.** Determination of accuracy of preoperative templating of noncemented femoral prostheses. *J Arthroplasty* 1995 ; 10 : 507-513.
- Charnley J.** *Low Friction Arthroplasty of the Hip. Theory and Practice.* Springer Verlag, Berlin, 1979.
- Conn KS, Clarke MT, Hallett JP.** A simple guide to determine the magnification of radiographs and to improve the accuracy of preoperative templating. *J Bone Joint Surg* 2002 ; 84-B : 269-272.
- Davila JA, Kransdorf MJ, Duffy GP.** Surgical planning of total hip arthroplasty : accuracy of computer-assisted EndoMap software in predicting component size. *Skeletal Radiol* 2006 ; 35 : 390-393.
- Della Valle A, Comba F, Taveras N, Salvati E.** The utility and precision of analogue and digital pre-operative planning for total hip arthroplasty. *Int Orthop* 2008 ; 32 : 289-294.
- Eggl S, Pisan M, Muller ME.** The value of preoperative planning for total hip arthroplasty. *J Bone Joint Surg* 1998 ; 80-B : 382-390.
- Gamble P, de Beer J, Petruccioli D, Winemaker M.** The accuracy of digital templating in uncemented total hip arthroplasty. *J Arthroplasty* 2010 ; 25 : 529-532.
- Gorski JM, Schwartz L.** A device to measure X-ray magnification in preoperative planning for cementless arthroplasty. *Clin Orthop Relat Res* 1986 ; 202 : 302-306.
- Iorio R, Siegel J, Specht LM et al.** A comparison of acetate vs digital templating for preoperative planning of total hip arthroplasty : is digital templating accurate and safe ? *J Arthroplasty* 2009 ; 24 : 175-179.
- Knight JL, Atwater RD.** Preoperative planning for total hip arthroplasty. Quantitating its utility and precision. *J Arthroplasty* 1992 ; 7 Suppl : 403-409.
- Kosashvili Y, Shasha N, Olschewski E et al.** Digital versus conventional templating techniques in preoperative planning for total hip arthroplasty. *Can J Surg* 2009 ; 52 : 6-11.
- Linclau L, Dokter G, Peene P.** Radiological aspects in preoperative planning and postoperative assessment of cementless total hip arthroplasty. *Acta Orthop Belg* 1993 ; 59 : 163-167.
- Müller M.** Lessons of 30 years of total hip arthroplasty. *Clin Orthop Relat Res* 1992 ; 274 : 12-21.
- Noble PC, Sugano N, Johnston JD et al.** Computer simulation : how can it help the surgeon optimize implant position ? *Clin Orthop Relat Res* 2003 ; 417 : 242-252.
- Oddy MJ, Jones MJ, Pendegrass CJ, Pilling JR, Wimhurst JA.** Assessment of reproducibility and accuracy in templating hybrid total hip arthroplasty using digital radiographs. *J Bone Joint Surg* 2006 ; 88-B : 581-585.
- Reiner BI, Salkever D, Siegel EL et al.** Multi-institutional analysis of computed and direct radiography : part II. Economic analysis. *Radiology* 2005 ; 236 : 420-426.
- Reiner BI, Siegel EL, Hooper FJ et al.** Multi-institutional analysis of computed and direct radiography : part I. Technologist productivity. *Radiology* 2005 ; 236 : 413-419.
- Sariali E, Mouttet A, Pasquier G, Durante E, Catone Y.** Accuracy of reconstruction of the hip using computerised three-dimensional pre-operative planning and a cementless modular neck. *J Bone Joint Surg* 2009 ; 91-B : 333-340.
- Steinberg EL, Shasha N, Menahem A, Dekel S.** Preoperative planning of total hip replacement using the TraumaCad system. *Arch Orthop Trauma Surg* 2010 ; 130 : 1429-1432.
- The B, Diercks RL, van Ooijen PM, van Horn JR.** Comparison of analog and digital preoperative planning in total hip and knee arthroplasties. A prospective study of 173 hips and 65 total knees. *Acta Orthop* 2005 ; 76 : 78-84.

- 23. Unnanuntana A, Wagner D, Goodman SB.** The accuracy of preoperative templating in cementless total hip arthroplasty. *J Arthroplasty* 2009 ; 24 : 180-186.
- 24. Viceconti M, Lattanzi R, Antonietti B et al.** CT-based surgical planning software improves the accuracy of total hip replacement preoperative planning. *Med Eng Phys*. 2003 ; 25 : 371-377.
- 25. Wedemeyer C, Quitmann H, Xu J et al.** Digital templating in total hip arthroplasty with the Mayo stem. *Arch Orthop Trauma Surg*. 2008 ; 128 :1023-1029.
- 26. White SP, Shardlow DL.** Effect of introduction of digital radiographic techniques on pre-operative templating in orthopaedic practice. *Ann R Coll Surg Engl*. 2005 ; 87 :53-54.