



Resurfacing hip arthroplasty A 3 to 5-year matched pair study of two different implant designs

Hendrik P. DELPORT, Jo DE SCHEPPER, Evert J. SMITH, Margaret NICHOLS, Johan BELLEMANS

From the Algemeen Ziekenhuis Nikolaas, Sint Niklaas, Belgium

We compared the 3 to 5 year clinical and radiological results of two different hybrid metal-on-metal resurfacing hip arthroplasty designs in 28 patients who had undergone bilateral hip resurfacing with ReCap implants on one side and BHR implants on the other side. Both hips were compared in each patient, to specifically evaluate the bone response to the cemented femoral component.

Post operative function was measured with the Harris Hip Score and University of California at Los Angeles (UCLA) Activity Score, and was excellent in these patients. Mean cup inclination was $43.3^\circ \pm 7^\circ$ ($43.3^\circ \pm 7^\circ$ for the BHR and $43.4^\circ \pm 6^\circ$ for the Recap). The inclination angle was greater than 45° in 15 patients : 7 with a BHR, 8 with a Recap ; eight patients showed inclination angles greater than 50° (4 patients in each group). All acetabular monoblock cups were well fixed. One patient (1.8%) had radiographs showing bone changes of uncertain significance around the stem of the femoral component. Three percent had femoral bone resorption in the BHR hip and two percent showed bone resorption in the ReCap hip. There was no evidence of migration of the femoral components.

The dual energy X-ray absorptiometry (DEXA) scans identified no real reduction in bone density in these resurfacing hip arthroplasties. None of these hips showed any other adverse features.

The biological response showed no difference for the two different designs of resurfacing hip arthroplasties.

Keywords : hip resurfacing ; metal on metal ; different designs.

INTRODUCTION

The concept of a bone preserving hip arthroplasty is an exciting option, and resurfacing hip arthroplasty has enjoyed a significant revival in the late 1990s to date (1).

Wagner recommended resurfacing as a method of delaying a conventional total hip arthroplasty and the procedure is still directed preferentially toward the younger active patient (1,2,10,25,30).

-
- Hendrik P. Delport, MD, Orthopaedic Surgeon.
 - Jo De Schepper, MD, Orthopaedic Surgeon.
Department of Orthopaedic Surgery, Algemeen Ziekenhuis Nikolaas, Sint Niklaas, Belgium.
 - Evert J. Smith BSc, MBBCh, FRCS, Orthopaedic Surgeon.
 - Margaret Nichols, Research Coordinator.
Department of Orthopaedic Surgery, Avon Orthopaedic Centre, Southmead Hospital, Bristol, UK.
 - Johan Bellemans, MD, PhD, Orthopaedic Surgeon, Head of the Department.
Department of Orthopaedics, University Hospital Pellenberg, Belgium.
- Correspondence : Hendrik P. Delport, August de Boeckstraat 1 bus 8, 9100 Sint Niklaas, Belgium.
E-mail : hendrik.delport@telenet.be
© 2011, Acta Orthopædica Belgica.
-

No benefits or funds were received in support of this study. Evert J Smith and Margaret Nichols were paid by Biomet UK according to a Consultancy agreement. Evert J Smith also receives royalties from Biomet UK.

Hip resurfacing has a long history using different materials and designs. Advances in the 1950s included designs from Charnley. High failure rates were reported, whereas very good mid-term results have been reported with modern metal-on-metal resurfacing hip arthroplasties from specialist centres (4,5,29).

There are specific complications associated with resurfacing such as femoral neck fracture, avascular necrosis, the biological phenomenon of femoral neck narrowing and concerns about the body burden from metal debris and cobalt and chromium ions (8,11,17,19,20,23,24,28,31).

The aim of this study was to compare the ReCap (Biomet Inc. Warsaw, USA) with the Birmingham Hip Resurfacing (BHR) (Smith and Nephew – MMT, Birmingham, U.K.) in this matched pair study. The mid-term functional and radiographic results were assessed and we specifically evaluated the bone response to the cemented femoral component.

MATERIALS AND METHODS

This study retrospectively compared 28 patients (5 females) with 56 resurfacing hip arthroplasties *in situ*. One type of hip resurfacing (ReCap) was compared with a different contralateral resurfacing arthroplasty (BHR).

The ReCap is machined as cast and is heat treated. The cementless acetabular monoblock cup has a porous coating with or without hydroxyapatite. The cover is a 180° hemisphere. The bearing surface clearance is 150-250 microns and there is a 0.5 millimetre space for a cement mantle at the bone – femoral component interface. The stem is cylindrical. The femoral head is rounded when cut.

The BHR is machined as cast and has a cementless acetabular monoblock cup with cobalt chrome beads cast in hydroxyapatite (Porocast). The cover is a 160° hemisphere. The bearing surface clearance is 200-300 microns and there is no space for a cement mantle at the bone-femoral component interface. The stem is tapered. The femoral head is chamfered when cut.

All the operations were performed by the senior author (HPD) between 1997 and 2002. The patients were matched for gender, age, body mass index (BMI) and activity levels. The follow-up of the BHR was longer than for the ReCap resurfacing arthroplasty.

The pre-operative pathology was osteoarthritis in all 28 patients.

The Harris Hip Score (14) and the University of California at Los Angeles (UCLA) Activity Score (17,18) were used in the evaluation of the patients. The UCLA score ranges from 1 point (inactive) to 10 points (impact sport). Patients were asked specifically about running, jogging or any sporting activity and manual work.

Anteroposterior (AP) and lateral radiographs were used to assess changes and measure cup inclination and femoral neck resorption (16). The bone shell interface was evaluated in the 3 zones of DeLee and Charnley (12) and the zones around the femoral component according to the 'Amstutz' method. The zones on the lateral radiographs were evaluated according to Pollard *et al* (25).

The neck diameter measurements and definitions of femoral neck narrowing were evaluated according to the method of Hing *et al* (15). The radiographic classification of the appearance of the femoral component was performed according to the method of Pollard *et al* (25). The surface arthroplasty risk index according to Beaulé, a validated predictor of failure (6), was calculated for each patient and correlated with the radiological findings and grading according to Schmalzried *et al* (27).

Preoperative templating was performed on all patients to ascertain the size and the inclination of the components. All operations were performed via a posterior approach. The femoral head was reflected anteriorly and then the acetabulum was reamed prior to preparing the femoral head. Reference pins and alignment guides were used to position the femoral component. Simplex cement (Stryker, Newbury, UK) was used in the BHR cases and Refobacin Plus (Biomet Orthopaedics, Switzerland) in the ReCap cases. The cement technique was also different. The BHR cases used a technique filling the femoral component to one third with very liquid cement after less than one minute of mixing. The ReCap cases used a pasting technique inside the femoral component (26).

Thromboprophylaxis was provided for a 6 week period. All complications were recorded.

All patients received a post-operative DEXA scan after the second operation. The Hologic QDR 45000A scanner was used in conjunction with the Hologic prosthetic hip foot positioner. The software 9.8D, v8.26a was used for analysis of the densities of the 3 constructed ROI's (regions of interest, see Fig. 1).

Approval for the study was obtained from the local ethics committee.

Statistical Analysis

The data was analysed by a medical statistician. Non-parametric statistics were used to analyze the paired

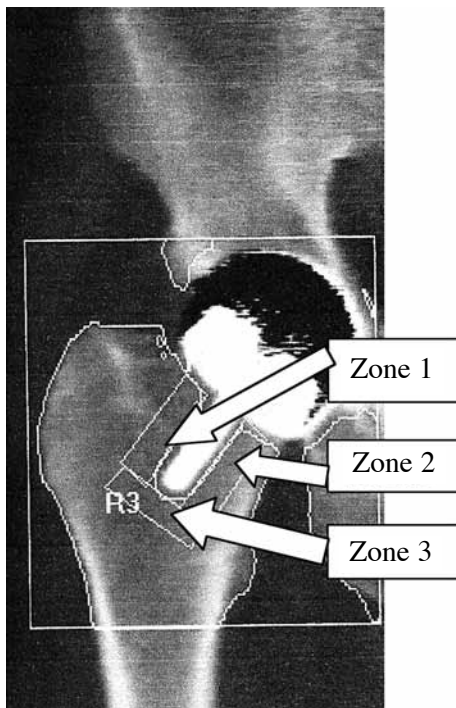


Fig. 1. — DEXA scan image with indication of the three measured regions.

data ; specifically the Wilcoxon matched-pairs rank test for nominal data and the Sign test for ordinal data. The Spearman rank correlation test was used to evaluate the relation between sizes and resorption/density data. The level of significance was always kept at 5%.

RESULTS

The mean age at surgery was 52 years, with a range from 38 to 74 years. There were 23 males and 5 females. The mean follow-up was 57.2 months (range : 28-89 months) for BHR and 17.0 months (range : 0-44 months) for ReCap.

The ReCap resurfacing was the second operation in all patients.

Acetabular component mean size was 54 mm (range : 48-60 mm). Femoral component mean size was 48 mm (range : 42-54 mm). Anatomical femoral neck shaft angle was $136.0^{\circ} \pm 6$ ($136.1^{\circ} \pm 6$ for BHR and $135.9^{\circ} \pm 7$ for ReCap).

Functional Outcome Scores

The mean Harris Hip score was 45 (range : 20-76) pre-operatively and 96.3 (range : 65-100) post-operatively. Following the operation the UCLA activity score was 6 for all patients.

Three of the patients participated in intense sporting activities.

Radiological Outcomes

All the acetabular sockets were well fixed (osseointegrated) and there was no evidence of any radiolucent lines.

The mean cup inclination was $43.3 \pm 7^{\circ}$ ($43.3 \pm 7^{\circ}$ for the BHR and $43.4 \pm 6^{\circ}$ for the ReCap). The inclination angle was greater than 45° in 15 patients (7 with a BHR and 8 with a ReCap) ; 8 patients had inclination angles greater than 50° (4 with a BHR and 4 with a ReCap).

There was no significant difference between the two components in terms of inclination angle.

Three femoral components showed a sclerotic line in zone 2. There was no evidence of migration.

The mean femoral neck resorption ratio was 0.93 (BHR) and 0.96 (ReCap). There was no significant difference in the resorption ratio of the 2 different RAs. Two femoral necks showed overt resorption (both components had been functioning in the patients for over 6 years).

The mean surface arthroplasty risk index according to Beaulé *et al* (6) was 2.19 (range : 0 to 5). A surface arthroplasty risk index greater than 3 was noted in three patients and these were categorised as high risk. Two of the three patients had overt femoral neck resorption.

Thirty five hips were graded A, 19 hips were graded B while 2 hips were graded as C according to the Schmalzried index (27) (See tables).

The DEXA scans cannot be used to identify reduction in bone density in this group of resurfacing hip arthroplasties, because it was only a one time measurement without reference. According to Brodner *et al* (9) however, the most important bone loss occurs during the first year post-operatively. Since our DEXA acquisitions took place at least 17 months after the second operation (ReCap), we

Table I. — Wilcoxon matched-pairs rank test

Recap	BHR	P	Variable
			Age at surgery
53.8+/-3	55.1+/-3	< 0.001	Cup size
47.6+/-3	48.4+/-3	< 0.1	Fem size
43.4+/-6	43.3+/-7	> 0.2	Inclination
0.85+/-0.3	0.90+/-0.2	> 0.2	Resorption
0.88+/-0.06	0.86+/-0.08	< 0.2	Final resorption
			BMD
1.27+/-0.8	0.40+/-0.7	< 0.001	Change in ROM
51.3+/-12	54.0+/-16	0.53	Change in HHS
135.9+/-7	137.1+/-8	> 0.2	CCD

Table II. — Sign test

Surface arthroplasty risk index	p = 0.5
Schmalzried index	p = 0.5
Head-neck	ns
Cyst	p = 0.387
Neck length	ns
LLD	ns

assume that remodelling had stabilised by that time. Comparing both sides did not reveal any significant difference.

Zone 1 : BHR 0.742+/-0.18 ; Recap 0.749+/-0.2 ; p = 0.5

Zone 2 : BHR 1.25+/-0.24 ; Recap 1.22+/-0.27 ; p = 0.6

Zone 3 : BHR 0.93+/-0.26 ; Recap 0.92+/-0.27 ; p = 0.7

There was no radiological evidence of notching or of impending femoral neck fracture noted on the scans.

Complications

One patient developed an aseptic trochanteric bursitis, which resolved spontaneously.

No patients suffered superficial or deep wound infection and none developed a deep vein thrombosis. There was no evidence of dislocation and no hips required any further surgery.

Table III. — Spearman rank correlation : final resorption(Fres)/BMD in the different zones

CupRecap	FresRecap	R = 0.253
	BMDRecap	R = 0.163
	BMDRecap1	R = -0.02
	BMDRecap2	R = 0.268
CupBHR	BMDRecap3	R = -0.73
	FresBHR	R = 0.341
	BMDBHR	R = 0.274
	BMDBHR1	R = 0.125
FemRecap	BMDBHR2	R = 0.181
	BMDBHR3	R = -0.086
	FresRecap	R = 0.239
	BMDRecap	R = 0.178
FemBHR	BMDRecap1	R = -0.001
	BMDRecap2	R = 0.273
	BMDRecap3	R = -0.0067
	FresBHR	R = 0.294
	BMDBHR	R = 0.256
	BMDBHR1	R = -0.119
	BMDBHR2	R = 0.052
	BMDBHR3	R = 0.031

DISCUSSION

This retrospective study compared two different resurfacing hip arthroplasties in the same patients, thus eliminating all other confounding variables. A ReCap resurfacing in one hip was compared with a BHR resurfacing in the contra-lateral hip at a mean of 50 months.

All operations were performed by a single surgeon using the same approach and technique. The follow-up was longer for the BHR as compared with the ReCap resurfacing arthroplasty. The design of the implant and the cementing technique were slightly different.

The mid-term results of modern metal-on-metal resurfacing from specialist centres are very good but these results have been tempered by the National Joint Registry from England and Wales 2007 (22) and the Australian Registry (3) which identified resurfacing arthroplasty as having the highest incidence of revision since its introduction in the Registry four years previously.

In 2006-2007, resurfacing arthroplasty accounted for 7% of all total hip arthroplasties and 33% of

hip arthroplasties in patients under 55 years in the UK (22). The Australian Joint Replacement Registry in 2007 (3) went further and documented a trend of early revision surgery associated with a high incidence of femoral neck fractures. The document noted different outcomes with differing designs of resurfacing hip arthroplasties.

Remodelling has been noted by Kishida *et al* (18) and Pollard *et al* (25). Pollard *et al* suggested that radiolucent lines and migration are representative of avascular necrosis. No evidence of such was observed in this group. On analysis of radiographs, no differences were discovered between BHR and ReCap.

In our study we identified remodelling, peri-stem sclerosis but more importantly altered bone mineral density was not noted in the neck region, at least comparing both sides. Since we did not perform sequential bone density measurements, we were not able to observe post-operative changes over time. However Brodner *et al* and Mulier *et al* (9, 21) reported that the most important loss occurred in the first year after surgery. Since we know that there are no differences in BMD between sides, right or left of the same location (18,21), pre-operatively, we may conclude that the type of implant has no influence on the post operative BMD. Operative technique was identical in both types, i.e. the posterior approach, not influencing the post-operative outcome differently.

Neck narrowing has been documented in cemented femoral components where the stem is functioning as a guide. The mechanism of this biological phenomenon is unknown, but it is seen in retrieved specimens with avascular necrosis of the femoral head.

Hing *et al* (15) reported that 27.6% (45/163) of hips showed a reduction of more than 10% of the diameter of the femoral neck. There was an association with the anatomical neck-shaft angle and gender: neck narrowing was 2.5 times more likely to occur in women than in men, and a valgus femoral neck was associated with narrowing, with a 9% increase in the risk of developing neck narrowing for every one degree increase in the valgus position of the neck. This was more important than the size of the femoral component and BMI of the patient.

There was no link between notching of the neck and femoral neck narrowing (7).

Blood supply to the osteoarthritic femoral head has been shown to be through retinacular vessels rather than via an intraosseous supply as suggested by Freeman (13), and reduction in blood supply occurs with the leg internally rotated and during seating of the component. The high number of surviving BHRs performed via the posterior approach does not support the surgical approach as being the crucial factor in avascular necrosis of the femoral head.

Biological response of the femoral head/neck to the rigid metal shell on an area of cancellous bone will result in changes in the loads transmitted through the femoral neck. Stress shielding would be expected as would the concentration of stresses under the rim of the femoral component. The thickness and distribution of the cement mantle may influence the loading in the femoral head and neck.

Remodelling is the likely response to the femoral component, but femoral neck narrowing is probably due to a combination of the mechanical changes, and one cannot exclude the continued biological insults from the metal debris and an associated effusion, given that the femoral head/neck junction has survived the effects of surgery on the oxygen supply to the bone.

There is also no significant relationship between cup size or femoral size and final resorption (a measure for neck narrowing) nor with BMD in both types of implants.

This study shows several weaknesses. All patients received first a BHR implant and as a second contra-lateral operation the ReCap implant. This means that the follow-up period is different. This also implies consequences for the DEXA scan measurements, although several authors reported a steady state of the BMD after 12 months (9,21). Another weakness is the lack of pre-operative and longitudinal DEXA studies.

The conclusion of this study is that there is no difference between BHR/ReCap regarding all parameters studied, except range of motion.

Given the unknown long-term biological response to this operation and the existence of a known high risk group of peri-menopausal females,

surgeons should consider narrowing the criteria for the current indications. Some women receiving this type of operation during their fifties, will probably become osteoporotic at a later age, which may lead to femoral neck fracture. Selection of female patients in the categories at risk for osteoporosis is advised.

REFERENCES

1. **Amstutz HC, Beaulé PE, Dorey FJ.** Metal on metal hybrid surface arthroplasty : two to six year follow-up study. *J Bone Joint Surg* 2004 ; 86-A : 28-39.
2. **Amstutz HC, Thomas BJ, Jinnah R et al.** Treatment of primary osteoarthritis of the hip : a comparison of total joint and surface replacement arthroplasty. *J Bone Joint Surg* 1984 ; 66-A : 228-241.
3. **Australian Orthopaedic Association National Joint Replacement Registry.** Annual Report Adelaide AOA.2007 ISSN 1445-3665 :58-64.
4. **Back DL, Dalziel R, Young D, Shimmin A.** Early results of primary Birmingham hip resurfacings : an independent prospective study of the first 230 hips. *J Bone Joint Surg* 2005 ; 87-B : 324-329.
5. **Beaulé P, Le Duff M, Campbell P et al.** Metal-on-metal surface arthroplasty with a cemented femoral component : a 7-10 year follow-up study. *J Arthroplasty* 2004 ; 19 Suppl 3 : 17-22.
6. **Beaulé P, Dorey FJ, Le Duff M, Gruen T, Amstutz HC.** Risk factors affecting early outcome of metal on metal surface arthroplasty of the hip. *Clin Orthop Relat Res* 2004 ; 418 : 87-93.
7. **Beaulé EP, Campbell PA, Hoke R, Dorey F.** Notching of the femoral neck during resurfacing arthroplasty of the hip ; a vascular study. *J Bone Joint Surg* 2006 ; 88-B : 35-39.
8. **Bierbaum BE, Sweet R.** Complications of resurfacing arthroplasty. *Orthop Clin North Am* 1982 ; 13 : 761-775.
9. **Brodner W, Bitzan P, Lomoschitz F et al.** Changes in bone mineral density in the proximal femur after cementless total hip arthroplasty. A five year longitudinal study. *J Bone Joint Surg* 2004 ; 86-B : 20-26.
10. **Daniel J, Pynsent PB, McMinn DJ.** Metal-on-metal resurfacing of the hips in patients under the age of 55 years with osteoarthritis. *J Bone Joint Surg* 2004 ; 86-B : 177-184.
11. **De Haan R, Pattyn C, Gill H et al.** Correlation between cup inclination and metal ion levels in metal-on-metal hip resurfacing replacement. *J Bone Joint Surg* 2008 ; 90-B : 1291-1297.
12. **DeLee JG, Charnley J.** Radiological demarcation of cemented sockets in total hip replacement. *Clin Orthop Relat Res* 1976 ; 121 : 20-32.
13. **Freeman MAR.** Some anatomical and mechanical considerations relevant to the surface replacement of the femoral head. *Clin Orthop Relat Res* 1978 ; 134 : 19-24.
14. **Harris WH.** Traumatic arthritis of the hip after dislocation and acetabular fractures : treatment by mold arthroplasty. An end result study using a new method of result evaluation. *J Bone Joint Surg* 1969 ; 51-A : 737-755.
15. **Hing CB, Young DA, Dalziel RE et al.** Narrowing of the neck in resurfacing arthroplasty of the hip. A radiological study. *J Bone Joint Surg* 2007 ; 89-B : 1019-1024.
16. **Katrana P, Crawford JR, Vowler S, Lilikakis A, Villar RN.** Femoral neck resorption after hip resurfacing arthroplasty ; a comparison of cemented and uncemented prostheses. *J Bone Joint Surg* 2006 ; 88-B (Suppl II) : 234.
17. **Khan M, Kuiper J-H, Richardson J.** The exercise-related rise in plasma cobalt levels after metal on metal resurfacing arthroplasty. *Bone Joint Surg* 2008 ; 90-B : 1152-1157.
18. **Kishida Y, Sugano N, Nishii T et al.** Preservation of the bone mineral density of the femur after surface replacement of the hip. *J Bone Joint Surg* 2004 ; 86-B : 185-189.
19. **Little CP, Ruiz AL, Harding IJ et al.** Osteonecrosis in retrieved femoral heads after failed resurfacing arthroplasty of the hip. *J Bone Joint Surg* 2005 ; 87-B : 320-330.
20. **McDonald SJ.** Metal on metal total hip arthroplasty : the concerns. *Clin Orthop Relat Res* 2004 ; 429 : 86-93.
21. **Mulier M, Jacques SVN, Raaijmakers M et al.** Early periprosthetic bone remodelling around cemented and uncemented custom-made femoral components and their uncemented cups. *Arch Orthop Trauma Surg* 2011 Jan 19 (Epub ahead of print).
22. **National Joint Registry for England and Wales 4th Annual Report.** ISSN 1753-9382 :61-70.
23. **Ollivere B, Darrah C, Barker T, Nolan J, Porteous MJ.** Early clinical failure of the Birmingham metal-on-metal hip resurfacing is associated with metallosis and soft-tissue necrosis. *J Bone Joint Surg* 2009 ; 91-B : 1025-1030.
24. **Pandit H, Glyn-Jones S, McLardy-Smith P et al.** Pseudotumours associated with metal-on-metal hip resurfacings. *J Bone Joint Surg* 2008 ; 90-B : 847-851.
25. **Pollard TCB, Baker RP, Eastaugh-Waring SJ, Bannister GC.** Treatment of the young active patient with osteoarthritis of the hip. A five to seven year comparison of hybrid total hip arthroplasty and metal on metal resurfacing. *J Bone Joint Surg* 2006 ; 88-B : 592-600.
26. **Scheerlinck T, Delpport HP, Kiewitt T.** How does the cementing technique influence the cement mantle in hip resurfacing ? An in vitro CT scan based analysis. *J Bone Joint Surg* 2010 ; 92-A : 375-387.
27. **Schmalzried TP, Silva M, de la Rosa M, Choi ES, Fowble VA.** Optimizing patient selection and outcomes with total hip resurfacing. *Clin Orthop Relat Res* 2005 ; 441 : 200-204.
28. **Shimmin AJ, Back DL.** Femoral neck fractures associated with hip resurfacing : a national review of 50 cases. *J Bone Joint Surg* 2005 ; 87-B : 463-464.

- 29. Treacy RB, McBryde CW, Pynsent PB.** Birmingham hip resurfacing arthroplasty. A minimum follow-up of five years. *J Bone Joint Surg* 2005 ; 87-B : 167-170.
- 30. Wagner H.** Surface replacement arthroplasty of the hip. *Clin Orthop Relat Res* 1978 ; 134 : 102-130.
- 31. White SP, Beard DJ, Smith EJ.** Resurfacing hip replacement – an audit in the United Kingdom 2002-2003. *Hip International* 2004 ; 14 : 163-168.