



Initial diagnostic approach of the irritable hip in childhood : is ultrasound really useful ?

Charalampos E. KONSTANTOULAKIS, Dimitrios V. PETRATOS, Michail KOKKINAKIS,
Emmanouil MORAKIS, John N. ANASTASOPOULOS

From "Aghia Sophia" Children's Hospital , Athens, Greece

The acutely painful hip is a common complaint in childhood and has numerous significant causes. This prospective study explored the use of ultrasound as an adjunct to medical history and clinical examination in children with an irritable hip attending a department of orthopaedic emergencies over the course of 8 months. One hundred thirty four children met the inclusion criteria. A provisional diagnosis was made after history, clinical examination and ultrasound scan and this initial diagnosis was compared with the final diagnosis after a 3-year follow-up. The nature and number of further investigations required to reach the final diagnosis were reviewed. The use of ultrasound reduced the number of early radiographs by 84% and in conjunction with history and clinical findings had a diagnostic accuracy of 92%.

Keywords : irritable hip ; children ; ultrasound ; diagnosis.

“an ephemeral form of hip disease” and was then differentiated from tuberculosis (9). Although it has always been considered as a distinct clinical entity, there are no specific pathognomonic physical signs and the final diagnosis based on the exclusion of other conditions like Perthes' disease, slipped upper femoral epiphysis (SUFE), juvenile chronic arthritis, tumours, trauma or septic arthritis is speculative and retrospective (1,6). A definitive diagnosis to be made in the very early stages of the disease, especially in cases of suspected septic arthritis (4), would be of utmost importance but an ideal diagnostic tool is not currently available.

The purpose of this study was to evaluate the diagnostic role of ultrasound (US) when combined with the patient's medical history and clinical examination and eventually determine if such a

INTRODUCTION

Irritable hip is one of the most common orthopaedic conditions during childhood. Pain is usually experienced in the groin or anterior - antero-medial portion of the proximal thigh but not uncommonly can be felt either in the knee or distal thigh. Limping, refusal to bear weight and limitation of movements are the usual concomitant symptoms in a child.

The specific disorder was first described by Lovett and Morse, more than one century ago, as

- Charalampos E. Konstantoulakis, MD, Orthopaedic Consultant.
- Dimitrios V. Petratos, MD, Orthopaedic Consultant.
- Michail Kokkinakis, MD, Orthopaedic resident.
- Emmanouil A. Morakis, MD, Orthopaedic Consultant.
- John N. Anastasopoulos, MD, Orthopaedic Consultant.
2nd Orthopaedic department, "Aghia Sophia" Children's Hospital, Athens, Greece.

Correspondence : Dimitrios V. Petratos, 2nd Orthopaedic department, Aghia Sophia Children's Hospital Thivon & Papadiamantopoulou – Goudi Athens, 11527, Greece. E-mail : dimpetr70@hotmail.com

© 2011, Acta Orthopædica Belgica.

combination could be safely used to reduce the number of potentially harmful investigations such as radiographs, bone scans and CT scans in the initial assessment of an irritable hip.

PATIENTS AND METHODS

From December 1st 2005 to July 31st 2006, 134 children presented to the Accident and Emergency (A&E) department of our pediatric hospital, complaining of unilateral hip pain. They all were prospectively enrolled in a protocol in which a diagnostic sonogram was performed. Exclusion criteria were a previous diagnosis of any condition known to cause hip pain, bilateral hip pain or a history of trauma. There were 102 boys and 32 girls, ranging from 18 months to 14 years of age (mean, 7.1 years).

Complete clinical history was obtained and clinical examination was performed by an orthopaedic surgeon, looking for limitation of hip movements, ability to bear weight, toxic appearance and generalized irritability. The degree of hip irritability was classified as mild, moderate or severe. Mild irritability was defined as dull ache, with or without a slight limp, absence of muscle spasm and terminal limitation of hip movements. Severe irritability included significant pain, inability to bear weight and gross restriction of hip movements. All intermediate cases were classified in the moderate group.

All children underwent ultrasound evaluation of their hips using an anterior parasagittal approach. The ultrasound scans were carried out by one of the authors (C.E.K.) using a 6.6 MHz linear array transducer (General Electric 500 Pro) with the children in supine position. During examination, the hip joint was kept in extension and slight internal rotation of about 20 degrees in order to neutralise the increased anteversion of the femoral head existing in this age group. In all patients both hips were scanned for comparison while the normal side was examined first to gain the child's confidence. With the probe centered on the growth plate the femoral head, physis and femoral neck were identified.

The US examination allowed us to evaluate four parameters. The *capsular distension* (capsule-to-bone distance) was measured as the maximal distension of the anterior capsule away from the femoral neck. A discrepancy of 2 mm or more between the two sides was considered indicative of joint effusion. The *synovial fluid* was characterized as clear or turbid depending on its echogenicity that was visually assessed and compared with the contralateral hip. The *femoral head contour* was also assessed and was characterized as normal or sugges-

tive of Perthes' disease in case of depression or fragmentation of the femoral head. The fourth parameter evaluated was the alignment between the head and the femoral neck, the so-called *femoral head alignment*. If a step at the head – physis interface was recognized, this was suggestive of SUFE.

Following clinical assessment and US scan (USS) an initial diagnosis was made for every child and further investigations were performed or treatment initiated as necessary. The diagnosis of idiopathic hip pain was made in children with normal USS. Transient synovitis was the diagnosis in children with suggestive symptoms and relevant findings on clinical and US examination and only after any other definitive pathologic conditions were excluded. Children with painful hip and turbid joint effusion detected on USS were initially diagnosed as having septic arthritis.

For standardization and analysis purposes we used a six-month and three-year clinical follow-up. Many children with a diagnosis of transient synovitis had repeat USS during follow-up ; these scans were not included in this study.

The initial diagnosis made after the first assessment was compared with the final diagnosis at the 3-year review in order to evaluate the accuracy of the diagnosis suggested by the patients' history, clinical examination and US scan.

RESULTS

The results of the initial assessment are summarized in Table I.

Thirty seven children had normal USS with absence of joint effusion. The average capsular distension for the painful hip was 2.1 ± 0.32 mm ; the synovial fluid was clear in all cases and the diagnosis of idiopathic hip pain was made. At presentation 29 children had mild irritability whilst 8 had moderate or severe irritability. Children in the latter group had plain hip radiographs in addition to the USS in order to exclude Perthes' disease or slipped upper femoral epiphysis (SUFE).

The initial diagnosis of transient synovitis was made in 76 children whose clinical examination revealed mild or moderate irritability and USS showed increased but clear effusion of the affected hip (Fig. 1). The average capsular distension was 6.93 ± 0.82 mm. Four of them had an anteroposterior radiograph of the pelvis for family reassurance

Table I. — Initial assessment after hip USS, further investigation when needed and final diagnosis in 134 painful hips

Provisional diagnosis	Number of hips	Further investigation (number of patients)	Treatment – Outcome	Change in diagnosis after further investigation	Change in diagnosis at 3-year review
Idiopathic hip pain	37	X-rays of the pelvis (8)	Bed rest – Recovery within 1 week	No	No
Transient synovitis	76	X-rays of the pelvis for family reassurance (4)	Bed rest – Recovery within 1-4 weeks	No	No
Septic arthritis	12	Blood sample (12)	Purulent aspirate and surgical drainage (2) Non purulent aspirate and recovery with bed rest (10)	No (in two children) Yes (in 10 children the initial diagnosis was finally adjusted to transient synovitis)	No
Osteomyelitis	1	X-rays and blood sample for confirmation	Antibiotics – Full recovery	No	No
SUFE	4	X-rays for confirmation (4)	In situ fixation with good outcome	No	No
Perthes' disease	4	X-rays for confirmation (4)	No surgical intervention	No	No

(SUFE = slipped upper femoral epiphysis).

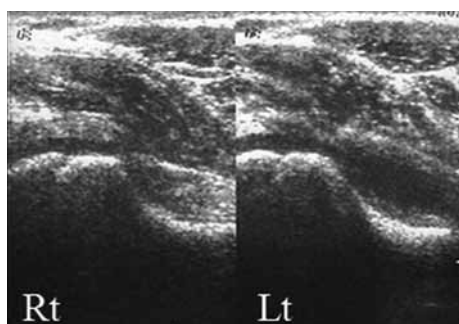


Fig. 1. — 7-year-old boy with transient synovitis of the left hip. Note the large (8.7 mm) distension of the anterior recess of the left hip (Lt) which is filled with anechogenic fluid. The normal right hip (Rt) is shown for comparison.

and only a slight bulging of the lateral plane was obvious in two. All children diagnosed with transient synovitis had recovered within one month of their diagnosis and by three years none had received an alternative diagnosis or had a further episode of pain.

Twelve children presented to the A&E department with moderate (7 cases) or severe (5 cases) irritability. The USS showed gross capsular distension (11.9 ± 0.48 mm) and the synovial fluid was characterized as turbid because of its increased

echogenicity. A preliminary diagnosis of septic arthritis was made in all these cases. Laboratory tests including WBC count, ESR and CRP were performed and an aspiration of the painful hip joint was undertaken under general anaesthesia in the operating theatre. Among them, two boys, an 18-month-old and a 7 year-old, who had a capsular distension of respectively 9.5 and 10.4 mm, had a purulent aspirate and subsequently their joint was surgically drained. Both of them presented with severe symptoms from the hip joint and the respective mean values for the peripheral WBC count, ESR and CRP were $13.100/\text{mm}^3$, 43 mm and 58 mg/L. In the rest of the children, hip aspiration was negative for septic arthritis (macroscopically no turbid or frankly purulent synovial fluid, negative Gram stain, sterile cultures). Those ten children whose mean peripheral WBC count, ESR and CRP were respectively $11.900/\text{mm}^3$, 36 mm and 47 mg/L had their diagnosis adjusted to transient synovitis. At the 6-month and 3-year review no one had received an alternative diagnosis.

One child (a 20 month-old boy) was diagnosed with osteomyelitis of the femoral neck after ultrasound revealed a cavity in the femoral neck and a clear effusion that caused a difference of the

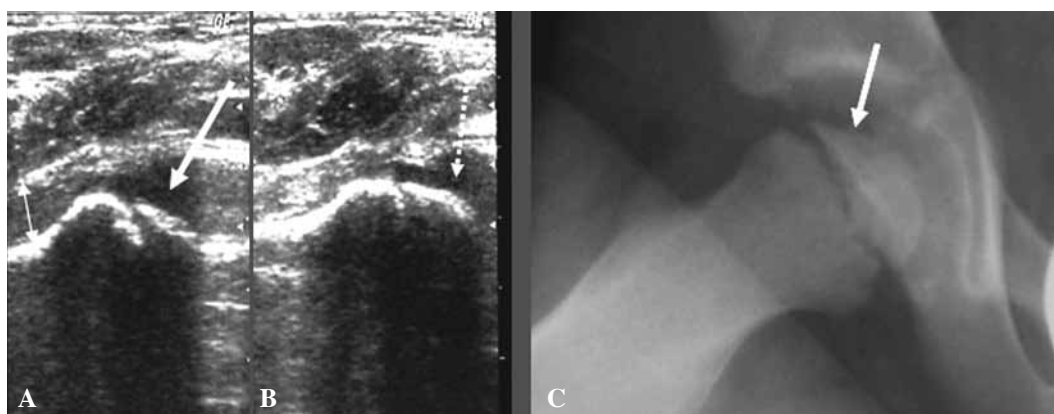


Fig. 2. — Sonographic images of both hips and plain radiograph of the right hip of a 6½-year-old child who presented with right hip pain. **A** : Ultrasound scan demonstrated abnormal contour of the right femoral head (thick arrow) and convex bulging of the joint capsule due to the presence of a moderate-size anechogenic effusion (small double arrow). The diagnosis of Perthes' disease was made. **B** : Sonography of the left hip showed no effusion and normal morphology of the femoral head (dotted arrow). **C** : Plain radiograph of the right hip revealed the flattening of the femoral head (arrow) confirming the diagnosis.

capsule-to-bone distance, between the hips, of 9.8 mm. He had received a course of antibiotics for an ear infection a month prior to the hip pain, and it would appear that the antibiotics had obscured symptoms of the infection, causing a subacute osteomyelitis and only some limping and discomfort (moderate irritability).

Four children were diagnosed with Perthes' disease following ultrasound that showed flattening of the femoral head and widening of the head cartilage (Fig. 2). In four children a step at the physis – femoral head interface was found at ultrasound and the diagnosis of SUFE was made (Fig. 3). The ultrasound diagnosis of SUFE and Perthes' disease was confirmed with plain radiographs.

Ultrasound provided an accurate diagnosis as guidance to further treatment or investigation in 124 out of the 134 hips (92.5%). However, 21 children had plain radiographs after the US scan. In 4 cases they were performed for family reassurance while in 17 cases the radiographs were requested by the orthopaedic surgeon. In 9 children radiographs were performed for confirmation of the diagnosis or to aid treatment plans whilst in 8 children for specific diagnostic purposes. Overall, the use of ultrasound reduced the number of early radiographs in 113 children (84.3%).

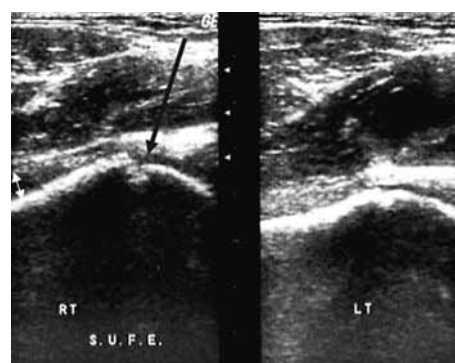


Fig. 3. — 13-year-old boy who presented with right hip pain. Ultrasound scan of the right (RT) hip revealed a step at the physis-head interface (black arrow) suggestive of SUFE and a small joint effusion (white double arrow). Sonography of the left hip was normal.

DISCUSSION

Diagnosis of the precise cause of hip pain in children is difficult (7) and a systematic approach is necessary in order to exclude important conditions such as SUFE, septic arthritis, Legg-Calve-Perthes' disease and to avoid their devastating sequelae (7, 16). There is a strong desire for a single, accurate, simple and cost-effective test for early detection of

the exact cause of the irritable hip. The test that could be used as an irreplaceable adjunct to the clinical examination has not yet been developed, however.

Multiple imaging modalities as well as laboratory studies are available for the assessment of hip pain in children. The detection of abnormal joint effusion has traditionally been very important in the initial diagnostic approach.

The classic signs of joint effusion on plain radiographs are the increased distance of the femoral metaphysis from the lateral margin of the Köhler teardrop, the so-called stand off sign and the bulging of the hip capsule. Bickerstaff *et al* reported that joint effusion could be detected by plain radiographs in only 15% of cases while Marchal *et al* reported that radiography disclosed stand-off in only 40% of the patients with transient synovitis (3,10).

Zawin *et al* reported 78 cases examined for hip joint effusion with radiographs and USS. Thirteen plain radiographs were read as normal while the USS revealed a joint effusion (27% false-negative) and in 29 cases the radiographs were interpreted as suspicious for joint effusion while subsequent USS ruled out a joint effusion (21% false-positive) (19). Although plain radiographs seem to have a low sensitivity in detecting the presence or absence of joint effusion, they are very useful in detecting other abnormalities like stress fractures, osteomyelitis or avascular necrosis of the femoral head (3,10,19).

Bone scan has been reported to have very low sensitivity in detecting clear joint effusion but a relatively much higher sensitivity in cases of septic arthritis (2). It additionally requires venipuncture and the child's cooperation in lying still, while not being available at the time of admission in every hospital. CT scan can easily reveal the presence of clear or turbid joint effusion. Furthermore both of them are expensive, time consuming examinations that involve significant doses of radiation (18).

Sonography has the advantage of not exposing the patient to radiation in contrast to the aforementioned studies, it is noninvasive and easy to perform. With the prerequisite that there is no extrusion of the femoral head (11) the US scan is extremely sensitive in detecting even small amounts of fluid (10,12) which is of utmost importance during the initial

diagnostic approach of an irritable hip. The main disadvantage of USS is that it can be a relatively subjective and examiner-dependent procedure leading to difficulty in interpretation and standardization of the results.

In our study 37 children had normal US scan. There is no specific explanation for the fact that 1/3 of the patients (27.6%) who presented with irritable hip had no signs of joint effusion. The late presentation of these children – most of them with mild and moderate irritability – that may have resulted in disappearance of a small effusion seems to be a reasonable explanation. A second reason might be the possible extra-articular location of the pathological process that did not cause intra-articular effusion. We think that children with negative US findings do not need further investigations at initial assessment. We requested radiographs in 8 children, who had additional risk factors and those radiographs were normal. All these children returned to the orthopaedic outpatient clinic free of symptoms after having completed a week of bed rest.

The synovial membrane forms only a minute part of both layers of the anterior joint capsule and its thickening can not be appreciated by USS. Therefore enlargement of the anterior recess is caused solely by joint effusion (14). In our series, 76 children who presented with mild or moderate irritability and clear joint effusion did not have further investigations at initial assessment and were thought to have transient synovitis. All of them had a resolution of their symptoms after 1-3 weeks of bed rest. On the contrary, in the 12 children with turbid joint effusion, only two were proved to have septic arthritis. Marchal *et al* reported two patients with echogenic effusion who turned out to have transient synovitis whereas one patient with anechogenic effusion had a purulent aspirate (10). In our series, all patients with initially anechogenic effusion and no other abnormalities had finally transient synovitis but only two of the children with echogenic synovial fluid had septic arthritis. Although sonography is extremely sensitive in detecting increased synovial fluid, as mentioned before, it is non specific and can not be used with accuracy to determine the type of fluid (10,13,17). Even power doppler sonography, used for the

differentiation of infectious from noninfectious joint effusion by depicting increased flow to the femoral head proved to be unsuccessful (15).

Moreover USS has the ability to reveal specific bone abnormalities. A step between the head and the physis was detected in four children on US scan. The diagnosis of SUFE was confirmed on plain radiographs which are also important to determine the severity of the slip. Concomitant clear joint effusion may be present as in our cases or may not (19). The diagnosis of Perthes' disease was correctly made in children with abnormalities of the femoral head contour on USS. Gopakumar *et al* reported no effusion in patients who developed Perthes' disease (5). On the contrary, clear joint effusion was detected in all our children with Perthes and these findings are in agreement with other authors who concluded that transient or permanent joint effusion is present in Perthes depending on its severity (8,19). Although US scan detected the cavity in the femoral neck in the child with osteomyelitis and although the initial diagnosis was correct we think that plain radiographs are of superior quality for the diagnosis of these cases.

Although sonography is non specific in determining the type of fluid and detecting with accuracy the cases of septic arthritis, our results have shown ultrasound to be a useful adjunct to clinical history and examination in the initial assessment of a painful hip. Following this line of management 84.3% of the children did not require early radiographs and therefore the radiation risk was avoided. After three years of follow-up there were no adverse sequelae in the cohort and the diagnosis did not require alteration in 92.5% of cases.

REFERENCES

1. **Adams JA.** Transient synovitis of the hip joint in children. *J Bone Joint Surg* 1963 ; 45-B : 471-476.
2. **Bialik V, Volpin G, Jerushalmi J, Stein H.** Sonography in the diagnosis of painful hips. *Int Orthop* 1991 ; 15 : 155-159.
3. **Bickerstaff DR, Neal LM, Booth AJ, Brennan PO, Bell MJ.** Ultrasonography of the irritable hip. *J Bone Joint Surg* 1990 ; 72-B : 549-553.
4. **Fabry G, Meire E.** Septic arthritis of the hip in children : poor results after late and inadequate treatment. *J Pediatr Orthop* 1983 ; 3-A : 461-466.
5. **Gopakumar TS, Vaishya R, Klenerman L, Carty H.** The role of ultrasound and isotope scanning in the management of irritable hips. *Eur J Radiol* 1992 ; 15 : 113-117.
6. **Illinworth CM.** Recurrences of transient synovitis of the hip. *Arch Dis Child* 1983 ; 58 : 620-623.
7. **Kocher MS, Zurakowski D, Kasser JR.** Differentiating between septic arthritis and transient synovitis of the hip in children : an evidence based clinical prediction algorithm. *J Bone Joint Surg* 1999 ; 81-A : 1662-1670.
8. **Linnenbaum FJ, Woltering H, Karbowski A, Harle A.** Ultrasonography of the hip for Perthes' disease. *Arch Orthop Trauma Surg* 1989 ; 108 : 166-172.
9. **Lovet RW, Morse JL.** A transient or ephemeral form of hip-disease, with a report of cases. *Boston Med Surg J* 1892 ; 127 : 161-163.
10. **Marchal GJ, van Holsbeeck MT, Raes M et al.** Transient synovitis of the hip in children : Role of US. *Radiology* 1987 ; 162 : 825-828.
11. **Mathie AG, Benson MK, Wilson DJ.** Lessons in the investigation of irritable hip : failure of ultrasound to detect haemarthrosis. *J Bone Joint Surg* 1991 ; 73-B : 518-519.
12. **McGoldrick F, Bourke T, Blake N et al.** Accuracy of sonography in transient synovitis. *J Pediatr Orthop* 1990 ; 10-A : 501-503.
13. **Miralles M, Gonzalea G, Pulpeiro JR et al.** Sonography of the painful hip in children : 500 consecutive cases. *AJR* 1989 ; 152 : 579-582.
14. **Robben SG, Lequin MH, Diepstraten AF et al.** Anterior joint capsule of the normal hip and in children with transient synovitis : US study with anatomic and histologic correlation. *Radiology* 1999 ; 210 : 499-507.
15. **Strouse PJ, DiPietro MA, Adler RS.** Pediatric hip effusion : evaluation with power doppler sonography. *Radiology* 1998 ; 206 : 731-735.
16. **Twee TD.** Transient synovitis as a cause of painful hip in children. *Curr Opin Pediatr* 2000 ; 12 : 48-51.
17. **Wilson DJ, Green DJ, MacLarnon JC.** Arthrosonography of the painful hip. *Clin Radiol* 1984 ; 35 : 14-19.
18. **Wingstrand H.** Transient synovitis of the hip in the child. *Acta Orthop Scand* 1986 ; 57 : 5-61.
19. **Zawin JK, Hoffer FA, Rand FF, Teele RL.** Joint effusion in children with an irritable hip : US diagnosis and aspiration. *Radiology* 1993 ; 187 : 459-463.