



## Failures of the three-ligament tenodesis for chronic static scapholunate dissociation are due to insufficient reduction

Luc DE SMET, Sofie GOEMINNE, Ilse DEGREEF

*From the University Hospitals of Leuven, Pellenberg Campus, Pellenberg, Belgium*

**We retrospectively reviewed 13 patients who had successfully undergone three-ligament tenodesis for scapholunate instability, and compared the radiological outcome with 14 failed cases. The scapholunate angle in the failed group increased from 73° to 81° with a scapholunate gap of 5.32 mm, compared to a decrease in the successful group from 76° to 66° with a scapholunate gap of 2.94 mm. Postoperative radiographs may thus have a prognostic value and can also be used if confronted with a patient with persisting symptoms after operation. Salvage procedures may offer a better solution when tenodesis has failed and reduction is insufficient on radiographs, and we believe that redo operations are not indicated, when the initial reduction already failed.**

**Keywords:** scapholunate dissociation ; three-ligament tenodesis ; failure ; reduction ; wrist instability.

### INTRODUCTION

In 1995 Brunelli and Brunelli described a technique for the treatment of chronic static scapholunate (SL) dissociation (1). A distally based strip of the flexor carpi radialis (FCR) is drilled through the distal pole of the scaphoid and fixed on the dorsal rim of the distal radius. Van den Abbeele *et al* (1998) and Garcia-Elias *et al* (2006) subsequently modified this procedure and fixed the tendon strip on the dorsal side of the lunate (5,11) (Fig. 1). Good clinical outcomes were reported. However, some

patients remained with a painful wrist and had to undergo a salvage procedure.

The aim of this survey is to investigate if the failed procedures were due to technical failure of the procedure or to attenuation of the tendon strip with an incomplete radiological reduction.

### MATERIAL AND METHODS

We retrieved 13 patients (2 women, 11 men) with a successful procedure (good or excellent) out of two follow-up surveys done at our department (De Smet 2007 (4), Goeminne 2011, sent for publication) We compared the radiographs with those in whom a salvage procedure was performed (N = 12, 4 women, 8 men). Measurements of the scapholunate angle and scapholunate gap were done in the immediate postoperative period and also at final follow-up. When available, the preoperative values were also recorded. Both the scapholunate angle and scapholunate gap were measured with the electronic device available in the software package of the radiology department.

- 
- Luc De Smet, MD, PhD, Surgeon-in-chief.
  - Sofie Goeminne, MD, Resident.
  - Ilse Degreef, MD, PhD, Assistant-Surgeon-in-chief.  
*Department of Orthopaedic Surgery, Upper Limb Surgery, University Hospitals of Leuven, Pellenberg Campus, Pellenberg, Belgium.*
- Correspondence : Luc De Smet, Department of Orthopaedic Surgery, University Hospital Pellenberg, Weligerveld 1, B-3212 Pellenberg. E-mail : Luc.Desmet@uz.kuleuven.ac.be  
© 2011, Acta Orthopædica Belgica.
-

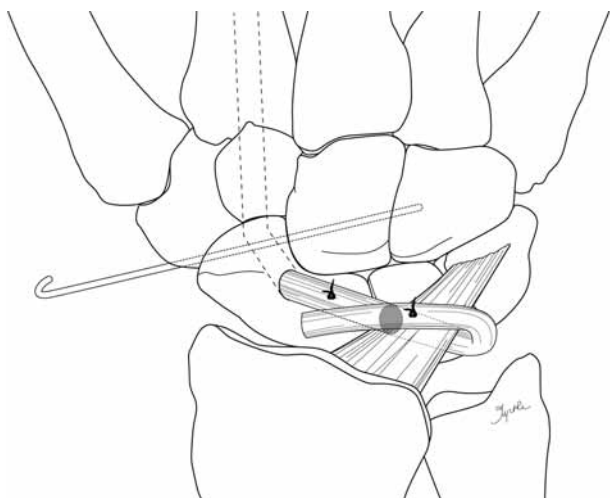


Fig. 1. — Schematic presentation of the operative technique

The values in the failed group at final follow-up were compared with those of the successful procedures. We compared the preoperative values with those at final follow-up and with the postoperative values in the failed group (paired T-test).

### Operative technique

The technique as described by Brunelli and modified by Garcia-Elias was used (1,2,5). The wrist was approached dorsally. The third extensor compartment was opened and the dorsal capsule was visualized. A ligament splitting (Berger technique) capsulotomy was performed. The carpus was inspected, scar tissue removed, adhesions between the scaphoid and the capsule were released and the scaphoid was reduced and fixed with two K-wires, one to the capitate and one to the lunate. The wrist was then approached volarly through a limited Matti Russe approach. The bed of the FCR was incised, exposing the STT joint. A 3.2 mm hole was drilled from volar to dorsal in the distal part of the scaphoid. A distally based 10 cm strip of the FCR was harvested. It was passed through the hole and retrieved dorsally, where it was passed under the radiotriquetral ligament, turned back and fixed to the dorsal aspect of the lunate with a bone anchor (Fig. 1). In some cases an additional fixation on the scaphoid was performed. The wrist was immobilised for 6 weeks. Mobilisation was started at 8 weeks, strengthening exercises at 12 weeks.

## RESULTS

Follow-up was similar in both groups: 39 months in the failed group (11-70) and 40 months in the successful group (11-69). The scapholunate angle in the failed group was 74° preoperatively. It remained practically unchanged postoperatively (73°, SD 15.33) and at final follow-up it was 81° (SD 9.15). This change was not significant ( $p = 0.16$ ). The scapholunate angle in the successful group was 76° preoperatively and decreased to 66° at final follow-up (SD 7.6). The difference between both groups was highly significant ( $p = 0.0004$ ). The scapholunate gap in the failed group was 5.32 mm (SD 20.28) and 2.94 mm (SD 9.12) in the successful group. This difference is also highly significant. In the successful group, the values of the scapholunate angle and gap remained unchanged from the immediate postoperative radiographs to the final follow-up.

## DISCUSSION

Most reported series on scapholunate reconstruction concentrate – quite rightly – on the clinical outcomes (3,4,7,10,11). However when confronted with an operated patient with persisting symptoms, it is interesting to verify how the tenodesis has changed the scapholunate angle and/or scapholunate gap. In cadaveric studies, the modified Brunelli technique has been shown to restore the normal carpal relationship between the scaphoid and lunate bones (9). However, little data is available on clinical outcome and radiographic findings.

The Wrightington series did not mention radiographic data (10). Van Den Abbeele *et al* reported that no radiological changes were observed (11). Garcia-Elias *et al* only briefly reported recurrence of the carpal collapse without hard data (5). Chabas *et al* also reported the radiographic outcome (3). The scapholunate angle in their series was corrected from 63° to 54°, but at final follow-up (37 months) it relapsed to 62°. The scapholunate gap remained corrected from the immediate postoperative measurement to final follow-up. These data are comparable to the findings reported here. We found a significant difference in measurements between

the successful procedures compared to those with the failed procedures. It is likely that these failures are due to insufficient reduction of the scapholunate angle, since the immediate postoperative radiographs showed insufficient reduction and there was no significant change in the scapholunate angle between the immediate postoperative value and the value at final follow-up.

With these data, the postoperative radiographs can have a prognostic value. These data can also be used when confronted with a postoperative patient with persisting symptoms. Redo operations are unlikely to succeed since the initial reduction already failed and revision of a ligamentous reconstruction seems highly unpredictable due to excessive scar tissue formation and primary tendon graft failure. A salvage procedure is probably a better solution.

## REFERENCES

1. **Brunelli GA, Brunelli GR.** A new technique to correct carpal instability with scaphoid rotary subluxation : a preliminary report. *J Hand Surg* 1995 ; 20-A : S82-S85.
2. **Brunelli GA, Brunelli GR.** [A new surgical technique for carpal instability with scapho-lunar dislocation (Eleven cases).] (in French). *Ann Chir Main Memb Supér* 1995 ; 14 : 207-213.
3. **Chabas JF, Gay A, Valenti D, Guinard D, Legre R.** Results of the modified Brunelli tenodesis for treatment of scapholunate instability : a retrospective study of 19 patients. *J Hand Surg* 2008 ; 33-A : 1469-1477.
4. **De Smet L, Van Hoonacker P.** Treatment of chronic, static scapholunate dissociation with the modified Brunelli technique : preliminary results. *Acta Orthop Belg* 2007 ; 73 : 188-191.
5. **Garcia-Elias M, Lluch A, Stanley JK.** Three-ligament tenodesis for the treatment of scapholunate dissociation : indications and surgical technique. *J Hand Surg* 2006 ; 31-A : 125-134.
6. **Howlett JP, Pfaeffle HJ, Waitayawinyu T, Trumble TE.** Distal tunnel placement improves scaphoid flexion with the Brunelli tenodesis procedure for scapholunate dissociation. *J Hand Surg* 2008 ; 33-A : 1756-1764.
7. **Links AC, Chin SH, Waitayawinyu T, Trumble TE.** Scapholunate interosseous ligament reconstruction : results with a modified Brunelli technique versus four-bone weave. *J Hand Surg* 2008 ; 33-A : 850-856.
8. **Linscheid R, Dobyns J, Beabout J, Bryan R.** Traumatic instability of the wrist, diagnosis, classification and pathomechanics. *J Bone Joint Surg* 1972 ; 54-A : 1612-1632.
9. **Pollock PJ, Sieg RN, Baechler MF et al.** Radiographic evaluation of the modified Brunelli technique versus the Blatt capsulodesis for scapholunate dissociation in a cadaver model. *J Hand Surg* 2010 ; 35-A : 589-1598.
10. **Talwalkar SC, Edwards AT, Hayton MJ et al.** Results of tri-ligament tenodesis : a modified Brunelli procedure in the management of scapholunate instability. *J Hand Surg* 2006 ; 31-B : 110-117.
11. **Van Den Abbeele KL, Loh YC, Stanley JK, Trail IA.** Early results of a modified Brunelli procedure for scapholunate instability. *J Hand Sur* 1998 ; 23-B : 258-261.