



Unrecognized acute exertional compartment syndrome of the leg and treatment

Nebojsa POPOVIC, Craig BOTTONI, Charles CASSIDY

From Aspetar, Qatar Orthopaedic and Sports Medicine Hospital, Doha, Qatar

Acute-on-chronic exertional compartment syndrome is rare and may be easily missed without a high degree of awareness and clinical suspicion. We report a case of unrecognized acute-on-chronic exertional compartment syndrome in a recreational soccer player. The late sequela of this condition, foot drop, was successfully treated with transfer of the peroneus longus tendon.

Keywords : exertional compartment syndrome ; acute-on-chronic ; dropfoot ; peroneus longus transfer.

INTRODUCTION

Acute on chronic exertional compartment syndrome has been well recognized as a complication of sports activity (1,2,3,4,5,8).

The pathophysiological features of exertional compartment syndrome still remain unclear (6,9). Failure to rapidly recognize and to institute early treatment for this condition may result in disastrous complications for the athlete. The literature describing specific reconstruction for the sequelae of compartment syndrome is scarce (7). We describe a case of unrecognized acute exercise-induced compartment syndrome in the anterior leg and treatment with peroneus longus transfer.

CASE REPORT

A healthy 24-year-old male, a recreational soccer player, was seen in the emergency department with

a complaint of increasing pain in his right lower leg for three days, and drop foot.

Four days earlier, he played football in the evening with friends. As was usual for him, after 20 minutes he started to feel antero-lateral shin pain bilaterally which resolved after the game.

The subsequent day, he continued his normal daily activities without pain. Later in the night, 24 hours after his football game, he started to experience right leg pain. The next morning, he went to a hospital emergency department for evaluation. On examination, his vital signs were normal. He was noted to be in pain, with tenderness and tension over the anterior right leg. There was no swelling and distal limb sensation was intact. He was discharged without diagnosis with advice to take analgesics, rest and use local ice packs.

The pain persisted and became progressively worse despite treatment. On the same day, medical personnel evaluated the patient on two further separate occasions.

A diagnosis was not made and each time he was discharged with analgesics.

-
- Nebojsa Popovic, MD, PhD, Orthopaedic Surgeon.
 - Craig Bottoni, MD, Orthopaedic Surgeon.
 - Charles Cassidy, MD, Orthopaedic Surgeon.

Correspondence : Dr Nebojsa Popovic, Aspetar, Qatar Orthopaedic and Sports Medicine Hospital, PO BOX 29222, Doha, Qatar. E-mail : Nebojsa.popovic@aspetar.com

© 2011, Acta Orthopædica Belgica.

The following day, he presented to the emergency department of another hospital, for the fourth time in 26 hours since the onset of right leg pain.

On examination, he had no sensation to light touch in the first dorsal web space of his right foot. There was no active dorsiflexion of the right ankle. The severe pain persisted in the anterior right leg. He was given an analgesic and allowed to go home.

The next day in the early morning, he was seen for the first time in our clinic. On examination, he had evidence of foot drop on the right with no active motor function present in either extensor hallucis longus or tibialis anterior.

He had complete absence of sensation on the dorsum of the first web space. Passive dorsiflexion of the ankle was pain free. Plantar flexion of the ankle and toes was painful.

On palpation, his anterior and lateral compartments were firm (anterior more than lateral), and the posterior compartment was soft. Posterior tibial and dorsalis pedis pulses were palpable.

Finally, compartment pressures were measured with a hand-held Stryker compartment monitor (Stryker, Kalamazoo, USA). His anterior compartment pressure was 90 mmHg. No pressure measurements of the lateral and posterior compartment were obtained. Due to the clinical urgency of the condition, the patient was taken to the operating room for fasciotomy of the anterior and lateral compartments. A long longitudinal skin incision was used for fasciotomy of the anterior and lateral compartment; the muscles in both compartments were widely exposed. Under direct visualization the anterior compartment musculature appeared discolored and was not responsive to electrocautery stimulator (Fig. 1).

The lateral compartment muscles were red, contractile and viable. The wound was packed with V.A.C. GranuFoam dressing (San Antonio, USA), while the skin and aponeurosis were left open, and a posterior splint was applied. The patient was given prophylactic antibiotics. Postoperatively, he noted relief of pain. He was hospitalized and carefully monitored. Two days later, he was brought back to the operating theatre for reevaluation. The peroneal muscles were found to be healthy in appearance, pink and contractile. In contrast, the

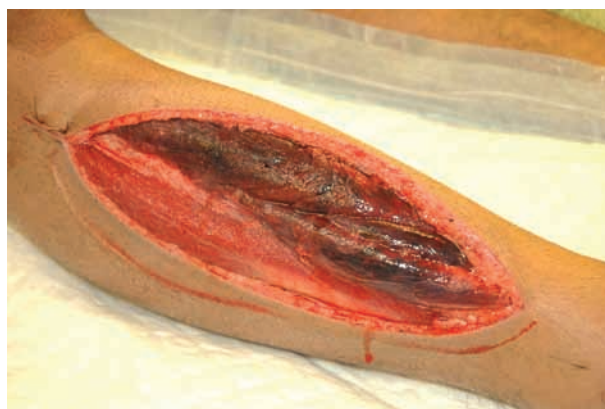

Fig. 1. — Intraoperative photograph of the right leg showing necrotic muscles in the anterior compartment.

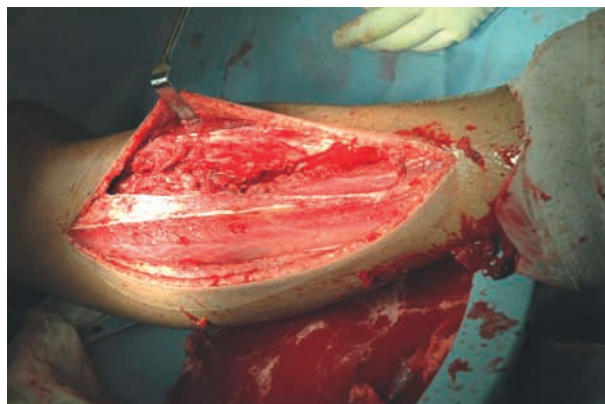


Fig. 2. — Intraoperative photograph showing the extensive debridement of the necrotic muscle in the anterior compartment and the healthy appearance of the peroneal muscles.

muscles in the anterior compartment were dark, necrotic and non viable.

Extensive debridement of the necrotic muscle of the anterior compartment was performed (Fig. 2).

The fascia was not sutured, but the skin was closed without difficulty. Suction drainage was employed for 48 hours.

After discharge from the hospital, he received physical therapy and wore a solid ankle foot orthosis.

Twelve weeks after decompression, as expected, there was no evidence of any recovery of dorsiflexion of the ankle. The patient used a plastic fixed ankle foot orthosis to assist with walking. He presented to our clinic over 4 months after his initial

surgery for evaluation and another opinion concerning his right lower extremity functional deficits. In the meantime, he had developed an equinus deformity of the ankle. The options of a posterior tibialis tendon transfer or a transfer of the peroneus longus were reviewed with the patient. Considering that he had normal function of his lateral compartment muscles, transfer of the peroneus longus to the dorsum of the foot was proposed.

Operative technique

The patient was in supine position under general anaesthesia with a tourniquet at the right thigh. Lengthening of the Achilles tendon through percutaneous Z plasty was first performed.

The Achilles tendon was tensioned by forced dorsiflexion of the foot. A percutaneous incision was made lateral to the Achilles tendon 3 cm proximal to its calcaneus insertion and at the medial side about 5 cm proximally to the calcaneus insertion.

The width of the Achilles tendon was evaluated by palpation and the cut was extended approximately to the midline. Gradual regression of the equinus was felt.

Next, a horizontal incision was made laterally, distal to the lateral malleolus. The peroneus longus was identified and released distal to the peroneal tubercle on the lateral calcaneal wall. The tendon of peroneus longus was cut at the base of the fifth metatarsal and its distal stump was sutured to the intact peroneus brevis tendon. A second retrofibular incision was made through the existing lateral scar and the peroneus longus was retrieved in the proximal wound. The peroneus longus muscle was carefully mobilized. A third incision was made over the lateral cuneiform under fluoroscopic control. Using a tendon passer introduced through the distal incision under the extensor retinaculum the peroneus longus tendon was delivered. With the ankle maintained in dorsiflexion, the proper tension was estimated. Two # 2 fiberwire sutures were placed through the tendon at this level and through an Endobutton, and the excess tendon was excised. A 4.5 mm drill hole in the center of the lateral cuneiform was made from dorsal to plantar, and the upper cortex was then overdrilled to 7 mm. A Beath

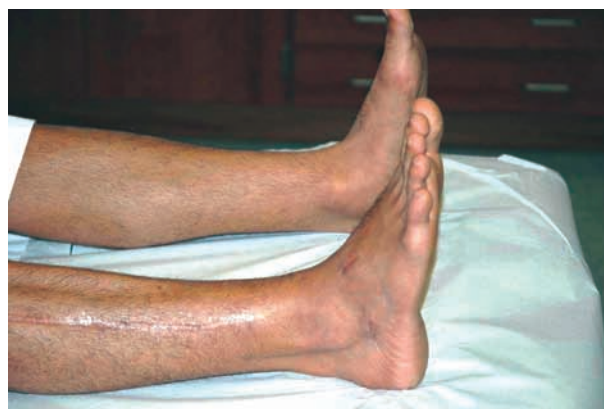

Fig. 3. — Clinical photograph 6 months post surgery demonstrating near full active dorsiflexion of the right ankle.

pin was used to pass a #5 Ethibond and #2 fiberwire traction suture through the Endobutton, exiting through the sole of the foot. Under fluoroscopic control, the Endobutton was advanced and flipped, engaging on the plantar surface of the lateral cuneiform. The resultant resting posture of the ankle was approximately 5° of dorsiflexion. The operative wounds were closed. Sterile dressing and a well-padded bivalved short leg fiberglass cast were applied with the ankle in 5° of dorsiflexion.

The ankle was immobilized for 6 weeks. The patient was then allowed active range of motion without weight bearing for another 6 weeks.

At the 6 months follow-up, he demonstrated active dorsiflexion and was able to walk without external support (Fig. 3).

The results of peroneus longus tendon transfer in this patient was assessed with Yeap *et al's* scoring system (86 of 100 points) (11). The result was rated as excellent. The patient was very satisfied with the clinical and functional outcome.

DISCUSSION

Exertional compartment syndrome is precipitated by exercise ; in some cases the onset of pain is delayed for several hours after intensive exercise (1,2,8). The acute form of chronic exertional compartment syndrome is a progressive entity, which leads to destruction of the compartment.

This case illustrates the progression of acute-on-chronic exertional anterior tibial compartment syndrome in a recreational soccer player. Acute exercise-induced compartment syndrome is rare and may be easily missed without a high degree of awareness and clinical suspicion. The onset of pain may be delayed, as in this patient, who developed pain after 24 hours. Our patient was seen successively by multiple health care providers without a diagnosis being made.

In retrospect, this young man had symptoms of a chronic bilateral exertional anterior tibial compartment syndrome prior to developing an acute compartment syndrome, in the absence of trauma. This report is in agreement with the studies published by Reneman (8) and Leache *et al* (6) who warned against the possibility of progression of the chronic form of anterior compartment syndrome to the acute form.

It is well known that the diagnosis and treatment should be prompt after the onset of symptoms to avoid long term complications. The role of fasciotomy in cases of compartment syndrome that have been diagnosed at a late stage (after 8 hours) is controversial. It is well known that only 8% of patients regained full function when the delay of fasciotomy was greater than 12 hours. Esmail *et al* (2) however described in a case report a good outcome in a patient despite an extended delay before fasciotomy. They theorized that several unique factors in acute on chronic compartment syndrome, such as a slow progression of increasing pressure with, perhaps, a late sudden increase in compartment pressure shortly before measurements were taken, meant that no significant permanent damage occurred. For that reason, we decided to perform fasciotomy in this case while accepting the risk of possible complications from fasciotomy.

Late clinical sequelae of anterior tibial compartment syndrome include the development of a drop foot deformity. Loss of active dorsiflexion of the foot in our patient was the result of the complete absence of muscle function in tibialis anterior, extensor hallucis longus and extensor digitorum longus. With the unopposed action of the strong triceps surae muscle, an equinus deformity progressively developed. Our patient was unable to

actively dorsiflex his ankle. In this case the lateral compartment muscles were found to be spared : the peroneus longus and brevis were functional.

In this specific patient who had two functional peroneal muscles, transfer of peroneus longus was considered preferable to maintain the muscle balance of the foot. This option was preferred to avoid the risk of progressive planovalgus deformity of the foot from unopposed pull of the peroneus brevis muscle with transfer of the tibialis posterior tendon.

CONCLUSION

A thorough physical examination and high level of suspicion are required for accurate diagnosis of acute on chronic exertional compartment syndrome to avoid invalidating long-term sequelae. This awareness is particularly important in the current time of increased recreational sports activity in several populations.

Transfer of peroneus longus appears as a reasonable option in the treatment of late sequelae of this condition, when it selectively affects the anterior compartment.

REFERENCES

1. **Brodsky M, Bonggiiovanni MS.** Bilateral lower leg acute exertional compartment syndrome [case report]. *Orthopedics* 2000 ; 23 : 607-609.
2. **Esmail AN, Flynn JM, Ganley Th J, Pill SG, Harnly H.** Acute exercise-induced compartment syndrome in the anterior leg : case report. *Am J Sports Med* 2001 ; 29 : 509-512.
3. **Fehlandt A Jr, Micheli L.** Acute exertional anterior compartment syndrome in an adolescent female. *Med Sci Sports Exerc* 1995 ; 27 : 3-7.
4. **Green JE, Crowley B.** Acute exertional compartment syndrome in an athlete. *Br J Plastic Surg* 2001 ; 54 : 265-267.
5. **Klondell CT, Pokorny R, Carrillo EH, Heniford BT.** Exercise-induced compartment syndrome : Case report. *Am Surg* 1996 ; 62 : 469-471.
6. **Leach RE, Hammoud G, Stryker WS.** Anterior tibial compartment syndrome. Acute and chronic. *J Bone Joint Surg* 1967 ; 49-A : 451-462.
7. **Perry MD, Manoli II A.** Reconstruction of the foot after leg or foot compartment syndrome. *Foot Ankle Clin* 2006 ; 11 : 191-201.
8. **Reneman RS.** The anterior and the lateral compartmental syndrome of the leg due to intensive use of muscle. *Clin Orthop Relat Res* 1975 ; 113 : 69-80.

- 9. Rorabeck CH, Bourne RB, Fowler PJ.** The surgical treatment of exertional compartment syndrome in athletes. *J Bone Joint Surg* 1983 ; 65-A : 1245-1251.
- 10. Willy C, Becker HP, Evers B, Gerngross H.** Unusual development of acute exertional compartment syndrome due to delayed diagnosis [case report]. *Int J Sports Med* 1996 ; 17 : 458-461.
- 11. Yeap JS, Singh D, Birch R.** A method for evaluating the results of tendon transfers for foot drop. *Clin Orthop Relat Res* 2001 ; 383 : 208-213.