



Debonding of the acetabular porous coating in hip resurfacing arthroplasty A case report

Hendrik P. DELPORT, Bart VAN BACKLE, Jo DE SCHEPPER

From Algemeen Ziekenhuis Nikolaas, Sint Niklaas, Belgium

This report presents the case of a patient in whom hip resurfacing arthroplasty failed because of loosening of the acetabular shell secondary to debonding of the surface coating. During normal function, there will inevitably be cyclic shear stress between the coating and the surrounding bone. This might result in fatigue failure of the bond. In spite of increasing numbers of porous coated acetabular shells being implanted, little is known about the fatigue performance of the interface between coating and implant.

Keywords : hip resurfacing ; metal on metal ; porous coating ; debonding.

INTRODUCTION

Modern concepts in hip resurfacing are the main cause of the revival of metal-on-metal hybrid implants. Better metallurgy and manufacturing methods contributed to this recent clinical success (3,4). The Birmingham Hip Replacement (BHR[®], Smith&Nephew) was the first and remains the most widely used implant. Several other manufacturers followed the new trend and started to market similar metal-on-metal hip resurfacing implants. One of these is the ReCap[®] Total Resurfacing System (Biomet). It consists of a metal-on-metal implant with a cemented femoral component and a press-fit uncemented acetabular component. This cobalt-chromium acetabular component is plasma-sprayed with a titanium porous coating.

In this report, we present the case of a patient in whom hip resurfacing with the ReCap System failed because of loosening of the acetabular shell secondary to debonding of the surface coating. Two similar cases have been previously reported (1).

The patient was informed and consented that the data concerning his case would be submitted for publication.

CASE REPORT

A 43 year-old man presented to our clinic in June 2006 with a painful advanced osteoarthritis of his right hip. As this patient was well informed about the good results of resurfacing arthroplasty, he specifically requested a so-called “sports hip”. He underwent a right hip resurfacing arthroplasty on June 26, 2006 with the use of the ReCap[®] (Biomet)

-
- Hendrik P. Delpport, MD, Orthopaedic Surgeon, Head of the Department.
 - Bart Van Backle, MD, Orthopaedic Surgeon.
 - Jo De Schepper, MD, Orthopaedic Surgeon.
Department of Orthopaedic Surgery, Algemeen Ziekenhuis Nikolaas, Sint Niklaas, Belgium.

Correspondence : Hendrik P. Delpport, Department of Orthopaedic Surgery, Algemeen Ziekenhuis Nikolaas, Sint Niklaas, Belgium. E-mail : hendrik.delpport@telenet.be

© 2011, Acta Orthopædica Belgica.

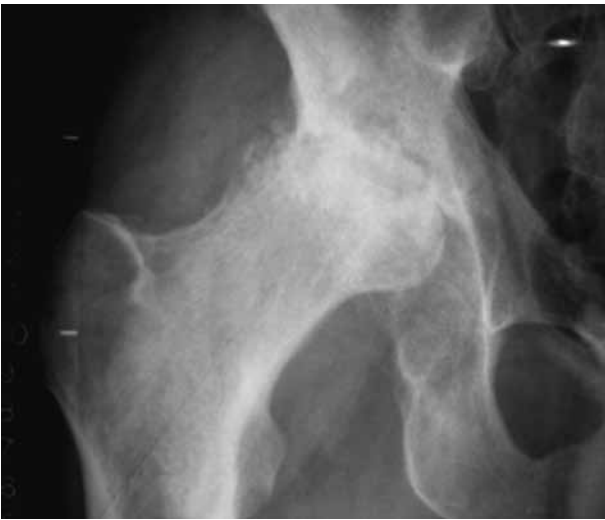

Fig. 1. — Pre-operative radiograph with end-stage arthritis

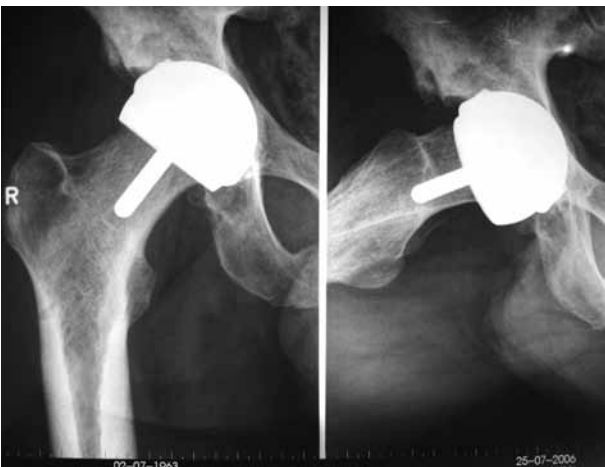


Fig. 2. — Post-operative radiograph showing the correctly implanted hip resurfacing implants.

System. The acetabular cup measured 56 × 50 mm and the outer diameter of the cemented femoral head was 50 mm (ReCap resurfacing femoral head, Biomet). This procedure was performed by the junior author (JDS) as part of a prospective study. The preoperative Harris Hip score was 46. The patient did extremely well. The postoperative Harris Hip score was 95 at 6 months, 99 at 1 year and at 2 years postoperatively. The pre-operative and immediate postoperative radiographs are shown in

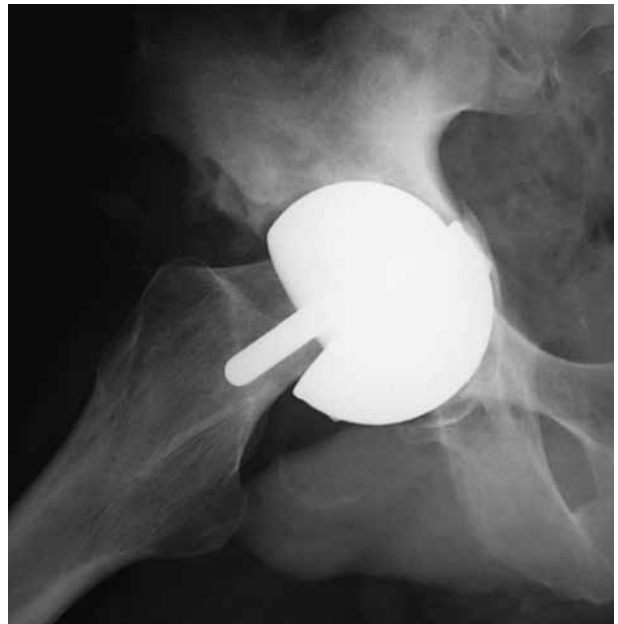

Fig. 3. — Radiograph at failure with marked cup displacement

Figures 1 and 2. Postoperative radiographs made at 6 weeks and 6 months showed excellent component positioning and no radiolucent lines. However, in the beginning of July 2009, 36 months postoperatively, the patient experienced a sudden snap followed by a grinding sensation during heavy work. Radiographs suggested a possible loosening of the acetabular component. The patient returned after 2 weeks with more complaints but without much pain. Further radiographs revealed gross displacement of the acetabular component (Fig. 3). There were no signs indicating infection.

Shortly thereafter the patient underwent a revision arthroplasty of the right hip by the senior author (HD). The acetabular shell was loose and had dislocated. The acetabular component was removed. Part of the titanium porous coating had “debonded” from the back side of the acetabular shell and was extremely well fixed to the pelvic bone (Fig. 4). We had to use curettes to remove the ingrown coating from the acetabular floor. The surrounding area showed signs of metallosis. The acetabulum was re-reamed and a new porous coated shell with screws, two sizes larger than the previously used resurfacing cup (Exceed ABT 15°



Fig. 4. — View of the porous coated cup showing debonding of the plasma spray coating.

acetabular shell, porous and HA coated, 60 mm diameter, Biomet), was inserted. The femoral component was well fixed in good position, but had to be removed also because a revision cup with a larger outer diameter and an unchanged inner diameter equipped with offset screws for fixation is not available now. A short porous coated and lateralized stem (Taperloc Microplasty 13.5 mm × 112.5 mm, Biomet) replaced the femoral component. The acetabular insert (Exceed ABT ceramic BioloX Delta) and the head (BioloX Delta 36 mm – 3 mm neck type 1 taper, Biomet) were ceramic.

The failed cup was returned to the manufacturer for analysis. At six weeks post-revision, the patient was completely pain free and walked normally without limping and without walking aids.

DISCUSSION

Hip resurfacing is regularly performed at our institution since October 1998. To date our unit has performed over 1100 metal-on-metal hip resurfacing arthroplasties. Porous coated cups have very

low failure rates and are considered the gold standard. Until now, to our knowledge, debonding of the porous coating of a metal-on-metal acetabular component has only been reported recently by Jacobs *et al* (1). The question arises if this might be a new complication related to the larger head diameters of resurfacing prostheses. Porous coatings can be applied to prostheses by three different techniques : sintering, diffusion bonding or plasma spraying.

Debonding is impossible with the porous coating of the Birmingham Hip Resurfacing (BHR, Smith & Nephew) which is an entire part of the cup. In the ReCap as in many other systems a plasma-sprayed coating is used. This coating proved to be working well in the classic total hip replacement with a stem and a relatively smaller head. If bony ingrowth of the shell to the pelvis is incomplete, shear forces applied to the bony junction are too high and patches of porous coating are sheared from the cup during loading, resulting in failure. Manley *et al* (2) performed a biomechanical study to evaluate the shear stresses of five different interfaces and found that the shear strength of the coating-substrate interface was similar to or less than that between coating and bone. This might be a possible explanation for this rather new complication.

This case report illustrates the need for continued research into the ideal techniques to produce a porous coating which will remain intact during normal patient loading.

REFERENCES

1. **Jacobs MA, Bhargava T, Lathroum JM, Hungerford MW.** Debonding of the acetabular porous coating in hip resurfacing arthroplasty. A report of two cases. *J Bone Joint Surg* 2009 ; 91-A : 961-964.
2. **Manley MT, Kotzar G, Stern LS, Wikde A.** Effects of repetitive loading on the integrity of porous coatings. *Clin Orthop Relat Res* 1987 ; 217 : 293-302.
3. **McMinn D, Daniel J.** History and modern concepts in surface replacement. *Proc Inst Mech Eng {H}* 2006 ; 220 : 239-251.
4. **Treacy RB, McBryde CW, Pynsent PB.** Birmingham hip resurfacing arthroplasty. A minimum follow-up of five years. *J Bone Joint Surg* 2005 ; 87-B : 167-70.