



Closing wedge patellar osteotomy in combination with trochleoplasty

Peter P. KOCH, Bruno FUCHS, Dominik C. MEYER, Sandro F. FUCENTESE

From the University of Zurich, Balgrist, Zurich, Switzerland

Sulcus-deepening trochleoplasty may result in a serious patellofemoral incongruence in cases where the patella also is highly dysplastic. In such cases, a closing wedge osteotomy of the patella may be considered. The technique was used in two patients (both female, 16½ and 14 years old respectively) out of 85 trochleoplasties performed.

At two years follow-up, both patients showed a stable patella with correct tracking. Both considered their functional result as excellent. Postoperative radiographs showed a normal sulcus angle (135° and 132°) with good congruence.

Closing wedge patellar osteotomy, combined with sulcus-deepening trochleoplasty, can increase patellofemoral congruence with good clinical outcome.

Keywords: closing-wedge patellar osteotomy; trochleoplasty.

INTRODUCTION

The results of surgical sulcus-deepening techniques for severe trochlear dysplasia with patellofemoral instability are encouraging (11,15,20,24-26). A CT study confirmed that surgery can normalize the geometry of the trochlear groove in most cases (12) and improve congruence between patella and trochlear groove with an increased trochlear depth and an increased lateral trochlear slope.

A mismatch between the restored trochlear groove and a dysplastic patella may however persist

and continue to cause maltracking, certainly when the soft tissues are not balanced. Patellar osteotomy combined with a reconstruction of the medial patello-femoral ligament (MPFL) can then center the patella in the reshaped trochlea.

SURGICAL TECHNIQUE

Surgery is carried out under general or spinal anaesthesia in combination with a femoral nerve catheter. A tourniquet is applied to the thigh.

Trochleoplasty is carried out as described by Bereiter using a lateral parapatellar skin incision (5, 20,26). After restoration of the trochlear groove, patellofemoral tracking is evaluated. If the patella is dysplastic and incongruency persists, we proceed with a closing wedge patellar osteotomy. The periosteal layer covering the patella midline is elevated, and a longitudinal dorsally closing wedge osteotomy is performed down to the subchondral

-
- Peter P. Koch, MD, Head of knee surgery.
 - Bruno Fuchs, MD, PhD, Professor, Head of tumour surgery.
 - Dominik C. Meyer, MD, Lecturer, Deputy head of knee surgery.
 - Sandro F. Fucentese, MD, Chief resident.
Department of Orthopaedic Surgery, University of Zurich Balgrist, Zurich, Switzerland.
- Correspondence : Peter P. Koch, MD, University of Zurich Balgrist, Forchstrasse 340, CH-8008 Zurich, Switzerland.
E-mail : peter.koch@balgrist.ch
© 2011, Acta Orthopædica Belgica.
-

layer using a small oscillating saw. Care is taken not to disturb the articular cartilage. The wedge is carefully closed with a reposition clamp. The osteotomy is fixed with two 3.5 mm screws entering medially (Fig. 2A-C & 3A-C) and patellar tracking is assessed. After closing the joint capsule with an absorbable suture n° 2-0 (Vicryl, Ethicon, Norderstedt, Germany), surgery is completed with a reconstruction of the medial patellofemoral ligament using the ipsilateral gracilis tendon (22). The retinaculum is then closed with a continuous resorbable n° 2 Vicryl suture. The oblique muscle fibres of vastus medialis are fixed onto the patella (n° 2 Vicryl stitches). The skin is closed with a resorbable intracutaneous suture n° 4-0 (Maxon, Ethicon, Norderstedt, Germany). Intraarticular drainage is removed after 24 hours. Post-operative mobilisation consists of 15 kg weight bearing in a knee immobilizer in full extension for six weeks. Passive flexion is limited to 60° during the first three weeks, then to 90° until the end of the 6th week.

ILLUSTRATIVE CASES

Since 1999, 85 sulcus deepening trochleoplasties according to Bereiter have been performed at our institution (5). Among these, two patients, both female, had a concomitant dorsal closing wedge patellar osteotomy, both performed in 2007. These patients continued to suffer recurrent instability despite two previous surgical stabilisations of the patella performed elsewhere (Case 1: Roux-Goldthwaite procedure (19) on the right knee at age 12, followed one year later by a soft tissue release

with an anteromedialisation of the tibial tuberosity; in case 2, Roux-Goldthwaite procedure (19) at the age of 8 years, followed at the age of 14 years by a vastus medialis plasty with a lateral soft tissue release). Both teenagers had a normal growth and development, but were manifestly hyperlax. They suffered from habitual lateral dislocation of the patella in flexion. The legs were clinically well aligned. Bony reconstruction of patella and trochlea was combined in both with a reconstruction of the MPFL. On preoperative clinical examination no effusion was noted. The patella of both patients dislocated at 40° to 50° of flexion during active flexion. The patella apprehension test was highly positive in both. No other clinical pathological findings were recorded.

Preoperative planning (Table I) included measurement of Caton index on conventional radiographs, patellar tilt angle, sulcus angle of the trochlea and Wiberg angle of the patella on axial MRI slices and drawing of the planned correction angles.

The trochlea was severely dysplastic (Type D) (8) as well as the patella, according to the classification of Wiberg (28) and Baumgartl (4,27). The aim of surgery was to restore a physiological sulcus angle of about 130° to 140° and a congruent patellar articular surface (Fig. 1). Exact preoperative planning of the osteotomy angle is difficult, as the depth of the trochleoplasty and resulting trochlear angle are not fully predictable.

Postoperatively only conventional radiographs were taken.

Postoperatively rehabilitation was uneventful in the first case and the subjective result was excellent. Physical examination showed a stable patella with-

Table I. — Summary of the radiological findings. Trochlear dysplasia is defined according to Dejour (8) and patellar dysplasia according to Wiberg (27) and Baumgartl (4). Patellar height is defined according to Caton-Dechamps (6) (index more than 1.2 is a patella alta, less than 0.8 a patella infera)

| | Preoperative radiographs | | | | | | Postoperative radiographs | | | |
|------|--------------------------|--------------|--------------|--------------|-------------|---------------|---------------------------|--------------|-------------|---------------|
| Case | Trochlea type | Sulcus angle | Type patella | Wiberg angle | Caton-index | Patellar tilt | Sulcus angle | Wiberg angle | Caton-index | Patellar tilt |
| 1 | D | 150° | III - IV | 160° | 1.33 | 10° | 135° | 133° | 1.34 | 1° |
| 2 | D | 150° | III- IV | 171° | 1.01 | 17° | 132° | 137° | 0.98 | 1° |

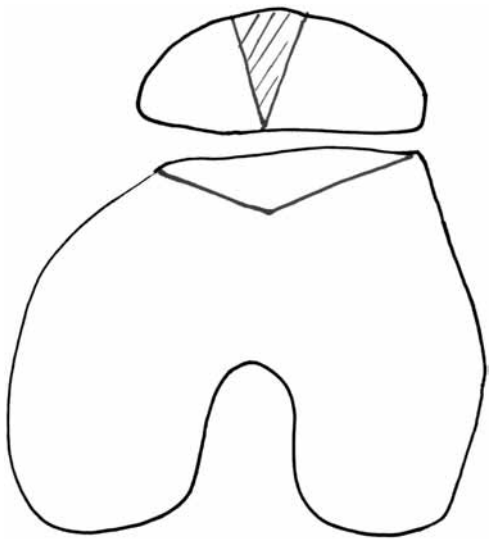


Fig. 1. — Drawing of the preoperative planning, showing the contour of the femoral trochlea before and after trochleoplasty, and the patellar bone wedge to be resected.

out apprehension for lateral subluxation and a correct tracking of the patella. No spells of instability or new dislocations were reported. Range of motion was 150-0-10°, equal to the preoperative range and symmetrical to the contralateral side.

Immediate postoperative recovery was also uneventful in the second case. At six weeks she presented without pain and a stable patella, but a reduced range of motion (40-10-0°). Unfortunately, she had a fall only a few days after the six week follow-up due to contralateral patellofemoral instability, a haemarthrosis necessitated aspiration of 120 ml of blood. At three months she presented with arthrofibrosis, with a range of motion of 60-0-0°. The patella however was subjectively and objectively stable. Because of the limited range of motion mobilisation under anaesthesia was performed 3.5 months after surgery and a range of motion of 150-0-5° was obtained during anaesthesia.

Both patients were seen at two years and two and a half years after surgery, respectively. The postoperative clinical parameters were stability during the apprehension test, a history of new dislocation or instability sensation, and subjective rating of the result (excellent, good, fair, poor). The radiological results are summarized in Table I, Figures 2C and

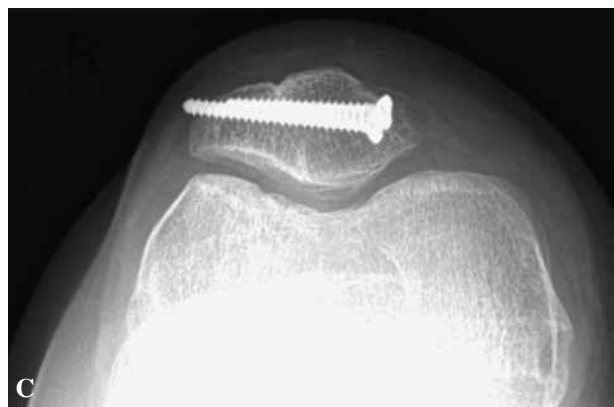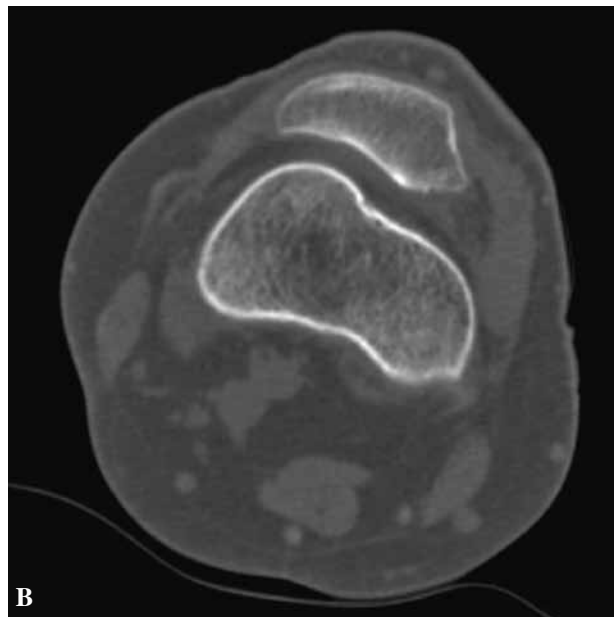
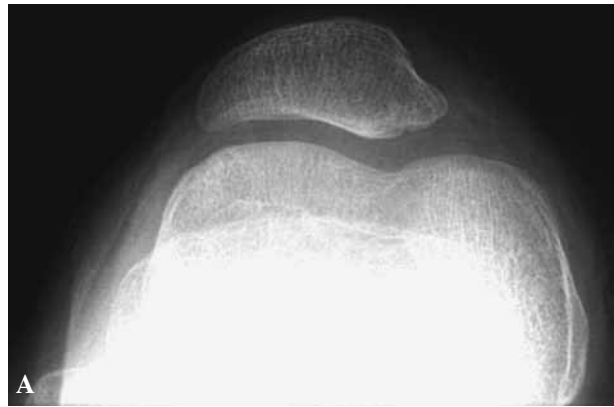


Fig. 2 A-C. — Preoperative patella sunrise view (A), preoperative axial CT image (B), and postoperative patella sunrise view (C) at the last follow-up of case no. 1. The last radiograph shows the congruency of the patellofemoral joint.

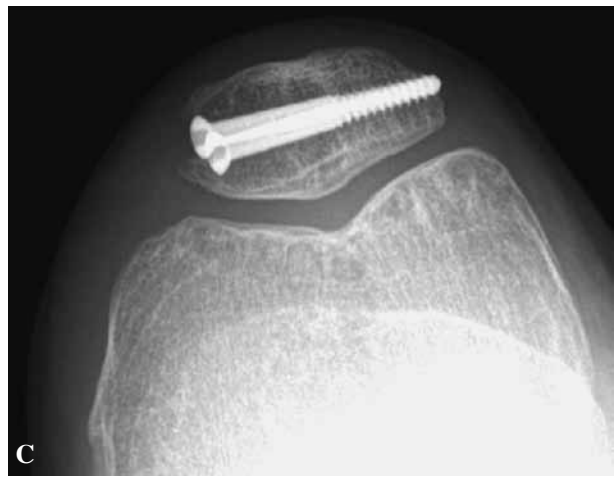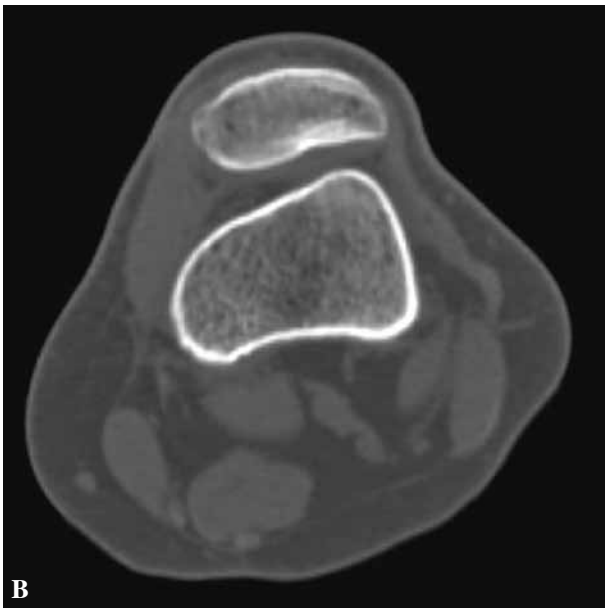

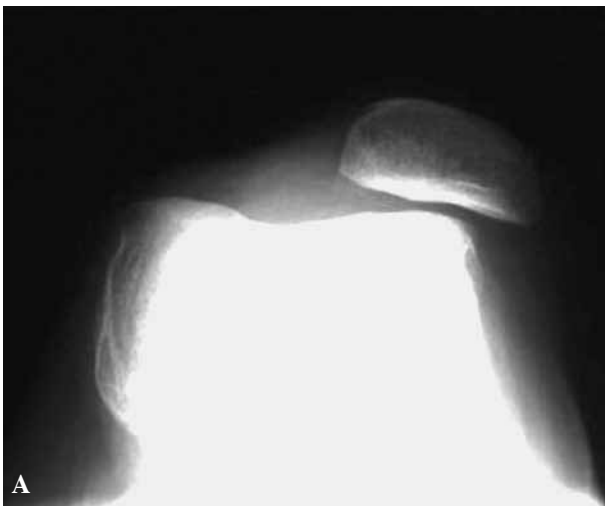
Fig. 3 A-C. — Preoperative patella sunrise view (A), preoperative axial CT image (B), and postoperative patella sunrise view (C) at the last follow-up of case no. 2. The last radiograph shows the congruency of the patellofemoral joint.

3C. The radiographs showed a united and well shaped patella with good congruency. There were no signs of necrosis or non-union.

DISCUSSION

Mild forms of patellar instability with trochlear dysplasia can be treated successfully with an MPFL-reconstruction (21). When the tibial tuberosity-trochlear groove (TTTG) distance is elevated or in case of patella alta, medialisation and/or distalisation of the tibial tuberosity reduces the forces on the

lateral facet and the risk of lateral dislocation (23). In severe cases of dysplasia however, a combination of trochleoplasty and patellar osteotomy and MPFL-reconstruction may be needed to balance the patella in the trochlear groove.

Trochleoplasty is a valuable treatment option for patients with patellofemoral instability and combined severe patellofemoral dysplasia, and the reported results often appear encouraging (11,15,20,24-26). However, patellofemoral dysplasia does not only affect the femoral trochlea, but also the patella. Following isolated surgical correction of the trochlear groove (12), a mismatch between the trochlea and the still flat and dysplastic patella remains. We present a new surgical technique, which allows adapting the dysplastic patella to the normalized trochlear shape.

The indication for patellar osteotomy was very restrictive and reserved for cases of extreme mismatch in the absence of other causes of instability such as ligamentous imbalance, knee malalignment and high or lateral riding patella. The combined operation will probably be of benefit in a larger number of patients than reported here, as many patients continue having a persistent instability after trochlear deepening (11,15,20,24-26). The final decision for a patellar osteotomy is taken during

surgery by direct observation of the tracking of the dysplastic patella.

Patellar necrosis or malunion remains a threat, particularly with previous extensive lateral release, but was not seen in our two patients.

Reports of patellar osteotomies are rare. Our technique must not be confounded with Morscher's sagittal dorsal open wedge osteotomy described in 1978 and designed as a pain reliever for persistent patellofemoral pain (18). Closing wedge osteotomy was first reported by Griss in five cases with incipient osteoarthritis. The results were good after one year follow-up (14). Dejour and Le Coultre (7) in a review of the literature, considered patellar osteotomy a very attractive adjunct to trochleoplasty in cases with a flat patella, but did not recommend the procedure because of a high rate of complications such as necrosis and non-union.

Only one article mentions patellar osteotomy in combination with trochleoplasty. Badhe and Forster (2) presented 4 patients suffering from patellar instability due to an underlying trochlea dysplasia and treated with elevation of the lateral femoral condyle according to Albee in combination with a dorsal closing wedge patellar osteotomy. The result was fair. The patella was stable but patients experienced residual patellofemoral pain, in the absence of necrosis or non-union. Elevation of the lateral condyle as described by Albee however increases the patellofemoral pressure; the technique has been abandoned for this reason (16).

In conclusion, closing wedge patellar osteotomy can be helpful in combination with trochleoplasty in patients with patellofemoral instability due to trochlear and patellar dysplasia. If trochleoplasty is done, patellar tracking should be carefully observed; in cases with serious incongruency, osteotomy of the patella may be considered.

REFERENCES

1. **Albee FH.** The bone graft edge in the treatment of habitual dislocation of patella. *Med Rec* 1915 ; 88 : 257-259.
2. **Badhe NP, Forster W.** Patellar osteotomy and Albee's procedure for dysplastic patellar instability. *Eur J Orthop Surg Traumatol* 2003 ; 13 : 43-47.
3. **Barnett AJ, Gardner RO, Lankester BJ, Wakeley CJ, Eldridge JD.** Magnetic resonance imaging of the patella : a comparison of the morphology of the patella in normal and dysplastic knees. *J Bone Joint Surg* 2007 ; 89-B : 761-765.
4. **Baumgartl F.** [Anatomical and clinical importance of the femoropatellar joint.] (in German). *Zentralbl Chir* 1966 ; 91 : 506-516.
5. **Bereiter H, Gautier E.** [Trochleoplasty in trochlea dysplasia with repetitive patella dislocation.] (in German). *Arthroskopie* 1994 ; 7 : 281-286.
6. **Caton J, Deschamps G, Chambat P et al.** [Patella infera. Apropos of 128 cases]. (in French). *Rev Chir Orthop Reparatrice Appar Mot* 1982 ; 68 : 317-325.
7. **Dejour D, Le Coultre B.** Osteotomies in patello-femoral instabilities. *Sports Med Arthrosc* 2007 ; 15 : 39-46.
8. **Dejour D, Reynaud P, Le Coultre B.** [Patellar pain and instability : a classification]. (in French). *Méd Hyg* 1998 ; 56 : 1466-1471.
9. **Dejour H, Walch G, Neyret P, Adeleine P.** [Dysplasia of the femoral trochlea.] (in French). *Rev Chir Orthop Reparatrice Appar Mot* 1990 ; 76 : 45-54.
10. **Dejour H, Walch G, Nove-Josserand L, Guier C.** Factors of patellar instability : an anatomic radiographic study. *Knee Surg Sports Traumatol Arthrosc* 1994 ; 2 : 19-26.
11. **Donell ST, Joseph G, Hing CB, Marshall TJ.** Modified Dejour trochleoplasty for severe dysplasia : operative technique and early clinical results. *Knee* 2006 ; 13 : 266-273.
12. **Fucentese SF, Schottle PB, Pfirrmann CW, Romero J.** CT changes after trochleoplasty for symptomatic trochlear dysplasia. *Knee Surg Sports Traumatol Arthrosc* 2007 ; 15 : 168-174.
13. **Fucentese SF, von Roll A, Koch PP et al.** The patella morphology in trochlear dysplasia – a comparative MRI study. *Knee* 2006 ; 13 : 145-150.
14. **Griss P.** [Modification of sagittal osteotomy of the patella as treatment of excentric chondromalacia or retropatellar arthrosis. Preliminary communication.] (in German). *Z Orthop Ihre Grenzgeb* 1980 ; 118 : 822-824.
15. **Koeter S, Pakvis D, van Loon CJ, van Kampen A.** Trochlear osteotomy for patellar instability : satisfactory minimum 2-year results in patients with dysplasia of the trochlea. *Knee Surg Sports Traumatol Arthrosc* 2007 ; 15 : 228-232.
16. **Kuroda R, Kambic H, Valdevit A, Andrish J.** Distribution of patellofemoral joint pressures after femoral trochlear osteotomy. *Knee Surg Sports Traumatol Arthrosc* 2002 ; 10 : 33-37.
17. **Masse Y.** [Trochleoplasty. Restoration of the intercondylar groove in subluxations and dislocations of the patella.] (in French). *Rev Chir Orthop Reparatrice Appar Mot* 1978 ; 64 : 3-17.
18. **Morscher E.** Osteotomy of the patella in chondromalacia. Preliminary report. *Arch Orthop Trauma Surg* 1978 ; 92 : 139-147.
19. **Roux C.** The classic. Recurrent dislocation of the patella : operative treatment. *Clin Orthop Relat Res* 1979 ; 144 : 4-8.

20. **Schottle PB, Fucentese SF, Pfirrmann C et al.** Trochleoplasty for patellar instability due to trochlear dysplasia : A minimum 2-year clinical and radiological follow-up of 19 knees. *Acta Orthop* 2005 ; 76 : 693-698.
21. **Schottle PB, Fucentese SF, Romero J.** Clinical and radiological outcome of medial patellofemoral ligament reconstruction with a semitendinosus autograft for patella instability. *Knee Surg Sports Traumatol Arthrosc* 2005 ; 13 : 516-521.
22. **Schottle PB, Romero J, Schmeling A, Weiler A.** Technical note : anatomical reconstruction of the medial patellofemoral ligament using a free gracilis autograft. *Arch Orthop Trauma Surg* 2008 ; 128 : 479-484.
23. **Servien E, Verdonk PC, Neyret P.** Tibial tuberosity transfer for episodic patellar dislocation. *Sports Med Arthrosc* 2007 ; 15 : 61-67.
24. **Utting MR, Mulford JS, Eldridge JD.** A prospective evaluation of trochleoplasty for the treatment of patellofemoral dislocation and instability. *J Bone Joint Surg* 2008 ; 90-B : 180-185.
25. **Verdonk R, Jansegers E, Stuyts B.** Trochleoplasty in dysplastic knee trochlea. *Knee Surg Sports Traumatol Arthrosc* 2005 ; 13 : 529-533.
26. **von Knoch F, Bohm T, Burgi ML et al.** Trochleoplasty for recurrent patellar dislocation in association with trochlear dysplasia. A 4- to 14-year follow-up study. *J Bone Joint Surg* 2006 ; 88-B : 1331-1335.
27. **Wiberg G.** Roentgenographic and anatomic studies on the femoropatellar joint. *Acta Orthop Scand* 1941 ; 12 : 319-410.