

The influence of sagittal cervical profile, gender and age on the thoracic kyphosis

Serkan ERKAN, Hüseyin S. YERCAN, Güvenir OKCU, R. Taçkın ÖZALP

From Celal Bayar University, School of Medicine, Manisa, Turkey

The objective of this prospective consecutive cohort study was to investigate the effect of sagittal cervical profile, gender and age on the thoracic kyphosis in 228 subjects, mainly adults, free of spinal complaints and with a thoracic kyphosis of less than 50°. The subjects, who were actually treated for lower extremity problems, were divided into two groups: the 68 subjects in group 1 (30%) had loss of cervical lordosis, while the 160 subjects in group 2 (70%) had a physiological cervical lordosis. In group 1 (loss of cervical lordosis) the mean angles of the upper (T1T6), lower (T7T12), and whole (T1T12) thoracic kyphosis were $8^\circ \pm 2$ (range: 3-28°), $15^\circ \pm 4$ (range: 6-40°), and $24^\circ \pm 6$ (range: 10-46°), respectively. In group 2 the normal cervical lordosis seemed to lead to a compensatory increase in these values: $13^\circ \pm 4$ (range, 4-35°) ($p = 0.008$), $21^\circ \pm 5$ (range: 6-45°) ($p = 0.012$), and $34^\circ \pm 8$ (range: 12-50°) ($p = 0.007$). In both groups gender had no significant effect on the values of the thoracic kyphosis ($p > 0.05$). Also age had no influence, neither in group 1 nor in group 2 as a whole, but in group 2 advanced age (> 50 years) was correlated with a significant increase in the lower (T7T12) ($p = 0.009$) and whole (T1T12) thoracic kyphosis ($p = 0.007$). This study yields standards for reference for the normal curvatures of the spine in the sagittal plane. The literature is quite controversial on this matter.

Keywords: sagittal cervical profile; gender; age; thoracic kyphosis.

INTRODUCTION

The significance of the sagittal curvatures of the spinal column has been reported previously (14). The thoracic curve is mostly seen as the primary curve, while the cervical and the lumbar curves are considered as secondary curves. However, some authors consider the cervical curve to be the primary curve, because it is already formed at approximately 10 weeks of fetal life.

-
- Serkan Erkan, MD, Assistant Professor.
 - Hüseyin S. Yercan, MD, Associate Professor.
 - Güvenir Okcu, MD, Associate Professor.
 - R. Taçkın Özalp, MD, Associate Professor.
- Celal Bayar University, School of Medicine, Department of Orthopaedics and Traumatology, Manisa, Turkey.*
- Correspondence: Serkan Erkan, MD, Department of Orthopaedics and Traumatology, School of Medicine, Celal Bayar University, Izmir cad. No:10, 45050, Manisa, Turkey.
E-mail: serkanerkan73@yahoo.com
- Part of this study was presented as a poster at the 8th Annual Meeting of the European Spine Society, October 25-28, 2006, in Istanbul, Turkey.
- © 2010, Acta Orthopædica Belgica.
-

It has been reported (17) that the prevalence of “loss of cervical lordosis” is 42% in asymptomatic patients, a ratio comparable with the ratio in the current study (30%); however, one third of these patients’ films were taken in a position of cervical kyphosis. A recent study (13) demonstrated that in individuals around 40 years of age and with no kyphotic deformity, the mean cervical lordotic curve was the lowest in a group with chronic neck pain, and the greatest in normal controls, with acute pain having the intermediate lordosis.

To the best of our knowledge, there has been only one study examining the relation between the sagittal profile of the cervical spine and the thoracic spine, more specifically in 8, 11 and 15-year-old children (18). This is why the current study focused on a mainly adult population.

PATIENTS AND METHODS

Between 2004 and 2009, 228 subjects, free of spinal problems but undergoing treatment for lower extremity problems, were included in this study. There were 127 females and 101 males, with an average age of 38.7 years (range: 13 to 72). All subjects who were asked agreed to take part in the study. The exclusion criteria were: previous history of spinal trauma, surgery, degenerative and systemic disease, and a thoracic kyphosis of more than 50°. The 228 volunteers were divided into two groups: group 1 consisted of 68 subjects (30%) with loss of cervical lordosis, and group 2 of 160 sub-

jects (70%) with physiological cervical lordosis (table I). For each patient medical history, physical examination, gender, age, height and weight were recorded.

The radiological assessment was carefully standardized. The subject stood in a relaxed position, holding onto a support at the level of the chest. Using the light beam of the X-ray machine, the shadow of a metal wire was projected onto the lateral aspect of the head, and this was used to define the inclination of the head. The angle to the horizontal line was adjusted to 20° and the head was orientated so that this line projected from the external opening of the ear to the eye (10). Cervical radiographs were made with the beam of the X-ray machine centred 15 cm below the ear at the standard distance of 183 cm. Lateral thoracic and whole spine radiographs were similarly taken, but at a lower level. The cervical lordosis was evaluated according to the posterior tangent technique originally described by Albers (1) and Gore *et al* (9): the lordosis was defined as the angle between the posterior walls of the vertebral bodies C2 and C7 (fig 1). Harrison *et al* (16) analyzed this technique and reported good inter- and intra-observer reliability, with a lower standard error of measurement (less than 2°) than with the Cobb method. The literature yields no definition of a normal cervical lordosis. For this reason we chose a tolerance of $\pm 4^\circ$ as a possible measurement error, with 95% confidence intervals (6,10,23), and therefore defined physiological lordosis as $< -4^\circ$ (negative = lordotic), and cervical kyphosis as

Table I. — Demographics

	Group 1 : loss of cervical lordosis : 68 subjects or 30%		Group 2 : normal cervical lordosis : 160 subjects or 70%		p value
Cervical sagittal curve (Mean, SD) (negative value = lordotic curvature)	-2.4° ± 1.4°		-18.2° ± 13.2°		< 0.001
Gender (F/M)	57%F	43%M	54%F	46%M	0.71
Age (Mean, SD)	37.9 ± 12.7y		39.4 ± 13.6y		0.63
Height (F/M)	166.2 ± 6.8cm	174.5 ± 8.1cm	164.9 ± 6.2cm	176 ± 7.9cm	0.42
Weight (F/M)	72.4 ± 10.6kg	84.5 ± 11.4kg	70.8 ± 9.7kg	82.3 ± 10.8kg	0.55
Global sagittal alignment (modified technique)	68 ± 9mm		74 ± 6mm		0.12

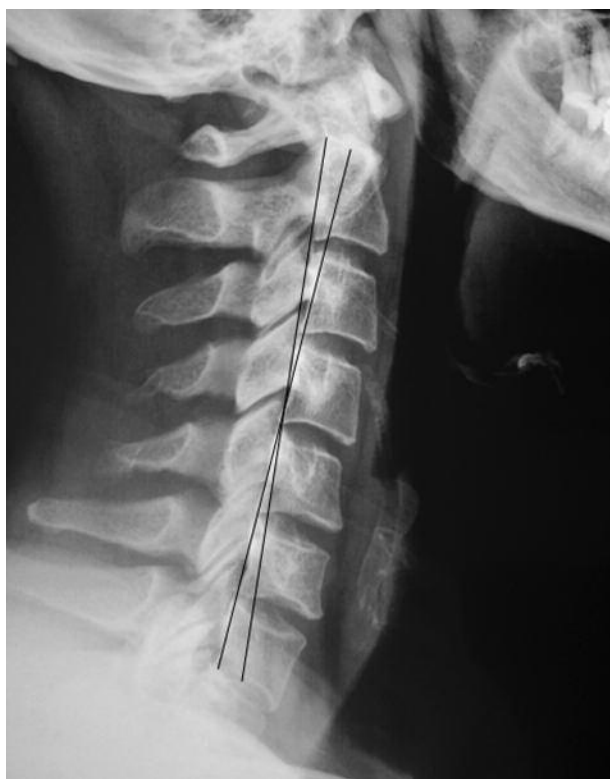

Fig. 1. — Posterior tangent method of Harrison *et al* (16) : the angle formed by the tangent lines at the posterior margins of the vertebral bodies C2 and C7 is a measure of the cervical sagittal curve.

+4° (positive = kyphotic), while the grey area in between or “loss of cervical lordosis” was defined as +4° to -4° (19). The upper (T1-T6), the lower (T6-T12), and the whole (T1-T12) thoracic kyphosis were measured by means of the Cobb method. Global sagittal alignment was analyzed by measuring the horizontal distance between the plumb line (a vertical line drawn through the center of C7 vertebra) and the posterior (modified technique : classically the *anterior*) superior corner of the sacrum. All the measurements were done by the same observer (SE).

Statistical analysis was performed using SPSS version 11.0 (Chicago, IL). Differences in continuous variables between group 1 and group 2 were examined with an unpaired t-test. The Pearson’s correlation coefficient test was used to evaluate the influence of cervical lordosis, gender and age on

upper, lower, and whole thoracic kyphosis. Significance was defined as $p < 0.05$.

RESULTS

Comparability of the study groups

Group 1 and 2 were comparable with regard to their gender distribution (F/M = 57%/43% versus 54%/46% : $p = 0.71$) (table I). They were also of comparable age (37.9 years, SD 12.7, range 13–70, versus 39.4 years, SD 13.6, range : 12–72) : $p = 0.63$. No significant height ($p = 0.42$) or weight ($p = 0.55$) differences were observed. As to global sagittal alignment (the mean distance between the plumb line from the center of C7 and -in the current study- the *posterior* superior corner of the sacrum) : 68 ± 9 mm in group 1 and 74 ± 6 mm in group 2, which was absolutely comparable ($p = 0.12$). The plumb line fell anterior to the posterior superior corner of the sacrum on all radiographs.

Influence of sagittal cervical profile on thoracic kyphosis

In group 1 (loss of cervical lordosis) the upper, lower and whole thoracic kyphosis were not pronounced : respectively $8 \pm 2^\circ$ (range : 3-28°), $15 \pm 4^\circ$ (range, 6-40°), and $24 \pm 6^\circ$ (range : 10-46°). In group 2 (physiological cervical lordosis) the normal lordosis seemed to lead to a compensatory increase of these curves : $13 \pm 4^\circ$ (range : 4-35°), $21 \pm 5^\circ$ (range : 6-45°), and $34 \pm 8^\circ$ (range : 12-50°), respectively. The differences with group 1 were significant : $p = 0.008$, $p = 0.012$, and $p = 0.007$ (fig 2).

Influence of gender on thoracic kyphosis

In group 1 gender had no influence on upper, lower and whole thoracic kyphosis : $p = 0.78$, $p = 0.86$, and $p = 0.81$. In group 2 the same statement could be made : $p = 0.72$, $p = 0.66$, and $p = 0.69$.

Influence of age on thoracic kyphosis

In group 1, no significant correlation was found between age and upper, lower and whole thoracic

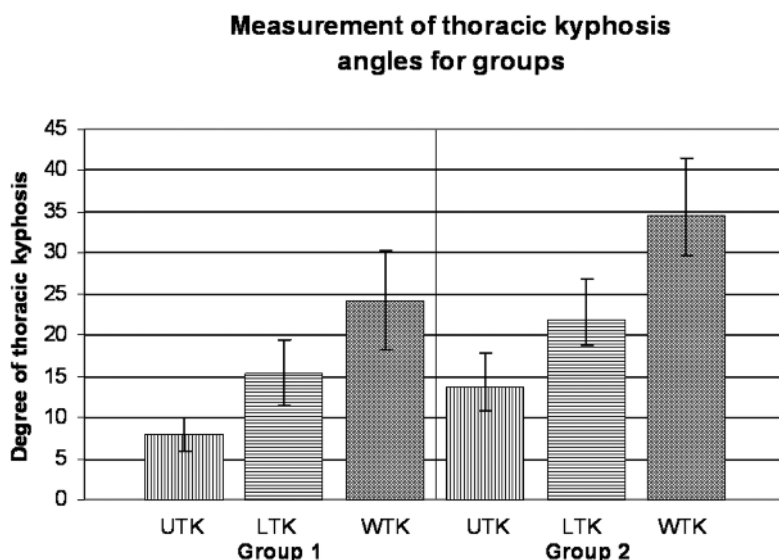


Fig. 2. — In group 1 (loss of cervical lordosis) the upper (UTK), lower (LTK), and whole (WTK) thoracic kyphosis were significantly less pronounced than in group 2 (normal cervical lordosis), apparently because in group 2 the kyphosis compensated for the more pronounced cervical curve.

kyphosis : $p = 0.066$, $p = 0.082$ and $p = 0.075$. In group 2, the same was true, but if individuals older than 50 were compared with those younger than 50, there was a significant increase in the lower and whole thoracic kyphosis : $p = 0.009$ and $p = 0.007$ (fig 3).

DISCUSSION

This is the first study to investigate the influence of cervical sagittal curvature, age, and gender on the upper, lower and whole thoracic kyphosis in mainly adult asymptomatic subjects.

Several methods have been described for the evaluation of the sagittal curvature of the cervical spine (1,9,16). There is a consensus that a lordotic curvature constitutes the “physiological” or “normal” situation for the cervical spine (14), however, the exact values and the recommended methods of measurement are not clearly described. Normal limits have been published ranging from -20° to -35° for C2C7 (3,8,11,22), but these values are highly related to the method of measurement used and the positioning of the patient during the radiograph. Moreover, factors such as tilt of the pelvis, sitting or standing position, shape of the back rest when sit-

ting, and head position can all influence the sagittal curve of the cervical spine (17,20,22). We used the roentgenographic approach described by Grob *et al* (10). We assumed that keeping the head position in a standardized position would limit any possible drawbacks in this respect.

We used the posterior tangent method to evaluate the sagittal cervical curvature (8,22,25). We chose a tolerance of $\pm 4^\circ$ as a possible measurement error, with 95% confidence intervals (6,10,23), and therefore defined physiological lordosis as $< -4^\circ$, and cervical kyphosis as $> +4^\circ$, while the grey area in between or “loss of cervical lordosis” was defined as $+4^\circ$ to -4° . This scale led to an average physiological cervical lordosis of $-18.2 \pm 13.2^\circ$ in 70% of the subjects (group 2) (table I), which was consistent with the findings of Gore *et al* (8), Harrison *et al* (15), and Nojiri *et al* (22) : respectively $-23 \pm 21^\circ$, -34° (range-16.5 to $+66^\circ$) and $-16.2 \pm 12.9^\circ$. The same scale led to an average “loss of cervical lordosis” of $-2.4 \pm 1.4^\circ$, in 30% of the subjects (group 1) (table I). This last incidence was lower in most other comparable studies : 7.2% according to Borden *et al* (3), 19% according to Juhl *et al* (20), 7.4% according to Hald *et al* (11), and 42% according to Helliwell *et al* (18). The high incidence of

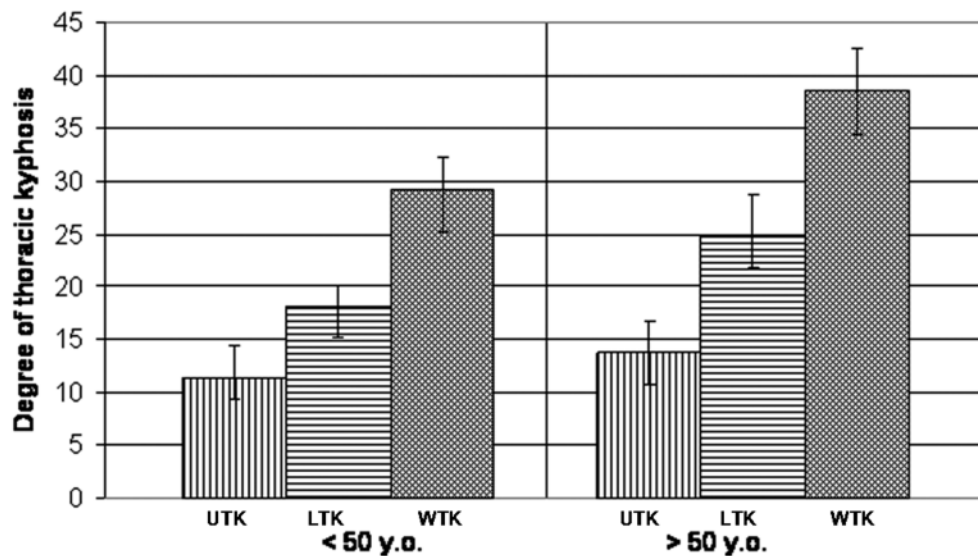


Fig. 3. — In group 2 (normal cervical lordosis) subjects above age 50 have a significant increase of the lower and whole thoracic kyphosis (UTK : upper thoracic kyphosis ; LTK : lower thoracic kyphosis ; WTK : whole thoracic kyphosis).

“loss of cervical lordosis” in the present study can be attributed to the fact that different measurement techniques (depth of curvature, categorisation in relation to the aspect) were used in the other studies.

Influence of cervical sagittal curve on thoracic kyphosis : we observed that patients with loss of cervical lordosis (group 1) also had a less pronounced upper, lower, and whole thoracic kyphosis than patients with a physiological cervical lordosis. This is consistent with the findings of Hardacker *et al* (12). Cervical and thoracic sagittal curves seem to compensate each other. In contrast, Hellsing *et al* (18) found no such correlation, but all their subjects were children.

Gender : Hardacker *et al* (12) observed that statistically men had a more pronounced cervical lordosis than women. Also Helliwel *et al* (17) reported that women were more likely to have loss of cervical lordosis than men. But Gore *et al* (8) found no significant effect of gender on cervical spinal alignment. However, these studies did not group patients as having either “loss of cervical lordosis” or “physiological lordosis”. In the current study, we observed no effect of gender on “loss of cervical lordosis” or “physiological lordosis”, as women were equally represented in group 1 and 2. Moreover, gender had no

effect on the upper, lower, and whole thoracic kyphosis, neither in group 1 nor in group 2. These findings concur with those of Gelb *et al* (7) who found no difference between females and males as to thoracic kyphosis.

Age : Gore *et al* (8) observed a significant increase in the *cervical lordosis* between age 20-25 and age 40-45, in women as well as in men. Hardacker *et al* (12) also noted this correlation. In contrast with these findings, we did not observe any such correlation. Moreover, in the current study we found no significant correlation between age and the degree of the upper, lower, and whole *thoracic kyphosis*, neither in group 1 nor in group 2. However, in group 2, subjects older than 50 years, had a significant increase in the lower and the whole thoracic kyphosis. This finding was not supported by Hardacker *et al* (12) and Gelb *et al* (7) who found no correlation between increasing age and thoracic kyphosis.

A limitation of this study is the fact that it did not check intra- and inter-observer reliability, as all measurements were made only once by the same observer (SE). In conclusion, this study yields standards for reference for the normal curvatures of the sagittal plane of the spine. The literature is quite controversial on this matter.

REFERENCES

1. **Albers D.** [Study on the function of the cervical vertebral column in dorsal and ventral flexion.] (in German) *Fortschr Geb Röntgenstr* 1954 ; 81 : 606-615.
2. **Bagnall KM, Harris PF, Jones PR.** A radiographic study of the human fetal spine. I. The development of the secondary cervical curvature. *J Anat* 1977 ; 123 : 777-782.
3. **Borden AG, Rechtman AM, Gershon-Cohen J.** The normal cervical lordosis. *Radiology* 1960 ; 74 : 806-809.
4. **Broberg KB.** On the mechanical behaviour of the intervertebral discs. *Spine* 1983 ; 8 : 151-165.
5. **Clausen JD, Goel VK, Traynelis VC, Scriver J.** Uncinate processes and Luschka joints influence the biomechanics of the cervical spine : quantification using a finite element model of the C5-C6 segment. *J Orthop Res* 1997 ; 15 : 342-347.
6. **Frobin W, Brinckmann P, Leivseth G, Biggemann M, Reikeras O.** Precision measurement of segmental motion from flexion-extension radiographs of the lumbar spine. *Clin Biomech* 1996 ; 11 : 457-465.
7. **Gelb DE, Lenke LG, Bridwell KH, Blanke K, McEneaney KW.** An analysis of sagittal spinal alignment in 100 asymptomatic middle and older aged volunteers. *Spine* 1995 ; 20 : 1351-1358.
8. **Gore DR, Sepic SB, Gardner GM.** Roentgenographic findings of the cervical spine in asymptomatic people. *Spine* 1986 ; 11 : 521-524.
9. **Gore DR, Sepic SB, Gardner GM, Murray MP.** Neck pain : a long-term follow-up of 205 patients. *Spine* 1987 ; 12 : 1-5.
10. **Grob D, Frauenfelder H, Mannion AF.** The association between cervical spine curvature and neck pain. *Eur Spine J* 2007 ; 16 : 669-678.
11. **Hald HJ, Danz B, Schwab R, Burmeister K, Bahren W.** Radiographically demonstrable spinal changes in asymptomatic young men. *Rofo* 1995 ; 163 : 4-8.
12. **Hardacker JW, Shuford RF, Capicotto PN, Pryor PW.** Radiographic standing cervical segmental alignment in adult volunteers without neck symptoms. *Spine* 1997 ; 22 : 1472-1480.
13. **Harrison DD, Harrison DE, Janik TJ et al.** Modeling of the sagittal cervical spine as a method to discriminate hypolordosis : results of elliptical and circular modeling in 72 asymptomatic subjects, 52 acute neck pain subjects, and 70 chronic neck pain subjects. *Spine* 2004 ; 29 : 2485-2492.
14. **Harrison DD, Troyanovich SJ, Harrison DE, Janik TJ, Murphy DJ.** A normal sagittal spinal configuration : a desirable clinical outcome. *J Manipulative Physiol Ther* 1996 ; 19 : 398-405.
15. **Harrison DE, Bula JM, Gore DR.** Roentgenographic findings in the cervical spine in asymptomatic persons : a 10-year follow-up. *Spine* 2002 ; 27 : 1249-1250.
16. **Harrison DE, Harrison DD, Cailliet R et al.** Cobb method or Harrison posterior tangent method : which to choose for lateral cervical radiographic analysis. *Spine* 2000 ; 25 : 2072-2078.
17. **Helliwell PS, Evans PF, Wright V.** The straight cervical spine : does it indicate muscle spasm ? *J Bone Joint Surg* 1994 ; 76-B : 103-106.
18. **Helsing E, Reigo T, McWilliam J, Spangfort E.** Cervical and lumbar lordosis and thoracic kyphosis in 8, 11 and 15-year-old children. *Eur J Orthod* 1987 ; 9 : 129-138.
19. **Hopkins WG.** Measures of reliability in sports medicine and science. *Sports Med* 2000 ; 30 : 1-15.
20. **Juhl JH, Miller SM, Roberts RM.** Roentgenographic variations in the normal cervical spine. *Radiology* 1962 ; 78 : 591-597.
21. **Morningstar M.** Cervical curve restoration and forward head posture reduction for the treatment of mechanical thoracic pain using the pettibon corrective and rehabilitative procedures. *J Chiropr Med* 2002 ; 1 : 113-115.
22. **Nojiri K, Matsumoto M, Chiba K et al.** Relationship between alignment of upper and lower cervical spine in asymptomatic individuals. *J Neurosurg* 2003 ; 99 (1 Suppl) : 80-83.
23. **Panjabi M, Chang D, Dvorak J.** An analysis of errors in kinematic parameters associated with in vivo functional radiographs. *Spine* 1992 ; 17 : 200-205.
24. **Panjabi MM, Oda T, Crisco JJ3rd, Dvorak J, Grob D.** Posture affects motion coupling patterns of the upper cervical spine. *J Orthop Res* 1993 ; 11 : 525-536.
25. **Wiegand R, Kettner NW, Brahee D, Marquina N.** Cervical spine geometry correlated to cervical degenerative disease in a symptomatic group. *J Manipulative Physiol Ther* 2003 ; 26 : 341-346.